



Since January 2020 Elsevier has created a COVID-19 resource centre with free information in English and Mandarin on the novel coronavirus COVID-19. The COVID-19 resource centre is hosted on Elsevier Connect, the company's public news and information website.

Elsevier hereby grants permission to make all its COVID-19-related research that is available on the COVID-19 resource centre - including this research content - immediately available in PubMed Central and other publicly funded repositories, such as the WHO COVID database with rights for unrestricted research re-use and analyses in any form or by any means with acknowledgement of the original source. These permissions are granted for free by Elsevier for as long as the COVID-19 resource centre remains active.

COVID-19-related organ dysfunction and management strategies on the intensive care unit: a narrative review

Peter B. Sherren^{1,*}, Marlies Ostermann¹, Sangita Agarwal², Christopher I. S. Meadows¹, Nicholas Ioannou¹ and Luigi Camporota¹

¹Department of Critical Care Medicine, UK and ²Department of Rheumatology, Guy's and St Thomas' NHS Foundation Trust, London, UK

*Corresponding author. E-mail: Peter.Sherren@gstt.nhs.uk

Summary

The coronavirus disease 2019 (COVID-19) pandemic has resulted in a significant surge of critically ill patients and an unprecedented demand on intensive care services. The rapidly evolving understanding of pathogenesis, limited disease specific evidence, and demand-resource imbalances have posed significant challenges for intensive care clinicians. COVID-19 is a complex multisystem inflammatory vasculopathy with a significant mortality implication for those admitted to intensive care. Institutional strategic preparation and meticulous intensive care support are essential to maximising outcomes during the pandemic. The significant mortality variation observed between institutions and internationally, despite a single aetiology and uniform presentation, highlights the potential influence of management strategies on outcome. Given that optimal organ support and adjunctive therapies for COVID-19 have not yet been well defined by trial-based outcomes, strategies are predicated on existing literature and experiential learning. This review outlines the relevant pathophysiology and management strategies for critically ill patients with COVID-19, and shares some of the collective learning accumulated in a high volume severe respiratory failure centre in London.

Keywords: ARDS; COVID-19; ECMO; MODS; respiratory failure; SARS-CoV-2; ventilation

Editor's key points

- COVID-19 is a complex, multisystem, inflammatory vasculopathy with a significant risk of mortality.
- The marked variability in mortality rates observed in the published literature, despite limited disease heterogeneity, highlights the importance of institutional strategic preparation and meticulous intensive care support.
- This narrative review outlines the relevant pathophysiology and management strategies for critically ill patients with COVID-19, and shares the collective learning accrued in a high-volume severe respiratory failure centre in the UK.

Severe acute respiratory distress syndrome coronavirus 2 (SARS-CoV-2) is a novel enveloped RNA beta-coronavirus associated with coronavirus disease 2019 (COVID-19).¹ The viral genomic sequence and clinical significance was outlined by the WHO on January 12 2020, and has since been declared a global pandemic.² The first case in the UK was confirmed on the January 31, 2020, and by the end of June, there had been 312 654 confirmed cases and 43 730 deaths.³

Guy's and St. Thomas' NHS Foundation Trust is one of six severe respiratory failure (SRF) centres in the UK, and offers a complete spectrum of advanced respiratory support including extracorporeal membrane oxygenation (ECMO). By virtue of its central London location and SRF referral network covering a population of 18 million people, the critical care department has admitted 329 patients with COVID-19 to date, including 58 mobile ECMO retrievals. This has facilitated a rapid learning of

Received: 7 July 2020; Accepted: 31 August 2020

Crown Copyright © 2020 Published by Elsevier Ltd on behalf of British Journal of Anaesthesia. All rights reserved.

For Permissions, please email: permissions@elsevier.com

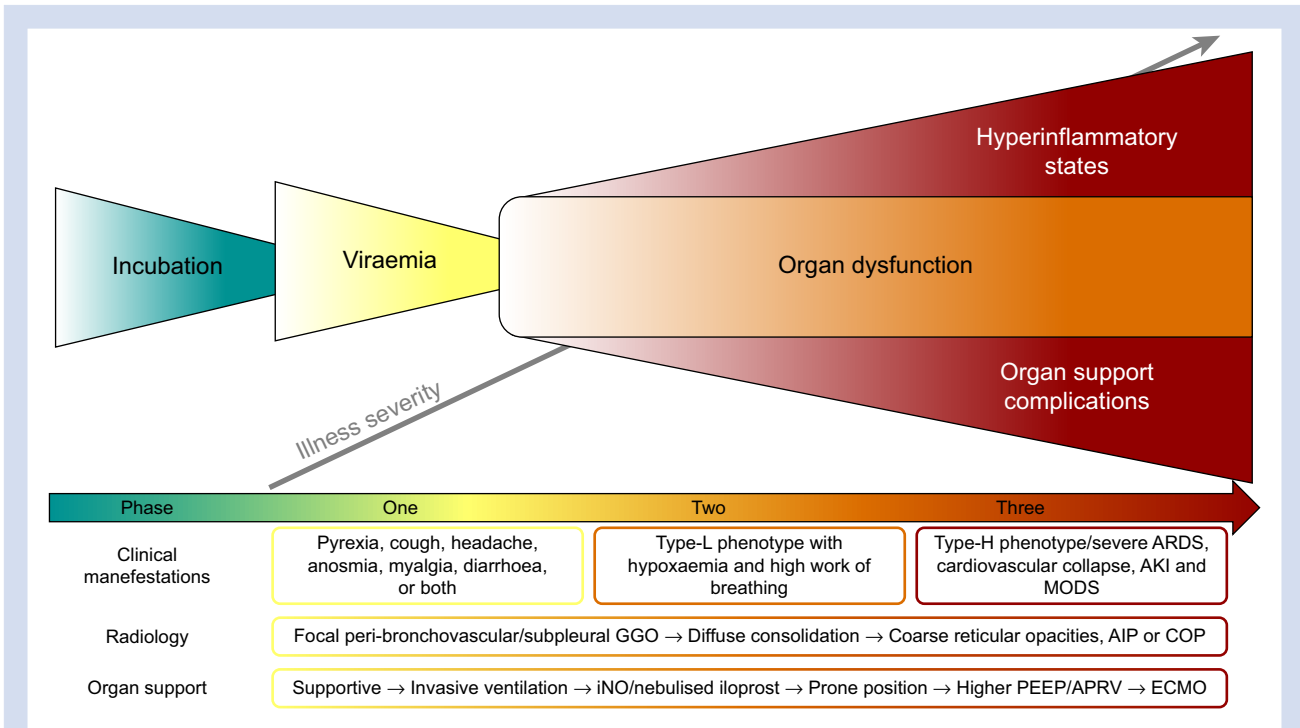


Fig 1. Three phases of coronavirus disease 2019 (COVID-19). AIP, acute interstitial pneumonitis; AKI, acute kidney injury; APRV, airway pressure release ventilation; ARDS, acute respiratory distress syndrome; COP, cryptogenic organising pneumonia; ECMO, extracorporeal membrane oxygenation; GGO, ground glass opacities; Ino, inhaled nitric oxide; MODS, multiorgan dysfunction syndrome.

disease behaviour and emerging phenotypes, and allowed tailored patient therapies to evolve accordingly. Despite a significant surge of patients, the authors have been encouraged by their 71.1% survival to critical care discharge,⁴ which compares favourably to large contemporaneous datasets in the UK and Italy.^{5,6} This narrative review looks at the relevant pathophysiology and management strategies for critically ill COVID-19 patients, and shares some of the collective learning accrued in a quaternary SRF centre.

History and presentation

The majority of early SARS-CoV-2 infections were related to zoonotic exposure in Huanan Seafood Wholesale Market in Wuhan, China; however, human-to-human transmission has since been demonstrated in the initial outbreak.⁷ Although respiratory tract related droplets likely account for the majority of new infections, there is increasing interest in the potential for fomite, aerosol, and faeco-oral transmission.⁸ These factors, combined with a large proportion of infectious patients with only mild or asymptomatic carriage,⁹ makes pertinent contact and travel history insensitive tools for stratifying the risk of COVID-19.

Beta-coronaviruses enter the body predominantly through the angiotensin converting enzyme-2 (ACE2) receptors, and this is followed by intracellular translocation.¹⁰ The abundance of ACE2 receptors within the lower respiratory tract explains the high incidence of cough (67.8%) amongst symptomatic cases at presentation.¹¹ COVID-19 may also be associated with pyrexia (43.8%), fatigue (38.1%), anosmia (19.4%), myalgia (14.9%), sore throat (13.9%), headache (13.6%), and

diarrhoea (3.8%).^{11,12} Disease severity can be highly variable ranging from asymptomatic through to fulminant multiorgan failure. These variations may be related to the route of transmission, inoculation dose, and host immunity status.¹³

The median (inter-quartile range [IQR]) incubation period, time from first symptoms to hospital admission, and first symptoms to developing acute respiratory distress syndrome (ARDS) are 4 days (IQR, 2–7), 7 days (IQR, 4–8), and 8 days (IQR, 6–12), respectively.^{11,14} To date, the 10 624 patients requiring critical care in the UK have been predominantly male (70.2%) with a median age of 60 (IQR, 51–68) yr and an increased BMI > 25 kg m⁻² (73.7%).⁵ Critically ill patients are also more likely to have a smoking history and underlying cardiovascular comorbidities.^{10,14}

Given the variability in host response during different stages of COVID-19, the authors have found it helpful to conceptualise three phases of illness after an incubation period (Fig. 1). Although these phases represent a continuum of disease, the varied behaviour observed in certain phases may lend themselves to time-sensitive tailored therapies:

1. Phase one (0–7 days after symptoms develop): rapid viral replication and innate immune response phase resulting in the symptomatology outlined, lymphopaenia, and elevated inflammatory biomarkers and cytokine concentrations.¹⁵ In this early phase, focal peri-bronchovascular and subpleural ground glass opacities on CT can precede respiratory symptoms.¹⁶
2. Phase two (5–14 days after symptoms develop): organ dysfunction phase related to ongoing viral cytopathy and emerging adaptive immune response. Two


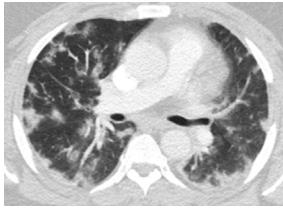
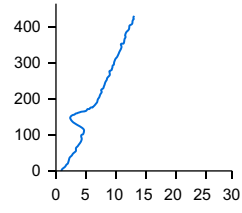
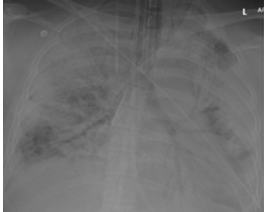

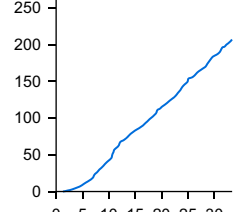
Phenotype	Chest radiograph	CT	Low flow PV curve (x-axis cm H ₂ O, y-axis ml)	Gas exchange and pulmonary mechanics
Type-L				<ul style="list-style-type: none"> • PF ratio=11.8 kPa • Cstat=37.9 ml cm H₂O⁻¹ • C20/Cstat=1.06 • LIP=2 cm H₂O • R/I ratio=0.02
Type-H				<ul style="list-style-type: none"> • PF ratio=8.6 kPa • Cstat=10.4 ml cm H₂O⁻¹ • C20/Cstat=0.82 • LIP=11 cm H₂O • R/I ratio=0.72

Fig 2. Comparison of two typical coronavirus disease 2019 (COVID-19) patients with the Type-L and Type-H phenotypes contrasting chest radiographs, CT, quasi-static pressure-volume loop, gas exchange, and pulmonary mechanics ($P_{a_{O_2}}/F_{iO_2}$, Cstat, static lung compliance; C20/Cstat, ratio of static compliance in the last 20% of inspiration to total compliance; LIP, lower inflection point; R/I ratio, recruitment-to-inflation ratio).

divergent groups appear to develop with an acute respiratory failure necessitating early invasive ventilatory support and those with more indolent organ dysfunction.¹⁵

- Phase three (>10 days after symptoms develop): this late deterioration despite invasive organ support is mediated by either:
 - Hyperinflammation: dysregulated immune response appears to take the form of either a persistent systemic hyperinflammatory state, a more limited pulmonary hyperinflammation or rarely idiosyncratic hyperinflammatory syndromes such as secondary haemophagocytic lymphohistiocytosis (sHLH) or cytokine release syndrome (CRS).¹⁷
 - Organ support complications: the severe pulmonary inflammation observed in COVID-19 appears to be exquisitely sensitive to the myriad of complications of critical illness and organ support; including patient self-inflicted lung injury, ventilator-induced lung injury, extravascular lung water (EVLW) accumulation, nosocomial infections, and multiorgan dysfunction syndrome.^{18–20}

Respiratory system

Despite profound hypoxaemic respiratory failure being the dominating clinical feature of COVID-19, a unifying explanation of the pathophysiology remains contentious.^{21,22} Betacoronaviruses usually enter the body through the binding of surface spike glycoprotein via the variable receptor-binding-protein (mutated RaTG13) to the ACE2 receptors, and this is followed by intracellular translocation of virions through endocytosis or direct cell membrane fusion.¹⁰ ACE2 receptors are expressed principally on type II pneumocytes but can also

be found within the kidney, enterocytes, and cardiac myocytes.^{10,13} SARS-CoV-2 can elicit a pronounced inflammatory response through antigen presenting cells, and induction of cytokines and chemokines.¹⁰ It remains uncertain what proportion of the pneumonitis and increased vascular permeability is driven by the viral cytopathy or dysregulated immune response.

The hypoxaemia seen in the early stages of COVID-19 has a different pathophysiology to that described in typical ARDS. Type-L phenotype presents with focal subpleural and peribronchovascular ground glass opacifications, limited atelectasis, low EVLW, and low elastance, and the main mechanism seems to be ascribed to a dysregulation of pulmonary perfusion.²² Recent histological data suggest an early isolated lymphocytic viral pneumonia in COVID-19 with later transition to an acute fibrinous and organising pneumonia.²³ Whilst the validity of such respiratory phenotypes in COVID-19 has been widely debated, it is important to remember that ARDS has never been a distinct diagnosis but rather a syndrome with a number of sub-phenotypes and different aetiologies.²⁴ This syndrome represents a final common pathway for a hugely heterogeneous group of diseases that may require biologically targeted therapies in addition to lung protective ventilation (LPV).

These focal ground glass opacifications observed in early disease cannot fully explain the significant shunt fraction often observed. The aetiology of this early respiratory failure and disproportionate hypoxaemia is likely multifactorial:

- Pulmonary vasculopathy with loss of adaptive hypoxic pulmonary vasoconstriction and dysregulated pulmonary perfusion.^{21,22} Although the pivotal role ACE2 receptors play in SARS-CoV-2 transmission is well defined, their expression within the pulmonary endothelium and role in dysregulated pulmonary perfusion is now becoming apparent.²¹ The carboxypeptidase ACE2

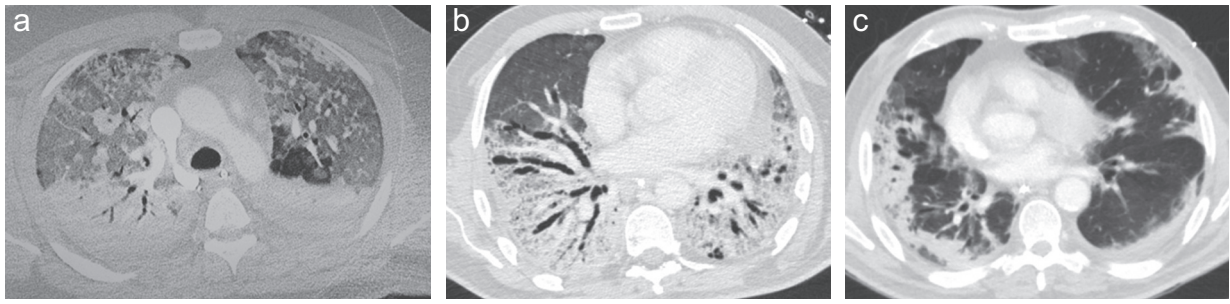


Fig 3. Admission CT of three coronavirus disease 2019 (COVID-19) patients requiring retrieval to the severe respiratory failure unit at Guy’s and St. Thomas’ NHS Foundation Trust after extracorporeal membrane oxygenation implantation at the referring centre. (a) A 44-yr-old male referred after 5 days of invasive ventilation. CT shows classical acute respiratory distress syndrome pattern with diffuse ground glass opacities and dorsal consolidation/atelectasis. Required standard intensive care therapies and no immunomodulation. (b) A 52-yr-old male with CT demonstrating more extensive parenchymal distortion/fibrosis and traction bronchiectasis typical of acute interstitial pneumonitis or Hamman-Rich syndrome after 7 days of invasive ventilation and preceding noninvasive ventilation. Pulsed methylprednisolone (500 mg for 3 days) utilised followed by tapering course. (c) A 32-yr-old male admitted with severe respiratory failure, vasoplegia (norepinephrine $1.7 \mu\text{g kg}^{-1} \text{min}^{-1}$), and normal biventricular function related to cytokine release syndrome. Ferritin of $12\,000 \text{ ng ml}^{-1}$ and CT appearances of cryptogenic organising pneumonia with occasional reverse halos noted (Atoll sign). Immunomodulation in the form of i.v. immunoglobulin, methylprednisolone 1 mg kg^{-1} twice daily, and anakinra.

counteracts the renin-angiotensin-aldosterone system through conversion of angiotensin-I and -II to angiotensin-(1–9) and -(1–7), respectively, these then promote localised vasodilation and attenuation of the immune response.²⁵ The initial downregulation of ACE2 results in angiotensin-II accumulation with resulting chemotactic effects and accelerated lymphocyte recruitment.^{21,26} The resulting pulmonary vascular inflammation results in an ACE1 ‘shedding’ phenomenon where endothelial surface-bound ACE1 is released into the interstitium and ultimately results in sub-physiologic angiotensin-II concentrations.²⁶ Low angiotensin-II concentrations in this phase lead to vasodilation and worsened capillary leak.

- The high incidence of pulmonary microvascular and macrovascular thrombosis offers insight into the high compliance, increased dead space, D-dimer elevation, and right ventricular dysfunction frequently observed in COVID-19 and documented in post-mortem findings and histology.^{21,23,27–29}
- The neurotropic potential of SARS-CoV-2 with altered central control of breathing mediated by pontine pneumotaxic centre dysfunction which results in increased tidal volumes relative to ventilatory frequency. Although low pulmonary elastance partially explains the deceptively effortless work of breathing,³⁰ infiltration of SARS-CoV-2 into the CSF and impaired brainstem autor-regulation may also contribute.^{31,32}
- Increased basal metabolic rate resulting in higher tissue oxygen extraction, lower mixed venous oxygen content, and increased venous admixture.³³
- Increased intrapulmonary shunt fraction with cardiac output elevation.^{34,35} Although high peripheral oxygen extraction partially explains the increased venous admixture observed in catabolic states, there may also be alterations in regional pulmonary blood flow distinct from this related to increased cardiac output.^{33–35} The contributions oxygen extraction and cardiac output play

on arterial oxygen content can be seen when the Fick equation is rearranged: $\text{CaCO}_2 = \text{CvO}_2 + \text{VO}_2/\text{CO}$.

- Iatrogenic component through excess PEEP application to compliant non-atelectatic alveoli resulting in over-distention, increased dead space ventilation, and modification of shunt fraction because of redistribution of pulmonary perfusion.³⁶

Whilst many will recover from the type-L pattern with supportive measures, a proportion of patients will progress through to the type-H pattern. These two phenotypes do not represent discrete entities but a *continuum*, with a transition typically mediated by injurious organ support and hyper-inflammatory states.²² With the transition there are a number of associated changes in radiography and pulmonary mechanics outlined in Figure 2. The type-H phenotype more closely resembles ‘classical’ ARDS on CT with high EVLW, atelectasis, and increased non-aerated pulmonary units in the dependent areas, which results in significantly smaller normally aerated lung volume, high elastance, and higher potential for lung recruitment.²² This late phase three deterioration in pulmonary mechanics and oxygenation often coincides with referral for ECMO in our experience, typically 4–8 days after initiation of invasive ventilation. The early identification of other distinct CT patterns, such as acute interstitial pneumonia or cryptogenic organising pneumonias, is important for detecting any associated interstitial lung disease component and accelerated fibrosis that may benefit from a tailored immunomodulation strategy (Fig. 3).³⁷

With the heterogenous disease behaviour observed, it follows that the intensive care support and therapies should be tailored accordingly (Fig. 4). If significant hypoxaemia or work of breathing persists despite conventional oxygen therapy and a time-limited trial of awake prone position,³⁸ the authors believe that intubation should not be delayed. A peripheral oxygen saturation (SpO_2) less than 92% on a non-re-breather mask (FiO_2 approximately 0.8) already represents a shunt fraction greater than 30%. In addition, the typical response to

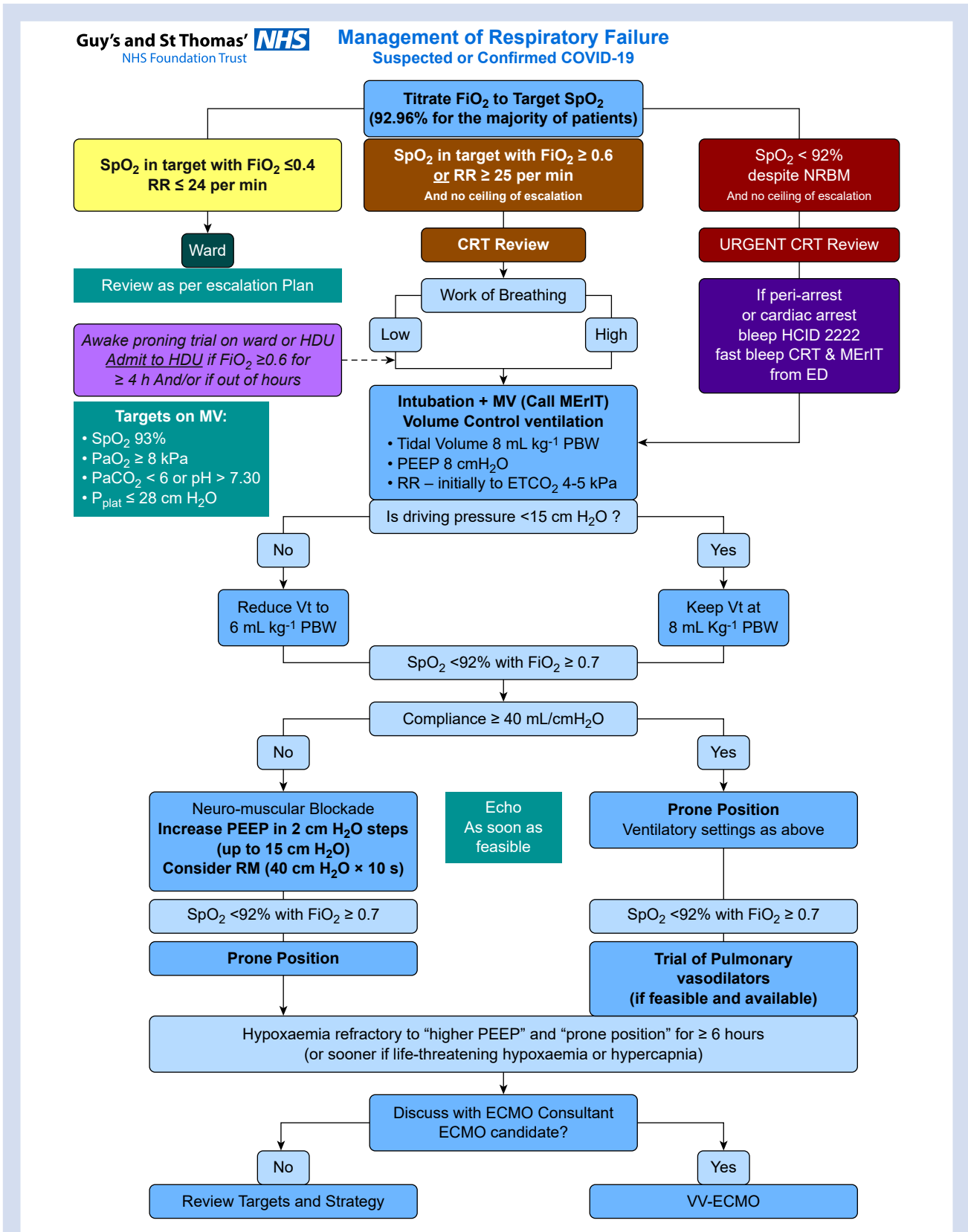


Fig 4. Guy's and St. Thomas' NHS Foundation Trust suggested management of respiratory failure in coronavirus disease 2019 (COVID-19). CRT, critical care response team; ECMO, extracorporeal membrane oxygenation; ED, emergency department; HCID, high consequence infectious disease; HDU, high dependency unit; MERIT, mobile emergency response intubation team; MV, minute ventilation; NRBM, non-re-breather mask; PBW, predicted body weight; RM, recruitment manoeuvre; RR, respiratory rate; Vt, tidal volume; VV-ECMO, venovenous extracorporeal membrane oxygenation.

hypoxaemia when combined with high compliance is to generate excessively negative intrapleural pressures which result in substantial pulmonary strain.³⁰ If these large transpulmonary pressures are left unchecked, they can result in significant patient self-inflicted lung injury.^{30,39,40} Injurious spontaneous breathing has been shown to be associated with a deterioration in radiological appearances and diffuse alveolar damage at post-mortem.^{21,40} Timely intubation and institution of LPV can overcome many of these problems.

The high shunt fraction with limited atelectasis and recruitability, combined with a protracted disease course and high transpulmonary pressures in spontaneous respiration, would question the role of prolonged noninvasive ventilation (NIV) or CPAP in early disease. The use of NIV in moderate-severe *de novo* hypoxaemic respiratory failure has also been consistently associated with high failure rates and increased mortality, particularly when associated with tidal volumes greater than 9 ml kg⁻¹ if there is no reduction in the amplitude of the oesophageal pressure swings.^{39,41} In the Intensive Care National Audit and Research Centre (ICNARC) report of 10 624 COVID-19 patients admitted to critical care in the UK, 84.7% of patients presented with moderate-severe hypoxaemic respiratory failure with a Pa_{o2}/FiO₂ ratio less than 26.7 kPa.⁵ In addition, any strategy involving wide-scale use of NIV should give consideration to the increased risk of aerosol generation and SARS-CoV-2 transmission,⁴² and the potential impact on institutional oxygen supplies.

After intubation, early LPV must be meticulously adhered to, given the propensity for beta-coronavirus infections to behave like an inflammatory lung disease,⁴³ which makes them extremely susceptible to ventilator-induced lung injury and biotrauma. Initially deep sedation and liberal use of neuromuscular block should be used to facilitate LPV, and to avoid dys-synchrony and dramatic swings in transpulmonary pressures. In the event of progressive hypoxaemia, the use of strategies involving prone position, inhaled pulmonary vasodilators, higher mean airway pressures, and ECMO should be tailored to disease behaviour (Fig. 4). The authors adapt ventilation strategies based on an assessment of radiology and bedside pulmonary mechanics, including interrogation of quasi-static pressure–volume curves and recruitment-to-inflation ratios.⁴⁴ In the Type-L phenotype with low elastance and recruitment-to-inflation ratio less than 0.5, strategies involving high PEEP typically result in limited alveolar recruitment with over-distention, increased dead space ventilation, and worsening venous admixture. To limit this unnecessary mechanical power application, the authors generally utilise a lower PEEP (5–10 cm H₂O), inhaled pulmonary vasodilators, and early prone position combined with standard tidal volume targets (6–8 ml kg⁻¹). Type-H phenotypes with high elastance and recruitment-to-inflation ratio greater than 0.5, are more receptive to typical ARDS ventilation strategies including higher PEEP (10–15 cm H₂O) and prone position while maintaining a plateau pressure less than 30 cm H₂O and tidal volume of 6 ml kg⁻¹. When severe hypoxaemia is associated with persistent hyperthermia, a hypermetabolic state, and hyperdynamic cardiac output, the authors use surface or endovascular cooling devices to limit oxygen consumption, improve mixed venous oxygenation, and improve venous admixture.³⁴ In SRF refractory to these conventional strategies, the authors have initiated mobile ECMO in 58 COVID-19 patients to date. Survival to critical care discharge was achieved in 42 of the 57 (73.7%) patients; with one patient still currently being supported on ECMO.

Given the unusual pulmonary mechanics and propensity for exaggerated inflammatory response, the timing of spontaneous breathing and extubation can be challenging in COVID-19. The initial improvements often observed with invasive ventilation can be falsely reassuring, resulting in premature deleterious spontaneous breathing and extubation attempts.⁴⁵ The authors believe that overreliance on pulmonary mechanics and oxygenation indices for assessing weaning readiness in isolation is flawed, and that other surrogates for disease resolution are needed. The authors regard an improving trajectory in radiological appearances and ‘inflammatory panel’ (temperature, C-reactive protein [CRP], ferritin, triglycerides, and lactate dehydrogenase) as vital preconditions that should be assessed before undertaking any weaning attempts. Once spontaneous breathing is deemed appropriate, the use of P_{musc} Index and P0.1 can be particularly helpful to limit injurious breathing patterns and ensure ongoing LPV.⁴⁶ With preconditions met and spontaneous breathing successfully initiated, a clear sensorium combined with an improved shunt fraction and tolerance of lower PEEP are particularly pertinent to extubation decisions. In patients with more extensive ICU-acquired weakness (ICU-AW) and greater risk of extubation failure, other traditional parameters for extubation readiness may also be helpful.⁴⁵ Prophylactic dexamethasone administration should be considered peri-extubation given the increased incidence of glottic oedema associated with prolonged periods of intubation and prone positioning.⁴⁷

Cardiovascular system

The cardiovascular manifestations of SARS-CoV-2 are less frequent than that of the respiratory system, with an increased troponin occurring in 27.3% of hospitalised patients.⁴⁸ These patients have an increased in-hospital mortality compared with those with normal troponins (59.6% and 8.9%, *P*<0.001).⁴⁸ Although direct cardiovascular complications can be conveniently divided into categories (i.e. myopericarditis, ischaemic, and arrhythmias⁴⁹), there is likely to be significant overlap between these groups.

There are few publications describing myocardial interstitial mononuclear inflammatory cell infiltrates and viral inclusions in COVID-19.^{50,51} Some of these changes are similar to those observed in classic viral myocarditis presenting with ECG alterations, depressed systolic function, biomarker leak, and cardiogenic shock.⁵² The proportion of myocardial necrosis related to direct viral cytopathy vs later molecular mimicry and dysregulated immune response varies amongst viruses.⁵² Whilst there have been a few reported cases of fulminant myocarditis presenting with low cardiac output states, dramatic elevations of troponin and N-terminal pro-brain natriuretic peptide (NT-proBNP),^{51,53,54} the vast majority of patients admitted with cardiac injuries present with only a mild biomarker leak, absent ECG changes, and preserved systolic function.⁵⁵ In addition, the authors have observed four COVID-19 myopericarditis cases with precipitous cardiovascular collapse and pericardial tamponade necessitating emergent pericardiocentesis.

The ischaemic cardiac injury observed in COVID-19 likely represents a range of disease pathogenesis including inflammatory myocarditis. Myocardial infarctions mediated by atherosclerotic plaque rupture and coronary thrombus or type II pattern related to flow-demand imbalance, are often observed in acute respiratory illnesses.⁵⁶ The linear correlation between troponin and CRP does, however, pose the

interesting question whether the majority of cardiac injuries are merely the consequence of an exaggerated immune response, and surrogate of disease severity and organ dysfunction, rather than a distinct entity.⁴⁸

The culmination of these mechanisms contributes to the 17.3% of patients with elevated troponin experiencing ventricular fibrillation or ventricular tachycardia during hospitalisation.⁴⁸ In 136 COVID-19 patients with witnessed in-hospital cardiac arrests, the initial rhythm was shockable, asystole, and pulseless electrical activity in 5.9%, 89.7%, and 4.4%, respectively.⁵⁷ Accounting for the higher proportion of primary respiratory events, there was still a disproportionate rate of asystole compared with non-COVID-19 in-hospital cardiac arrest data.⁵⁷ The authors have witnessed a number of sudden non-shockable cardiac arrests in previously fit and well young COVID-19 patients without preceding respiratory embarrassment, significant echocardiographic or ECG findings, and only mild troponin release. Published cardiovascular pathogenesis in COVID-19 cannot fully explain such unpredictable disease behaviours. A number of these patients have presented with symptoms compatible with meningoencephalitis, a recognised complication of COVID-19,^{32,58} and the authors hypothesise such precipitous cardiovascular collapse could be partly mediated by neurocardiac axis dysfunction as a result of vasomotor centre injury in the rostral ventrolateral medulla, as seen in other viral-induced rhombencephalitis.⁵⁹

The influence of cardiorespiratory interactions observed in critical illness must also be considered in COVID-19. Clinicians should remain vigilant for the development of acute cor pulmonale given the high incidence of thrombotic pulmonary complications combined with frequent hypoxaemia, hypercarbia, and elevated intrapulmonary pressures.^{28,60} Early therapies to optimise pulmonary vascular resistance and right ventricular function are key to avoiding ventricular uncoupling and worsening multiorgan dysfunction syndrome.⁶¹ Early bedside echocardiographic assessment in patients with high acute cor pulmonale scores or escalating vasoactive drug requirements is essential to facilitate timely resuscitation.⁶⁰ Therapies for acute right ventricular dysfunction in the context of pulmonary hypertension should be multifaceted^{61,62}:

- Treatment of specific aetiologies.
- Optimise intravascular volume and venous capacitance.
- Optimise inotropy with a preference for phosphodiesterase III inhibitors or levosimendan.
- Minimise right ventricular afterload through ventilatory manipulation to optimise functional residual capacity, limit intrathoracic pressures, and achieve normocarbida/normoxia.
- Prone position to improve right ventricular pressure overload.
- Reduction in pulmonary vascular resistance through inhaled or systemic pulmonary vasodilators, and a preference for vasopressin over catecholaminergic agents if a systemic vasopressor is required.
- Temporary percutaneous and extracorporeal life support.

Given the overwhelming volume of admissions and low incidence of cardiovascular derangement observed in COVID-19, a standardised approach to general haemodynamic support is suitable for the majority of patients.⁶³

In the later phase of the COVID-19 pandemic, a number of patients (predominantly children and adolescents) have

presented with a prior respiratory illness followed many weeks later by gastrointestinal symptoms, fever, and acute heart failure; this syndrome has been since named paediatric multisystem inflammatory syndrome temporally associated with SARS-CoV-2.⁵⁴ Ten young patients have been referred to our ECMO service with similar symptomatology, severe left ventricular systolic dysfunction, and a high CRP and ferritin. These patients have all responded to a combination of i.v. immunoglobulin, methylprednisolone, and inotropes. Depending on the mode and severity of the cardiovascular decline, a strategy including extracorporeal life support may also be appropriate.^{65,66} Although a proportion of these cases may represent a classical viral myocarditis, there is growing interest in the possibility of a distinct vasculitic process such as Kawasaki disease shock syndrome.^{67,68} If this presentation is combined with SARS-CoV-2 IgM, IgG positivity, or both, and any mucocutaneous features (strawberry tongue, conjunctivitis, and palmar or plantar erythema), consideration should also be given to high-dose aspirin and a follow-up CT coronary angiogram to exclude coronary aneurysms.

Neurological system

Neurological symptoms occur in up to 36.4% of patients presenting with COVID-19, and these are more prevalent in those with severe disease.⁶⁹ These complications appear to be mediated by either an anoxic injury or SARS-CoV-2 neurotropism through haematogenous and retrograde neuronal infiltration.^{31,32,58,69} The pathogenesis of the anoxic injury could be global oxygen delivery issues or more territorial related to cardioembolic disease and primary *in situ* thrombosis.^{32,70} The neurological consequences of these can include meningoencephalitis, HLH, and cerebrovascular infarcts and bleeds.^{32,58,69,71,72} The authors have sadly seen three catastrophic multi-territory strokes in patients with severe COVID-19; all patients were under the age of 35, with no cardiovascular risk factors or echocardiogram abnormalities detected.

For the majority of neurological emergencies in COVID-19 the treatment will be supportive. Maintaining homeostasis with a particular focus on gas exchange and blood pressure optimisation is essential to limiting secondary brain injury. In patients presenting with strokes, the complex decision-making around the timing of anticoagulation, and the role of mechanical thrombectomy and surgery are best addressed in high volume centres.⁷³

COVID-19 can present significant sedation challenges given the need for deep planes of anaesthesia in hypermetabolic patients. Despite the use of propofol 2% and a strict upper dose limit of 5 mg kg⁻¹ h⁻¹, the authors have observed high rates of hypertriglyceridaemia. This elevation likely reflects exaggerated macrophage activation rather than evolving propofol-related infusion syndrome.^{74,75} However, given the high prevalence of risk factors for propofol-related infusion syndrome in COVID-19, it would seem prudent to utilise adjunctive sedatives such as alpha-2 agonists, benzodiazepines, or ketamine early to limit the lipid load when hypertriglyceridaemia develops. Reducing lipid intake and modulating the underlying disease process are the primary therapeutic strategies for hypertriglyceridaemia in critical illness. In patients requiring ECMO support with hypertriglyceridaemia, the authors initiate fenofibrate given the increased risk of mechanical failure of extracorporeal circuits⁷⁶ and potential novel protective effect in acute lung

injury through restoration of free fatty acid oxidation.⁷⁷ Volatile anaesthesia use in intensive care has a growing evidence base,⁷⁸ and where the depth of sedation is difficult to attain without significant side-effects in COVID-19, they have been delivered locally with the AnaConDa® (Sedana Medical, Vendevägen 87, SE-182 32 Danderyd, Sweden) system to good effect.

Renal system

Acute kidney injury (AKI) has emerged as a serious complication in critically ill patients with COVID-19. The prevalence is variable with an incidence of less than 5% in some initial reports from China, to greater than 20% in more contemporary UK datasets.^{5,11} This variation may be explained by differences in clinical practice, but there also appear to be socioeconomic and genetic components. ACE2 receptor expression in renal podocytes and proximal tubule cells is more pronounced in Occidental subjects than in Asians, suggesting that the risk of COVID-19-associated AKI may differ between different ethnic groups.⁷⁹

The aetiology of COVID-19-related AKI is multifactorial and includes haemodynamic disturbance, inflammation, cytokine release, endothelial dysfunction, alteration of the microcirculation, nephrotoxic exposure, and the impact of invasive mechanical ventilation.^{80–82} Although these factors are similar to AKI in non-COVID-19 settings, it appears there are additional factors specific to SARS-CoV-2:

- The SARS-CoV-2 virus uses ACE2 as a cell entry receptor. After entry into the tubular epithelium and podocytes, the virus may exert direct cytopathic effects in the kidney.⁸³ The deposition of immune complexes of viral antigen or virus-induced specific immunological effector mechanisms (specific T-lymphocytes, complement C5b-9, or antibodies) may cause additional damage.^{83,84}
- ACE2 is pivotal in the conversion of angiotensin-II to the vasodilatory and anti-inflammatory peptide angiotensin-(1–7). With ACE2 downregulation there is an initial increase in local angiotensin-II concentration associated with vasoconstriction, endothelial activation, and cytokinaemia.⁸⁵ With evolving pulmonary vascular inflammation and ACE-1 ‘shedding’ there is an eventual decrease in angiotensin-II concentration to sub-physiologic concentrations.⁸⁶ This results in vasodilation, worsened capillary leak, alteration of glomerular autoregulation, and reduction of glomerular filtration.
- Renovascular microthrombi. Post-mortem studies have shown segmental fibrin thrombi and erythrocyte aggregates obstructing peritubular capillaries and impacting intrarenal microcirculation.⁸³
- Rhabdomyolysis. Some reports of renal histology demonstrated pigmented tubular casts containing high concentrations of creatine phosphokinase.⁸³
- Collapsing glomerulopathy, an aggressive variant of focal segmental glomerulosclerosis with high rates of podocyte injury and depletion, has also been reported in renal biopsies.⁸⁷

Presently, there is no specific treatment for COVID-19 associated with AKI, although several potential therapies targeting different aspects of the pathophysiology are being explored.^{88–90} Intravascular volume, microvascular flow, and perfusion pressure should be optimised and if renal replacement therapy (RRT) is required, there is no evidence that a particular timing, mode, or dose is superior, but adjustments

may need to be made in case of reduced RRT capacity.^{91,92} Given the frequent thrombotic loss of extracorporeal circuits in COVID-19,⁹³ the authors have a low threshold for initiating systemic anticoagulation alongside regional citrate if problems are encountered.

COVID-19-related AKI is associated with an increased risk of mortality especially if RRT is required.^{5,94} The long-term impact on kidney function, risk of chronic dialysis, cardiovascular morbidity and mortality remain unknown at this stage.

Haematology

There is escalating concern over thrombotic complications in COVID-19 related to the intricate interplay between cytopathic ACE2-related endotheliopathy, hypoxic pulmonary vasoconstriction, and the inflammatory response with procoagulant–anticoagulant disequilibrium. Initially, it was reported that 71.4% of COVID-19 deaths fulfilled the International Society on Thrombosis and Haemostasis criteria for disseminated intravascular coagulation.⁹⁵ However, a French case series of 150 patients has since revealed no cases of disseminated intravascular coagulation as defined by the same score,⁹³ and there have been no reported cases of the classical hyperfibrinolytic consumptive process with bleeding propensity.⁹⁶ There has been renewed interest in D-dimer concentrations given the significant elevation noted in patients admitted to intensive care and non-survivors.^{14,95} It remains unclear what proportion of these D-dimer elevations are related to thrombosis formation and fibrin turnover or merely intense pulmonary inflammation. A number of procoagulants have also been reported to be increased in COVID-19 including fibrinogen, factor VIII, von Willebrand factor activity and antigen, and interestingly, lupus anticoagulant and anticardiolipin antibodies.^{93,97} Although the incidence of prolonged direct Russell viper venom time does seem particularly high, caution must be exercised when interpreting a single set of tests in the context of critical illness with acute viral infections, particularly given the lack of reporting of anti-β₂-glycoprotein-1 titres. Furthermore, during significant inflammation there is frequent impairment of endogenous anticoagulant pathways such as activated protein C, antithrombin III, and tissue factor pathway inhibitor.⁹⁸

There is a growing body of evidence suggesting a significant microvascular and macrovascular thrombus burden in COVID-19,^{21,23,27–29,93,99,100} and this incidence exceeds those observed in matched non-COVID-19 severe ARDS patients.^{21,93} In addition to standard cross-sectional imaging, the authors feel there is an emerging role for dual energy CT to better delineate the presence of subtle perfusion defects and microvascular thrombosis.¹⁰¹ The underlying mechanism as alluded to is not fully understood but appears primarily immunothrombotic in nature, culminating in high fibrinogen concentrations with hypercoagulability, endothelial injury, and hypoxic pulmonary vasoconstriction with stasis. Tang and colleagues¹⁰² suggested anticoagulation treatment may reduce mortality in COVID-19 patients with ‘sepsis-induced coagulopathy’ or elevated D-dimers but the dose of anticoagulation utilised constituted venous thromboprophylaxis. Enhanced thromboprophylaxis may reduce fibrinogen and D-dimer concentrations along with improving hypercoagulable viscoelastic parameters,¹⁰³ however, given the small sample size and retrospective nature of this work, it remains unclear whether this was causation or association. Upstream immunotherapy, particularly interleukin-6 (IL-6) modulation given

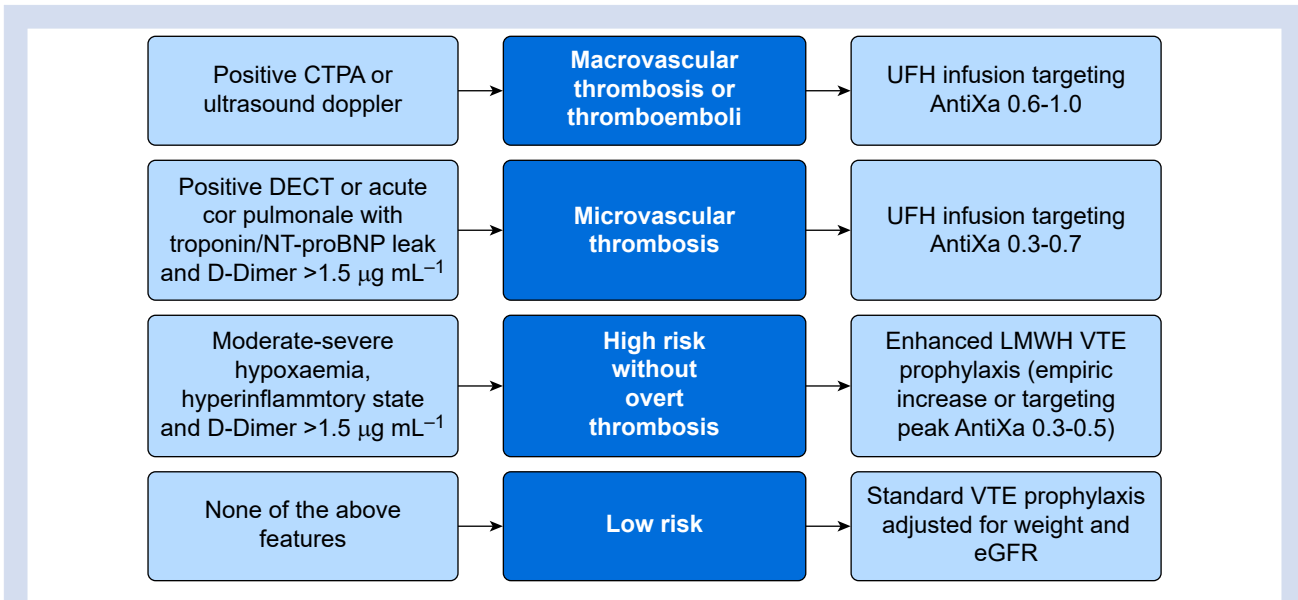


Fig 5. Anticoagulation strategy in coronavirus disease 2019 (COVID-19). CTPA, CT pulmonary angiogram; DECT, dual energy CT; eGFR, estimated glomerular filtration rate; LMWH, low molecular weight heparin; NTproBNP, N-terminal pro-brain natriuretic peptide; UFH, unfractionated heparin; VTE, venous thromboembolism.

its correlation with fibrinogen concentrations,¹⁰³ could also have an important role in limiting immunothrombosis.

While there appears to be consensus on anticoagulation in confirmed thrombosis and thromboprophylaxis in all other critically ill COVID-19 patients, the role for enhanced thromboprophylaxis remains uncertain. Given a pressing clinical need and previous precedent in other high risk populations,¹⁰⁴ an interim solution may be to titrate thromboprophylaxis according to anti-Xa concentrations or an empiric increase in patients stratified to be at high risk of thrombosis and low risk of bleeding.¹⁰⁵ Whilst the use of antiplatelet agents in pulmonary microvascular thrombosis related to ARDS has some biological plausibility, more evidence is required before widespread adoption.¹⁰⁶ There has also been growing interest in the use of direct thrombin inhibitors such as argatroban in COVID-19-related thrombosis, given their efficacy is independent of antithrombin (AT) activity which can be highly variable in critically ill patients.¹⁰⁷ AT concentrations are routinely measured on all our new ECMO admissions, and when low, the authors' current approach is to supplement with AT concentrate in increments of 1000 IU titrated to an AT concentration greater than 60 IU dl⁻¹. Argatroban may be a reasonable alternative to unfractionated heparin if therapeutic anti-Xa concentrations can still not be attained despite adequate AT concentrations or when heparin-induced thrombotic thrombocytopenia syndrome develops.

Figure 5 represents one potential pragmatic solution to anticoagulation management while further prospective trials are awaited.

Immunology

There is an increasing appreciation of the critical impact the host immune response has on illness severity and outcomes in COVID-19.^{108,109} Initial rapid SARS-CoV-2 replication results in activation of lymphocytes (natural killer, T-helper, and T-

cytotoxic cells), release of a range of cytokines and chemokines, and in severe cases, lymphocyte exhaustion and peripheral lymphopaenia. In COVID-19, IL-1 α /1ra/2/7/10/17, interferon- γ , inducible interferon protein-10, granulocyte colony-stimulating-factor, and monocyte chemoattractant peptide-3 concentrations are strongly associated with viral load and lung injury scores.¹¹⁰ Synergistic innate and adaptive immunity is an essential host response to ensure viral clearance. In a small proportion of patients this host response is either protracted or disproportionate with exaggerated monocyte activation and IL-6 production.^{15,17} Maladaptive macrophage activation can result in hyperinflammatory syndromes such as sHLH characterised by a persistent pyrexia, hyperferritinaemia, similar cytokine profiles, and organ dysfunction.¹⁷ The authors routinely screen all COVID-19 patients admitted to critical care for sHLH utilising the H-score,¹¹¹ but in our experience only a small proportion of patients have scores greater than 169. High concentrations of IL-6 associated with decreased lymphocyte subsets, pyrexia, and organ dysfunction are critical components of CRS. While there has been much interest in COVID-19-related CRS and 'cytokine storms',¹¹² the IL-6 concentrations and inopressor requirements in the majority of patients rarely approach those previously outlined in the CRS literature and are probably overstated.²⁶ The authors feel while a generalised hyperinflammatory state is relatively common in COVID-19, only a small proportion of patients have true sHLH or CRS.

The authors consider a maladaptive hyperinflammatory state in the context of persistent organ dysfunction associated with ongoing pyrexia and inflammation (raised CRP, hyperferritinaemia, and hypertriglyceridaemia) in the absence of demonstrable infection. The role of immunomodulation in maladaptive immune responses in COVID-19 remains controversial with a paucity of high-quality evidence. The WHO recommended against the use of corticosteroids, but this was largely based on concerns over increased viral shedding

observed in Middle Eastern Respiratory Syndrome¹¹³ and an inconclusive systematic review in SARS-CoV-1.¹¹⁴ One of the largest studies of corticosteroids in SARS-CoV-1 has since been published demonstrating both safety and a decreased risk of death in severe disease (hazard ratio 0.53; 95% confidence interval 0.35–0.82).¹¹⁵ Prolonged use of corticosteroids in ARDS has also been previously associated with decreased mortality and healthcare utilisation.^{116,117} The authors believe this data, combined with the high incidence of acute fibrinous and organising pneumonia²³ and preliminary evidence of improved outcomes in COVID-19,¹¹⁸ justified the judicious use of corticosteroids in patients with hyperinflammatory disease behaviour. The dose of methylprednisolone utilised locally is 1 mg kg⁻¹ day⁻¹ in early disease or 2 mg kg⁻¹ day⁻¹ if initiated late in patients with persistent SRF. After 5 days at this dose, the methylprednisolone is then weaned over 3 weeks. Reassuringly, this approach is supported by recent initial reports from the ‘randomised evaluation of COVID-19 therapy’ (RECOVERY) trial which suggested early, low-dose dexamethasone can improve survival in COVID-19 patients, with a number needed to treat of 8.5 in those requiring invasive mechanical ventilation.¹¹⁹ When deciding on the timing of immunomodulation, integration of proactive surveillance for intercurrent infections with procalcitonin, microbiological cultures, cytomegalovirus viral load, and fungal serology is essential. The use of high-dose corticosteroids, i.v. immunoglobulin, anakinra (IL-1 receptor antagonist), or tocilizumab (IL-6 receptor antagonist) is reserved locally for patients with more overt features of sHLH or CRS.

The use of vitamin C in severe ARDS may attenuate cytokine surges, and limit activated neutrophil accumulation and extracellular trap formation.¹²⁰ These mechanisms may improve alveolar fluid clearance and limit endothelial injury. In the CITRIS-ALI trial, although the use of vitamin C in ARDS was not associated with an improvement in any of the primary outcomes, there was a significant reduction in 28-day mortality.¹²⁰ Given the perceived benefits and favourable safety profile, we tend to administer Pabrinex® to COVID-19 patients with organ dysfunction, particularly in the context of increased thiamine losses with diuresis or RRT.¹²¹

Whilst the use of antivirals to limit replication, cytopathic injury, and immune response would seem intuitive, initial RCTs of remdesivir and Kaletra proved disappointing.^{122,123} However, the recent ‘adaptive COVID-19 treatment trial’ showed that remdesivir was associated with a reduced time to recovery and non-significant reduction in mortality.¹²⁴ The reduction in median recovery time from 15 to 11 days is a particularly meaningful endpoint in the resource limited backdrop of a pandemic. The impact on outcome was greatest in patients in the initial phases of illness on oxygen therapy alone rather than those requiring ventilation or ECMO.¹²⁴

The ongoing and wider use of other novel therapies such as macrolides, hydroxychloroquine, interferon-β-1a, anakinra, tocilizumab, sarilumab, or convalescent plasma should be limited to prospective clinical trials such as the ‘randomised, embedded, multifactorial, adaptive platform trial for community acquired pneumonia’ (REMAP-CAP).¹²⁵

Conclusion

COVID-19 is a complex multisystem inflammatory and microvascular disease conferring a significant mortality. A greater understanding of pathogenesis, combined with evidence-based organ support and tailored therapies where

appropriate, will optimise outcomes in the later stages of the pandemic.

Authors’ contributions

Conceived the idea for the manuscript: PBS

Involved in the literature review and drafting of the manuscript: all authors

Reviewed and approved the final manuscript for publication: all authors

Declarations of interest

The authors declare that they have no conflicts of interest. The views expressed in the submitted article are his or her own and not an official position of the institution or funder. Ethical approval was not required given nature of the manuscript.

Funding

The authors received no grants, equipment, drugs and/or other support that facilitated conduct of the work described in the article or the writing of the article itself.

References

1. World Health Organisation. Naming the coronavirus disease (COVID-19) and the virus that causes it. Available from: https://www.who.int/docs/default-source/coronaviruse/situation-reports/20200211-sitrep-22-ncov.pdf?sfvrsn=fb6d49b1_2 (accessed 20 April 2020).
2. World Health Organisation. WHO Director-General’s opening remarks at the media briefing on COVID-19. Available from: <https://www.who.int/dg/speeches/detail/who-director-general-s-opening-remarks-at-the-media-briefing-on-covid-19—11-march-2020> (accessed 20 April 2020).
3. Department of Health and Social Care, and Public Health England. Number of coronavirus (COVID-19) cases and risk in the UK. Available from: <https://www.gov.uk/guidance/coronavirus-covid-19-information-for-the-public#number-of-cases-and-deaths> (accessed 30 June 2020).
4. Sherren P, Camporota L, Sanderson B, et al. Can ventilatory strategies in COVID-19 have an impact on outcomes? *Preprints* 2020: 2020070569. <https://doi.org/10.20944/preprints202007.0569.v1>
5. Intensive Care National Audit and Research Centre. ICNARC report on COVID-19 in critical care. Available from: <https://www.icnarc.org/DataServices/Attachments/Download/42ceb4d2-3dd3-ea11-9128-00505601089b> (accessed 1 August 2020).
6. Grasselli G, Zangrillo A, Zanella A, et al. Baseline characteristics and outcomes of 1591 patients infected with SARS-CoV-2 admitted to ICUs of the Lombardy Region, Italy. *JAMA* 2020; **323**: 1574–81
7. Li Q, Guan X, Wu P, et al. Early transmission dynamics in Wuhan, China, of novel coronavirus-infected pneumonia. *N Engl J Med* 2020; **382**: 1199–207
8. van Doremalen N, Bushmaker T, Morris DH, et al. Aerosol and surface stability of SARS-CoV-2 as compared with SARS-CoV-1. *N Engl J Med* 2020; **382**: 1564–7
9. Perlman S. Another decade, another coronavirus. *N Engl J Med* 2020; **382**: 760–2

10. Rabi FA, Al Zoubi MS, Kasasbeh GA, Salameh DM, Al-Nasser AD. SARS-CoV-2 and coronavirus disease 2019: what we know so far. *Pathogens* 2020; **9**: 231
11. Guan WJ, Ni ZY, Hu Y, et al. Clinical characteristics of coronavirus disease 2019 in China. *N Engl J Med* 2020; **382**: 1708–20
12. Vaira LA, Salzano G, Deiana G, De Riu G. Anosmia and ageusia: common findings in COVID-19 patients. *Laryngoscope* 2020; **130**: 1787
13. Greenland JR, Michelow MD, Wang L, London MJ. COVID-19 infection: implications for Perioperative and Critical Care Physicians. *Anesthesiology* 2020; **132**: 1346–61
14. Wang D, Hu B, Hu C, et al. Clinical characteristics of 138 hospitalized patients with 2019 novel coronavirus-infected pneumonia in Wuhan, China. *JAMA* 2020 Mar 17; **323**: 1061–9
15. Qin C, Zhou L, Hu Z, et al. Dysregulation of immune response in patients with COVID-19 in Wuhan, China. *Clin Infect Dis* 2020; **71**: 762–8
16. Shi H, Han X, Jiang N, et al. Radiological findings from 81 patients with COVID-19 pneumonia in Wuhan, China: a descriptive study. *Lancet Infect Dis* 2020; **20**: 425–34
17. Mehta P, McAuley DF, Brown M, et al. COVID-19: consider cytokine storm syndromes and immunosuppression. *Lancet* 2020; **395**: 1033–4
18. Tonetti T, Vasques F, Rapetti F, et al. Driving pressure and mechanical power: new targets for VILI prevention. *Ann Transl Med* 2017; **5**: 286
19. Ferrer M, Torres A. Epidemiology of ICU-acquired pneumonia. *Curr Opin Crit Care* 2018; **24**: 325–31
20. Repessé X, Charron C, Vieillard-Baron A. Acute cor pulmonale in ARDS: rationale for protecting the right ventricle. *Chest* 2015; **147**: 259–65
21. Ackermann M, Verleden SE, Kuehnel M, et al. Pulmonary vascular endothelialitis, thrombosis, and angiogenesis in Covid-19. *N Engl J Med* 2020; **383**: 120–8
22. Gattinoni L, Chiumello D, Caironi P, et al. COVID-19 pneumonia: different respiratory treatments for different phenotypes? *Intensive Care Med* 2020 Jun; **46**: 1099–102
23. Copin MC, Parmentier E, Duburcq T, Poissy J, Mathieu D. The Lille COVID-19 ICU and Anatomopathology Group. Time to consider histologic pattern of lung injury to treat critically ill patients with COVID-19 infection. *Intensive Care Med* 2020; **46**: 1124–6
24. Calfee CS, Delucchi K, Parsons PE, et al. Subphenotypes in acute respiratory distress syndrome: latent class analysis of data from two randomised controlled trials. *Lancet Respir Med* 2014; **2**: 611–20
25. Kuba K, Imai Y, Rao S, et al. A crucial role of angiotensin converting enzyme 2 (ACE2) in SARS coronavirus-induced lung injury. *Nat Med* 2005; **11**: 875–9
26. Leisman DE, Deutschman CS, Legrand M. COVID-19 in the ICU: vascular dysfunction, thrombosis, and dysregulated inflammation. *Intensive Care Med* 2020; **46**: 1105–8
27. Cui S, Chen S, Li X, Liu S, Wang F. Prevalence of venous thromboembolism in patients with severe novel coronavirus pneumonia. *J Thromb Haemost* 2020; **18**: 1421–4
28. Klok FA, Kruip MJHA, van der Meer NJM, et al. Incidence of thrombotic complications in critically ill ICU patients with COVID-19. *Thromb Res* 2020; **191**: 145–7
29. Zhang T, Sun LX, Feng RE. Comparison of clinical and pathological features between severe acute respiratory syndrome and coronavirus disease 2019. *Zhonghua Jie He He Hu Xi Za Zhi* 2020; **43**: E040
30. Vaporidi K, Akoumianaki E, Telias I, Goligher EC, Brochard L, Georgopoulos D. Respiratory drive in critically ill patients. pathophysiology and clinical implications. *Am J Respir Crit Care Med* 2020; **201**: 20–32
31. Li YC, Bai WZ, Hashikawa T. The neuroinvasive potential of SARS-CoV2 may play a role in the respiratory failure of COVID-19 patients. *J Med Virol* 2020; **92**: 552–5
32. Montalvan V, Lee J, Bueso T, De Toledo J, Rivas K. Neurological manifestations of COVID-19 and other coronavirus infections: a systematic review. *Clin Neurol Neurosurg* 2020; **194**: 105921
33. Takala J. Hypoxemia due to increased venous admixture: influence of cardiac output on oxygenation. *Intensive Care Med* 2007; **33**: 908–11
34. Lynch JP, Mhyre JG, Dantzker DR. Influence of cardiac output on intrapulmonary shunt. *J Appl Physiol Respir Environ Exerc Physiol* 1979; **46**: 315–21
35. Dantzker DR, Lynch JP, Weg JG. Depression of cardiac output is a mechanism of shunt reduction in the therapy of acute respiratory failure. *Chest* 1980; **77**: 636–42
36. Hasan FM, Beller TA, Sobonya RE, Heller N, Brown GW. Effect of positive end-expiratory pressure and body position in unilateral lung injury. *J Appl Physiol Respir Environ Exerc Physiol* 1982; **52**: 147–54
37. Taniguchi H, Kondoh Y. Acute and subacute idiopathic interstitial pneumonias. *Respirology* 2016; **21**: 810–20
38. Caputo ND, Strayer RJ, Levitan R. Early self-proning in awake, non-intubated patients in the emergency department: a single ED's experience during the COVID-19 pandemic. *Acad Emerg Med* 2020; **27**: 375–8
39. Rodríguez A, Ferri C, Martín-Loeches I, et al. Risk factors for noninvasive ventilation failure in critically ill subjects with confirmed influenza infection. *Respir Care* 2017; **62**: 1307–15
40. Tonelli R, Fantini R, Tabbì L, et al. Inspiratory effort assessment by esophageal manometry early predicts noninvasive ventilation outcome in de novo respiratory failure: a pilot study. *Am J Respir Crit Care Med* 2020; **202**: 558–67
41. Bellani G, Laffey JG, Pham T, et al. Noninvasive ventilation of patients with acute respiratory distress syndrome. Insights from the LUNG SAFE study. *Am J Respir Crit Care Med* 2017; **195**: 67–77
42. Tran K, Cimon K, Severn M, Pessoa-Silva CL, Conly J. Aerosol generating procedures and risk of transmission of acute respiratory infections to healthcare workers: a systematic review. *PLoS One* 2012; **7**, e35797
43. Channappanavar R, Perlman S. Pathogenic human coronavirus infections: causes and consequences of cytokine storm and immunopathology. *Semin Immunopathol* 2017; **39**: 529–39
44. Chen L, Del Sorbo L, Grieco DL, et al. Potential for lung recruitment estimated by the recruitment-to-inflation ratio in acute respiratory distress syndrome. A clinical trial. *Am J Respir Crit Care Med* 2020; **201**: 178–87
45. Thille AW, Cortés-Puch I, Esteban A. Weaning from the ventilator and extubation in ICU. *Curr Opin Crit Care* 2013; **19**: 57–64
46. Russotto V, Bellani G, Foti G. Respiratory mechanics in patients with acute respiratory distress syndrome. *Ann Transl Med* 2018; **6**: 382

47. McGrath BA, Wallace S, Goswamy J. Laryngeal oedema associated with COVID-19 complicating airway management. *Anaesthesia* 2020; **75**: 972
48. Guo T, Fan Y, Chen M, et al. Cardiovascular implications of fatal outcomes of patients with coronavirus disease 2019 (COVID-19). *JAMA Cardiol* 2020; **5**: 1–8
49. Madjid M, Safavi-Naeini P, Solomon SD, Vardeny O. Potential effects of coronaviruses on the cardiovascular system: a review. *JAMA Cardiol* 2020 Jul 1; **5**: 831–40
50. Xu Z, Shi L, Wang Y, et al. Pathological findings of COVID-19 associated with acute respiratory distress syndrome. *Lancet Respir Med* 2020; **8**: 420–2
51. Tavazzi G, Pellegrini C, Maurelli M, et al. Myocardial localization of coronavirus in COVID-19 cardiogenic shock. *Eur J Heart Fail* 2020; **22**: 911–5
52. Pollack A, Kontorovich AR, Fuster V, Dec GW. Viral myocarditis—diagnosis, treatment options, and current controversies. *Nat Rev Cardiol* 2015; **12**: 670–80
53. Inciardi RM, Lupi L, Zaccone G, et al. Cardiac involvement in a patient with coronavirus disease 2019 (COVID-19). *JAMA Cardiol* 2020; **5**: 1–6
54. Hu H, Ma F, Wei X, Fang Y. Coronavirus fulminant myocarditis saved with glucocorticoid and human immunoglobulin. *Eur Heart J* 2020. <https://doi.org/10.1093/eurheartj/ehaa190>. Advance Access published on March 16
55. Deng Q, Hu B, Zhang Y, et al. Suspected myocardial injury in patients with COVID-19: evidence from front-line clinical observation in Wuhan, China. *Int J Cardiol* 2020; **311**: 116–21
56. Kwong JC, Schwartz KL, Campitelli MA, et al. Acute myocardial infarction after laboratory-confirmed influenza infection. *N Engl J Med* 2018; **378**: 345–53
57. Shao F, Xu S, Ma X, et al. In-hospital cardiac arrest outcomes among patients with COVID-19 pneumonia in Wuhan, China. *Resuscitation* 2020; **151**: 18–23
58. Moriguchi T, Harii N, Goto J, et al. A first case of meningitis/encephalitis associated with SARS-Coronavirus-2. *Int J Infect Dis* 2020; **94**: 55–8
59. Fu YC, Chi CS, Lin NN, et al. Comparison of heart failure in children with enterovirus 71 rhombencephalitis and cats with norepinephrine cardiotoxicity. *Pediatr Cardiol* 2006; **27**: 577–84
60. Mekontso Dessap A, Boissier F, Charron C, et al. Acute cor pulmonale during protective ventilation for acute respiratory distress syndrome: prevalence, predictors, and clinical impact. *Intensive Care Med* 2016; **42**: 862–70
61. Hoepfer MM, Granton J. Intensive care unit management of patients with severe pulmonary hypertension and right heart failure. *Am J Respir Crit Care Med* 2011; **184**: 1114–24
62. Vieillard-Baron A, Charron C, Caille V, Belliard G, Page B, Jardin F. Prone positioning unloads the right ventricle in severe ARDS. *Chest* 2007; **132**: 1440–6
63. Alhazzani W, Møller MH, Arabi YM, et al. Surviving Sepsis Campaign: guidelines on the management of critically ill adults with Coronavirus Disease 2019 (COVID-19). *Intensive Care Med* 2020; **48**: e440–69
64. Riphagen S, Gomez X, Gonzalez-Martinez C, Wilkinson N, Theocharis P. Hyperinflammatory shock in children during COVID-19 pandemic. *Lancet* 2020; **395**: 1607–8
65. Bemtgen X, Krüger K, Supady A, et al. First successful treatment of COVID-19 induced refractory cardiogenic plus vasoplegic shock by combination of pVAD and ECMO – a case report. *ASAIO J* 2020; **66**: 607–9
66. Vogel DJ, Murray J, Czapanan AZ, et al. Venous-arteriovenous ECMO for septic cardiomyopathy: a single-centre experience. *Perfusion* 2018; **33**: 57–64
67. Verdoni L, Mazza A, Gervasoni A, et al. An outbreak of severe Kawasaki-like disease at the Italian epicentre of the SARS-CoV-2 epidemic: an observational cohort study. *Lancet* 2020; **395**: 1771–8
68. Tersalvi G, Vicenzi M, Calabretta D, et al. Elevated troponin in patients with Coronavirus Disease 2019 (COVID-19): possible mechanisms. *J Card Fail* 2020; **26**: 470–5
69. Mao L, Jin H, Wang M, et al. Manifestations of hospitalized patients with coronavirus disease 2019 in Wuhan, China. *JAMA Neurol* 2020; **77**: 1–9
70. Markus HS, Brainin M. EXPRESS: COVID-19 and stroke - a Global World Stroke Organisation perspective. *Int J Stroke* 2020; **15**: 361–4
71. Radmanesh F, Rodriguez-Pla A, Pincus MD, Burns JD. Severe cerebral involvement in adult-onset hemophagocytic lymphohistiocytosis. *J Clin Neurosci* 2020; **76**: 236–7
72. Poyiadji N, Shahin G, Noujaim D, Stone M, Patel S, Griffith B. COVID-19-associated acute hemorrhagic necrotizing encephalopathy: CT and MRI features. *Radiology* 2020; **296**: E119–20
73. Smith M, Reddy U, Robba C, Sharma D, Citerio G. Acute ischaemic stroke: challenges for the intensivist. *Intensive Care Med* 2019; **45**: 1177–89
74. Feingold KR, Shigenaga JK, Kazemi MR, et al. Mechanisms of triglyceride accumulation in activated macrophages. *J Leukoc Biol* 2012; **92**: 829–39
75. Hemphill S, McMenamin L, Bellamy MC, Hopkins PM. Propofol infusion syndrome: a structured literature review and analysis of published case reports. *Br J Anaesth* 2019; **122**: 448–59
76. Son KH, Lee SI, Choi CH, Park CH. Mechanical failure of extracorporeal membrane oxygenation induced by hypertriglyceridemia. *Ann Thorac Surg* 2017; **104**: e85
77. Cui H, Xie N, Banerjee S, Ge J, Guo S, Liu G. Impairment of fatty acid oxidation in alveolar epithelial cells mediates acute lung injury. *Am J Respir Cell Mol Biol* 2019; **60**: 167–78
78. Bellgardt M, Bomberg H, Herzog-Niescery J, et al. Survival after long-term isoflurane sedation as opposed to intravenous sedation in critically ill surgical patients: retrospective analysis. *Eur J Anaesthesiol* 2016; **33**: 6–13
79. Pan XW, Xu D, Zhang H, Zhou W, Wang LH, Cui XG. Identification of a potential mechanism of acute kidney injury during the COVID-19 outbreak: a study based on single-cell transcriptome analysis. *Intensive Care Med* 2020; **46**: 1114–6
80. Rabb H. Kidney diseases in the time of COVID-19: major challenges to patient care. *J Clin Invest* 2020; **130**: 2749–51
81. Joannidis M, Forni LG, Klein SJ, et al. Lung-kidney interactions in critically ill patients: consensus report of the Acute Disease Quality Initiative (ADQI) 21 Workgroup. *Intensive Care Med* 2020; **46**: 654–72
82. Ostermann M, Liu K. Pathophysiology of AKI. *Best Pract Res Clin Anaesthesiol* 2017; **31**: 305–14
83. Su H, Yang M, Wan C, et al. Renal histopathological analysis of 26 postmortem findings of patients with COVID-19 in China. *Kidney Int* 2020; **98**: 219–27

84. Diao B, Wang C, Wang R, et al. Human kidney is a target for novel severe acute respiratory syndrome coronavirus 2 (SARS-CoV-2) infection. *medRxiv* 2020. <https://doi.org/10.1101/2020.03.04.20031120>
85. Hall A, Busse LW, Ostermann M. Angiotensin in critical care. *Crit Care* 2018; **22**: 69
86. Nukiwa T, Matsuoka R, Takagi H, Ishii Y, Arai T, Kira S. Responses of serum and lung angiotensin-converting enzyme activities in the early phase of pulmonary damage induced by oleic acid in dogs. *Am Rev Respir Dis* 1982; **126**: 1080–6
87. Peleg Y, Kudose S, D'Agati V, et al. Acute kidney injury due to collapsing glomerulopathy following COVID-19 infection. *Kidney Int Rep* 2020; **5**: 940–5
88. Zhang H, Penninger JM, Li Y, Zhong N, Slutsky A. Angiotensin-converting enzyme 2 (ACE2) as a SARS-CoV-2 receptor: molecular mechanisms and potential therapeutic target. *Intensive Care Med* 2020; **46**: 586–90
89. Ronco C, Reis T. Kidney involvement in COVID-19 and rationale for extracorporeal therapies. *Nat Rev Nephrol* 2020; **16**: 308–10
90. Busse L, Chow JH, McCurdy MT, Khanna AK. COVID-19 and the RAAS – a potential role for angiotensin II? *Crit Care* 2020; **24**: 136
91. Durvasula R, Wellington T, McNamara E, Watnick S. COVID-19 and kidney failure in the acute care setting: our experience from Seattle. *Am J Kidney Dis* 2020; **76**: 4–6
92. Naicker S, Yang CW, Hwang SJ, Liu BC, Chen JH, Jha V. The Novel Coronavirus 2019 epidemic and kidneys. *Kidney Int* 2020; **97**: 824–8
93. Helms J, Tacquard C, Severac F, et al. High risk of thrombosis in patients in severe SARS-CoV-2 infection: a multicenter prospective cohort study. *Intensive Care Med* 2020; **46**: 1089–98
94. Ali H, Daoud A, Mohamed MM, et al. Survival rate in acute kidney injury superimposed COVID-19 patients: a systematic review and meta-analysis. *Ren Fail* 2020; **42**: 393–7
95. Tang N, Li D, Wang X, Sun Z. Abnormal coagulation parameters are associated with poor prognosis in patients with novel coronavirus pneumonia. *J Thromb Haemost* 2020; **18**: 844–7
96. Connors JM, Levy JH. Thromboinflammation and the hypercoagulability of COVID-19. *J Thromb Haemost* 2020; **18**: 1559–61
97. Zhang Y, Xiao M, Zhang S, et al. Coagulopathy and antiphospholipid antibodies in patients with covid-19. *N Engl J Med* 2020; **382**: e38
98. José RJ, Williams AE, Chambers RC. Proteinase-activated receptors in fibroproliferative lung disease. *Thorax* 2014; **69**: 190–2
99. Menter T, Haslbauer JD, Nienhold R, et al. Post-mortem examination of COVID19 patients reveals diffuse alveolar damage with severe capillary congestion and variegated findings of lungs and other organs suggesting vascular dysfunction. *Histopathology* 2020. <https://doi.org/10.1111/his.14134>. Advance Access published on May 4
100. Fox SE, Akmatbekov A, Harbert JL, et al. Pulmonary and cardiac pathology in African American patients with COVID-19: an autopsy series from New Orleans. *Lancet Respir Med* 2020 Jul; **8**: 681–6
101. Lang M, Som A, Mendoza DP, et al. Hypoxaemia related to COVID-19: vascular and perfusion abnormalities on dual-energy CT. *Lancet Infect Dis* 2020. [https://doi.org/10.1016/S1473-3099\(20\)30367-4](https://doi.org/10.1016/S1473-3099(20)30367-4). Advance Access published on April 30
102. Tang N, Bai H, Chen X, Gong J, Li D, Sun Z. Anticoagulant treatment is associated with decreased mortality in severe coronavirus disease 2019 patients with coagulopathy. *J Thromb Haemost* 2020; **18**: 1094–9
103. Ranucci M, Ballotta A, Di Dedda U, et al. The procoagulant pattern of patients with COVID-19 acute respiratory distress syndrome. *J Thromb Haemost* 2020; **18**: 1747–51
104. Singer GA, Riggi G, Karcutskie CA, et al. Anti-Xa-guided enoxaparin thromboprophylaxis reduces rate of deep venous thromboembolism in high-risk trauma patients. *J Trauma Acute Care Surg* 2016; **81**: 1101–8
105. Barnes GD, Burnett A, Allen A, et al. Thromboembolism and anticoagulant therapy during the COVID-19 pandemic: interim clinical guidance from the anticoagulation forum. *J Thromb Thrombolysis* 2020; **50**: 72–81
106. Panka BA, de Grooth HJ, de Man AS, Looney M, Tuinman PR. Prevention or treatment of ARDS with aspirin: a review of preclinical models and meta-analysis of clinical studies. *Shock* 2017; **47**: 13–21
107. Arachchillage DJ, Remington C, Rosenberg A, et al. Anticoagulation with argatroban in patients with acute antithrombin deficiency in severe COVID-19. *Br J Haematol* 2020. <https://doi.org/10.1111/bjh.16927>. Advance Access published on June 9
108. Henry BM, de Oliveira MHS, Benoit S, Plebani M, Lippi G. Hematologic, biochemical and immune biomarker abnormalities associated with severe illness and mortality in coronavirus disease 2019 (COVID-19): a meta-analysis. *Clin Chem Lab Med* 2020; **58**: 1021–8
109. Ruan Q, Yang K, Wang W, Jiang L, Song J. Clinical predictors of mortality due to COVID-19 based on an analysis of data of 150 patients from Wuhan, China. *Intensive Care Med* 2020; **46**: 846–8
110. Yang Y, Shen C, Li J, et al. Exuberant elevation of IP-10, MCP-3 and IL-1ra during SARS-CoV-2 infection is associated with disease severity and fatal outcome. *MedRxiv* 2020. <https://doi.org/10.1101/2020.03.02.20029975>
111. Fardet L, Galicier L, Lambotte O, et al. Development and validation of the HScore, a score for the diagnosis of reactive hemophagocytic syndrome. *Arthritis Rheumatol* 2014; **66**: 2613–20
112. Wang W, Liu X, Wu S, et al. The definition and risks of cytokine release syndrome in 11 COVID-19-affected critically ill patients with pneumonia: analysis of disease characteristics. *J Infect Dis* 2020 Jun 30. jiaa387
113. Arabi YM, Mandourah Y, Al-Hameed F, et al. Corticosteroid therapy for critically ill patients with middle east respiratory syndrome. *Am J Respir Crit Care Med* 2018; **197**: 757–67
114. Stockman LJ, Bellamy R, Garner P. SARS: systematic review of treatment effects. *PLoS Med* 2006; **3**: e343
115. Long Y, Xu Y, Wang B, et al. Clinical recommendations from an observational study on MERS: glucocorticoids was benefit in treating SARS patients. *Int J Clin Exp Med* 2016; **9**: 8865–73
116. Meduri GU, Bridges L, Shih MC, Marik PE, Siemieniuk RAC, Kocak M. Prolonged glucocorticoid treatment is associated with improved ARDS outcomes: analysis of individual patients' data from four randomized trials and trial-level meta-analysis of the updated literature. *Intensive Care Med* 2016; **42**: 829–40

117. Meduri GU, Siemieniuk RAC, Ness RA, Seyler SJ. Prolonged low-dose methylprednisolone treatment is highly effective in reducing duration of mechanical ventilation and mortality in patients with ARDS. *J Intensive Care* 2018; **6**: 53
118. Wu C, Chen X, Cai Y, et al. Risk factors associated with acute respiratory distress syndrome and death in patients with coronavirus disease 2019 pneumonia in Wuhan, China. *JAMA Intern Med* 2020; **180**: 1–11
119. Horby P, Lim WS, Emberson JR, et al. Dexamethasone in hospitalized patients with Covid-19 – preliminary report. *N Engl J Med* 2020 Jul 17. NEJMoa2021436
120. Fowler 3rd AA, Truitt JD, Hite RD, et al. Effect of vitamin c infusion on organ failure and biomarkers of inflammation and vascular injury in patients with sepsis and severe acute respiratory failure: the CITRIS-ALI randomized clinical trial. *JAMA* 2019; **322**: 1261–70. Erratum in: *JAMA* 2020; **323**: 379
121. Suter PM, Vetter W. Diuretics and vitamin B1: are diuretics a risk factor for thiamin malnutrition? *Nutr Rev* 2000; **58**: 319–23
122. Cao B, Wang Y, Wen D, et al. Trial of lopinavir-ritonavir in adults hospitalized with severe covid-19. *N Engl J Med* 2020; **382**: 1787–99
123. Wang Y, Zhang D, Du G, et al. Remdesivir in adults with severe COVID-19: a randomised, double-blind, placebo-controlled, multicentre trial. *Lancet* 2020; **395**: 1569–78
124. Beigel JH, Tomashek KM, Dodd LE, et al. Remdesivir for the treatment of Covid-19 – preliminary report. *N Engl J Med* 2020 May 22. NEJMoa2007764. Online ahead of print
125. Angus DC, Berry S, Lewis RJ, et al. The randomized embedded multifactorial adaptive platform for community-acquired pneumonia (REMAP-CAP) study: rationale and design. *Ann Am Thorac Soc* 2020; **17**: 879–91

Handling editor: Jonathan Hardman