

Oncology

Management of acute post-operative hemorrhage following partial nephrectomy with renal artery embolization

Andrew T. Gabrielson, Farzana A. Faisal, Phillip M. Pierorazio*

The James Buchanan Brady Urological Institute and Department of Urology, Johns Hopkins University School of Medicine, Baltimore, MD, USA



ARTICLE INFO

Keywords:

Renal mass
Variant anatomy
Renal artery embolization

ABSTRACT

Hemorrhage after robotic-assisted partial nephrectomy (RAPN) is uncommon but can cause significant morbidity. We present a case of acute hemorrhage isolated to the collecting system that was managed with renal artery embolization (RAE).

A 76-year-old male developed sudden onset transfusion-dependent hematuria and hypotension following uncomplicated RAPN. He had no signs of intra-abdominal bleeding and his hypotension was responsive to volume resuscitation. Renal angiography identified a segmental artery with extravasation into the collecting system. RAE eliminated the patient's hematuria, the need for further transfusion, and allowed preservation of renal function. RAE is a viable option for collecting system hemorrhage following RAPN.

Introduction

RAPN is considered first-line treatment for all T1a and most T1b renal masses.¹ Partial nephrectomy (PN) confers superior post-operative renal function and non-inferior oncologic outcomes compared to radical nephrectomy (RN).¹ Nonetheless, rates of complications with PN range from 8 to 20%.² Post-operative hemorrhage (POH) occurs in 3–10% of RAPNs and typically presents in a delayed fashion, often days to weeks post-operatively.² Hematuria and flank pain are common presentations, and bleeds are associated with pseudoaneurysm or arteriovenous (AV) fistula formation.³ Rarely, POH after RAPN can occur in the acute setting, within hours of surgery.² Acute bleeds are seen infrequently as they can be prevented with intraoperative identification and management, including meticulous renorrhaphy. If acute bleeds do occur post-operatively, most can be managed with transfusion alone. A small number require an additional intervention (re-exploration vs. RAE); these patients typically have high drain output, peritoneal signs, and/or hemodynamic instability indicative of intra-abdominal bleeding and often warrant re-exploration for repair or completion nephrectomy. However, RAE can also be utilized to treat acute POH following RAPN in select cases with no significant adverse effect on glomerular filtration rate (GFR).⁴

Herein we report an acute POH after RAPN isolated to the collecting system that was managed effectively with RAE.

Case presentation

A 76-year-old male presented with a small renal mass (SRM) incidentally found on cross-sectional imaging. Initial CT revealed an exophytic 2.7 x 2.5 x 2.3 cm upper pole mass in the right kidney. The patient elected to proceed with active surveillance according to the Delayed Intervention and Surveillance for Small Renal Masses (DISSRM) protocol.⁵ After two years of surveillance, the patient's SRM had grown to 3.9 cm in largest dimension on contrast-enhanced MRI (Fig. 1). The combination of overall size and growth rate (>0.5 cm/year) prompted recommendation for definitive extirpative treatment. Salient pre-operative labs included creatinine of 0.7 mg/dL (eGFR 71 ml/min/1.73 m²) and hemoglobin of 15.2 g/dL. The patient underwent uncomplicated RAPN: the tumor was identified in the anterior upper pole of the right kidney, total warm ischemia time was 23 minutes, renorrhaphy was performed with a running 3-0 V-Loc™ suture to close the defect bed and interrupted 3-0 Polysorb™ sutures with a sliding clip over a Surgicel® bolster were used to close the renal defect. The patient remained hemodynamically stable with adequate urine output. However, on arrival to the recovery room, sudden onset bright red blood was noted in the urinary catheter. Within minutes, the catheter became clotted requiring manual irrigations. The urinary catheter was exchanged for a 3-way catheter, and continuous bladder irrigation (CBI) was initiated. Despite CBI at full strength, passage of bright red blood persisted. The patient's abdominal exam remained benign, with

* Corresponding author. James Buchanan Brady Urological Institute, The Johns Hopkins Medical Institutions, 600 N. Wolfe Street, Baltimore, MD 21287, USA.
E-mail address: philpierorazio@jhmi.edu (P.M. Pierorazio).

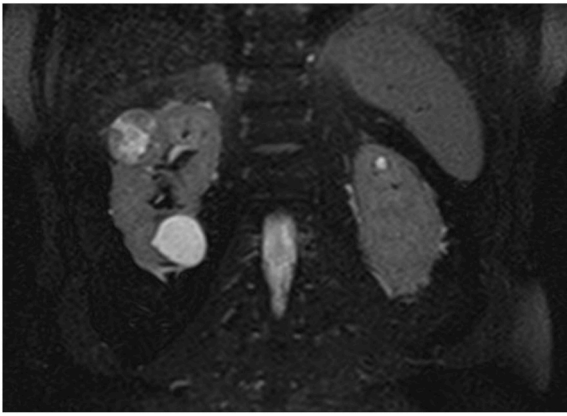


Fig. 1. Coronal MRI T2 demonstrating 3.9cm upper pole renal mass in the right kidney.

no abdominal distention or peritoneal signs. Hemoglobin was 12.9 g/dL. Hemodynamically, the patient developed hypotension that was responsive to crystalloid infusion and transfusion of 2 units of packed red blood cells. Interventional radiology was consulted, and the patient was taken to the interventional radiology suite for arteriography. Injection of contrast into the right renal artery revealed extravasation from an upper pole segmental artery into the collecting system without extravasation into the renal parenchyma or extra-renal space (Video 1). Embolization of the segmental artery was performed with figure-of-eight microcoils. Post-embolization, the patient's hematuria immediately improved on CBI and hemoglobin was 9.8 g/dL. The patient was taken to the ICU for monitoring. He remained stable, and CBI was weaned the night of surgery. He had no further hematuria or transfusion requirements. Urinary catheter was removed on post-operative day 2, and the patient was discharged on post-operative day 3. On discharge, creatinine was 1.0mg/dL (eGFR of 71ml/min/1.73mm²) and hemoglobin was 8.6 g/dL.

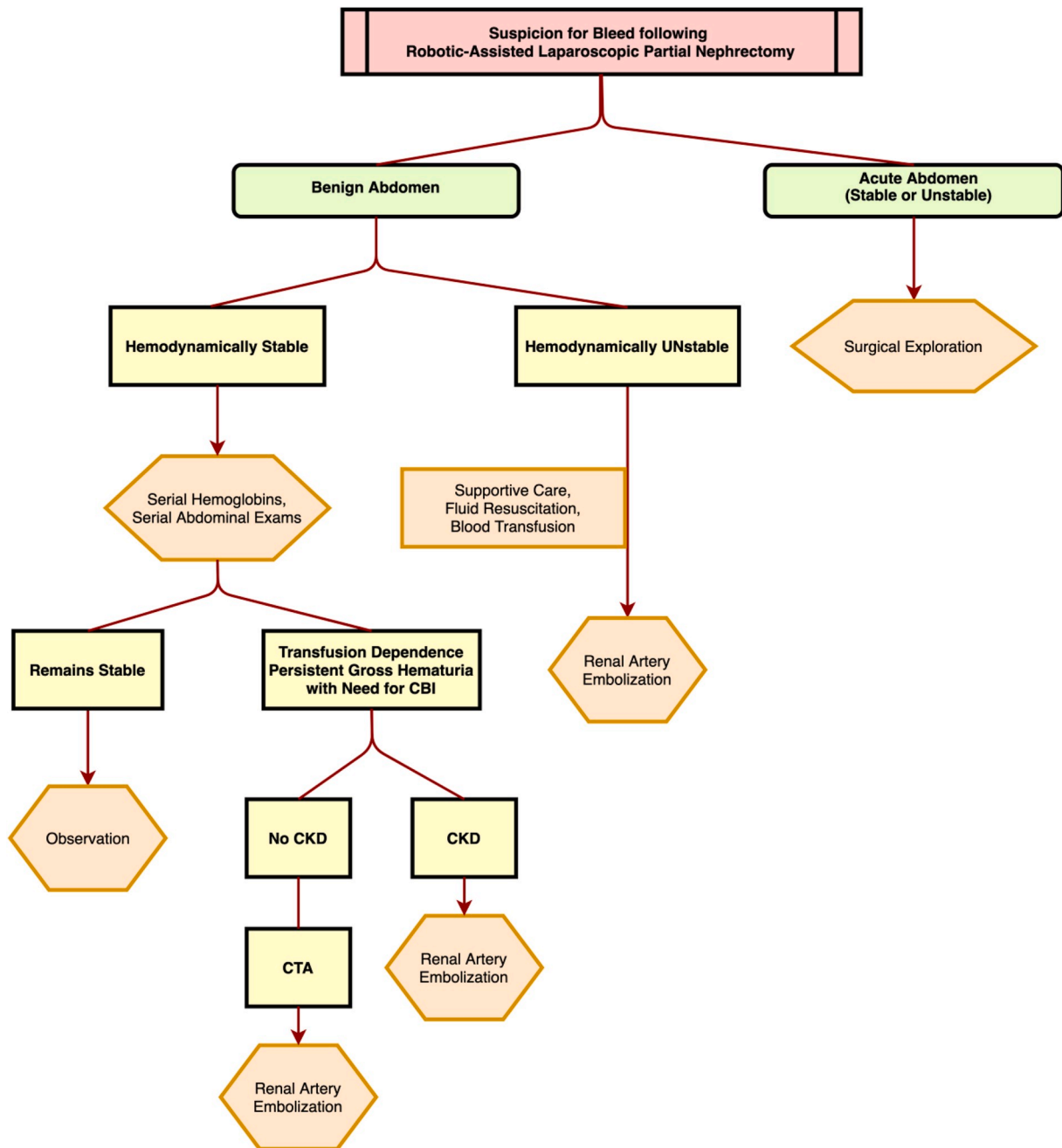


Fig. 2. Algorithm for utilization of renal artery embolization for acute hemorrhage following partial nephrectomy.

Supplementary video related to this article can be found at <https://doi.org/10.1016/j.eucr.2020.101252>

Discussion

Given the technical aspects of RAPN, perioperative morbidity, including POH, is higher with RAPN than other forms of treatment for localized renal masses.^{2,3} Predictors of postoperative hemorrhage after PN include tumor complexity, including endophytic properties, and distance of segmental arteries to resection margin.³

Acute hemorrhage after RAPN with hemodynamic instability and clinical signs of intra-abdominal bleeding necessitates urgent/emergent re-exploration, and often results in completion nephrectomy to control bleeding. RAE provides a safe and effective method to achieve hemostasis and preserve renal function; however it is typically reserved for hemodynamically stable patients with clinically significant hematuria – presentations similar to delayed hemorrhage secondary to pseudoaneurysm or AV fistula. The patient presented here had an arterial bleed that was not noted intra-operatively and developed transfusion-dependent hematuria post-operatively with subsequent hypotension. However, the patient's abdominal exam remained benign, and his hypotension was responsive to volume resuscitation. This constellation of findings was suggestive of an isolated collecting system bleed. The decision was made to attempt preservation of his kidney and proceed with RAE, which was ultimately successful.

Currently, there are no established guidelines for management of POH following PN. Typically, hemorrhage occurs in a delayed fashion and can be managed acutely with blood transfusion alone. Patients requiring multiple transfusions with continued downtrending hemoglobin but are otherwise hemodynamically stable may benefit from RAE. Although there is no established algorithm for utilizing RAE for acute bleeds after PN, the authors provide a framework that can aid clinical decision-making (Fig. 2). If patients are hemodynamically stable, CT angiography (CTA) should be performed prior to RAE. CTA can help locate the vascular defect, as well as assess for the presence of renal artery pseudoaneurysm, AV fistula or collecting system disruption. However, CTA may not be advisable in patients with pre-existing CKD where a second contrast load may dispose a hypotensive patient to acute kidney injury. There are data supporting the successful use of RAE for renal artery pseudoaneurysm and AV fistula.⁴ Evidence from this case supports that RAE can successfully treat acute hemorrhage isolated to the collecting system with excellent preservation of GFR.⁴ Ultimately,

urologists should be aware of RAE, as it can be a valuable tool to manage acute POH following RAPN without the need for invasive re-operation.

Conclusion

We report an isolated collecting system bleed following RAPN that was successfully managed with RAE. Although POH is not common, RAE is an effective and often underutilized modality to non-invasively manage acute bleeds with minimal impact on renal function.

Funding

This research did not receive any specific grant from funding agencies in the public, commercial, or not-for-profit sectors.

Authors contribution

AG - manuscript writing and editing.
FF - manuscript writing and editing.
PP - manuscript writing and editing.

Declaration of competing interest

None.

Acknowledgements

None.

References

1. Kunath F, Schmidt S, Krabbe LM, et al. Partial nephrectomy versus radical nephrectomy for clinical localised renal masses. *Cochrane Database Syst Rev.* 2017;(5).
2. Potretzke AM, Weaver J, Benway BM. Review of robot-assisted partial nephrectomy in modern practice. *Journal of kidney cancer and VHL.* 2015;2(2):30–44.
3. Jung S, Min GE, Chung BI, Jeon SH. Risk factors for postoperative hemorrhage after partial nephrectomy. *Korean journal of urology.* 2014;55(1):17–22.
4. Collins CS, Eggert CH, Stanson AJ, Garovic VD. Long-term follow-up of renal function and blood pressure after selective renal arterial embolization. *Perspect Vasc Surg Endovasc Ther.* 2010;22(4):254–260.
5. Pierorazio PM, Johnson MH, Ball MW, et al. Five-year analysis of a multi-institutional prospective clinical trial of delayed intervention and surveillance for small renal masses: the DISSRM registry. *Eur Urol.* 2015;68(3):408–415.