

Case Report

A Case of Primary Small-Cell Carcinoma of the Bladder

Ashita Ono^a Yosuke Hirasawa^b Mitsumasa Yamashina^c
Naoto Kaburagi^b Takashi Mima^b Toru Sugihara^b Riu Hamada^a
Tatsuo Gondo^b Makoto Ohori^b Toshitaka Nagao^c Yoshio Ohno^b

^aDepartment of Urology, Akabane Central General Hospital, Tokyo, Japan; ^bDepartment of Urology, Tokyo Medical University, Tokyo, Japan; ^cDepartment of Anatomic Pathology, Tokyo Medical University, Tokyo, Japan

Keywords

Small-cell carcinoma · Bladder cancer · Radical cystectomy · Histological variant

Abstract

Primary small-cell carcinoma arising from the bladder (SmCCB) is uncommon. It differs from urothelial carcinoma (UC), the most common type of bladder cancer, with respect to its cell of origin, biology, and prognosis. Biologically, prostatic SmCCB is much more aggressive than UC, and the prognosis for cases with distant metastasis is especially poor. We report here a case of primary SmCCB (cT3bN1M0) treated with radical cystectomy.

© 2016 The Author(s)
Published by S. Karger AG, Basel

Introduction

Primary small-cell carcinoma of the bladder (SmCCB) is extremely rare, accounting for less than 1% of all bladder cancer cases [1, 2]. SmCCB is much more aggressive than urothelial carcinoma (UC), the most common type of bladder cancer, and it has a worse prognosis. Herein, we report a case of SmCCB that progressed rapidly after radical cystectomy (RC). Most cases of SmCCB are histologically diagnosed on final pathologic examination after RC or transurethral resection of bladder tumor (TURBT). Alternatively, it is rare that suspected

SmCCB is diagnosed on preoperative urine cytology, as in the presented case. In addition, we summarize four cases of SmCCB at our institution.

Case Presentation

A 61-year-old Japanese woman presented to our urology outpatient clinic with the chief complaint of gross hematuria. The urine cytology was class V. Urinary cytology findings revealed clusters of small tumor cells, resembling neuroendocrine carcinoma (fig. 1). Cystoscopy revealed a broad-based solitary nodular bladder tumor on the anterior bladder wall. Plain and enhanced computed tomography (CT) scans and magnetic resonance imaging (MRI) showed a broad-based solitary nodular tumor on the anterior wall of the bladder with a diameter of 54 × 50 × 24 mm, indicating extracystic invasion without distant or lymph node metastasis (fig. 2). TURBT was performed for histological diagnosis. A nodular tumor was found on the anterior wall. Bilateral orifices were not involved and had clear efflux of urine. There were no other notable lesions. The tumor along the anterior wall was resected and coagulated. Microscopically, the specimen displayed the features of a neuroendocrine neoplasm or small-cell carcinoma. It displayed small, round or oval-shaped tumor cells, a nest-like structure, little cytoplasm, marked hyperchromatic nuclei, a rough granular karyosome, frequent massive mitotic figures, and extensive necrosis. Immunohistochemically, the tumor cells stained positive for cluster of differentiation (CD) 56, chromogranin A, and synaptophysin, (fig. 3a–c) partially positive for cytokeratin, and positive for Ki-67. Pathological diagnosis of TURBT revealed pure SmCCB (G3, pT1). In addition, a brain CT was performed to rule out potential brain metastasis, a characteristic of small-cell carcinoma, but brain metastasis was not observed. As a result, the patient was diagnosed with primary SmCCB (cT3bN1M0).

The patient underwent RC and ileal conduit urinary diversion and standard lymph node dissection under general anesthesia. The results of the final pathological examination of the bladder tumor were as follows: primary SmCCB on cystectomy specimen, pT3b, N1, lymphovascular invasion, and negative resection margins. The patient had no complications after RC and she was discharged on day 24 after RC. Immediate adjuvant systemic cisplatin-based chemotherapy was planned for the patient, but she was admitted to our hospital with back pain in an emergency. We reevaluated the CT scans, and discovered the presence of multiple bone metastases. The patient died from disease just 2 months after RC, without being able to receive adjuvant systemic chemotherapy due to the rapid progression and highly aggressive behavior of the disease.

Discussion

SmCCB is an extremely rare malignant tumor of the urinary tract. It accounts for less than 1.0% of all primary bladder carcinomas [1, 2]. In a retrospective study of 3,778 bladder cancer cases, Blomjous et al. [1] reported that 18 (0.48%) cases were SmCCB. Choong et al. [2] reported that 44 of 8,345 (0.53%) bladder cancer cases were SmCCB. The male:female prevalence ratio of SmCCB is 5:1, and the average age of onset for SmCCB is approximately 67 years (range: 32–91 years) [3, 4]. Symptoms of SmCCB are similar to those of UC, especially hematuria, which occurs at a rate of 90% [5]. Other common symptoms include dysuria, urinary obstruction, chronic pelvic pain, and urinary tract infection [5]. The diagnosis

mainly depends on the pathological diagnosis and the immunohistochemical analysis of TURBT or RC specimens [6]. Preoperative urine cytology may also be beneficial in the diagnosis, although the specificity of this method is low [7]. Takada et al. [7] reported that 67.4% of 43 SmCCB patients had class IV or V preoperative urine cytology, but SmCCB was suspected in only three cases (6.9%), based on the urine cytology. In the present case, SmCCB was initially suspected based on urine cytology features; these included clusters of small tumor cells with little cytoplasm that resembled neuroendocrine carcinoma and marked hyperchromatic nuclei (fig. 1). Therefore, preoperative urine cytology may be an important auxiliary diagnostic tool for SmCCB, contributing to the early diagnosis of SmCCB. Early diagnosis of SmCCB is very important because, due to the rapid progression and poor prognosis of the disease, treatment must be initiated as soon as possible.

Another characteristic of SmCCB is its poor prognosis. SmCCB is biologically much more aggressive than UC, with early metastasis and poor prognosis. Approximately 40% of SmCCB patients present with advanced disease at the time of diagnosis [8]. Cheng et al. [3] showed that 98% of SmCCB patients had muscle-invasive disease, and 66% had lymph node metastasis at the time of RC. In a study of 27 patients with SmCCB, Choong et al. [2] demonstrated that the distribution of stage II, III, and IV disease was 27.3, 29.6, and 43.2%, respectively. In that study, the 3- and 5-year survival rates were 20 and 8–13.5%, respectively, and the mean survival time was only 9.4–19.6 months [2]. The characteristics and prognosis for patients with SmCCB at our institution are presented in table 1. Between 2000 and 2015, a total of 263 patients underwent RC at our institution, and of these, four patients (1.5%) had SmCCB. The mean survival time in those four cases was 9.75 months, which is consistent with previous reports. Surprisingly, two of the four patients with SmCCB died just 2 months after undergoing RC, although there was no evidence of metastasis on CT or MRI prior to surgery. In the present case, persistent gross hematuria with high T stage was identified using CT and MRI. In such cases, when systemic chemotherapy is not effective, it was expected that the patient's quality of life would be markedly worsened due to bladder tamponade or frequent transfusions. Therefore, RC was performed as the initial treatment, after which immediate adjuvant chemotherapy was scheduled. However, the disease progressed too rapidly and the chemotherapy could not be administered. The patient died just 2 months after RC.

There is no standard therapy for primary SmCCB because it is so rare. Options for local treatment include TURBT, RC, and radiation, similar to those for UC. It has been reported that simple TURBT treatment may result in uncontrolled disease, high recurrence rates, and poor survival periods of 3–6 months [9]. In addition, Cheng et al. [3] demonstrated that there was no difference in the 5-year survival rate between patients who underwent RC and those who did not (15 vs. 18%, $p = 0.65$). These studies showed that surgery alone, even RC, does not confer any survival benefit for the majority of patients with SmCCB. On the other hand, multimodal therapies using a combination of neoadjuvant chemotherapy (NAC) and RC may improve long-term survival [10]. SmCCB is a systemic disease, even if it does not initially manifest as such, and its cells respond to platinum-based chemotherapy. It can be downstaged by NAC and chemosensitive micrometastases can be treated, resulting in extended survival periods. Siefker-Radtke et al. [10] showed that patients with SmCCB who received a combination of NAC and RC had longer survival periods than the patients who underwent RC alone (5-year survival rate: NAC + RC, 78%; RC alone, 36%). In another study by the same authors, it was demonstrated that pathological downstaging occurred via NAC in 78% of patients, resulting in a median overall survival of 58 months [11]. Lynch et al. [12] demonstrated even more favorable results for the SmCCB patients at their institution, with a median survival of 159.5 months and a 5-year survival rate of 79%. Some studies reported that

chemoradiotherapy may be used as an alternative to NAC and RC. Lohrisch et al. [13] reported that the 5-year survival rate in the 10 SmCCB patients in their study was 44% after chemoradiotherapy. Bex et al. [14] reported complete response in 88% of 17 SmCCB patients who underwent chemoradiotherapy after TURBT, with a median overall survival time of 32.5 months.

In summary, based on these previous studies, systemic chemotherapy before local treatments such as RC and radiation may represent a key treatment strategy for patients with SmCCB. In fact, in the present study, adjuvant chemotherapy after RC had been scheduled for the two SmCCB patients (50%) at our institution who died only 2 months after RC, but the disease progressed too rapidly and the adjuvant therapy could not be administered. Systemic chemotherapy as soon as possible after a diagnosis of SmCCB appears to be an important parameter in reducing chemosensitive micrometastases, even if metastasis is not observed at diagnosis and the patients appear suitable for surgery. In that regard, early diagnosis is necessary for early initiation of systemic chemotherapy. Preoperative urine cytology may contribute to this auxiliary diagnosis.

Only one patient at our institution underwent NAC. This patient had lymph node metastasis at the time of diagnosis. This resulted in a survival period of 13 months after RC, which is shorter than that reported in previous studies.

Conclusion

Early initiation of systemic chemotherapy before local treatment such as RC or radiation is a key treatment strategy for SmCCB. It should be discussed in detail before surgery.

Acknowledgments

The authors acknowledge the support provided by the Department of Anatomic Pathology (Tokyo Medical University) who prepared the specimens for microscopic observation and prepared the figures presented in this study.

Statement of Ethics

Consent for publication of this case report was obtained from the patient at the outpatient clinic at our institution.

Disclosure Statement

None of the authors has any relevant financial or nonfinancial relationships to disclose.

References

- 1 Blomjous CE, Vos W, De Voogt HJ, et al: Small cell carcinoma of the urinary bladder. A clinicopathologic, morphometric, immunohistochemical, and ultrastructural study of 18 cases. *Cancer* 1989;64:1347.

- 2 Choong NW, Quevedo JF, Kaur JS: Small cell carcinoma of the urinary bladder. The Mayo Clinic Experience. *Cancer* 2005;103:1172.
- 3 Cheng L, Pan CX, Yang XJ, et al: Small cell carcinoma of the urinary bladder: a clinicopathologic analysis of 64 patients. *Cancer* 2004;101:957.
- 4 Sved P, Gomez P, Manoharan M, et al: Small cell carcinoma of the bladder. *BJU Int* 2004;94:12.
- 5 Pervez N, El-Gehani F, Joseph K, et al: Genitourinary small-cell carcinoma: a single-institution experience. *Curr Oncol* 2013;20:258.
- 6 Hou CP, Lin YH, Chen CL, et al: Clinical outcome of primary small cell carcinoma of the urinary bladder. *Onco Targets Ther* 2013;6:1179.
- 7 Takada S, Yoshikawa M, Hosokawa Y, et al: Small cell carcinoma of the urinary bladder detected by urinary cytology: a case report (in Japanese). *Hinyokika Kyo* 2010;56:173.
- 8 Koay EJ, Teh BS, Paulino AC, et al: A Surveillance, Epidemiology, and End Results analysis of small cell carcinoma of the bladder: epidemiology, prognostic variables, and treatment trends. *Cancer* 2011;117:5325.
- 9 Celik O, Ekin G, Ipekci T, et al: Diagnosis and treatment in primary bladder small cell carcinoma: literature review. *Arch Ital Urol Androl* 2016;88:52.
- 10 Siefker-Radtke AO, Dinney CP, Abrahams NA, et al: Evidence supporting preoperative chemotherapy for small cell carcinoma of the bladder: a retrospective review of the M. D. Anderson cancer experience. *J Urol* 2004;172:481.
- 11 Siefker-Radtke AO, Kamat AM, Grossman HB, et al: Phase II clinical trial of neoadjuvant alternating doublet chemotherapy with ifosfamide/doxorubicin and etoposide/cisplatin in small-cell urothelial cancer. *J Clin Oncol* 2009;27:2592.
- 12 Lynch SP, Shen Y, Kamat A, et al: Neoadjuvant chemotherapy in small cell urothelial cancer improves pathologic downstaging and long-term outcomes: results from a retrospective study at the MD Anderson Cancer Center. *Eur Urol* 2013;64:307.
- 13 Lohrisch C, Murray N, Pickles T, et al: Small cell carcinoma of the bladder: long term outcome with integrated chemoradiation. *Cancer* 1999;86:2346.
- 14 Bex A, Nieuwenhuijzen JA, Kerst M, et al: Small cell carcinoma of bladder: a single-center prospective study of 25 cases treated in analogy to small cell lung cancer. *Urology* 2005;65:295.

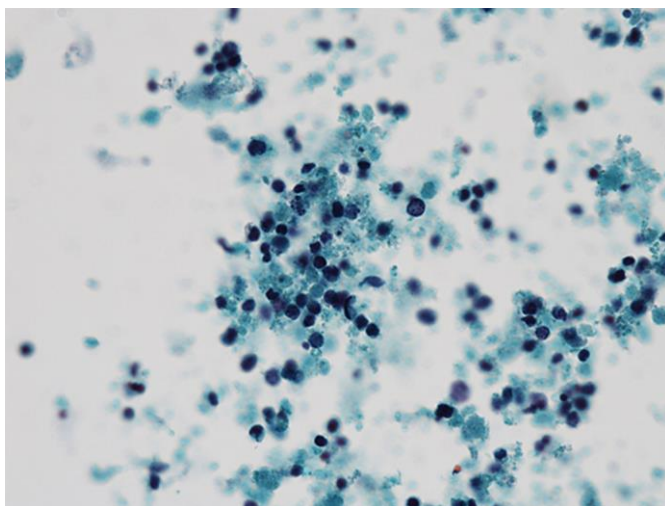


Fig. 1. Preoperative urinary cytology findings reveal clusters of small tumor cells resembling neuroendocrine carcinoma ($\times 40$).

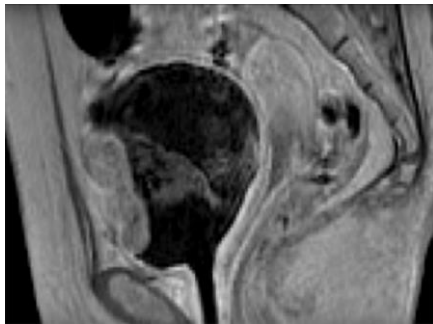


Fig. 2. MRI (sagittal section) before the initiation of transurethral resection of bladder tumor shows a broad-based solitary nodular tumor on the anterior wall of the bladder with a diameter of 54 × 50 × 24 mm, indicating extracystic invasion, and no evidence of distant or lymph node metastasis.

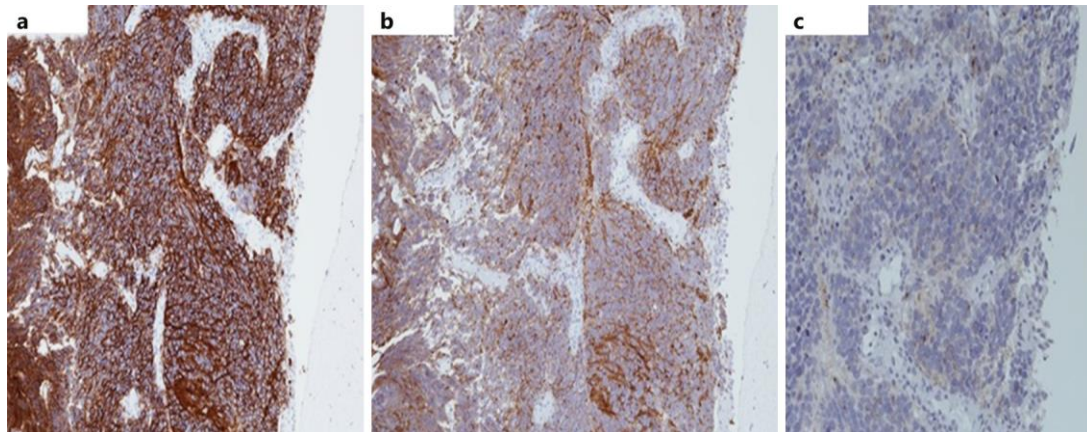


Fig. 3. Immunohistochemical staining for cluster of differentiation 56 (a) (original magnification: ×10), synaptophysin (b) (×10), and chromogranin A (c) (×10) of small-cell carcinoma of the bladder.

Table 1. Characteristics of the patients with small-cell carcinoma of the bladder at our institution

Case No.	Age, years	Gen-der	Stage	cTNM	Location of metas-tasis	Histology	Neo-adjuvant chemo-therapy	Local therapy	Location of recurrence	Outcome (months after surgery)
1	68	M	III	cT3bN0M0	–	SmCCB + UC + AC	–	TC + IC	lung, bone, brain	DOD (22)
2	74	M	IV	cT3bN1M0	LN	SmCCB + UC	GC 2	TC + IC	brain	DOD (13)
3	73	M	III	cT3aN0M0	–	SmCCB	–	TC + IC	liver	DOD (2)
4 (present case)	61	F	III	cT3bN0M0	–	SmCCB	–	TC + IC	bone	DOD (2)

UC = Urothelial carcinoma; SmCCB = small-cell carcinoma of the bladder; AC = adenocarcinoma; GC = gemcitabine + cisplatin; TC = total cystectomy; IC = ilial conduit; LN = lymph node; DOD = died of disease; cTNM = clinical classification of tumor node metastasis.