

Inflammation and infection

Spontaneous rupture of pyonephrosis leading to pyoperitoneum

Imran Khan Jalbani*, Muhammad Khurram, Wajahat Aziz

Aga Khan University Hospital, Karachi, Pakistan



ABSTRACT

Forniceal rupture after pyonephrosis can lead to retroperitoneal abscess but extension into peritoneal cavity is unusual. We present a case of 50 year old lady who presented with acute abdomen, CT scan of abdomen showed features suggestive of left pyelonephritis and large intraperitoneal collection. Laparotomy was planned on suspicion of intraperitoneal source of sepsis. Peroperatively no intraperitoneal source of sepsis was found. Retrograde pyelography showed forniceal rupture at lower pole of kidney extending to peritoneal cavity without any obstructing stone or lesion. This case highlights an unusual presentation of pyonephrosis with peritonitis and pyoperitoneum.

Introduction

Acute abdomen is a common clinical presentation in emergency department. Stratifying patients into those requiring surgery and those to be managed conservatively is an important aspect of initial evaluation.¹ Diagnosis of peritonitis is mainly clinical, supported by imaging studies to confirm the diagnosis and find out underlying cause.² In cases of peritonitis patient is usually evaluated for an intraabdominal source of sepsis and if found should undergo surgical treatment. Extraperitoneal pathologies e.g. pancreatitis and pyelonephritis may also present with signs of peritonitis, however these are managed conservatively as there is no direct extension into peritoneal cavity. We present a case of forniceal rupture after pyonephrosis leading to direct extension into peritoneal cavity causing pyoperitoneum and acute abdomen.

Case presentation

A 50 year old, female with no known comorbidities presented to ER with severe abdominal pain and vomiting for last one month. Pain started in epigastric region and was radiating towards umbilicus. There was no exacerbating or relieving factor and no history of dyspepsia, burning micturition or lower urinary tract symptoms. She also reported high grade intermittent fever during previous month. Past medical and surgical history was unremarkable. At presentation she was in sepsis with pulse of 102-beats/min, blood pressure of 90/53 mmHg and temperature of 101 °F. The abdomen was diffusely tender with some

guarding and rigidity more marked in left upper quadrant.

Baseline investigations showed TLC count of 25.5×10^9 with 97% neutrophils and Procalcitonin of 24.67ng/ml. Serum amylase, Lipase, Creatinine and liver function tests were within normal limits. Urinalysis was positive for nitrites and leucocyte esterase and microscopy showed > 20 WBC/HPF. Urine Culture later revealed $> 10^3$ and $< 10^4$ CFU/ml of *Klebsiella pneumoniae*.

Ultrasound showed swollen left kidney with moderate hydronephrosis and some echogenic material within lower pole calyx. As clinical examination was suggestive of generalized peritonitis, Contrast enhanced Computed tomography (CT) scan was carried out which showed swollen Left kidney with marked perinephric stranding. Additionally a perinephric collection was noted abutting left psoas muscle and extending anteriorly to duodenojejunal flexure. High-density fluid collection was also noted in rectouterine pouch, extending anterior to urinary bladder with peritoneal enhancement suggesting pyoperitoneum (Fig. 1).

As pyelonephritis usually leads to perinephric abscess with extension limiting to retroperitoneum, this intraperitoneal collection was unusual. So an additional intra-abdominal source of sepsis such as perforated bowel or diverticulitis was suspected and a laparotomy was performed both to drain pus collection and rule out intraperitoneal source of sepsis.

Urology and General Surgery teams were involved and after optimization, patient was planned for laparotomy. Intraoperatively purulent collection was found throughout the peritoneal cavity and 1 L of pus was drained. This intra-abdominal collection was found to be ex-

* Corresponding author.

E-mail address: wajahat.aziz@aku.edu (I.K. Jalbani).<https://doi.org/10.1016/j.eucr.2019.100928>

Received 25 March 2019; Accepted 29 May 2019

Available online 31 May 2019

2214-4420/ © 2019 The Authors. Published by Elsevier Inc. This is an open access article under the CC BY-NC-ND license (<http://creativecommons.org/licenses/by-nc-nd/4.0/>).

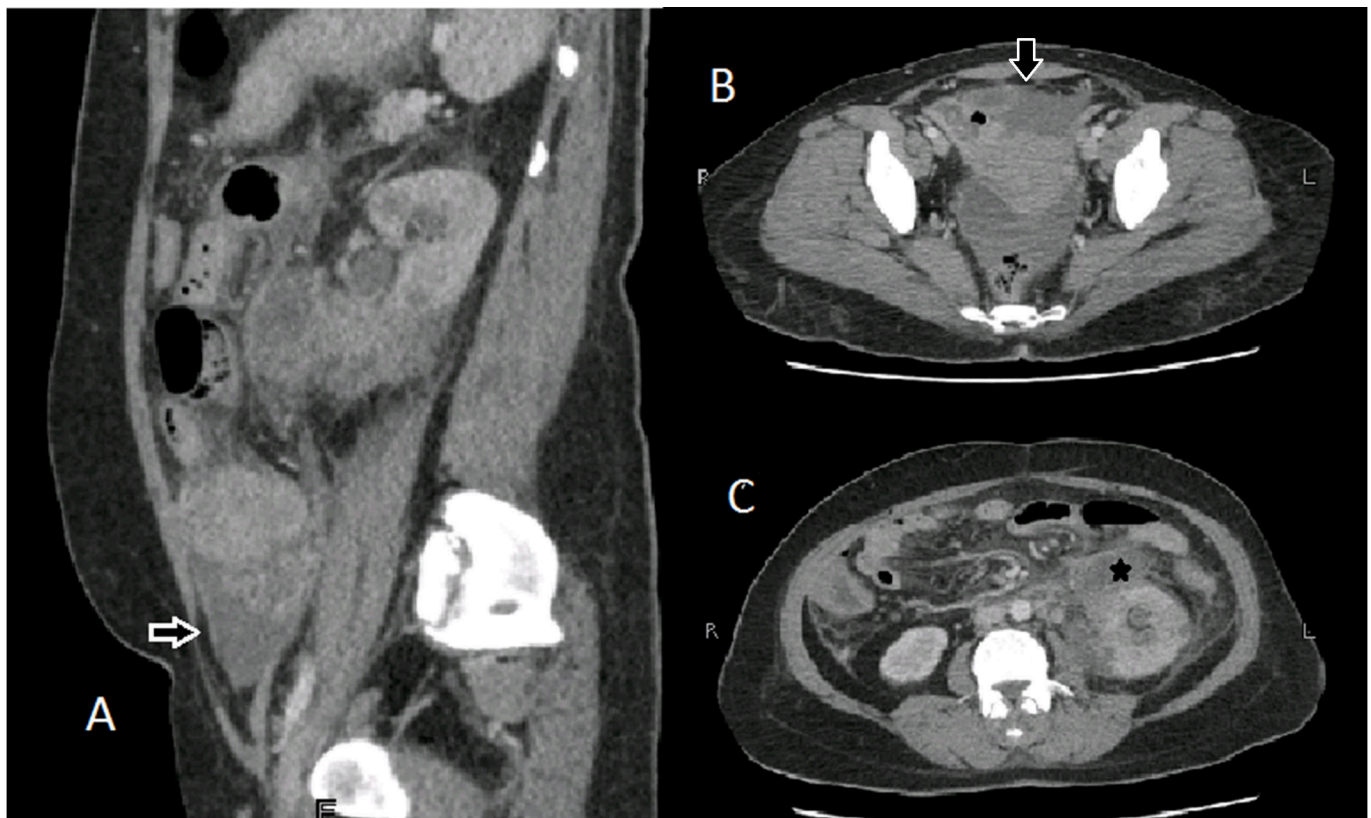


Fig. 1. CT abdomen showing intraperitoneal collection (A and B, black arrow) along with perinephric collection (C, asterisk*).

tending to left perinephric space which was also evacuated. No additional intraperitoneal source of pyoperitoneum was identified. However, on retrograde pyelography forniceal rupture was found at left lower pole calyx with contrast extravasating in perinephric space extending to peritoneal cavity (Fig. 2). A Double J stent was placed.

Postoperatively patient recovered well. She received IV fluids and IV antibiotics till complete resolution of sepsis and discharged on 6th postoperative day after removal of abdominal drains. She was followed in clinic 2 weeks after surgery and DJ stent was removed after 6 weeks. She has remained asymptomatic till last follow up. Repeat ultrasound showed no hydronephrosis or collection. As no pathological cause of pyelonephritis including diabetes mellitus, voiding dysfunction or renal stones was identifiable and pus culture was negative for any unusual pathogens, she has been advised general precautions to prevent recurrent UTI.

Discussion

Peritonitis and pyoperitoneum usually originate from intraperitoneal pathology. However retroperitoneal infections can also lead to irritation of peritoneum producing signs and symptoms of

peritonitis e.g. pyelonephritis and pancreatitis. Nevertheless in such cases the mainstay of management is conservative management, along with treatment of any underlying pathology, for instance ureteric stones in case of pyelonephritis or gallstones in cases of pancreatitis. Abdominal exploration with laparotomy or laparoscopy is only required if some additional pathology is suspected or there is direct involvement of intraperitoneal structures. In patients with pyelonephritis and forniceal rupture, the pus collection is usually limited to retroperitoneum as there is no anatomical extension with general peritoneal or pelvic cavity. Yet direct extension into peritoneal cavity from retroperitoneal infection without any inciting event has been reported previously. Shifti and Bekele reported a case of ruptured pyonephrosis leading to peritonitis in a patient with pelviureteric junction obstruction leading to cortical thinning.³ Similarly, Hendaoui presented similar case of intraperitoneal extension in patient with non-functioning kidney due to urolithiasis.⁴ However, our patient had a good functioning kidney with no parenchymal loss. Spontaneous forniceal rupture is known to occur in patients with pyelonephritis⁵ specially if there is an obstructing lesion. However, pyoperitoneum is an unusual sequelae of such retroperitoneal infection.

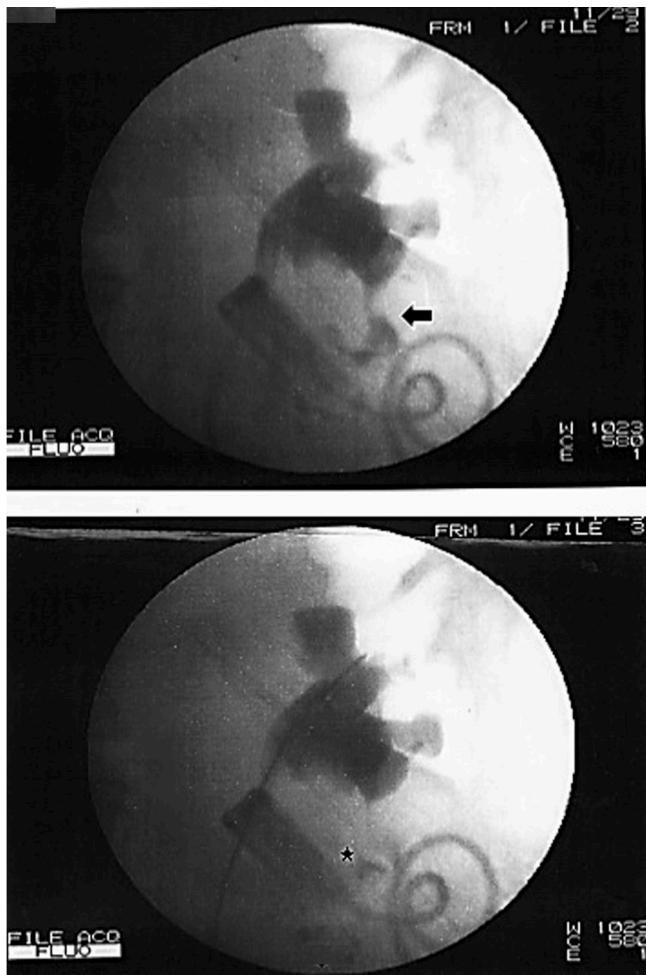


Fig. 2. Retrograde pyelography showing forniceal rupture at lower pole (black arrow) and contrast extension into retroperitoneum and peritoneal cavity (asterisk *).

Conclusion

This unusual presentation of pyonephrosis suggests that retroperitoneal infections can rarely lead to intraperitoneal extension and rupture of pyonephrosis can potentially occur even in absence of any obstructing stone or lesion. Peritoneal lavage and exploration is still warranted in such cases to rule out concomitant intraperitoneal pathology.

References

1. Nakagoe T, et al. Surgical risk model for acute diffuse peritonitis based on a Japanese nationwide database: an initial report on the surgical and 30-day mortality. *Surg Today*. 2015;45(10):1233–1243.
2. Reginelli A, et al. The role of computed tomography in the preoperative assessment of gastrointestinal causes of acute abdomen in elderly patients. *Int J Surg*. 2014;12:S181–S186.
3. Shifti DM, Bekele K. Generalized peritonitis after spontaneous rupture of pyonephrosis: a case report. *Int Med Case Rep J*. 2018;11:113.
4. Hendaoui M, et al. A rare complication of renal lithiasis: peritonitis and splenic abscess caused by rupture of pyonephrosis. *J Urol*. 1996;102(3):130–133.
5. Jalbani IK, Ather M. Renal forniceal rupture in pregnancy secondary to obstructive renal stone presenting with acute renal failure. *Saudi J Kidney Diseases Transplantation*. 2014;25(5):1081.