

## Endoscopic resection of a duodenal Brunner gland hamartoma presenting with GI bleeding

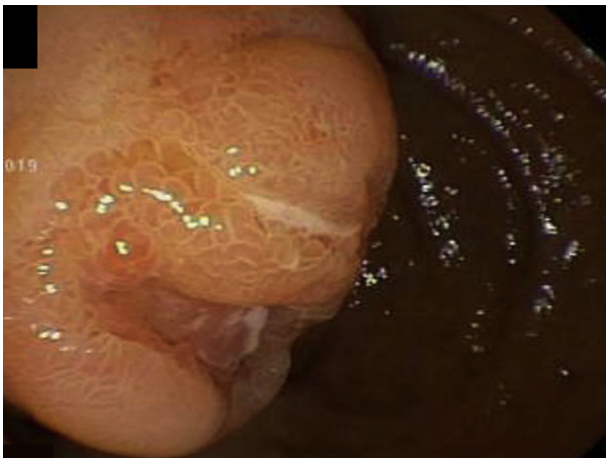


Tara Keihanian, MD, MPH,<sup>1</sup> Jonathan S. England, MD,<sup>2</sup> Sunil Amin, MD, MPH<sup>1</sup>

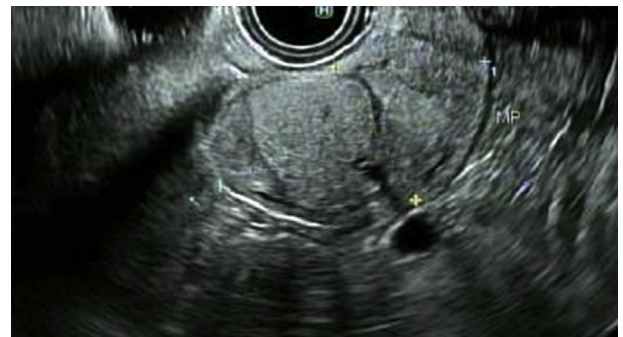A 64-year-old man with a history of diabetes mellitus, hypertension, chronic kidney disease, and primary mycotic infrarenal aortitis complicated with pseudoaneurysm formation after repair was seen at our hospital with a 3-day history of weakness and melena. His hemoglobin level on presentation was 6.1 g/dL from a baseline of 12.5 to 13 g/dL. International normalized ratio and platelet count were normal. Upper EGD was performed and revealed a large submucosal duodenal mass arising from the distal bulb to the second portion of the duodenum without involving the ampulla. The largest part of the mass ap-

peared to be submucosal with several superficial erosions and without active bleeding (Figs. 1 and 2, Video 1, available online at [www.VideoGIE.org](http://www.VideoGIE.org)).

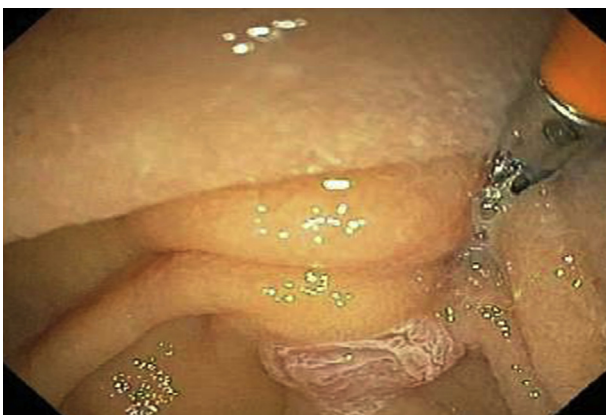The patient was referred for EUS to assess the depth of invasion and distal extent of the lesion. EUS was remarkable for a 3.5-cm submucosal polypoid mass with a broad-based stalk in the duodenal bulb prolapsing into the distal duodenum (Fig. 3). Both fine-needle and mucosal biopsy were performed. He was discharged from the hospital with stable hemoglobin after blood transfusion (8.7 g/dL), awaiting pathology results. Histologic examination demonstrated a lobular proliferation of Brunner's-type glands, compatible with a Brunner's gland hamartoma, without evidence of dysplasia.



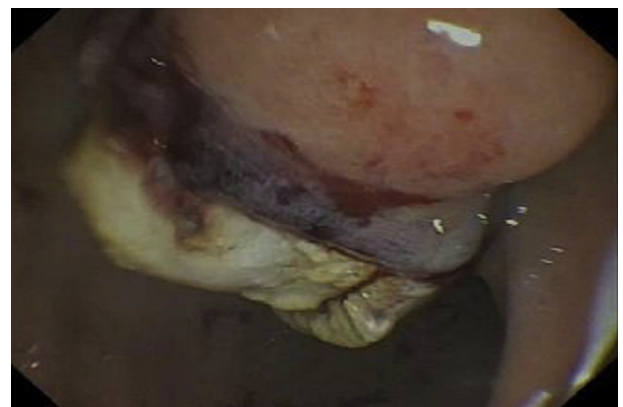**Figure 1.** First EGD showing duodenal bulb mass with superficial erosions causing melena and downtrending hemoglobin level.



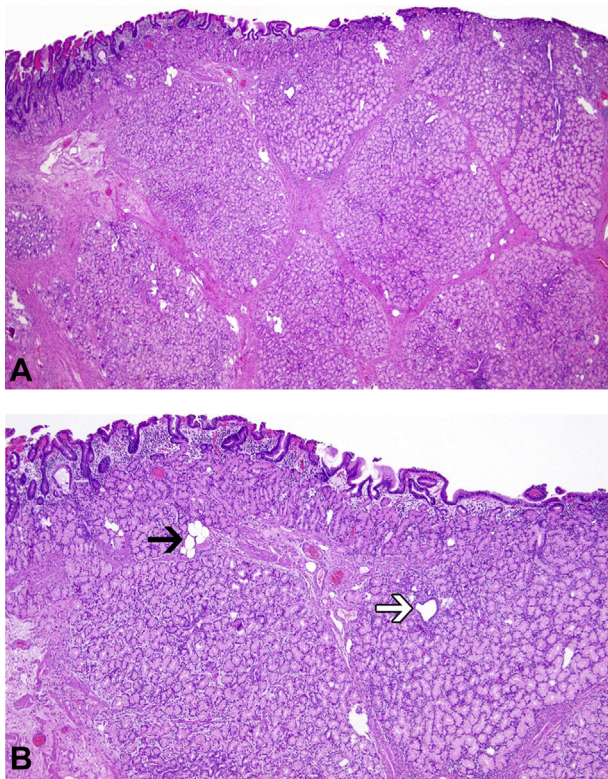
**Figure 3.** Linear EUS image of a 3.5-cm polypoid mass prolapsing in the second portion of the duodenum. The mass originates from the submucosa (layer 3). The muscularis propria (layer 4) is clearly seen as intact.



**Figure 2.** First EGD showing an intact ampulla.



**Figure 4.** Submucosal fat after resection consistent with Brunner's gland hamartoma.



**Figure 5.** Pathology testing of endoscopic resection specimen. **A**, Hematoxylin and eosin staining shows a proliferation of lobular Brunner's glands separated by fibromuscular septae. The proliferation is centered in the submucosa with extension into the overlying mucosa. **B**, At higher magnification, cystically dilated ducts (*black arrow*) and occasional foci of adipose tissue (*white arrow*) are present. There is surface mucosal injury characterized by flattening, congestion, and foveolar metaplasia.

The patient underwent endoscopic resection of the mass in a subsequent endoscopy session. A large endoloop (PolyLoop ligating device; Olympus America, Center Valley, Pa) was maneuvered over the hamartoma stalk and closed at the base before removal to prevent bleeding. Two milliliters of 1:10,000 epinephrine was then injected into the stalk to further prevent any immediate bleeding. A 30-mm standard-stiffness snare (Boston Scientific, Marlborough, Mass) was used with the forward-viewing gastroscope to remove the lesion using Endocut Q (ERBE USA, Marietta, Ga), Effect 3; however, complete resection of the hamartoma was not achieved.

Because of difficulty in placing the snare around the remainder of the lesion with the gastroscope, the side-viewer was used to successfully position the snare over the remaining hamartoma, close it above the endoloop at the base of the lesion, and complete the resection. A small part of the polyp was deliberately left above the endoloop to minimize the risk of perforation and bleeding—the endoscopic objective was not to achieve complete en bloc resection but rather cessation of GI bleeding (Fig. 4).

Histologic examination showed expansile lobules of predominantly submucosal Brunner's glands with occasional dilated ducts and adipose tissue, confirming the prior

biopsy interpretation of a Brunner's gland hamartoma. The overlying mucosa was flattened and demonstrated changes consistent with peptic-type injury (Fig. 5). The patient was discharged the same day as the procedure with no adverse events or further episodes of melena.

Brunner's gland hamartomas are benign proliferative tumors arising from the duodenal Brunner's glands and account for 10.6% of benign tumors of the duodenum.<sup>1</sup> These lesions are submucosal, mucin secreting, and most commonly located in the duodenal bulb (70%), followed by the second and third portion of the duodenum (26% and 4%, respectively).<sup>1,2</sup> Most of these lesions are between 2 and 5 cm, and the majority of symptomatic cases present with either bowel obstruction or GI bleeding as a result of superficial erosions and ulceration.<sup>3</sup> Diagnosis usually requires deep tissue biopsy with EUS for histopathologic evaluation. EUS also provides information about the depth of involvement and any associated submucosal vasculature.

Because endoscopic resection is a less-invasive procedure with fewer adverse events, it is the preferred approach over the surgical approach.<sup>4</sup> Usually the presence of a vessel within the stalk increases the risk of postresection bleeding, and pretreatment of the stalk with epinephrine and/or mechanical hemostasis is recommended.<sup>5</sup> Our case highlights the fact that endoscopic resection is usually a safe and easy approach for management of symptomatic Brunner's gland hamartomas.

## DISCLOSURE

*All authors disclosed no financial relationships.*

## REFERENCES

- Gao YP, Zhu JS, Zheng WJ. Brunner's gland adenoma of duodenum: a case report and literature review. *World J Gastroenterol* 2004;10:2616-7.
- Levine JA, Burgart LJ, Batts KP, et al. Brunner's gland hamartomas: clinical presentation and pathological features of 27 cases. *Am J Gastroenterol* 1995;90:290-4.
- Yi L, Cheng Z, Qiu H, et al. A giant Brunner's gland hamartoma being treated as a pedunculated polyp: a case report. *BMC Gastroenterol* 2019;19:151.
- Zhong YS, Shi Q, Wu HF, et al. Endoscopic resection for the treatment of duodenal Brunner's adenomas. *J Laparoendosc Adv Surg Tech A* 2012;22:904-9.
- Ferlitsch M, Moss A, Hassan C, et al. Colorectal polypectomy and endoscopic mucosal resection (EMR): European Society of Gastrointestinal Endoscopy (ESGE) Clinical Guideline. *Endoscopy* 2017;49:270-97.

Department of Medicine, Division of Gastroenterology, University of Miami Miller School of Medicine, Miami, Florida (1), Department of Pathology, University of Miami Miller School of Medicine, Miami, Florida (2).

Copyright © 2020 American Society for Gastrointestinal Endoscopy. Published by Elsevier Inc. This is an open access article under the CC BY-NC-ND license (<http://creativecommons.org/licenses/by-nc-nd/4.0/>).

<https://doi.org/10.1016/j.vgje.2020.05.019>