

CASE REPORT

Left ventricular outflow tract obstruction and mitral valve regurgitation in a patient with takotsubo cardiomyopathy

Yin Wu, MD¹, WuQiang Fan, MD^{1*}, Laura Chachula², Gary Costacurta, MD³, Rajeev Rohatgi, MD³ and Farhad Elmi, MD³

¹Department of Medicine, Easton Hospital, School of Medicine, Drexel University, Easton, PA, USA;

²Philadelphia College of Osteopathic Medicine, Philadelphia, PA, USA; ³Easton Cardiovascular Associates, Cardiovascular Institute, Easton Hospital, School of Medicine, Drexel University, Easton, PA, USA

Introduction: Takotsubo cardiomyopathy (TCM) can be complicated by left ventricular outflow tract (LVOT) obstruction and severe acute mitral regurgitation (MR), leading to hemodynamic instability in an otherwise benign disorder. Despite the severity of these complications, there is a paucity of literature on the matter. Because up to 20–25% of TCM patients develop LVOT obstruction and/or MR, it is important to recognize the clinical manifestations of these complications and to adhere to specific management in order to reduce patient morbidity and mortality. We report the clinical history, imaging, treatment strategy, and clinical outcome of a patient with TCM that was complicated with severe MR and LVOT obstruction. We then discuss the pathophysiology, characteristic imaging, key clinical features, and current treatment strategy for this unique patient population.

Case report: A postmenopausal woman with no clear risk factor for coronary artery disease (CAD) presented to the emergency department with chest pain after an episode of mental/physical stress. Physical examination revealed MR, mild hypotension, and pulmonary vascular congestion. Her troponins were mildly elevated. Cardiac catheterization excluded obstructive CAD, but revealed severe apical hypokinesia and ballooning. Notably, multiple diagnostic tests revealed the presence of severe acute MR and LVOT obstruction. The patient was diagnosed with TCM complicated by underlying MR and LVOT obstruction, and mild hemodynamic instability. The mechanism of her LVOT and MR was attributed to systolic anterior motion of the mitral valve (SAM), which the transesophageal echocardiogram clearly showed during workup. She was treated with beta-blocker, aspirin, and ACE-I with good outcome. Nitroglycerin and inotropes were discontinued and further avoided.

Conclusions: Our case illustrated LVOT obstruction and MR associated with underlying SAM in a patient with TCM. LVOT obstruction and MR are severe complications of TCM and may result in heart failure and/or pulmonary edema. Timely and accurate identification of these complications is critical to achieve optimal clinical outcomes in patients with TCM.

Keywords: *takotsubo cardiomyopathy; left ventricular outflow tract obstruction; mitral regurgitation; systolic anterior motion of the mitral valve*

*Correspondence to: WuQiang Fan, Department of Medicine, Easton Hospital, School of Medicine, Drexel University, 250 S 21st St, Easton, PA 18042, USA, Email: wuqiang_fan@chs.net

Received: 12 August 2015; Revised: 17 September 2015; Accepted: 22 September 2015; Published: 11 December 2015

Takotsubo cardiomyopathy (TCM) is characterized by severe, transient systolic cardiac dysfunction, mimicking an acute myocardial infarction, in the absence of obstructive coronary artery disease (CAD). The disease is mostly triggered by emotional/physical stress and its clinical outcome is typically both reversible and benign. Nonetheless, up to 20–25% of patients with TCM may develop left ventricular outflow tract (LVOT) obstruction and/or acute mitral regurgitation (MR), severe complications that can lead to heart failure, shock, and/or pulmonary edema. Despite its gravity, there

is a paucity of literature on this subset of TCM, which has its own unique clinical features and warrants specific management for best patient outcome. Here we broach this subject through case presentation of TCM complicated by both LVOT obstruction and MR, secondary to an underlying systolic anterior motion (SAM) of mitral valve.

Case presentation

A 63-year-old woman presented to the emergency department with anterior chest discomfort which began the previous night after she had a verbal altercation with her

11-year-old nephew, who also hit her several times on the chest. She took an over-the-counter pain pill for immediate relief and went to bed only to wake up with 10/10 chest pain the next morning. On review of symptoms, the patient denied diaphoresis, palpitations, lightheadedness, shortness of breath, nausea, and vomiting; she also denied having had any prior occurrence of her symptoms. Her past medical history was negative for hypertension, dyslipidemia, diabetes, angina, or congestive heart failure. She had no smoking history or family history of CAD.

On physical examination, her systolic blood pressure ranged from the high 80s to low 90s. SO_2 was 88–90% on room air, increasing to 92–93% with 3 LPM O_2 via nasal cannula. Cardiac examination revealed mild chest wall tenderness and a reduced S1 intensity with normal S2. There was no S3 gallop. A grade 3/6 holosystolic murmur was heard across the precordium and radiating to her back. No pericardial friction rub or thrill was appreciated. Scarce bibasilar crackles were heard in the lungs bilaterally. Peripheral pulses were strong, and she was without lower extremity edema or cyanosis.

The patient’s laboratory results were significant for an elevated troponin of 6.6 which increased slightly to 8.2 over 6 hours before trending downward to 5.6. A 12-lead electrocardiogram (EKG) showed isolated ST-T segment elevation in lead V2 (Fig. 1a) from baseline (Fig. 1b). Her CXR revealed new-onset vascular congestion. A bedside transthoracic echocardiogram (TTE) revealed moderately severe MR with pulmonary hypertension and extreme hypokinesia of the lower half of the septum, apex, and adjacent inferior wall (data not shown).

Because the patient’s symptoms warranted treatment as an acute coronary syndrome (ACS), cardiac catheterization was performed. Surprisingly, however, coronary angiography revealed the epicardial arteries were clean with exception of the mid-RCA having a non-obstructive stenosis of about 30% (data not shown). Of concern was the left ventriculogram, which showed severe hypokinesia, bordering on akinesia, in the anteroapical area and a balloon-like dilation of the LV apex during systole (Fig. 1c and d). Estimated LVEF was 40%. There was also evidence of moderate to severe MR, which was further

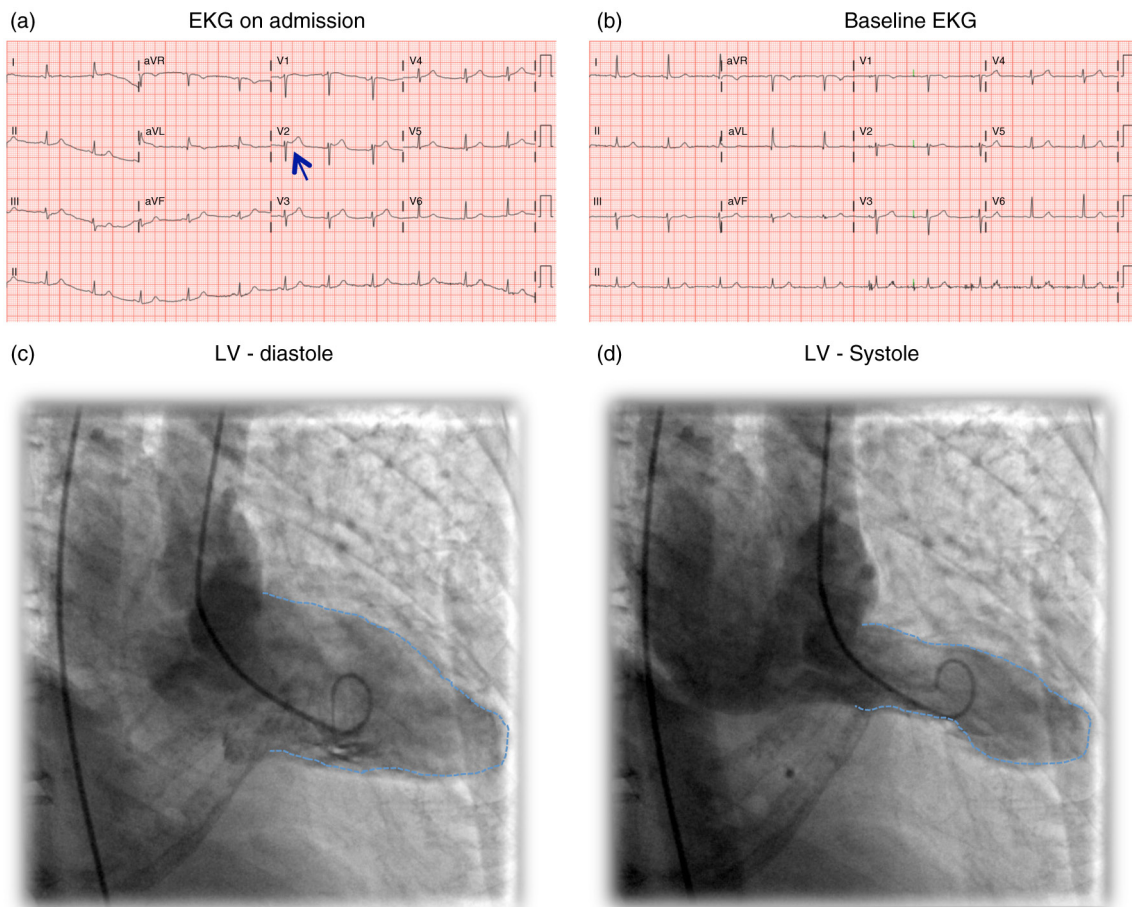


Fig. 1. (a) EKG on admission. Notice the isolated ST-T segment elevation in V2. (b) Patient’s baseline normal EKG obtained a few months prior to admission. (c) Left ventriculogram-end diastole. (d) Left ventriculogram-end systole. Notice the severe hypokinesia to akinesia in the anteroapical area and balloon-like dilation of the LV apex during systole.

supported by the pulmonary capillary wedge pressure of approximately 20 mmHg with large V waves (data not shown).

Of importance, the left heart catheterization revealed an LVOT obstruction. As shown in Fig. 2a and b, during pullback from left ventricle to aorta, there was a progressive pressure drop as the catheter passed through the LVOT, indicative of LVOT obstruction. Lack of this pressure drop from the LVOT to the aorta essentially ruled out presence of aortic stenosis (Fig. 2b).

Based on the aforementioned findings, the patient was diagnosed with TCM complicated by MR and LVOT obstruction and mild hemodynamic instability (i.e., mild hypotension and pulmonary edema). Upon diagnosis, nitroglycerin was discontinued, metoprolol and aspirin were continued, and ACE inhibitor was initiated, according to conservative therapy guidelines.

A subsequent transesophageal echocardiogram (TEE) was performed to further elucidate the patient's mechanism of MR. TEE with color Doppler confirmed severe MR (Fig. 2c), but found no definite prolapse, flail mitral valve leaflet, or papillary muscle rupture. More significantly, the TEE revealed obvious SAM of the anterior mitral valve leaflet (Fig. 2d). SAM is associated with

elevated velocities in the LVOT, consistent with LVOT obstruction. The aortic valve, however, was a normal tri-leaflet valve without stenosis.

A cardiac MRI confirmed the absence of delayed gadolinium enhancement, effectively ruling out myocarditis, fibrosis, and myocardial infarction, all of which can mimic TCM.

With the diagnosis and etiology confirmed, the patient began conservative therapy, to include beta-blocker, ACE inhibitor, aspirin, and gentle hydration, and continued to improve daily. Once her chest pain resolved and vital signs normalized, the patient was discharged and instructed to follow up regularly with her cardiologist. Repeat TTE in 1 week showed remarkable improvement of LV function and complete resolution of MR.

Discussion

First discovered and reported by a Japanese physician in 1990 (1), TCM is thought to be involved in 2% of patients presenting with suspected ACS (2, 3). Because 90% of these patients presenting with TCM are postmenopausal women with an average age of 68, it is also hypothesized that estrogen (or lack thereof) plays a key role in the development of this cardiomyopathy (4–6).

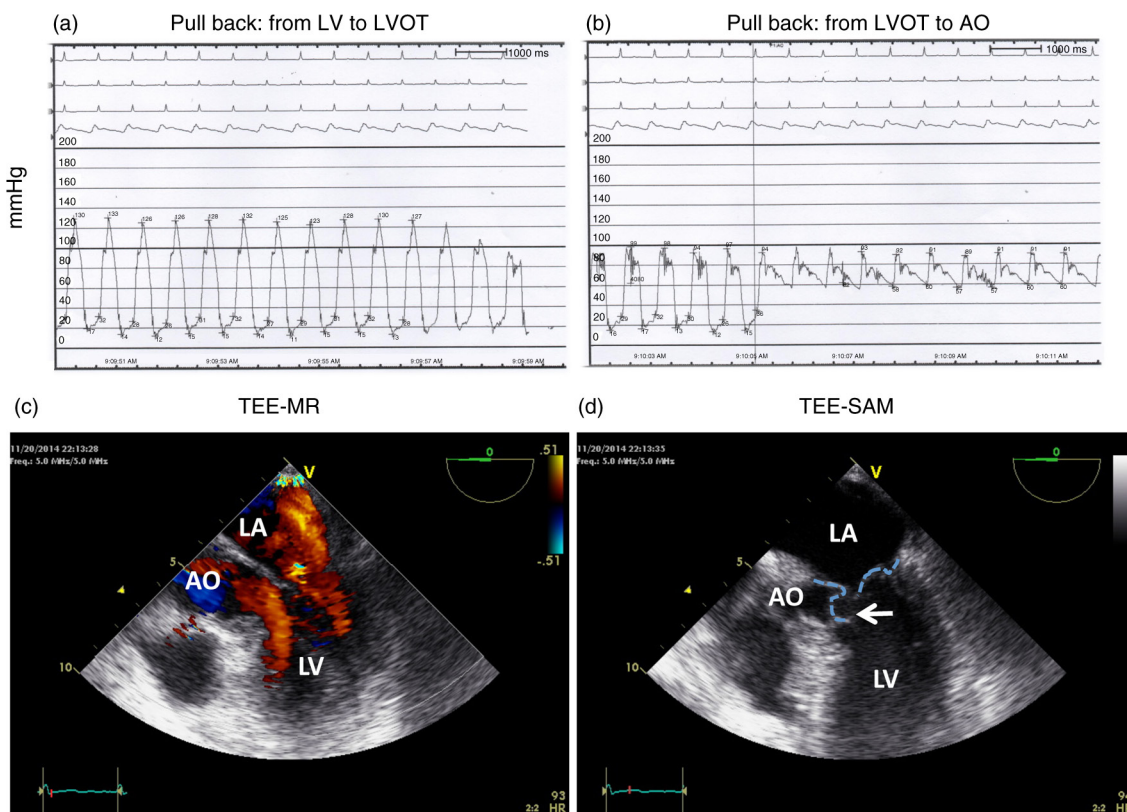


Fig. 2. (a) Pressure tracing during pull back from left ventricle to LVOT. Notice the progressive drop of pressure. (b) Pressure tracing from LVOT to aorta. (c) TEE with color Doppler during systole. Notice the severe MR jet from LV to LA. (d) Systolic anterior motion (SAM) of the anterior mitral valve leaflet. Positions of both leaflets during systole are outlined. Arrow pointing to the anterior leaflet.

Patients with TCM typically present as an ACS picture with symptoms of chest pain, palpitations, shortness of breath, and a moderately elevated troponin. This correlates with the so-called six indicative clinical features of TCM, including: 1) association with stressful emotional or physical event (seen in nearly two-thirds of the patients); 2) characteristic EKG changes (including ST segment elevation, inverted T waves or Q waves in the precordial leads, and QTc prolongation); 3) slight elevation in cardiac enzymes; 4) absence of coronary lesion on coronary angiography; 5) hypokinesia of the apex with balloon-like dilation and preserved contraction of the base; and last, 6) improvement of LV systolic function over 1 week with full recovery in 3–4 weeks (recovery typical of most patients).

These clinical features are also well incorporated in the Mayo Clinic's Diagnostic Criteria of TCM (7, 8), consisting of 1) suspicion of AMI based on precordial pain and ST elevation observed on the acute-phase EKG; 2) transient hypokinesia or akinesia of the middle and apical regions of the LV and functional hyperkinesia of the basal region (as observed on ventriculography or echo); 3) normal coronary arteries confirmed by arteriography (luminal narrowing of less than 50% in all the coronary arteries) within the first 24 hours after symptom onset; and 4) absence of recent significant head injury, intracranial hemorrhage, suspicion of pheochromocytoma, myocarditis, or hypertrophic cardiomyopathy.

In contrast to the complex diagnostic criteria for TCM, its treatment of supportive therapy is relatively straightforward. Hemodynamically stable patients are often treated solely with diuretics, ACE-I, and beta-blockers, whereas the addition of an anticoagulant is made in patients with severe LV apex akinesia until apex contractility improves. There is no consensus regarding long-term management, but it is reasonable to treat with beta-blockers and ACE inhibitors during the ventricular recovery period. No data supports the continuous use of these drugs, however, for the prevention of TCM recurrence or increased survivability.

Although the exact pathogenesis of TCM remains unknown, catecholamine-induced cardiotoxicity (9, 10) is a generally well-accepted theory in its etiology. The idea behind this theory is that supraphysiological levels of (stress) catecholamines induce beta-2 coupling from G_s to G_i , thus leading to the decline of myocyte contractility (11). Because there is a higher beta-2 adrenoceptor density in the apex than in the base (12), the redirection of beta-2 coupling from G_s to G_i results in stunning and paralysis of the LV apex, while the base of the heart remains hyperdynamic ('hypercontracting') due to excessive catecholamine levels.

Although paralysis of the LV apex gives rise to the majority of the characteristic clinical features of TCM (e.g., systolic LV ballooning, apical hypokinesia/akinesia,

and impaired EF) the 'hyperdynamic/hypercontracting base' can be just as problematic. Potential consequences of this hyperdynamic base include SAM, resulting in severe MR and LVOT obstruction due to the high blood flow velocity and vacuum effect at the LVOT. As illustrated in the case presentation, this unique combination of factors effectively complicates the otherwise relatively benign condition of TCM.

A recent study showed that up to 20% of TCM patients may develop LVOT obstruction (13). Factors associated with this complication are advanced age, septal bulging, SAM-induced MR, and hemodynamic instability. These patients are also more likely to present in cardiogenic shock as compared to their cohorts without LVOT obstruction (13). Of note, all patients with LVOT obstruction in this study showed SAM of the anterior mitral valve leaflet and high-grade MR (13). Together, LVOT obstruction and severe MR increase the risk of cardiogenic shock and pulmonary edema. Thus, prompt and accurate diagnosis of LVOT obstruction and MR is critical for optimal clinical outcome. For instance, in the setting of ACS, vasodilators such as nitroglycerin are commonly used; however, in cases of complicated TCM, vasodilation can exacerbate the pathology and should therefore be avoided. Inotropic therapy should also be avoided as it can increase circulating catecholamines, exaggerate basal hyperkinesia, and worsen LVOT obstruction. Instead, TCM complicated by LVOT obstruction and MR should be managed with fluid resuscitation and beta-blockers with the use of intra-aortic balloon pump when necessary.

Although SAM plays a crucial role in the mechanism of acute MR in TCM patients, a recent study revealed that this mechanism only accounts for 50% of MR, which in itself was present in 12 out of 47 (25.5%) confirmed TCM patients (14). Mitral valve leaflet tethering associated with LV systolic dysfunction and LV enlargement was found to serve as an alternate mechanism of acute MR in TCM patients without SAM (14). In contrast to MR associated with SAM, treatment of choice for MR associated with LV dysfunction and dilation may require inotropes or mechanical support from balloon counterpulsation. Medications such as levosimendan may also be beneficial due to its inotropic and vasodilatory effect.

Regardless of the mechanism, however, development of acute MR in TCM is associated with a lower EF and higher systolic pulmonary pressure (14), leading to a higher risk of heart failure and/or pulmonary edema. It is thus extremely important to establish an accurate diagnosis of MR and its etiology for the stratification of disease severity and determination of treatment regimen. Bedside 2D echo is a non-invasive, first-line diagnostic imaging technique, which can be helpful in stratifying disease etiology and management according to a recent extensive review on the application of echocardiography in TCM (15).

Conclusions

Although TCM is a relatively benign and reversible disease, the case presentation illustrates the complexities posed by MR and LVOT, which can lead to pulmonary edema and cardiogenic shock. Although SAM is thought to account for LVOT and MR in most patients, MV tethering may serve as an alternate mechanism of MR. Vasodilators and inotropes are contraindicated in the former etiology, yet may be beneficial in the latter. Because of such intricacies affecting treatment in complicated TCM, prompt and accurate recognition of underlying disease and MR etiology is crucial. Bedside echo is the preferred modality to achieve these ends and ensure the best clinical outcome.

Conflict of interest and funding

Authors declare no conflicts of interest.

References

1. Tsuchihashi K, Ueshima K, Uchida T, Oh-mura N, Kimura K, Owa M, et al. Transient left ventricular apical ballooning without coronary artery stenosis: A novel heart syndrome mimicking acute myocardial infarction. *Angina Pectoris-Myocardial Infarction Investigations in Japan. J Am Coll Cardiol* 2001; 38: 11–18.
2. Parodi G, Del Pace S, Carrabba N, Salvadori C, Memisha G, Simonetti I, et al. Incidence, clinical findings, and outcome of women with left ventricular apical ballooning syndrome. *Am J Cardiol* 2007; 99: 182–5.
3. Eshtehardi P, Koestner SC, Adorjan P, Windecker S, Meier B, Hess OM, et al. Transient apical ballooning syndrome – Clinical characteristics, ballooning pattern, and long-term follow-up in a Swiss population. *Int J Cardiol* 2009; 135: 370–5.
4. Strunk B, Shaw RE, Bull S, Adams J, Baer M, Gershengorn K, et al. High incidence of focal left ventricular wall motion abnormalities and normal coronary arteries in patients with myocardial infarctions presenting to a community hospital. *J Invasive Cardiol* 2006; 18: 376–81.
5. Wedekind H, Moller K, Scholz KH. [Tako-tsubo cardiomyopathy. Incidence in patients with acute coronary syndrome]. *Herz* 2006; 31: 339–46.
6. Kuo BT, Choubey R, Novaro GM. Reduced estrogen in menopause may predispose women to takotsubo cardiomyopathy. *Gend Med* 2010; 7: 71–7.
7. Scantlebury DC, Prasad A. Diagnosis of takotsubo cardiomyopathy. *Circ J* 2014; 78: 2129–39.
8. Prasad A, Lerman A, Rihal CS. Apical ballooning syndrome (Tako-Tsubo or stress cardiomyopathy): A mimic of acute myocardial infarction. *Am Heart J* 2008; 155: 408–17.
9. Abraham J, Mudd JO, Kapur NK, Klein K, Champion HC, Wittstein IS, et al. Stress cardiomyopathy after intravenous administration of catecholamines and beta-receptor agonists. *J Am Coll Cardiol* 2009; 53: 1320–5.
10. Wittstein IS, Thiemann DR, Lima JA, Baughman KL, Schulman SP, Gerstenblith G, et al. Neurohumoral features of myocardial stunning due to sudden emotional stress. *N Engl J Med* 2005; 352: 539–48.
11. Lyon AR, Rees PS, Prasad S, Poole-Wilson PA, Harding SE. Stress (takotsubo) cardiomyopathy – A novel pathophysiological hypothesis to explain catecholamine-induced acute myocardial stunning. *Nat Clin Pract Cardiovasc Med* 2008; 5: 22–9.
12. Mori H, Ishikawa S, Kojima S, Hayashi J, Watanabe Y, Hoffman JI, et al. Increased responsiveness of left ventricular apical myocardium to adrenergic stimuli. *Cardiovasc Res* 1993; 27: 192–8.
13. De Backer O, Debonnaire P, Gevaert S, Missault L, Gheeraert P, Muyldermans L. Prevalence, associated factors and management implications of left ventricular outflow tract obstruction in takotsubo cardiomyopathy: A two-year, two-center experience. *BMC Cardiovasc Disord* 2014; 14: 147.
14. Izumo M, Nalawadi S, Shiota M, Das J, Dohad S, Kuwahara E, et al. Mechanisms of acute mitral regurgitation in patients with takotsubo cardiomyopathy: An echocardiographic study. *Circ Cardiovasc Imaging* 2011; 4: 392–8.
15. Citro R, Lyon AR, Meimoun P, Omerovic E, Redfors B, Buck T, et al. Standard and advanced echocardiography in takotsubo (stress) cardiomyopathy: Clinical and prognostic implications. *J Am Soc Echocardiogr* 2015; 28: 57–74.