



Contents lists available at ScienceDirect

## International Journal of Surgery Case Reports

journal homepage: [www.casereports.com](http://www.casereports.com)

## Blindness following bilateral neck dissection. A case report and review of the literature

Alexandra Krasnikova<sup>a</sup>, Kilian Kreutzer<sup>a</sup>, Stefan Angermair<sup>b</sup>, Max Heiland<sup>a</sup>, Steffen Koerdt<sup>a,\*</sup><sup>a</sup> Charité – Universitätsmedizin Berlin, Corporate Member of Freie Universität Berlin, Humboldt-Universität zu Berlin, and Berlin Institute of Health, Department of Oral and Maxillofacial Surgery at Campus Benjamin Franklin, Berlin, Germany<sup>b</sup> Charité – Universitätsmedizin Berlin, Corporate Member of Freie Universität Berlin, Humboldt-Universität zu Berlin, and Berlin Institute of Health, Department of Anesthesiology and Operative Intensive Care Medicine at Campus Benjamin Franklin, Berlin, Germany

## ARTICLE INFO

## Article history:

Received 15 October 2020  
 Received in revised form 28 October 2020  
 Accepted 29 October 2020  
 Available online 4 November 2020

## Keywords:

Neck dissection  
 Oral cancer  
 Blindness  
 Oropharyngeal cancer

## ABSTRACT

**INTRODUCTION:** Visual loss is a very rare but dramatic complication of such an indispensable standard procedure in head and neck tumor surgery such as the cervical lymphadenectomy (neck dissection).

**PRESENTATION OF CASE:** We present a review of the literature and a new case of a postoperative blindness of a 65-year-old man with type 2 diabetes who underwent a unilateral radical neck dissection, a contralateral modified radical neck dissection and a hemimandibulectomy for an oropharyngeal squamous cell carcinoma.

**DISCUSSION:** By now there have been only 15 clinical cases of total blindness published during the last 60 years. In 13 cases blindness followed a bilateral radical neck dissection whereas in 2 cases blindness occurred after a combined selective and modified radical neck dissection. Ischemia of the optic nerve due to intraoperative hypotension, blood loss and venous congestion were the major etiological aspects of blindness. Perioperative management of differentiated volume and blood administration, blood pressure management and a close postoperative ophthalmological check seem to be of a major importance for prevention and early detection of visual deterioration. Nevertheless, there are no clear predicative factors for blindness after neck dissection and the prognosis is unfavorable.

**CONCLUSION:** Even though postoperative vision loss is a rare and devastating complication, this current case and the review of the literature show that it occurs every once in a while following standard operations to the head and neck. Patients undergoing high-risk procedures should have to be informed that there is a slight risk of perioperative vision loss and this should be highlighted in the standard declaration of consent.

© 2020 Published by Elsevier Ltd on behalf of IJS Publishing Group Ltd. This is an open access article under the CC BY-NC-ND license (<http://creativecommons.org/licenses/by-nc-nd/4.0/>).

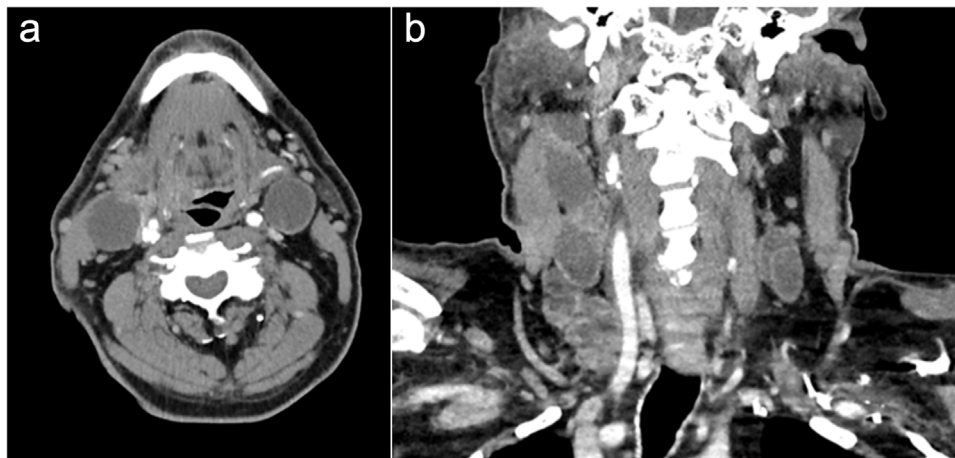
## 1. Background

Lymph nodes metastases occur frequently in advanced stages of Head and Neck Cancers, of which most are histologically Head and Neck Squamous Cell Carcinomas (HNSCC). In an individual treatment decision even in advanced stages the resection of the primary tumor as well as the clearance of the cervical lymph nodes is the guideline-based gold standard flanked by radiation and radio-chemo therapy [1]. Neck Dissection (ND) is established as a standard procedure in oncological head and neck surgery. However, selective neck dissection (SND) has no significant disadvantages in nodal relapse or overall survival compared to radical neck dissection (RND) [2,3]. Nevertheless, in cases with fixed lymph nodes

metastases RND with removal of non-lymphatic structures such as the internal jugular vein (IJV), spinal accessory nerve (SAN), and the sternocleidomastoid muscle (SCM) is inevitable. Modified Radical Neck Dissection (MRND) is defined as the clearance of levels I to V with preservation of IJV, SAN, and/or SCM. MRND has been established as a standard procedure in positive staged necks in a stage-wise clinical concept [4,5]. In addition to known surgical and medical complications following ND, blindness is a rare and unexpected risk especially in extensive head and neck procedures [6–10]. Almost all described cases occurred after bilateral RND, either simultaneously or in a 2-step approach. However, also few reports of unilateral RND and the combination of RND and MRND with postoperative blindness are described in the literature [6,7,11,12]. Etiologically, intraoperative hypotension and blood loss, increased venous pressure due to ligation of the IJV, and central retinal artery occlusion by an embolus are discussed in case reports [7].

\* Corresponding author at: Charité – Universitätsmedizin Berlin Hindenburgdamm 30, D-12203, Berlin, Germany.

E-mail address: [steffen.koerdt@charite.de](mailto:steffen.koerdt@charite.de) (S. Koerdt).



**Fig. 1.** Preoperative Computed Tomography (CT) scans in axial (a) and coronal (b) planes showing multiple lymph nodes metastases.

We present a case of a male patient with an advanced oropharyngeal carcinoma, who underwent ipsilateral RND and contralateral MRND and presented with postoperative bilateral persisting blindness. To our knowledge this is one of the few cases in the current literature with this specific postoperative complication that did not occur after bilateral RND. This case report is aimed to sensitize oncologic surgeons to this rare but existing complication following also less invasive and more commonly performed types of cervical lymph node clearance. Moreover, a review of the current literature in this special concern summarizes and categorizes causes, treatment options, and gives an overview of this specific complication. This case report has been reported in line with the SCARE 2018 criteria [13].

## 2. Case presentation

In January 2020, a 65-year-old Turkish male patient was admitted to our outpatient clinic at the Department of Oral and Maxillofacial Surgery at the Charité University Hospital, Berlin, Germany by referral of a smaller hospital. He was diagnosed with a cT3N2M0 squamous cell carcinoma of the right tonsil, with a possible infiltration of the lower jaw on the right side.

His medical history included arterial hypertension, controlled by candesartan 16 mg 1-0-1, nebivolol 5 mg 1-0-0, and lercarnidipin 10 mg 0-0-1; as well as type 2 diabetes, which was treated with insulin 300 units 0-0-1 and metformin 1000 mg 1-0-0. The patient had no history of cerebrovascular or visual disorders, he was a non-smoker, and had no history of alcohol abuse. Moreover, he had a negative family history of head and neck cancers.

A physical examination revealed an exophytic erythroleukoplakic mass arising from the right tonsil, involving the uvula and the palatoglossal arch, reaching the medial side of the mandibular ramus. Enlarged lymphatic nodes of level II and III could be palpated on both sides of his neck. The standard CT scan included in the staging procedures revealed a tumorous expansion to the right submandibular gland and metastatic lymph nodes of level II to IV on both sides (Fig. 1a and b). A combined therapeutic strategy was planned, consisting of surgery and adjuvant radio-chemotherapy.

The surgical procedure consisted of a surgical tracheostomy, an ipsilateral radical neck dissection and contralateral modified radical neck dissection, a partial pharyngectomy and hemimandibulectomy via lip split, external carotid artery was ligated on the right side during tumor resection, and reconstruction with an osteomyocutaneous fibular free flap and patient-specific implant using CAD/CAM technology.

The preoperative hematocrit was 38%. A hyperglycemia of 257 mg/dl was corrected with insulin in accordance to an intensive insulin therapy regimen. Metformin was paused 48 h prior to the operation. The preoperative blood pressure was approximately 140/80 mmHg.

The operation was performed in a two-team approach with the simultaneous flap harvest. Both, the leading surgeon performing the neck dissection and tumor resection as well as the assisting team members were experienced, operating on head and neck cancer cases on a daily basis. Total operation time was 681 min. Intraoperatively, the patient suffered two 20 min long hypotensive episodes with a minimum systolic pressure of 70 mmHg and an increased catecholamine requirement. The laboratory parameter showed an increase of serum lactate and a hyperkalemia of 5.6 mmol/L. He received a total of 12 l of isotonic electrolyte solution, 300 ml albumin, and 2 units of packed red blood cells for a total blood loss of 1 L. The intraoperatively performed transthoracic echocardiography was not informative enough to evaluate a cardiac cause of the hypotension.

The instability of the blood pressure lasted for the next 45 min after the operation. The serum lactate reached 6.6 mmol/l. During the course of the last part of the operation and immediately afterwards the patient developed a marked facial edema and flush. These symptoms improved dramatically after two hours of elevated position of head and upper body.

Immediately after the operation, reaction of the pupils was intact. Visual acuity could not be evaluated because of sedation. Postoperatively the patient was transferred to an intensive care unit where the sedation was gradually phased out. The administration of catecholamines was gradually reduced and finally stopped under differentiated volume therapy. His consciousness improved to a Glasgow Coma Scale of 13 by the third postoperative day. On the same day the patient started complaining about blurred vision and a constant pressuring headache. By the fourth postoperative he revealed non-reactive wide pupils. An urgent ophthalmological investigation showed chemosis in the anterior segment and a swelling of the head of the optic nerves of both sides in the posterior segment. No further pathological findings, such as retinal hemorrhaging or edema of the macula, could be uncovered. For further diagnosis and exclusion of any reduced cerebral perfusion or stroke, we performed a head CT which did not show any correlates for amaurosis. A high-dose intravenous cortisone treatment of 1000 mg for three days was started on the fifth postoperative day. In absence of any significant improvement, MRI scans of the head and orbital region were initiated to determine pathologies in the course of the optic nerve. A scattered infarction in the supply

area of the medial cerebral artery of the left side was discovered. Two days later, a MR-angiography did not indicate any intracranial vessel thrombosis or any enlargement of the infarction zone. In addition to anticoagulatory therapy an inhibition of thrombocyte aggregation with 100 mg of acetylsalicylic acid was started.

The repeated ophthalmological assessment on the 10<sup>th</sup> postoperative day showed a constancy of middle wide non-reacting pupils. A funduscopy revealed a pallid edematous optic nerve head, bilaterally, and a small hemorrhagic stripe close to the papilla. The chemosis of the anterior segment was completely resolved and the state was described as constant.

Further, through the postoperative course, the patient experienced a sub-segmental embolism of a lung artery and a hospital acquired pneumonia, which he successfully overcame with the appropriate therapy of anticoagulants and anti-infective treatment. By day 20, his general state had improved, he was mobile, could talk and eat on his own, but the visual function did not recover.

After a complete pathological investigation, the tumor was classified as pT2, pN1 (4/60; with extracapsular spread, ECS), R0, L0, V0. We discharged the patient on the 27-th postoperative day. The combined adjuvant therapy was scheduled to start 14 days later with a single dose of 1,8/2,13 Gray (cumulative dose of 54,0/63,9 Gray) and cisplatin.

After completion of the adjuvant therapy the patient was admitted to out standard tumor aftercare program, which is hospital-bases in our outpatient department. The last clinical visit was seven months after the operation, the last CT scan showed possible liver metastases, which are still subject to further diagnosis. Up to date, there is no evidence of tumor recurrence, cervical lymph node metastases or secondary carcinoma.

### 3. Discussion and conclusions

To the best of our knowledge, there have been fifteen reported cases of total blindness as a postoperative complication following a bilateral radical neck dissection in the literature (Table 1). One case was reported in Polish and another in French [14]. The latter was described in two different papers [15,16].

The analyzed cases showed similarities during the overall course of events. In the majority of cases, the bilaterality of the neck dissection was simultaneous. In three of the cases, there was a time-span of 2 months between the first and second neck dissection [17], 1 year [18], and 9 years [19]. All of the publications mention operations with a relatively long duration, ranging from over 6 h to 23 h in the longest case [19], and an extended tumor resection. Similarly, to our case intraoperative hypotension occurred in ten of the fifteen cases. Some of the authors do not indicate any hypotension, but do mention a significant blood loss [11,18,20]. To compensate hypotension and blood loss, an aggressive volume therapy and several units of red blood cells were administered in the majority of cases. There is only one case where the course of the operation and postoperative period were uneventful and no significant volume substitution or blood transfusion was required [21].

Ischemia of the optic nerve was common in almost all of the cases with the exception of the case described by Chutkow where blindness followed hemorrhaging [22]. One patient's case report did not distinguish between posterior ischemic optic neuropathy (PION) and anterior ischemic optic neuropathy (AION) but described an atrophy of the optic nerve as a result of ischemia [17].

Among the cases, there were six cases of PION, being here the most common etiology of blindness. The majority of cases with PION did not present any fundoscopic findings after the first signs of blindness. In one case report a slight papilledema is described [21]. Five cases included in our study diagnosed an AION, which manifested clinically as a marked swelling of the optic disc. In one

case, an occlusion of the central retinal artery was described as the etiological factor, which lead to an ischemia of the nerve as well.

Eight studies employed CT imaging as a diagnostic tool. Only two of them detected the following relevant pathological alterations: hypodensity of the occipital lobe [19], dilation of the periorbital veins and the veins close to the optic nerve. In three other cases, as well as in the case of our patient, the imaging was completed by MR-angiography which did not show any anatomical correlates, or infarctions of the relevant zones that could explain amaurosis.

Further diagnostic means vary. Some of the authors used: a Doppler ultrasonography of the cervical vessels [11,23], visually evoked potentials [19], a lumbar puncture [21,23], a biopsy of the temporal artery to exclude a rheumatic AION as a differential diagnosis [23], or an investigation concerning a microbiological infection [23]. A neurological consultation was requested in three studies [21,23,24].

An ophthalmologist was consulted in every study and a funduscopy was consistently performed on every patient. With the exception of one case of late onset blindness on the 4th postoperative day, the blindness manifested immediately after surgery, as soon as the patient could communicate it.

In most of the cases, no therapy was attempted. Four patients received corticosteroids, however the dosage, the way of administration, and duration of treatment varied. One study mentioned a low molecular-weight heparin, which was administered throughout the entire postoperative period [11]. Balancing fluid supply with diuretics and albumin was also described once [21]. Another study mentions a lateral canthotomy, performed in reaction to an increase in intraocular pressure [25].

Bilateral blindness represents a rare complication following surgery to the neck. To our knowledge up to date there have been fifteen reported cases in the literature following bilateral neck dissection, mostly RND, summarized in Table 1. Even more uncommon is this devastating complication following unilateral RND, as there are six cases described so far.

Etiologically, the specific course of this complication remains unclear. IJV drains blood from facial, lingual, superior, and middle thyroid veins making it the main venous drainage system in the neck. After ligation of one IJV drainage is carried out by the contralateral side and the prevertebral plexus, making also the bilateral scarification of both IJV possible. Nevertheless, the right IJV is dominant in 70% of the population, intracranial pressure rises six times more frequently after ligation of the right IJV, as in our specific case [26]. Most commonly discussed is PION in these cases of blindness following neck dissection. Typically, no specific fundoscopic findings are described upon presentation, as the optic disc appears normal or mildly dilated, intraocular pressure is usually normal or slightly elevated [19,27]. CT scans usually do not reveal any pathology as a cause for cortical blindness [19,25]. However, a multilayered cause seems reasonable, as ischemia because of anemia and/or hypotension together with edema from venous congestion to the acute loss of the internal jugular system can decrease the blood flow to the posterior portion of the optic nerve [8,19,25,27]. Almost all cases are accompanied with long duration of the operation, and intraoperative hypotension and increase blood loss [11,18–20]. Collateral venous systems such as the vertebral plexus, occipital veins, paravertebral veins, emissary veins, ophthalmic veins, posterior jugular veins of the posterior cervical region, pharyngoesophageal plexus, and pterygoid plexus can manage venous drainage from the head and neck after scarifying the IJV. Pathophysiologically, a venous congestion and back pressure from the ophthalmic vein results in ischemia and moreover hypoxia [19]. AION is reported less frequently as a possible cause of blindness following neck dissection. In AION cases an increase of the intraocular pressure without hypotensive events are seen. A severe ischemia to the bulb and anterior portion of the nerve

publication	Case No	Year	op duration	Resection	Timing	intraop. hypotension	Volume	RBC	Diagnostics and findings	Therapy	Outcome	Etiology
Milner	1	1960		comp. Resection RND	2mo	+	nm	5	Fundoscopy pallor optic disc, minor perfusion	-	3rd day blindness	optic atrophy bilat
Torti	2	1964	7h	pharynx/larynx RND	sim	+	nm	7	Intraocular pressure normal Fundoscopy minor perfusion, pale retinae, cherry red maculae Neurologic consult: normal	-	Immediate blindness	CRAO bilat
Chutkow	3	1973		Larynx RND	sim	+	ns	5,5ml	Ns	ns	Immediate blindness	AFH
Balm	4	1990		Laryngectomy RND	sim	-	1500 crystalloids	-	Fundoscopy: slight papillaedema CT: dilated orbital veins and around optic nerve Lumbar puncture: CSF increased Neurologist: normal	Furosemid Dexamethasone Albumin	Immediate blindness	PION bilat
Marks et al	5	1990	13h	pharynx/larynx RND	sim	+	ns	9 units	ns	ns	3rd day blindness	PION bilat
Nawa	5	1992										
Wilson et al	6	1991	13h	Total glossectomy, laryngectomy RND	1yr	-	11 l crystalloids 11 hetastarch 50 ml albumin	4 units	Fundoscopy: pale and edema of optic nerve bilat	Singeshot Dexamthasone 10 mg	Immediate blindness	Non arteriitic AION bilat PION bilat
Bouzaïene et al	7	1994		composite resection RND	sim	+		2 units				
Le Queau et al	7	1995										
Schobel et al	8	1995	12h	composite resection RND	sim	+	nm	12 units	Fundoscopy: nerve atrophy CT, MRI, angiography: no pathology	-	2nd month blindness, 6 mo post: partially recovered	PION bilat
Pazos et al	9	1999	23h	pharynx/larynx	9yr	laryngectomy, RND I	18l	8 units	Fundoscopy normal CT hypodensity of occipital lobe, ventriculomegaly VEP unrecordable	nm	20 pod when awake	PION bilat
Götte	10	2000	6h	SND, MRND larynx	sim	No, but bleeding		-	CT: no infarction Sono carotis MRI and MRI-angiogram Fluorescece angiogram: edema of the optic nerve	Fraxiparine 40 mg Cortison 2 weeks i.v.	Hand moton, late onset	Non areteritic AION bilat
Mamede, RC	11	2001 publ 1998	7h	Lateral ND left MRND right laryngectomy RND	sim	+	3l crystalloid 460 ml plasma	300 ml	Fundoscopy cloudy papilla, edem of the optic disc Doppler: unilateral thrombosis	Nm	Late onset blindness	Non arteriitic AION bilat
Worrell	12	2002	13h	Laryngectomy RND	sim	+	6l	1l	Fundoscopy normal Icrased intraocular pressure CT: normal	Lateral canthotomy bilat.	Immidiata blindness	PION bilat
Obuhowska	13	2010										
Suarez-Fernandez	14	2010	6h	Laryngectomy RND	sim	+(mild)	2500cc crystalloids 1000cc colloids	nm	fundoscopy:swallen optic disc, hämorrhagis Temporal artery biosy Doppler Lumbar puncture Infect. investigation CT: normal MRI:supratentorial lesions Neurological consult	Nm	Staged on set RE light perception LE 20/200	nonarteric AION bilat
Crockett	15	2012		Laryngectomy RND	sim	Bleeding 14pod	nm	nm	Fundoscopyoptic disc swelling, hemorrhagia CT orbta: normal	Oral corticosteroids 10d	Immediate reduced visual acquity bilat., reduced color vision unilat	Non arteritic AION bilat
Present study	16	2020	12h	Partial Pharngetomy Hemimandibleectomz RND unilat MRND contralat	sim	+	12l isotonic electrolyt solution 300 ml albumine	2un	Fundoscopy: edema of the optic nerve head, pale optic disc, hamorrhagia, blurred optic disc margin CT: normal MRI: scattedred infarction of MCA	Fraxiparine perioperative, Cortison i.v. 3 days	4 <sup>th</sup> day, blindness bilat	Non arteritic AION

Abbreviations: RBC: red blood cells; Sim: simultaneous neck dissection; CRAO: central retinal artery occlusion; AFH: amaurosis following hemorrhage; AION: anterior ischemic optic neuropathy; PION: posterior ischemic optic



is precipitated by atherosclerotic changes in the ophthalmic blood system, systemic causes like anemia, or thrombotic emboli and ocular events that lead to increased intraocular pressure [18,19,28].

In AION systemic corticosteroid therapy has been proven to be beneficial [23]. In risk patients undergoing RND, which is to the full extent nowadays a rare procedure, should be identified and special perioperative attention should be paid [23]. This may range from positioning their heads at the level of the heart or higher, maintain a neutral forward head positioning [29], careful use of vasopressors to elevate the blood pressure as they may cause local constriction of small vessels including those supplying the optic nerve [30], and perioperative transfusion should be evaluated carefully [19,23].

Even though postoperative vision loss is a rare and devastating complication, this current case and the review of the literature show that it occurs every once in a while following standard operations to the head and neck. Patients undergoing high-risk procedures should have to be informed that there is a slight risk of perioperative vision loss and this should be highlighted in the standard declaration of consent.

### Declaration of Competing Interest

The authors report no declarations of interest.

### Sources of funding

No funding of the current study exists.

### Ethical approval

The presentation of this specific case has been exempted from ethical approval.

### Consent

Written informed consent was obtained from the patient for publication of this case report and accompanying images. A copy of the written consent is available for review by the Editor-in-Chief of this journal on request.

### Author contribution

AK performed the literature research and wrote the first draft of the manuscript.

KK conceived of the design of the manuscript.

SA performed the analysis of perioperative data.

MH was assigned with proof reading.

SK wrote the final version of the manuscript.

### Registration of research studies

NA.

### Guarantor

Dr. Steffen Koerdt, Charité Berlin, Germany.

### Provenance and peer review

Not commissioned, externally peer-reviewed.

### Open Access

This article is published Open Access at [sciencedirect.com](https://www.sciencedirect.com). It is distributed under the [IJSR Supplemental terms and conditions](https://creativecommons.org/licenses/by/4.0/), which permits unrestricted non commercial use, distribution, and reproduction in any medium, provided the original authors and source are credited.

### Acknowledgements

Not applicable.

### References

- [1] K.D. Wolff, et al., Konsultationsfassung S3-Leitlinie "Diagnostik und Therapie des Mundhöhlenkarzinoms" AWMF-Register-Nummer (007-100OL), Leitlinienprogramm Onkologie der AWMF, Deutschen Krebsgesellschaft e.V. und Deutschen Krebshilfe e.V., Berlin, 2019.
- [2] D.D. Lydiatt, et al., Treatment of stage I and II oral tongue cancer, *Head Neck* 15 (4) (1993) 308–312.
- [3] G.I. Smith, et al., Management of the neck in patients with T1 and T2 cancer in the mouth, *Br. J. Oral Maxillofac. Surg.* 42 (6) (2004) 494–500.
- [4] G. Frohwitter, et al., Evaluation of neck dissection with frozen section biopsy - Management of levels IV and V, *J. Craniomaxillofac. Surg.* 47 (12) (2019) 1963–1967.
- [5] S. Koerdt, et al., Lymph node management in the treatment of oral cancer: analysis of a standardized approach, *J. Craniomaxillofac. Surg.* 44 (10) (2016) 1737–1742.
- [6] O. Aydin, et al., Anterior ischemic optic neuropathy after unilateral radical neck dissection: case report and review, *Auris Nasus Larynx* 35 (2) (2008) 308–312.
- [7] S. Fenton, et al., Ischaemic optic neuropathy following bilateral neck dissection, *J. Laryngol. Otol.* 115 (2) (2001) 158–160.
- [8] Y. Nawa, et al., Bilateral posterior optic neuropathy after bilateral radical neck dissection and hypotension, *Graefes Arch. Clin. Exp. Ophthalmol.* 230 (4) (1992) 301–308.
- [9] O. Ogretmenoglu, S. Kaya, O.F. Unal, Blindness as a rare complication of neck dissection, *Eur. Arch. Otorhinolaryngol.* 254 (9–10) (1997) 478–480.
- [10] S.E. Strome, et al., Anterior ischemic optic neuropathy following neck dissection, *Head Neck* 19 (2) (1997) 148–152.
- [11] K. Gotte, et al., Delayed anterior ischemic optic neuropathy after neck dissection, *Arch. Otolaryngol. Head Neck Surg.* 126 (2) (2000) 220–223.
- [12] M.E. Warner, et al., The frequency of perioperative vision loss, *Anesth. Analg.* 93 (6) (2001) 1417–1421, table of contents.
- [13] R.A. Agha, et al., The SCARE 2018 statement: updating consensus Surgical Case Report (SCARE) guidelines, *Int. J. Surg.* 60 (2018) 132–136.
- [14] I. Obuchowska, Z. Mariak, R. Budrowski, Posterior ischemic optic neuropathy following bilateral radical dissection of cervical lymph nodes, *Klin. Oczna* 112 (1–3) (2010) 63–66.
- [15] M. Bouzaïene, et al., Irreversible bilateral blindness after functional neck dissection. Apropos of a case and a review of the literature, *Rev. Stomatol. Chir. Maxillofac.* 95 (3) (1994) 226–232.
- [16] F. Le Queau, et al., Postoperative blindness after buccal tumorectomy and bilateral radical neck dissection, *Ann. Fr. Anesth. Reanim.* 14 (1) (1995) 37–40.
- [17] G.A. Milner, A case of blindness after bilateral neck dissection, *J. Laryngol. Otol.* 74 (1960) 880–885.
- [18] J.F. Wilson, S.B. Freeman, D.P. Breene, Anterior ischemic optic neuropathy causing blindness in the head and neck surgery patient, *Arch. Otolaryngol. Head Neck Surg.* 117 (11) (1991) 1304–1306.
- [19] G.A. Pazos, et al., Blindness after bilateral neck dissection: case report and review, *Am. J. Otolaryngol.* 20 (5) (1999) 340–345.
- [20] A.J. Crockett, et al., Visual loss following head and neck surgery, *J. Laryngol. Otol.* 126 (4) (2012) 418–420.
- [21] A.J. Balm, et al., Blindness: a potential complication of bilateral neck dissection, *J. Laryngol. Otol.* 104 (2) (1990) 154–156.
- [22] J.G. Chutkow, F.W. Sharbrough, F.C. Riley Jr., Blindness following simultaneous bilateral neck dissection, *Mayo Clin. Proc.* 48 (10) (1973) 713–717.
- [23] M.J. Suarez-Fernandez, et al., Bilateral anterior ischemic optic neuropathy after bilateral neck dissection, *Clin. Ophthalmol.* 4 (2010) 95–100.
- [24] R.A. Torti, A.J. Ballantyne, R.G. Berkeley, Sudden blindness after simultaneous bilateral radical neck dissection, *Arch. Surg.* 88 (1964) 271–274.
- [25] L. Worrell, M. Rowe, G. Petti, Amaurosis: a complication of bilateral radical neck dissection, *Am. J. Otolaryngol.* 23 (1) (2002) 56–59.
- [26] M.G. Hunt, et al., Improvement in papilledema and visual loss after endovascular stent placement in dural sinus thrombosis, *Neuroophthalmology* 26 (2) (2001) 85–92.
- [27] S.C. Marks, et al., Blindness following bilateral radical neck dissection, *Head Neck* 12 (4) (1990) 342–345.
- [28] J.A. Woolgar, et al., Cervical lymph node metastasis in oral cancer: the importance of even microscopic extracapsular spread, *Oral Oncol.* 39 (2) (2003) 130–137.
- [29] N.J. Newman, Perioperative visual loss after nonocular surgeries, *Am. J. Ophthalmol.* 145 (4) (2008) 604–610.
- [30] L.A. Lee, et al., Blindness in the intensive care unit: possible role for vasopressors? *Anesth. Analg.* 100 (1) (2005) 192–195.