

Bilateral absence of musculocutaneous nerve with unusual branching pattern of lateral cord and median nerve of brachial plexus

P. Sharmila Bhanu, K. Devi Sankar

Department of Anatomy, Narayana Medical College, Nellore, Andhra Pradesh, India

Abstract: A 43-year-old female cadaver showed a complete bilateral absence of the musculocutaneous nerve. The anterior compartment muscles of both arms were supplied by median nerve excepting the coracobrachialis which was innervated by a direct branch from the lateral cord of brachial plexus. The median nerve, after supplying the biceps and brachialis muscles, gave onto the lateral cutaneous nerve of the forearm. The median nerve also showed variation on the left side where it was formed by two lateral roots and one medial root. Variations of the brachial plexus are of great interest to anatomists, clinicians and surgeons, in that they may be incorporated in their day to day practice. Our present case may be noted for its clinical and surgical significance in the variations of brachial plexus which can be useful for diagnostic purposes.

Key words: Musculocutaneous nerve, Median nerve, Nerve to coracobrachialis, Variations

Received July 9, 2012; 1st Revised August 22, 2012, 2nd Revised August 24, 2012; Accepted August 27, 2012

Introduction

Variations in the upper limbs, especially in its nerves, vessels and muscles, are common and have been reported by many authors [1-3]. In this regard, variation in the formation of brachial plexus (BP) during its course, branches and distribution is of great interest for all the clinicians. Knowledge of such anatomical variations of BP and its branches in the upper limb is important because these variants could be injured during surgical procedures, producing unusual clinical symptoms.

The median nerve (MN) is formed by the union of lateral and medial roots from lateral and medial cord of BP respectively. It then courses downwards in front of the arm;

crosses the brachial artery from lateral to the medial side and finally enters into forearm by crossing the elbow joint. Usually MN does not branch to the arm muscles except to one of the forearm muscle, pronator teres whose nerve arises from the MN before the MN crosses the elbow [4]. All the anterior arm muscles, coracobrachialis (CB), biceps brachii and brachialis are supplied by musculocutaneous nerve (MCN) branch of lateral cord of BP, and after supplying these muscles, the MCN continues as the lateral cutaneous nerve of forearm (LCNF) to supply the skin of lateral forearm.

The aim of the present study is to report the bilateral absence of MCN and the variant innervation of the front muscles of arm and lateral side of skin of forearm from MN.

Case Report

During routine upper limb dissection for first year medical students, the BP of 43-year-old female cadaver showed the complete absence of MCN and variant branches of MN in the arm of both the upper limbs.

Corresponding author:

P. Sharmila Bhanu
Department of Anatomy, Narayana Medical College, Chinthareddy Palem, Nellore, Andhra Pradesh 524002, India
Tel: +91-9441705457, Fax: +91-861-2317962, E-mail: sharmilabp78@gmail.com

Copyright © 2012. Anatomy & Cell Biology

This is an Open Access article distributed under the terms of the Creative Commons Attribution Non-Commercial License (<http://creativecommons.org/licenses/by-nc/3.0/>) which permits unrestricted non-commercial use, distribution, and reproduction in any medium, provided the original work is properly cited.

Right side

In the right axilla, the lateral cord of BP had three branches i.e. lateral pectoral nerve, nerve to CB and lateral root of MN.

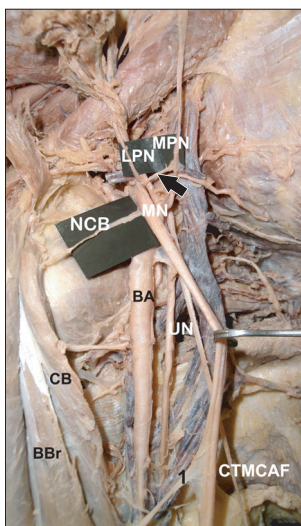


Fig. 1. Photograph of the right axilla showing the absence of musculocutaneous nerve. BA, brachial artery; BBr, biceps brachii muscle; CB, coracobrachialis muscle; CTMCAF, common trunk for medial cutaneous nerve of arm and forearm; LPN, lateral pectoral nerve; MN, median nerve; MPN, medial pectoral nerve; NCB, nerve to coracobrachialis; UN, ulnar nerve; arrow, communication between lateral and medial pectoral nerves; 1, nerve to biceps brachii from MN.

The lateral pectoral nerve pierced the clavipectoral fascia and supplied the pectoralis major as usual but during its course it communicated with the medial pectoral nerve (MPN) of medial cord of BP (Fig. 1). The MCN was completely absent. The nerve to the CB was a small motor twig arising directly from the lateral cord which innervated the CB muscle. The lateral and medial root of MN formed the MN proper and descended between the biceps brachii and brachialis muscle. It then crossed the brachial artery from lateral to medial and finally entered the cubital fossa. In the arm, deep in the biceps brachii, the MN gave two branches: a direct branch to the biceps brachii and another long branch which, after supplying the brachialis muscle, continued as the LCNF and supplied the lateral side of the skin of forearm. The medial cord also varied in the origin of medial cutaneous nerve of arm and forearm arising from a single common trunk, which became separated in the middle of the arm (Fig. 2).

Left side

The lateral cord of BP in the left axilla branched four times: the lateral pectoral nerve; nerve to CB and lateral root of MN and an additional lateral root of MN. The MCN was absent and the nerve to CB was a small twig which supplied and terminated in the muscle itself (Fig. 3). No communication between lateral and MPNs was found.

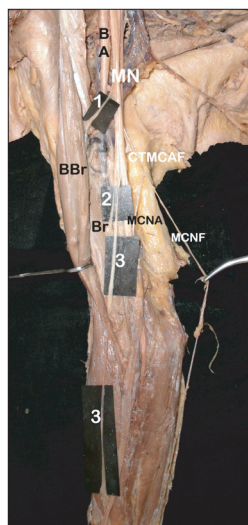


Fig. 2. Photograph showing the variant branches of median nerve on the right side. BA, brachial artery; BBr, biceps brachii; Br, brachialis; CTMCAF, common trunk for medial cutaneous nerve of arm and forearm from medial cord; MCNA, medial cutaneous nerve of arm; MCNF, medial cutaneous nerve of forearm; MN, median nerve; 1, nerve to biceps brachii from MN; 2, branch to brachialis from common trunk of MN; 3, lateral cutaneous nerve of forearm from common trunk of MN.

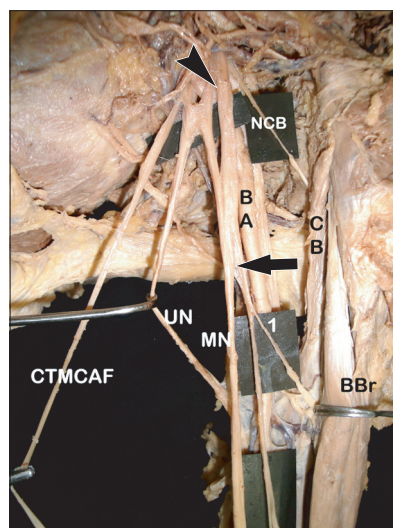


Fig. 3. Photograph of the left axilla showing the absence of musculocutaneous nerve. BA, brachial artery; BBr, biceps brachii muscle; CB, coracobrachialis; CTMCAF, common trunk for medial cutaneous nerve of arm and forearm; MN, median nerve; NCB, nerve to coracobrachialis; UN, ulnar nerve; arrow, single long trunk from MN; arrowhead, additional lateral root of MN from lateral cord; 1, nerve to biceps brachii from the single long trunk of MN.

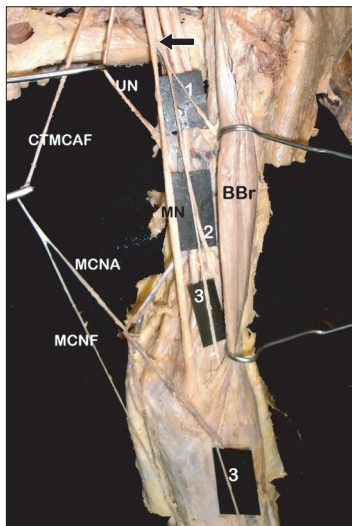


Fig. 4. Photograph showing the variant branches of median nerve on the left side. BBr, biceps brachii; CTMCAF, common trunk for medial cutaneous nerve of arm and forearm from medial cord; MCNA, medial cutaneous nerve of arm; MCNF, medial cutaneous nerve of forearm; MN, median nerve; UN, ulnar nerve; arrow, single long trunk from MN; 1, nerve to biceps brachii; 2, branch to brachialis; 3, lateral cutaneous nerve of forearm.

The MN was formed by two lateral roots from the lateral cord and one from medial root from the medial cord. After the formation, the left MN had the same course as the right side. During its course between the biceps brachii and brachialis, the MN split off a single long branch from which branches to the biceps brachii and brachialis were derived. After supplying these two muscles it continued as LCNF, which supplied the lateral side of the skin of forearm. The medial cutaneous nerve of arm and forearm arose from a common trunk, and separated in the middle of the arm, similarly to the right side (Fig. 4).

Discussion

Anatomical variations of the BP have been reported by several authors. The MCN and the MN are the two major nerves which have numerous variations in their formation and branching patterns. The MCN is one of the three terminal branches of lateral cord of the BP which after piercing the CB, innervates the musculatures of anterior compartment of arm and continues as LCNF [4].

Variations of the MN and absence of the MCN have been extensively studied by many authors [1, 5-7]. Variations in the formation, distribution and termination of the MCN have been described by Bergman et al. [8] who reported that 90%

of the MCN arises from the lateral cord while in 2% of the cases it may arise from the MN or may be completely absent. Le Minor [6] and Gümüşburun and Adigüzel [7] classified five types of variation, with the 5th type being the complete absence of MCN, where anterior arm muscles will be supplied by the MN. Similar cases of the absence of the MCN and the unusual branches of the MN have been reported in literature [3, 6]. Usually if the MCN is absent, the fibers of the MCN are en-routed through the lateral root of MN which takes the role of the MCN in supplying all the anterior arm muscles and lateral side of the skin of forearm [6]. Our present case had complete absence of the MCN coinciding Le Minor's [6] and Gümüşburun and Adigüzel's [7] 5th type of classification, but the innervation of the anterior compartment of arm muscles were unique in that none of the muscles were supplied by the MN. Only the branches to biceps brachii and brachialis were derived from the MN through its lateral root and the nerve to the CB arose directly from the lateral cord of the BP. However direct branches to the CB from the lateral cord [9] and the lateral root of the MN [10] are also been reported in addition to the presence of the MCN.

On the left side we found a variation in the formation of the MN with an additional lateral root which ran downwards, medially and joined the lower part of the medial root of the MN. Cases of MN formation with additional roots have been reported by several authors [3, 11, 12]. The additional lateral root with the absence of the MCN has been reported. This unusual root was found in our case, crossing the third part of axillary artery, and it may convey the fibers of the MCN but at the same time there is a risk of compression of the artery, lessening the blood supply to the left upper limb [11].

Anomalous communications in the branches of BP, like communication between medial and lateral pectoral nerve, median and ulnar nerve, medial root of MN and additional lateral root of MN have been reported in the literature [3]. The present case illustrates communication between medial and lateral pectoral nerve on the right upper limb. No communication was found between medial cutaneous nerve of the arm and forearm; instead both the nerves arose from a single common trunk which separated in the middle of the arm.

The present study can be incorporated with recapitulation of evolutionary aspects because in lower vertebrates like amphibians, reptiles and birds there is only one trunk equivalent to the MN in the thoracic limb. The absence of MCN and the innervation of the anterior arm muscles by MN may

also be interpreted on the developmental basis of the upper limb muscles. The upper limb muscles in man develop from the mesenchyme of paraxial mesoderm while the axons of spinal nerve supplying it grow distally to reach the muscles and skin of upper limb bud [3, 13]. Any variation in the co-ordination of muscle development and its neuronal signalling results in the anomalies of the upper limb musculature and its innervation.

In summary, this paper is to report the absence of the MCN, nerve to CB and innervation pattern of MN in the arm might be of significance in diagnostic clinical neurology. Knowledge of such variations of the BP as found in our study may provide additional anatomical information for the clinicians during diagnosis of unusual clinical symptoms and for surgeons to avoid damage to these nerves, during surgical exploration of axilla and arm region, shoulder reconstructive surgeries and anterior surgical approaches of the upper limb.

References

1. Sud M. Absence of the musculocutaneous nerve and the innervation of coracobrachialis, biceps brachii and brachialis from the median nerve. *J Anat Soc India* 2000;49:176-77.
2. Catli MM, Ozsoy U, Kaya Y, Hizay A, Yildirim FB, Sarikcioglu L. Four-headed biceps brachii, three-headed coracobrachialis muscles associated with arterial and nervous anomalies in the upper limb. *Anat Cell Biol* 2012;45:136-9.
3. Gupta M, Goyal N, Harjeet. Anomalous communications in the branches of brachial plexus. *J Anat Soc India* 2005;54:22-5.
4. Williams PL, Bannister LH, Berry MM, Collins P, Dyson M, Dussek JE, Ferguson MW. Nervous system. In: Gray H, Williams PL, Bannister LH, editors. *Gray's Anatomy: The Anatomical Basis of Medicine and Surgery*. 38th ed. New York: Churchill Livingstone; 1995. p.1266-72.
5. Aydin ME, Kale A, Edizer M, Kopuz C, Demir MT, Corumlu U. Absence of the musculocutaneous nerve together with unusual innervation of the median nerve. *Folia Morphol (Warsz)* 2006;65:228-31.
6. Le Minor JM. A rare variation of the median and musculocutaneous nerves in man. *Arch Anat Histol Embryol* 1990;73:33-42.
7. Gümüşburun E, Adigüzel E. A variation of the brachial plexus characterized by the absence of the musculocutaneous nerve: a case report. *Surg Radiol Anat* 2000;22:63-5.
8. Bergman RA, Thompson SA, Afifi AK, Saadeh FA. *Compendium of human anatomic variation: catalogue, atlas, and world literature*. Baltimore, Munich: Urban and Schwarzenberg; 1988. p.139-43.
9. Singhal S, Rao VV, Ravindranath R. Variations in brachial plexus and the relationship of median nerve with the axillary artery: a case report. *J Brachial Plex Peripher Nerve Inj* 2007;2:21.
10. Tatar I, Brohi R, Sen F, Tonak A, Celik H. Innervation of the coracobrachialis muscle by a branch from the lateral root of the median nerve. *Folia Morphol (Warsz)* 2004;63:503-6.
11. Sargon MF, Uslu SS, Celik HH, Akşit D. A variation of the median nerve at the level of brachial plexus. *Bull Assoc Anat (Nancy)* 1995;79:25-6.
12. Das S, Paul S. Anomalous branching pattern of lateral cord of brachial plexus. *Int J Morphol* 2005;23:289-92.
13. Arey LB. *Developmental anatomy: a textbook and laboratory manual of embryology*. 7th ed. London: W.B. Saunders Co. Philadelphia; 1966. p.501-4.