

# Odontogenic tumors: A review of 93 cases in the Vidharba region of Maharashtra

Preethi Narendra Sharma, Rajul Kamalkishore Ranka, Minal Shashi Chaudhary, Madhuri Nitin Gawande, Alka Harish Hande, Prajakta Fande Zade

Department of Oral Pathology and Microbiology, Sharad Pawar Dental College and Hospital, DMIMS (Deemed to be University), Sawangi (Meghe), Wardha, Maharashtra, India

## Abstract

**Background:** Tumors of the odontogenic origin (OTs) are rare tumors accounting for 1% of all the jaw tumors in the oral cavity. The behavior of these tumors ranges from hamartomatous proliferation to malignant neoplasm.

**Aim:** The aim of this study was to determine the epidemiological data, clinical and histopathological picture with variants of the OTs diagnosed at our institute in the Vidarbha region.

**Settings and Design:** A retrospective study was carried out with the permission from the institutional authorities. The archival records of the Department of Oral Pathology and Microbiology were reviewed.

**Materials and Methods:** A total of 93 cases of OTs were reviewed retrospectively from the archival records of the Department of Oral Pathology and Microbiology from January 2008 to December 2018. Statistical analysis was carried out and the determination of the age, gender, jaw, site, diagnosis, variants and year-wise distribution of odontogenic lesions was taken out using the SPSS software.

**Results:** Ninety-three cases of OTs were identified. The most common OT identified was ameloblastoma ( $n = 37/39.7\%$ ) followed by keratocystic OT ( $n = 8/8.6\%$ ), adenomatoid OT ( $n = 7/7.5\%$ ) and odontome (O) ( $n = 6/6.4\%$ ). The tumors were diagnosed in a wide age range from 1<sup>st</sup> to 3<sup>rd</sup> decennium of life. The mandibular posterior region was the most commonly affected anatomical site with the maxilla and mandible ratio of 1:6.

**Conclusion:** OTs were found to be rare in the sample studied. The findings of the study were in concordance to those of Asian and African series. Variations were shown from the series of American reports, and further investigations are needed for this disparity.

**Keywords:** Ameloblastoma, epidemiology, keratocystic, odontogenic, tumor

**Address for correspondence:** Dr. Preethi Narendra Sharma, Room No-105, Department of Oral Pathology and Microbiology, Sharad Pawar Dental College and Hospital, Sawangi (Meghe), Wardha, Maharashtra, India.  
E-mail: dr.preethisharma@gmail.com

**Submitted:** 03-May-2019, **Revised:** 07-Sep-2019, **Accepted:** 24-Sep-2019, **Published:** 08-May-2020

## INTRODUCTION

Tumors of odontogenic origin (OTs) found in the maxillofacial region are uncommon group of tumors exhibiting heterogeneous behavior ranging from hamartomatous proliferation to malignant neoplasms

with the potential of metastasis.<sup>[1,2]</sup> The OTs originates from epithelial and/or mesenchymal component of the tissue surrounding the teeth. The OTs are seen intraosseously in the jaw bones or extraosseously in the alveolar mucosa of the tooth-bearing apparatus.<sup>[3,4]</sup>

This is an open access journal, and articles are distributed under the terms of the Creative Commons Attribution-NonCommercial-ShareAlike 4.0 License, which allows others to remix, tweak, and build upon the work non-commercially, as long as appropriate credit is given and the new creations are licensed under the identical terms.

**For reprints contact:** reprints@medknow.com

**How to cite this article:** Sharma PN, Ranka RK, Chaudhary MS, Gawande MN, Hande AH, Zade PF. Odontogenic tumors: A review of 93 cases in the Vidharba region of Maharashtra. J Oral Maxillofac Pathol 2020;24:185.

### Access this article online

#### Quick Response Code:



#### Website:

www.jomfp.in

#### DOI:

10.4103/jomfp.JOMFP\_145\_19

It represents 1% of all the tumors of the jaw. The differences in the relative frequencies of these tumors is shown in the literature.<sup>[3,5]</sup>

Similar to the process of normal odontogenesis, OTs are capable of undergoing inductive mechanism where in interactions between odontogenic epithelium and ectomesenchyme takes place. Hence, the classification of OTs is introduced based on this mechanism. In 1971, the “histological typing of OTs” was first published by the World Health Organization (WHO).<sup>[6]</sup> The first edition was revised and the second edition was published in the year 1992.<sup>[7]</sup> In this classification, calcifying odontogenic cyst was included under OT. The third edition was published in 2005 where odontogenic keratocyst was reclassified as keratocystic OT (KCOT) with increased prevalence and distribution of OTs.<sup>[3]</sup> The fourth edition was published in 2017 to simplify the terminologies and classification reflecting their proper biological behavior. It included main differences from the 3<sup>rd</sup> edition (2005) introducing a new classification of odontogenic cysts, “reclassified” as OTs, and some new entities.<sup>[8]</sup>

The frequency of OTs occurring in different ethnic groups from different geographical areas of the world have been documented. The frequency of these lesions is seen occurring mostly among Americans and Africans according to the available literature. Many epidemiological studies have been reported on OTs from different parts of the world, but the studies reported from the Indian subcontinent are very few. Epidemiological studies help in assessing the concern for the disease, health-care planning and estimating the quantum for reducing the disease stress. Hence, this study was performed to determine the epidemiological data, clinical and histopathological picture of the OTs diagnosed at our institute over the period of January 2008 to December 2018 with comparison of these data to the previous reports.

**MATERIALS AND METHODS**

A retrospective study was carried out with the permission from the institutional authorities. The archival records of the Department of Oral Pathology and Microbiology were reviewed retrospectively for all the OTs occurring in the oral cavity from January 2008 to December 2018. The study variables were age, gender, jaw, site and histopathologic features with variants of OTs. The histopathological diagnosis was made according to the 2005 WHO classification of OTs.

Statistical analysis was carried out and determination of the age, gender, jaw, site, diagnosis, variants and year-wise distribution of odontogenic lesions was taken out.

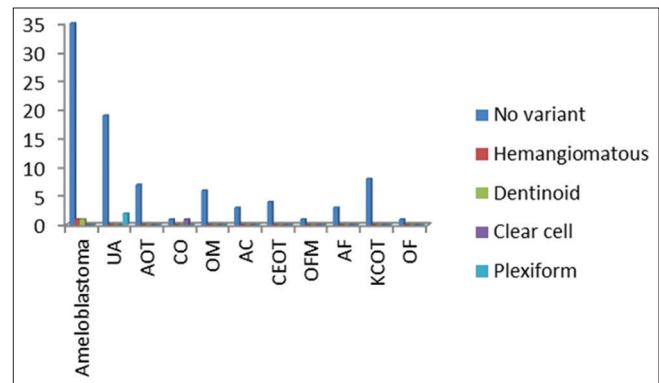
**RESULTS**

According to the retrospective study, the age distribution showed a peak occurrence of the OT in the 1<sup>st</sup>–3<sup>rd</sup> decennium of life. The type of lesions encountered is shown in the tabular form [Table 1 and Graph 1]. The most common OT diagnosed was ameloblastoma with 27% of cases occurring in the 2<sup>nd</sup>–3<sup>rd</sup> decennium of life and 18.9% in the 3<sup>rd</sup>–4<sup>th</sup> decennium of life [Table 2 and Graph 2]. Unicystic ameloblastoma (UA) which is a rare type of ameloblastoma was mostly seen in the 1<sup>st</sup>–2<sup>nd</sup> decennium of life [Table 2]. The second-most common OT was KCOT showing equal percentage of cases, i.e., 37.5% in both 1<sup>st</sup>–2<sup>nd</sup> and 2<sup>nd</sup>–3<sup>rd</sup> decennium [Table 2]. Adenomatoid OT (AOT) was the third-most common tumor showing 85.7% of cases occurring in the 1<sup>st</sup>–2<sup>nd</sup> decade [Table 2]. Odontome (O) was the fifth-most common tumor showing equal percentage, i.e., 33.3% of cases in the 1<sup>st</sup>–2<sup>nd</sup> and 4<sup>th</sup>–5<sup>th</sup> decennium [Table 2]. Among 93 OTs, 47 cases were seen in males and 46 cases in females, with a ratio of 1:1 [Table 3 and Graph 3]. All the cases diagnosed were benign except 4 cases

**Table 1: Type of lesions encountered**

Diagnosis	Number of lesions diagnosed	Variants
Ameloblastoma	37	Hemangiomatous-1 Dentinoid-1
UA	21	Plexiform-2
AOT	7	-
CEOT	2	Clear cell-1
CO	6	-
OM	3	-
AC	4	-
OFM	1	-
OF	3	-
KCOT	8	-
AF	1	-
Total	93	-

UA: Unicystic ameloblastoma, AOT: Adenomatoid odontogenic tumor, CEOT: Calcifying epithelial odontogenic tumor, OM: Odontogenic myxoma, AC: Ameloblastic carcinoma, KCOT: Keratocystic Odontogenic tumor, AF: Ameloblastic fibroma, OF: Odontogenic fibro, OFM: Odontogenic fibromyxoma, CO: Compound Odontome

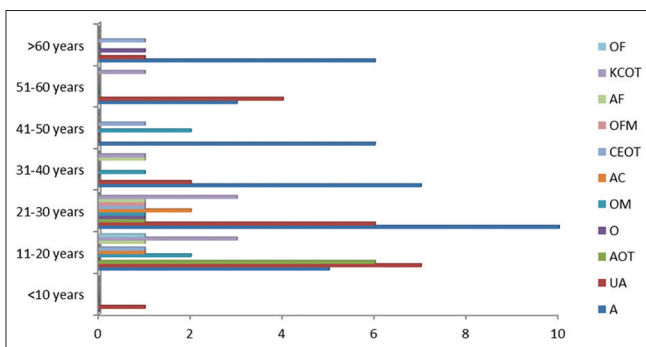


**Graph 1: Various lesions encountered**

**Table 2: Age-wise distribution of odontogenic tumours**

Diagnosis	Years							Total (%)
	≤10 (%)	11-20 (%)	21-30 (%)	31-40 (%)	41-50 (%)	51-60 (%)	>60 (%)	
Ameloblastoma	0 (0.0)	5 (13.5)	10 (27.0)	7 (18.9)	6 (16.2)	3 (8.1)	6 (16.2)	37 (100.0)
UA	1 (4.8)	7 (33.3)	6 (28.6)	2 (9.5)	0 (0.0)	4 (19.0)	1 (4.8)	21 (100.0)
AOT	0 (0.0)	6 (85.7)	1 (14.3)	0 (0.0)	0 (0.0)	0 (0.0)	0 (0.0)	7 (100.0)
CEOT	0 (0.0)	0 (0.0)	1 (50.0)	0 (0.0)	0 (0.0)	0 (0.0)	1 (50.0)	2 (100.0)
O	0 (0.0)	2 (33.3)	1 (16.7)	1 (16.7)	2 (33.3)	0 (0.0)	0 (0.0)	6 (100.0)
OM	0 (0.0)	1 (33.3)	2 (66.7)	0 (0.0)	0 (0.0)	0 (0.0)	0 (0.0)	3 (100.0)
AC	0 (0.0)	1 (25.0)	1 (25.0)	0 (0.0)	1 (25.0)	0 (0.0)	1 (25.0)	4 (100.0)
OFM	0 (0.0)	0 (0.0)	1 (100.0)	0 (0.0)	0 (0.0)	0 (0.0)	0 (0.0)	1 (100.0)
OF	0 (0.0)	1 (33.3)	133.3	1 (33.3)	0 (0.0)	0 (0.0)	0 (0.0)	3 (100.0)
KCOT	0 (0.0)	3 (37.5)	3 (37.5)	1 (12.5)	0 (0.0)	1 (12.5)	0 (0.0)	8 (100.0)
AF	0 (0.0)	1 (100.0)	0 (0.0)	0 (0.0)	0 (0.0)	0 (0.0)	0 (0.0)	1 (100.0)
Total	1 (1.1)	27 (29.0)	27 (29.0)	12 (12.9)	9 (9.7)	8 (8.6)	9 (9.7)	93 (100.0)

UA: Unicystic ameloblastoma, AOT: Adenomatoid odontogenic tumor, CEOT: Calcifying epithelial odontogenic tumor, OM: Odontogenic myxoma, AC: Ameloblastic carcinoma, KCOT: Keratocystic Odontogenic tumor, AF: Ameloblastic fibroma, OF: Odontogenic fibro, OFM: Odontogenic fibromyxoma, O: Odontome

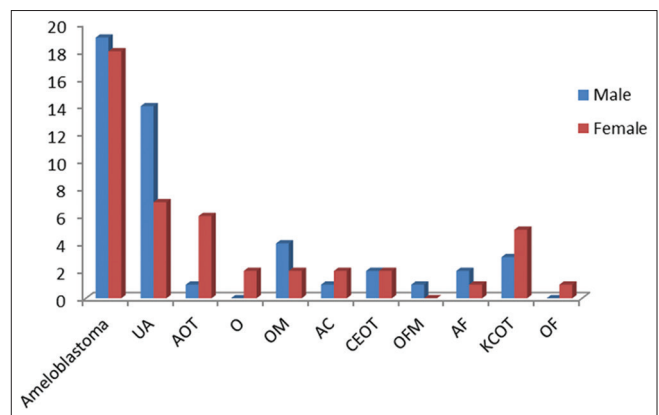


**Graph 2: Age-wise distribution of odontogenic tumours**

diagnosed with ameloblastic carcinoma. According to the study, 80 cases of OTs affected the mandible and 13 cases affected maxilla, with an overall mandible: Maxilla ratio of 1:6 [Table 4 and Graph 4]. The mandible was most commonly affected jaw by OTs. KCOT showed high predilection with 100% occurrence in the mandibular posterior region [Table 5 and Graph 5]. This was followed by UA affecting the mandible with 95.2% (posterior region 90.5%) and ameloblastoma with 91.9% (posterior region 86.5%) [Table 5]. AOT showed high predilection for maxilla with 57.1% (anterior region 100%) [Table 5]. O equally affected both the maxilla and the mandible with 50% (50% anterior and 50% posterior region) [Tables 4 and 5].

**DISCUSSION**

Ameloblastoma was the most common OT diagnosed in this study with 39.7% and is similar to other studies from Asian<sup>[9,10]</sup> and African<sup>[11,12]</sup> countries. The ameloblastomas mostly affect angle and ramus region of the mandible. There are three forms of ameloblastomas, namely multicystic (solid), peripheral and unicystic type. The UA which is a rare form of ameloblastoma accounts for 22.5% and is mostly seen in the 1–2 decennium.

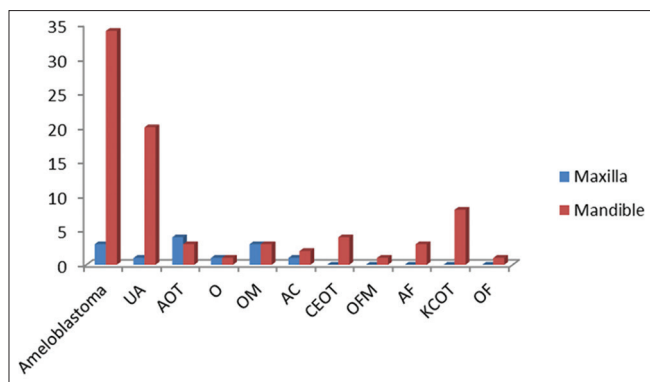


**Graph 3: Gender-wise distribution of odontogenic tumors**

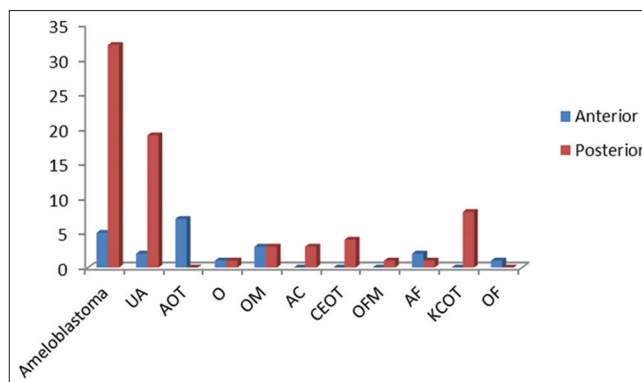
The prevalence of OTs has increased after the inclusion of the odontogenic keratocyst in 2005 WHO classification as KCOT. In this study, KCOT was the second most commonly occurring OT with 8.6%. The most common OT presented in the studies from the American countries was O followed by ameloblastoma.<sup>[13,14]</sup> In this study, odontoma is in the fourth position following ameloblastoma and KCOT, with a frequency of 6.4%. The reason behind may be the lack of routine dental checkup with radiographs in the Asian and African population. These tumors are unnoticed for years, and after surgical removal probably the specimen is not sent for histopathological examination.

AOT showed a frequency of 7.5% which is similar to studies from China.<sup>[10,15]</sup> AOT showed a higher frequency of 9% in the epidemiological studies from other parts of India.<sup>[16]</sup> To prove whether a racial difference exists, follow-up studies are required for the occurrence of different types of OTs in a given population.

Odontogenic myxoma (OM) showed a frequency of 3.2% in this study. The value is lower compared to previous studies.



**Graph 4:** Distribution of odontogenic tumors according to the jaw affected



**Graph 5:** Distribution of odontogenic tumors according to the site involved

**Table 3: Gender-wise distribution of odontogenic tumors**

Diagnosis	Gender		Total (%)
	Male (%)	Female (%)	
Ameloblastoma	19 (51.4)	18 (48.6)	37 (100.0)
UA	14 (66.7)	7 (33.3)	21 (100.0)
AOT	1 (14.3)	6 (85.7)	7 (100.0)
CEOT	0 (0.0)	2 (100.0)	2 (100.0)
CO	4 (66.7)	2 (33.3)	6 (100.0)
OM	1 (33.3)	2 (66.7)	3 (100.0)
AC	2 (50.0)	2 (50.0)	4 (100.0)
OFM	1 (100.0)	0 (0.0)	1 (100.0)
OF	2 (66.7)	1 (33.3)	3 (100.0)
KCOT	3 (37.5)	5 (62.5)	8 (100.0)
AF	0 (0.0)	1 (100.0)	1 (100.0)
Total	47 (50.5)	46 (49.5)	93 (100.0)

UA: Unicystic ameloblastoma, AOT: Adenomatoid odontogenic tumor, CEOT: Calcifying epithelial odontogenic tumor, OM: Odontogenic myxoma, AC: Ameloblastic carcinoma, KCOT: Keratocystic Odontogenic tumor, AF: Ameloblastic fibroma, OF: Odontogenic fibro, OFM: Odontogenic fibromyxoma, CO: Compound Odontome

**Table 4: Distribution of odontogenic tumors according to the jaw affected**

Diagnosis	Jaw		Total (%)
	Maxilla (%)	Mandible (%)	
Ameloblastoma	3 (8.1)	34 (91.9)	37 (100.0)
UA	1 (4.8)	20 (95.2)	21 (100.0)
AOT	4 (57.1)	3 (42.9)	7 (100.0)
CEOT	1 (50.0)	1 (50.0)	2 (100.0)
CO	3 (50.0)	3 (50.0)	6 (100.0)
OM	1 (33.3)	2 (66.7)	3 (100.0)
AC	0 (0.0)	4 (100.0)	4 (100.0)
OFM	0 (0.0)	1 (100.0)	1 (100.0)
OF	0 (0.0)	3 (100.0)	3 (100.0)
KCOT	0 (0.0)	8 (100.0)	8 (100.0)
AF	0 (0.0)	1 (100.0)	1 (100.0)
Total	13 (14.0)	80 (86.0)	93 (100.0)

UA: Unicystic ameloblastoma, AOT: Adenomatoid odontogenic tumor, CEOT: Calcifying epithelial odontogenic tumor, OM: Odontogenic myxoma, AC: Ameloblastic carcinoma, KCOT: Keratocystic Odontogenic tumor, AF: Ameloblastic fibroma, OF: Odontogenic fibro, OFM: Odontogenic fibromyxoma, CO: Compound Odontome

OM showed a frequency of 6.5–17.7% according to the retrospective studies from Brazil,<sup>[9]</sup> Nigeria,<sup>[17]</sup> and Mexico.<sup>[18]</sup> The frequency range of OM in China<sup>[10]</sup> and Sri Lanka<sup>[19]</sup> was in the range of 2.6%–4.9%. Higher frequency of OM was

also shown from other Indian studies.<sup>[16]</sup> The low incidence of OM needs further investigation.

According to the study, the incidence of OTs was mostly seen in the 1<sup>st</sup>–3<sup>rd</sup> decades of life and is similar to other studies from India<sup>[5]</sup> and Nigeria<sup>[17]</sup> China.<sup>[15]</sup> The mean age less than a decade was shown from studies of Brazil<sup>[11]</sup> and Chile.<sup>[13]</sup> There could be a racial difference in incidence or may be odontoma was the most common OT in those populations.

OTs showed a slight male predilection (ratio) in this study and is similar to studies from India,<sup>[5]</sup> Australia,<sup>[20]</sup> China.<sup>[10,15]</sup> Male-to-female ratio of 1:1 was shown by ameloblastoma. This is similar from studies in India,<sup>[5]</sup> Nigeria<sup>[17]</sup> and China.<sup>[10]</sup> However, female predilection was shown from a Brazilian study.<sup>[9]</sup> KCOT also showed a predilection for males which is in concordance with many other studies<sup>[10,21]</sup> but is not similar to a Brazilian study.<sup>[9]</sup> The difference is possibly disclosed among different populations.

The jaw most commonly affected was mandible with maxilla to mandible ratio of 1:6. This is in concordance with studies from Asia<sup>[10,16]</sup> and Africa.<sup>[17]</sup> However, the predilection for both the jaws was shown to be equal from the studies of the American continent.<sup>[13,18,22]</sup> The reason could be the lower frequency of ameloblastoma in that particular population.

In this study, different variants of ameloblastoma and calcifying epithelial OT (CEOT) were found. Ameloblastoma like tissue with unusual formation of dentinoid material was diagnosed in one of the cases. Dentinoameloblastoma (DA) is an unusual OT characterized by classic ameloblast like areas with unusual formation of dentinoid by neoplastic epithelial cells of odontogenic origin. The World Health Organization first defined the term DA in 1970.<sup>[23]</sup>



**Table 5: Distribution of odontogenic tumors according to the site involved**

Diagnosis	Site		Total (%)
	Anterior (%)	Posterior (%)	
Ameloblastoma	5 (13.5)	32 (86.5)	37 (100.0)
UA	2 (9.5)	19 (90.5)	21 (100.0)
AOT	7 (100.0)	0 (0.0)	7 (100.0)
CEOT	1 (50.0)	1 (50.0)	2 (100.0)
CO	3 (50.0)	3 (50.0)	6 (100.0)
OM	0 (0.0)	3 (100.0)	3 (100.0)
AC	0 (0.0)	4 (100.0)	4 (100.0)
OFM	0 (0.0)	1 (100.0)	1 (100.0)
OF	2 (66.7)	1 (33.3)	3 (100.0)
KCOT	0 (0.0)	8 (100.0)	8 (100.0)
AF	1 (100.0)	0 (0.0)	1 (100.0)
Total	21 (22.6)	72 (77.4)	93 (100.0)

UA: Unicystic ameloblastoma, AOT: Adenomatoid odontogenic tumor, CEOT: Calcifying epithelial odontogenic tumor, OM: Odontogenic myxoma, AC: Ameloblastic carcinoma, KCOT: Keratocystic Odontogenic tumor, AF: Ameloblastic fibroma, OF: Odontogenic fibro, OFM: Odontogenic fibromyxoma, CO: Compound Odontome

The variant of CEOT with clear cells was diagnosed in one of the cases. The first case of CEOT was described by Abrams and Howell in 1967 predominantly composed of clear cells.<sup>[24]</sup> Krolls and Pindborg considered two of those 23 cases of CEOT as a challenge in diagnosis due to predominance of clear cells. Since then, the clear-cell component in CEOTs has been reported mainly through single cases and its prognostic importance is still debatable.<sup>[24-31]</sup>

## CONCLUSION

OTs are rare group of lesions in the population studied and are represented mainly by the Ameloblastoma, KCOT, AOT and O. The clinical and histopathologic features of these neoplasms differentiates it from other oral lesions. OTs exhibits a male preponderance, and most cases are diagnosed in the 1<sup>st</sup>–3<sup>rd</sup> decades of life. Possible geographic variation of OTs was observed from the cases reviewed.

## Financial support and sponsorship

Nil.

## Conflicts of interest

There are no conflicts of interest.

## REFERENCES

- Philipsen HP, Reichart PA. Revision of the 1992-edition of the WHO histological typing of odontogenic tumours. A suggestion. *J Oral Pathol Med* 2002;31:253-8.
- Mosqueda-Taylor A. New findings and controversies in odontogenic tumors. *Med Oral Patol Oral Cir Bucal* 2008;13:E555-8.
- Barnes L, Eveson JW, Reichart P, Sidransky D, editors. World Health Organization classification of tumours. In: Pathology and Genetics of Head and Neck Tumours. Lyon: IARC Publishing Group; 2005.
- Buchner A, Merrell PW, Carpenter WM. Relative frequency of central odontogenic tumors: A study of 1,088 cases from Northern California and comparison to studies from other parts of the world. *J Oral Maxillofac Surg* 2006;64:1343-52.
- Sriram G, Shetty RP. Odontogenic tumors: A study of 250 cases in an Indian teaching hospital. *Oral Surg Oral Med Oral Radiol Endod* 2008;105:e14-21.
- Pindborg J, Kramer I, Torloni H. Histological Typing of Odontogenic Tumors, Jaw Cysts, and Allied Lesions. Geneva, Switzerland: World Health Organization; 1971.
- Kramer I, Pindborg J, Shear M. Histological Typing of Odontogenic Tumors, World Health Organization. 2<sup>nd</sup> ed. Berlin: Springer-Verlag; 1992.
- Suluk-Tekkeşin M, Wright JM. The world health organization classification of odontogenic lesions: A Summary of the changes of the 2017 (4<sup>th</sup>) edition. *Turk Patoloji Derg* 2018;34:1-18.
- Osterne RL, Brito RG, Alves AP, Cavalcante RB, Sousa FB. Odontogenic tumors: A 5-year retrospective study in a Brazilian population and analysis of 3406 cases reported in the literature. *Oral Surg Oral Med Oral Pathol Oral Radiol Endod* 2011;111:474-81.
- Luo HY, Li TJ. Odontogenic tumors: A study of 1309 cases in a Chinese population. *Oral Oncol* 2009;45:706-11.
- Fernandes AM, Duarte EC, Pimenta FJ, Souza LN, Santos VR, Mesquita RA, et al. Odontogenic tumors: A study of 340 cases in a Brazilian population. *J Oral Pathol Med* 2005;34:583-7.
- Santos JN, Pinto LP, de Figueredo CR, de Souza LB. Odontogenic tumors: Analysis of 127 cases. *Pesqui Odontol Bras* 2001;15:308-13.
- Ochsenius G, Ortega A, Godoy L, Peñafiel C, Escobar E. Odontogenic tumors in Chile: A study of 362 cases. *J Oral Pathol Med* 2002;31:415-20.
- Daley TD, Wysocki GP, Pringle GA. Relative incidence of odontogenic tumors and oral and jaw cysts in a Canadian population. *Oral Surg Oral Med Oral Pathol* 1994;77:276-80.
- Jing W, Xuan M, Lin Y, Wu L, Liu L, Zheng X, et al. Odontogenic tumours: A retrospective study of 1642 cases in a Chinese population. *Int J Oral Maxillofac Surg* 2007;36:20-5.
- Gupta B, Ponniah I. The pattern of odontogenic tumors in a government teaching hospital in the Southern Indian state of Tamil Nadu. *Oral Surg Oral Med Oral Pathol Oral Radiol Endod* 2010;110:e32-9.
- Ladeinde AL, Ajayi OF, Ogunlewe MO, Adeyemo WL, Arotiba GT, Bamgbose BO, et al. Odontogenic tumors: A review of 319 cases in a Nigerian teaching hospital. *Oral Surg Oral Med Oral Pathol Oral Radiol Endod* 2005;99:191-5.
- Mosqueda-Taylor A, Ledesma-Montes C, Caballero-Sandoval S, Portilla-Robertson J, Ruiz-Godoy Rivera LM, Meneses-García A. Odontogenic tumors in Mexico: A collaborative retrospective study of 349 cases. *Oral Surg Oral Med Oral Pathol Oral Radiol Endod* 1997;84:672-5.
- Okada H, Yamamoto H, Tilakaratne WM. Odontogenic tumors in Sri Lanka: Analysis of 226 cases. *J Oral Maxillofac Surg* 2007;65:875-82.
- Johnson NR, Savage NW, Kazoullis S, Batstone MD. A prospective epidemiological study for odontogenic and non-odontogenic lesions of the maxilla and mandible in Queensland. *Oral Surg Oral Med Oral Pathol Oral Radiol* 2013;115:515-22.
- Boffano P, Ruga E, Gallesio C. Keratocystic odontogenic tumor (odontogenic keratocyst): Preliminary retrospective review of epidemiologic, clinical, and radiologic features of 261 lesions from university of Turin. *J Oral Maxillofac Surg* 2010;68:2994-9.
- Regezi JA, Kerr DA, Courtney RM. Odontogenic tumors: Analysis of 706 cases. *J Oral Surg* 1978;36:771-8.
- Alqahtani M, Cohen DM, Islam MN, Bhattacharyya I. Dentinameloblastoma, a rare odontogenic tumor: Report of 2 cases with a review of the literature. *Oral Surg Oral Med Oral Pathol Oral Radiol* 2013;116:507-8.
- Rangel AL, da Silva AA, Ito FA, Lopes MA, de Almeida OP, Vargas PA. Clear cell variant of calcifying epithelial odontogenic tumor: Is it locally aggressive? *J Oral Maxillofac Surg* 2009;67:207-11.
- Philipsen HP, Reichart PA. Calcifying epithelial odontogenic tumour: Biological profile based on 181 cases from the literature. *Oral Oncol*

- 2000;36:17-26.
26. de Oliveira MG, Chaves AC, Visioli F, Rojas EU, Moure SP, Romanini J. Peripheral clear cell variant of calcifying epithelial odontogenic tumor affecting 2 sites: Report of a case. *Oral Surg Oral Med Oral Pathol Oral Radiol Endod* 2009;107:407-11.
  27. Anavi Y, Kaplan I, Citir M, Calderon S. Clear-cell variant of calcifying epithelial odontogenic tumor: Clinical and radiographic characteristics. *Oral Surg Oral Med Oral Pathol Oral Radiol Endod* 2003;95:332-9.
  28. Mesquita RA, Lotufo MA, Sugaya NN, De Araújo NS, De Araújo VC. Peripheral clear cell variant of calcifying epithelial odontogenic tumor: Report of a case and immunohistochemical investigation. *Oral Surg Oral Med Oral Pathol Oral Radiol Endod* 2003;95:198-204.
  29. Kumamoto H, Sato I, Tateno H, Yokoyama J, Takahashi T, Ooya K. Clear cell variant of Calcifying Epithelial Odontogenic Tumor (CEOT) in the maxilla: Report of a case with immunohistochemical and ultrastructural investigations. *J Oral Pathol Med* 1999;28:187-91.
  30. Azevedo RS, Mosqueda-Taylor A, Carlos R, Cabral MG, Románach MJ, de Almeida OP. Calcifying Epithelial Odontogenic Tumor (CEOT): A clinicopathologic and immunohistochemical study and comparison with dental follicles containing CEOT-like areas. *Oral Surg Oral Med Oral Pathol Oral Radiol* 2013;116:759-68.
  31. Afrogheh A, Schneider J, Mohamed N, Hille J. Calcifying epithelial odontogenic tumour with clear langerhans cells: A novel variant, report of a case and review of the literature. *Head Neck Pathol* 2014;8:214-9.