

'Burned-out' syndrome of testicular teratoma: A case report

ROBERTO SANSEVERINO¹, RAFFAELE BAIIO², MARIA ADDESSO³, GIORGIO NAPODANO¹,
 UMBERTO DI MAURO¹, OLIVIERO INTILLA¹, PAOLO VERZE²,
 ANNAMARIA LIBROIA⁴ and GIOVANNI MOLISSO¹

¹Department of Urology, Umberto I Hospital, I-84014 Salerno;

²Department of Medicine and Surgery 'Scuola Medica Salernitana', University of Salerno, I-84081 Salerno;

Departments of ³Pathological Anatomy and ⁴Oncology, Andrea Tortora Hospital, I-84016 Salerno, Italy

Received April 13, 2021; Accepted August 13, 2021

DOI: 10.3892/mco.2021.2424

Abstract. The majority of testicular tumors are germ cell tumors (GCTs) which, although rare, frequently present in young adults. In exceptional circumstances, spontaneous regression of the primary tumor occurs. The appellation 'burned-out' is applied to situations in which a metastatic GCT is found to be present, accompanied by histological regression of the primary testicular lesion. It is of crucial importance that a clinical examination of the testis is performed, and scrotal sonography is essential in the preliminary diagnosis of such neoplasms. In the present case report, a burned-out, non-seminomatous testicular GCT case is described. A CT scan revealed that a 29-year-old male patient who was experiencing loss of weight and appetite had retroperitoneal and mediastinal masses. A testicular examination did not reveal the presence of any palpable lesion, and an ultrasound examination of the scrotum disclosed a normal left testis and an atrophic right testicle with heterogeneous architecture, but with no evidence of a tumor. Chemotherapy was administered to the patient following surgical intervention into the retroperitoneal and mediastinal mass. It is evident that it remains problematic to accurately differentiate between a primary retroperitoneal tumor and a metastatic testicular tumor with an occult testicular primary or a 'burned-out' testicular cancer. The burned-out phenomenon is a rare occurrence, and further research into its

pathogenesis is required. Both the rarity of this phenomenon and the difficulties encountered in diagnosis prompted the writing of the present case report, especially considering that teratomas are categorized as belonging to the histology group that shows the least likelihood of regressing.

Introduction

Over 90% of testicular tumors are derived from the germ cells, which represent the main cell population of the testis. Testicular germ cell tumors (TGCTs) tend to occur most frequently in the age range of 15-35 years. The most commonly encountered type of histological pattern of the disease is the non-seminomatous TGCT (NS-TGCT) type, which peaks at 25 years (1). Among the risk factors associated with developing testicular cancer are conditions such as Klinefelter syndrome, cryptorchidism, a family history of testicular tumors, previous history of a testicular tumor, sperm abnormalities and infertility (1-3). In TGCTs, there are at least two possible histological types. Often, the combinations include seminoma and embryonal carcinoma, teratoma and yolk sac tumor. The prognosis becomes even poorer when aggressive histotypes are present (1). Spontaneous tumor regression has been reported in various neoplasias (2,4). One such case of regression is the so-called 'burned-out' testicular tumor. This is a TGCT that has regressed without intervention, and usually presents as metastasis to other sites (manifesting as secondary symptoms), such as the retroperitoneal and mediastinal regions (5). This occurrence of metastasis can present as raised tumor markers and as a dubious ultrasound image for the testis. The most likely condition to burn out is seminoma with the next most likely to burn out being embryonal carcinoma; however, it has previously been reported this process is unlikely to occur in the case of teratoma (6). Nevertheless, such an occurrence of a burned-out testicular teratoma that metastasized to the retroperitoneal and mediastinal areas without any palpable lesions on testicular examination, nor without ultrasound evidence of tumor, is documented in the present case report.

Correspondence to: Dr Raffaele Baio, Department of Medicine and Surgery 'Scuola Medica Salernitana', University of Salerno, Salvador Allende Street 43, Baronissi, I-84081 Salerno, Italy
 E-mail: dott.rbaio@gmail.com

Abbreviations: TGCTs, testicular germ cell tumors; LDH, lactate dehydrogenase; α -FP, α -fetoprotein; β -HCG, β -human chorionic gonadotropin; PEB, bleomycin, etoposide, cisplatin; RPLND, retroperitoneal lymph node dissection; GCTs, germ cell tumors; EGCTs, extragonadal germ cell tumors

Key words: testicular teratoma, burned-out syndrome, punctuate echogenic foci

Case report

A 29-year-old male was admitted to the Internal Medicine Unit of another hospital due to symptoms of incomplete

ileus (diffuse abdominal discomfort, nausea and abdominal distension), associated with fever and loss of appetite; the patient had no relevant past medical history, without common risk factors for testicular cancer (such as the presence of tumor in the contralateral testis, history of cryptorchidism or undescended testis, hypotrophic testis and Klinefelter syndrome). Furthermore, no family history of testicular cancer was reported among first degree relatives. A Computed Tomography (CT) scan revealed the presence of lymphadenopathies affecting the neck, mediastinum and retroperitoneum. In particular, the lymphadenopathies of the retroperitoneum and of the left external iliac site were voluminous, forming packages up to 18 cm in diameter, with infiltration of the large retroperitoneal vessels (Fig. 1A), the left common iliac vessel (Fig. 1B) and the left external iliac vessel (Fig. 1C and D).

The levels of baseline plasmatic specific biomarkers were as follows: Lactate dehydrogenase (LDH), 3006 U/l (normal values: 122-222 U/l); α -fetoprotein (α -FP), 8160 ng/ml (normal values <10 ng/ml); and β -human chorionic gonadotropin (β -HCG), 47382 mIU/ml (normal values: 0-5 mIU/ml). Physical examination revealed a palpable abdominal mass, although both testicles appeared normal. Testicular ultrasound revealed no focal alterations, although the right testis was atrophic, with a rarefied eco-structure. An excisional biopsy of the left sternocleidomastoid lymph nodes revealed a mixed non-seminomatous germ cell neoplasm, with prevalent aspects of mature teratoma while the minority component was represented by embryonic carcinoma (CD30+). The patient started a 3-cycle bleomycin, etoposide and cisplatin (PEB) chemotherapy. At the end of the course, the plasmatic biomarker levels were as follows: β -HCG, 11,9 mIU/ml; α -FP, 162 ng/ml; and LDH, 144 U/l.

A post-chemo CT scan disclosed a negligible decrease in the lymph node mass of the mediastinum, confirming the presence of voluminous pathological lymph nodes in the retroperitoneum (with bilateral hydronephrosis). A fourth cycle of PEB chemotherapy was scheduled but, despite a further decrease in the levels of the tumor markers (β -HCG, 9,5 mIU/ml and α -FP, 4,6 ng/ml), the lymph node masses did not decrease in size. Following an endoscopic positioning of a double J stent bilaterally, an open retroperitoneal lymph node dissection (RPLND) was performed, including nodes of the left renal hilum and intercaval-aortic, para-caval, para-aortic and left iliac and obturator nodes. Histological evaluation revealed a disorder of normal architecture of nodes structure due the presence of widespread mature teratoma (immunohistochemical examination, OCT3/4-, CD30-).

A post-operative CT scan was repeated 2 months later, which revealed no abdominal residual masses. At 3 months after surgery, the ureteral stents were removed. Subsequently, the patient was admitted to the Thoracic Surgery Unit for an open removal of thymus, subcarinal lymph node extending up to the arc of the azygos, left latero-cervical lymph node and neoformation of the anterior mediastinum. The thymic parenchyma resulted in partial adipose involution, but the other three samples were affected by germinal neoplasia, consisting of both cystic and solid areas, with elements of derivation of the three embryonic sheets. Respiratory, gastro-enteric and Mullerian epithelium were identified.

There were no structures referable to the lymph node. At 6 months' post-operation, a control CT scan revealed a hypodense formation in the anterior para-aortic site, strictly adjacent to the aortic arch. Furthermore, the retroperitoneum was affected by tumor recurrence. In particular, the following tumors were documented: in the lumbar aortic left region, long and close to the common iliac and external left vascular axis (Figs. 2A and B and 3B); and in the retrocaval region that compressed and displaced the venous vascular lumen anteriorly (Fig. 3A).

No evolutionary densitometric changes affecting the parenchymatous organs of the abdomen were identified. Neither were any suspicious focal lesions evidently due to secondary reactions of the skeleton included in the volume under examination. Given the low efficacy of pre-intervention chemotherapy in reducing the size of the tumor masses, it was decided against treating the patient with further chemotherapy cycles. Instead, at 12 months after the first operation, a second RPLND was performed, during which the left retro-ilar lymph nodes, para-caval lymph nodes, common right iliac lymph nodes and common and external left iliac lymph nodes were removed. Upon anatomopathological examination, the samples were found to be formed from fibro-adipose tissue in which no defined lymph node structures were recognized, and which also formed the site of massive secondary localization from germinal neoplasia of the teratoma type (with areas of necrosis and calcification), showing (in immunohistochemical examination) negativity for OCT3/4 and CD30. Six months have passed since the last surgery and, at CT follow-up checks, no neoplastic recurrences have been identified in the abdomen. At present, the patient is preparing for a second chest surgery.

Discussion

GCTs represent about 1-1,5% of all human cancers, being the most frequent malignancy in males between the ages of 15 and 40 (7). The incidence of testicular cancer is 3-6 new cases per year per 100,000 males in Western countries, with an increase in the incidence observed in the last 30 years (8). About 95% are primary testicular neoplasms, while a primitive extragonadal site is less common. Although not common, EGCTs are, nevertheless, well-known neoplasms. Between 3-5% of all GCTs are primary EGCTs. Of these tumors, in excess of 60% of them are seminomas originating in the anterior mediastinum and retroperitoneum. Instead, in total, ~60% of all cases of testicular mixed GCTs present with an advanced disease stage (stage II or III). Metastases most frequently occur at an early stage in the retroperitoneal lymph nodes. These can then develop to associate with mediastinal and supraclavicular lymph nodes (1,9). Occasionally, TGCTs can recede without intervention after their metastatic extension to the lymph nodes. The term 'burned-out' is often used to describe this unusual regression, and the burn out may be either partial or total (10). Previously, numerous of these cases were categorized as primary extragonadal GCTs (EGCTs), although in a number of cases spontaneous regression of the TGCT was recorded. An addition to the 2016 WHO classification is expanded discussion of 'burnt-out' germ cell tumour (11). Findings in the testis of such patients typically

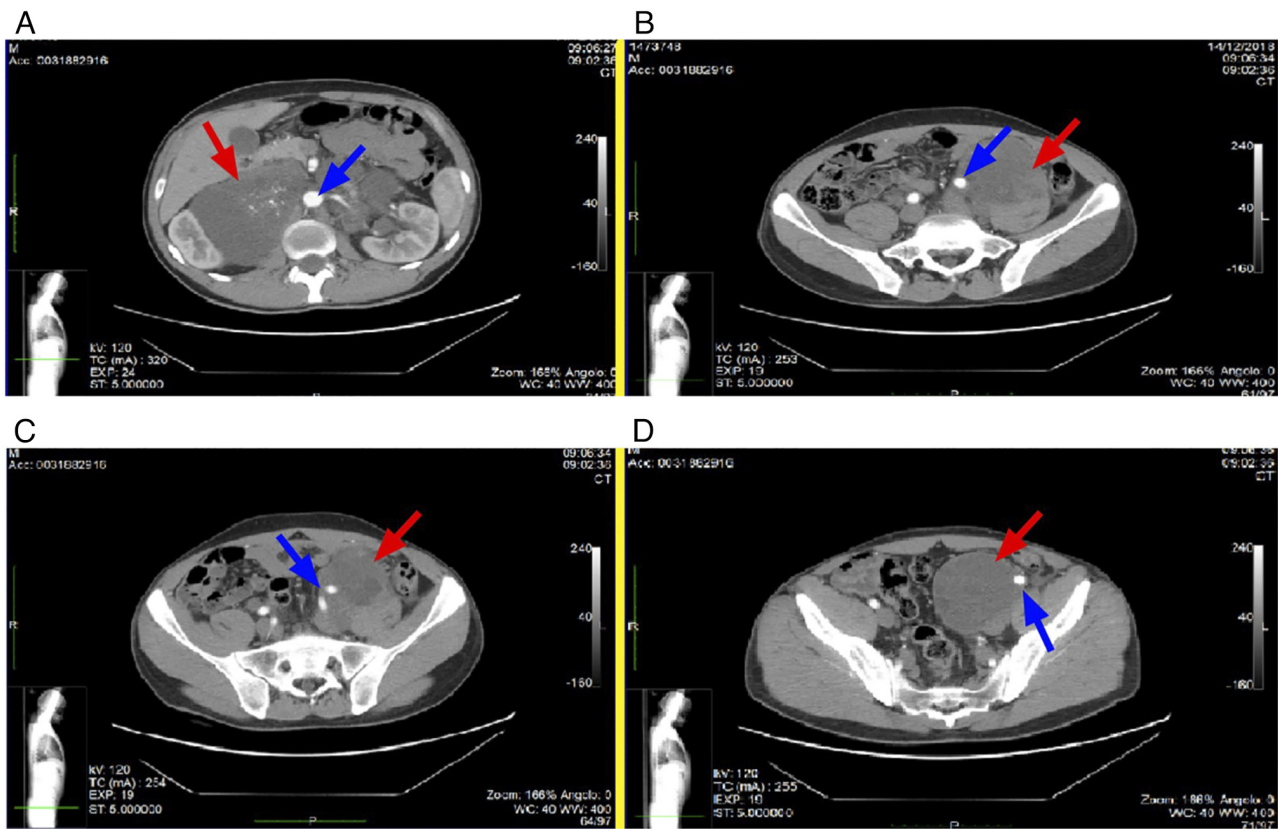


Figure 1. Pre-operative evaluation of the patient with imaging techniques. This CT, also performed with contrast medium, showed the lymphadenopathies of the retroperitoneum. (A) Arterial phase of the CT scan in which the voluminous lymph node mass is indicated by the red arrow while the blue arrow indicates the aorta. (B) The blue arrow shows the left common iliac artery while the red arrow indicates lymphadenopathy. (C) The blue arrow indicates the bifurcation of the left iliac arterial axis in the left internal and external iliac artery while the red arrow indicates the lymph node mass. (D) Voluminous lymphadenopathy (indicated by the red arrow) incorporates the left external iliac artery (indicated by the blue arrow).

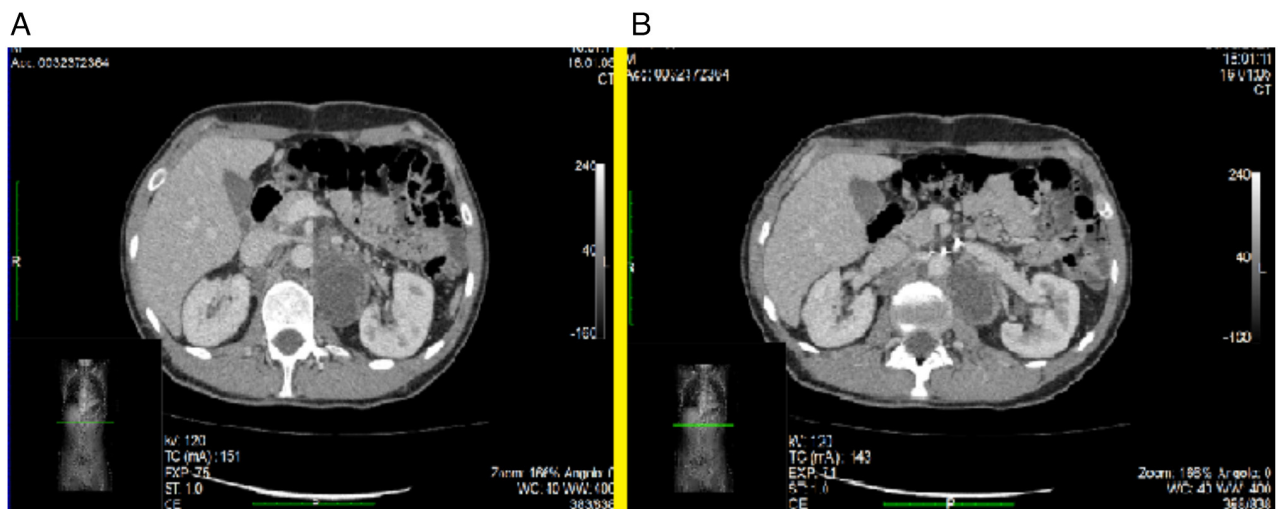


Figure 2. Follow-up performed with imaging techniques after the first surgery. This control CT scan revealed tumor recurrence of the retroperitoneum: (A) In the lumbar aortic left region (where a mass occupying space is visible between the aorta and the vascular peduncle of the left kidney), (B) long and close to the common iliac and external left vascular axis (since the mass extends to the bifurcation of the aorta into the iliac arteries).

include a scar, reduced spermatogenesis and microlithiasis. However, findings that have been proposed as specific for germ cell tumour regression rather than non-neoplastic scarring are limited to: i) Germ Cell Neoplasia *in Situ* (GCNIS) in the adjacent parenchyma; and ii) coarse, large intratubular calcifications. However, these coarse calcifications must be

distinguished from microlithiasis (small, rounded calcifications), which may be found in the adjacent parenchyma of germ cell tumour patients but are not specific for the presence of tumour. Overall, pathologists must be aware in the setting of scarring that, even if careful search does not reveal these highly specific lesions (GCNIS or coarse calcifications),

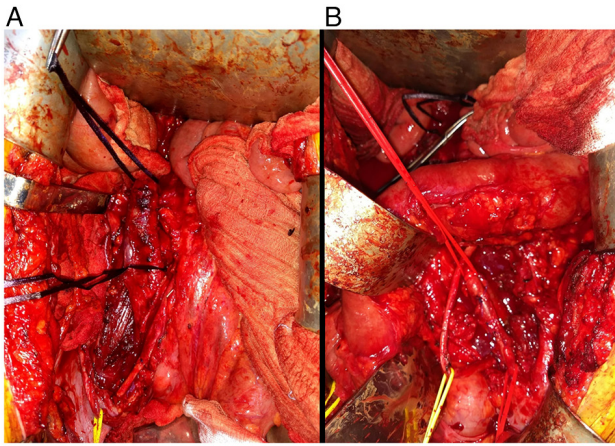


Figure 3. Access to the retroperitoneal space using an open surgical approach with a median incision. (A) Isolation, upstream and downstream between two blue ribbon-like wires, of the caval vein from the lymph node mass. (B) Isolation of the left iliac artery (with red vessel loop) and ureter (with yellow vessel loop).

the possibility of germ cell tumour regression remains a consideration for any testicular 'scar' and this must be communicated to clinical colleagues to ensure appropriate follow-up. As also highlighted in their review by Astigueta *et al* (12), there are not many publications on the regression of testicular GCTs and this entity has only recently been recognised in the last edition of the WHO's book on Tumours of the Urinary System and Male Genital Organs (2016), in the chapter on testicular tumours and paratesticular tissues (11). It is considered that the first to describe this phenomenon was Prym in 1927 (13); he, during an autopsy, recorded testicular scarring in a patient who had an extragonadal tumor. Azzopardi *et al* (14) have documented the presence of cell-poor, collagen-rich fibrous scars in some otherwise substantially normal testes of patients with metastatic NS-TGCTs. The authors uncovered hematoxyphilic deposits in seminiferous tubuli, which they identified as hematoxyphilic bodies. Comiter *et al* (15) recorded widespread degeneration of the testis with hematoxyphilic and psammoma forms in a number of cases, which they concluded as being representative of echogenic foci. In all instances, a fibrous scar was found in the testis, a condition which brings to an end the spontaneous reversal of a primary GCT after metastasis has diffused to different locations. A plausible explanation is the occurrence of an immune response, with an ischemia resulting from the high metabolic rate of the neoplasm outgrowing its blood supply. Burned-out tumors can be difficult to diagnose, as secondary tumors are often erroneously diagnosed as primary tumors. Discriminatory diagnosis of burned-out TGCT leads to a consideration of EGCTs as far as the diagnosis is concerned, although their occurrence is rare (between 5-10% of all TGCTs); the most common location of these is in the retroperitoneal region. However, if scarring in the testis is observed, the possibility of the reversal of the GCT must also be considered. The main difficulty in reaching a correct diagnosis is that of deciding whether a neoplasm under investigation is either primary or secondary in origin. In these situations, performing a testicular ultrasound is obligatory. The same prognosis applies to

metastatic disease, which occurs secondarily to burned-out lesion (as the primary testicular malignancy); accordingly, it is essential that it is accurately diagnosed. A 'burned-out' TGCT is an exceptional finding, and it is important to recognize that many burned-out TGCT cases lack molecular sequencing. This fact can hinder the understanding of this phenomenon; accordingly, further research is required. It is well established that all germinal tumors have the potential for regression; however, there is disagreement in the literature regarding the frequency of the histological subtypes that provide evidence of this phenomenon. Previously, choriocarcinoma [a non-seminomatous neoplasm, included in the group of germline tumors derived from GCNIS according to WHO 2016 classification (11)] was considered to be the most likely to recede but, more recently, seminoma has been identified as the most common histology, apart from the spermatocytic type, which is now categorized as a separate entity [in the group of germline cancers not derived from GCNIS according to WHO 2016 classification (11)]. The teratomas [which are non-seminomatous neoplasms, included in the group of germline tumors derived from GCNIS according to WHO 2016 classification (11)] remain as the histological group with the lowest likelihood of regression (16-20). Previous studies, as claimed also by Mosillo *et al* (21) in their case report, have shown that lymph-node diffuse metastases in testicular mature teratoma tend to be caused by aggressive germ cell components that have undergone early regression. That is what we consider best explains what occurred in the present case, although this is purely conjectural as it cannot be manifestly supported by histological evaluation of orchiectomy. However, the result of the left sternocleidomastoid lymph node excisional biopsy (i.e., mixed, non-seminomatous germ cell neoplasm with prevalent aspects of mature teratoma) is supportive of the present hypothesis. Furthermore, the scrotal ultrasound detection of an atrophic and rarefied right testicle was an important finding. In fact, two works entitled '*Shrinking Seminoma*' and '*Shrinking Seminoma-Fact or Fiction?*' (22,23), published in 1990 and 2000 respectively, described a reduction in volume in a testicle with seminoma, where the underlying mechanism was essentially ischemia-necrosis secondary to intermittent testicular torsion. However, other potential causes that need to be considered include chronic inflammation and hormonal disorder. Depending on which stage the condition has reached when it is diagnosed, a testicle shrunken in size (with or without a residual tumor) may be found. For this reason, when retroperitoneal, mediastinal or other types of mass that also present as testicular shrinking is found in a patient, a GCT should be suspected (22,23). Where echogenicity arises in a focal area of ultrasonographic images of burned-out tumors, this is likely to be due to calcium deposits and fibrosis. However, when punctuate echogenic foci are observed, but without any evidence of any hypoechoic mass lesions, a burned-out testicular tumor should be suspected (24). Similarly, in their review, Kreydin *et al* (25) claim that, on occasion, the initial presentation of testicular cancer may be a retroperitoneal mass, with testicular imaging not revealing an evident lesion. In these cases, according to them, a testicular malignancy must be considered (25). Mola Arizo *et al* (26)

contend that the presence of retroperitoneal tumors with ultrasonographical abnormalities observed upon testicular examination should be considered as metastases of a burned-out testicular cancer, and that surgical evaluation should be conducted in an individual setting (27). Gomez Parada *et al* (27) state that impalpable primary testicular tumor should be suspected in patients who present with an EGCT and normal testes on physical examination. As also argued by Kontos *et al* (28), who described the regression of primary testicular seminoma after the development of metastasis in the retroperitoneum, in patients with a retroperitoneal mass, diagnosis of metastatic progression of a germ cell neoplasia should be considered. A burned-out testicular tumor shows a distinctive constellation of findings that usually permits its recognition (such as a reduced volume testis and punctuate echogenic foci on ultrasound examination). This guidance draws attention to understanding the importance of the tumor markers and ultrasound in making the diagnosis. Furthermore, in conducting our own literature search, it was observed that, in all cases of testicular tumor burn-out syndrome which were treated with orchiectomy, tumor cells were not detected in the histological sample of the tissue. For this reason, given the result of the biopsy of the sternocleidomastoid lymph node and the relevance of the ultrasound findings, as reported in the literature, our consideration is that the diagnostic elements in the present case were sufficient to support a diagnosis of burned-out testicular teratoma.

Acknowledgements

Not applicable.

Funding

No funding was received.

Availability of data and materials

All data generated or analyzed during this study are included in this published article.

Authors' contributions

RB made substantial contributions to conception and design of the present study, and was the major contributor in writing the manuscript. RS, GN and PV were involved in revising the manuscript critically for important intellectual content and made important contributions to interpretation of data. MA, UDM, OI, GM and AL made substantial contributions to acquisition of data and data analysis. All the authors read and approved the final manuscript and agreed to be accountable for all aspects of the work in ensuring that questions related to the accuracy or integrity of any part of the work are appropriately investigated and resolved. RS and RB confirm the authenticity of all the raw data.

Ethics approval and consent to participate

Not applicable.

Patient consent for publication

Written informed consent was obtained from the patient for publication of this case report and any accompanying images.

Competing interests

The authors declare that they have no competing interests.

References

- Bosl GJ and Motzer NJ: Testicular germ-cell cancer. *N Engl J Med* 337: 242-253, 1997.
- Cole WH and Everson TC: Spontaneous regression of cancer preliminary report. *Ann Surg* 144: 366-383, 1956.
- Looijenga LH and Oosterhuis JW: Pathogenesis of testicular germ cell tumors. *Rev Reprod* 4: 90-100, 1999.
- Salman T: Spontaneous tumor regression. *J Oncol Sci* 2: 1-4, 2016.
- Johnson K and Brunet B: Brain metastases as presenting feature in 'burned out' testicular germ cell tumor. *Cureus* 8: e551, 2016.
- Fabre E, Jira H, Izard V, Ferlicot S, Hammoudi Y, Theodore C, Di Palma M, Benoit G and Droupy S: 'Burned-out' primary testicular cancer. *BJU Int* 94: 74-78, 2004.
- Cancer incidence in five continents, vol VIII. IARC Sci Publ 155: 1-781, 2002.
- Huyghe E, Matsuda T and Thonneau P: Increasing incidence of testicular cancer worldwide: A review. *J Urol* 170: 5-11, 2003.
- Surveillance, Epidemiology and End Result Program (SEER): Cancer Stat Facts: Testicular Cancer. National Cancer Institute, Bethesda, MD, 2015. <https://seer.cancer.gov/statfacts/html/testis.html>.
- Calvo OA, Rodríguez Alonso A, Pérez García D, Domínguez Freire F, Alonso Rodrigo A, Rodríguez Iglesias B, Benavente Delgado J, Barros Rodríguez JM, Fiaño Valverde C and Nogueira March JL: Extragonadal germ cell tumor with 'burned-out' phenomenon in the testis. *Actas Urol Esp* 23: 880-884, 1999.
- Ulbright T, Amin M, Balzer B, *et al*: Tumors of the testis and paratesticular tissue. In: WHO Classification of Tumors of the Urinary System and Male Genital Organs. Moch H, Humphrey PA, Ulbright TM and Reuter VE (eds). 4th edition. Lyon: IARC Press, pp185-258, 2016.
- Astigueta JC, Abad-Licham MA, Agreda FM, Leiva BA and De la Cruz JL: Spontaneous testicular tumor regression: Case report and historical review. *Ecancermedicalscience* 12: 888, 2018.
- Prym P: Spontanheilung eines bosartigen, wahrscheinlich chorionepitheliomatösen Gewachses im Hoden. *Virchows Arch Pathol Anat* 265: 239-258, 1927.
- Azzopardi JG, Mostofi FK and Theiss EA: Lesions of testes observed in certain patients with widespread choriocarcinoma and related tumors. The significance and genesis of hematoxylin-staining bodies in the human testis. *Am J Pathol* 38: 207-225, 1961.
- Comiter CV, Renshaw AA, Benson CB and Loughlin KR: Burned-out primary testicular cancer: Sonographic and pathological characteristics. *J Urol* 156: 85-88, 1996.
- Balzer BL and Ulbright TM: Spontaneous regression of testicular germ cell tumors: An analysis of 42 cases. *Am J SurgPathol* 30: 858-865, 2006.
- Extramiana J, De La Rosa F, Madero S, Tagarro D, Díaz González R, Martínez M, Gandía V, Leiva O and Borobia V: 'Burned-out' testicular tumor. *Actas Urol Esp* 10: 289-294, 1986 (In Spanish).
- Angulo JC, González J, Rodríguez N, Hernández E, Núñez C, Rodríguez-Barbero JM, Santana A and López JI: Clinicopathological study of regressed testicular tumors (apparent extragonadal germ cell neoplasms). *J Urol* 182: 2303-2310, 2009.
- López JI and Angulo JC: Burned-out tumor of the testis presenting as Retroperitoneal choriocarcinoma. *Int Urol Nephrol* 26: 549-553, 1994.
- Tejido Sánchez A, Villacampa Aubá F, Martín Muñoz MP, Rosino Sánchez A, Cruceyra Betriu G, Martínez Silva V and Leiva Galvis O: Burned-out testicular tumor. *Arch Esp Urol* 53: 447-452, 2000 (In Spanish).
- Mosillo C, Scagnoli S, Pomati G, Caponnetto S, Mancini ML, Bezzi M, Cortesi E and Gelibter A: Burned-Out testicular cancer: Really a different history. *Case Rep Oncol* 10: 846-850, 2017.

22. Simpson AH, Calvert DG and Codling BW: The shrinking semonima. *J R Soc Med* 83: 187, 1990.
23. Naseem S, Azzopardi A, Shrotri N and Mufti GR: The shrinking seminoma-fact or fiction? *Urol Int* 65: 208-210, 2000.
24. Yucel M, Kabay S, Saracoglu U, Yalcinkaya S, Hatipoglu NK and Aras E: Burned-out testis tumor that metastasized to retroperitoneal lymph nodes: A case report. *J Med Case Rep* 3: 7266, 2009.
25. Kreydin EI, Barrisford GW, Feldman AS and Preston MA: Testicular cancer: What the radiologist needs to know. *AJR Am J Roentgenol* 200: 1215-1225, 2013.
26. Mola Arizo MJ, Gonzalvo Perez V, Torregrosa Maicas MD, Navarro Anton JA, Gomez-Ferrer Lozano A, Estany Perez A and Polo Peris AC: Burn out bilateral testicular tumor. *Actas Urol Esp* 29: 318-321, 2005 (In Spanish).
27. Gomez Parada J and Puyol Pallas M: Occult primary testicular tumor or burnt testicular tumor. Apropos of a case. *Arch Esp Urol* 49: 635-638, 1996 (In Spanish).
28. Kontos S, Doumanis G, Karagianni M, Politis V, Simaioforidis V, Kachrilas S and Koritsiadis S: Burned-out testicular tumor with retroperitoneal lymph node metastasis: A case report. *J Med Case Rep* 3: 8705, 2009.



This work is licensed under a Creative Commons Attribution-NonCommercial-NoDerivatives 4.0 International (CC BY-NC-ND 4.0) License.