

Bronchorrhea, a Rare and Debilitating Symptom of Lung Cancer: Case Report and Review of the Treatment



Milind Bhagat, M.B.B.S.,^{a,*} Aditi Singh, M.B.B.S.,^b Talal Bazzi, MD,^b Jason Green, DO^a

^aDepartment of Pulmonary and Critical Care Medicine, University of Tennessee, Knoxville, Tennessee

^bDepartment of Hematology and Oncology, St. John Hospital, Detroit, Michigan

Received 13 April 2022; revised 2 July 2022; accepted 7 August 2022
Available online - 27 August 2022

ABSTRACT

Bronchorrhea, defined as production of voluminous watery sputum greater than 100 mL/d, is a debilitating symptom mostly found in end-stage lung cancer, specifically in invasive mucinous adenocarcinomas. Very rarely, it can primarily contribute to hypoxic respiratory failure and found in a critical care setting. We report a case of a 51-year-old woman diagnosed with having mucinous adenocarcinoma of the lung who presented to the intensive care unit with rapidly worsening respiratory failure and found to have massive bronchorrhea with daily sputum volume exceeding 1000 mL/d at its peak. With the limited quantity and quality of evidence available for the treatment of this condition, multiple agents were tried without considerable benefit. We discuss the pathogenesis of this condition and the different treatment options that can be used for palliation of the sputum volume.

© 2022 The Authors. Published by Elsevier Inc. on behalf of the International Association for the Study of Lung Cancer. This is an open access article under the CC BY-NC-ND license (<http://creativecommons.org/licenses/by-nc-nd/4.0/>).

Keywords: Case report; Bronchorrhea; Lung cancer; Invasive mucinous adenocarcinomas; Respiratory failure; EGFR inhibitors

Introduction

Most common symptoms of lung cancer include cough, dyspnea, chest pain, and weight loss. Bronchorrhea is a condition found in only a few of the patients with cancer and is characterized by voluminous non-purulent watery sputum more than 100 mL/d. It may be idiopathic or associated with various lung diseases, such

as tuberculosis, chronic bronchitis, asthma, or malignancy of the lung. Historically, it has been mostly associated with bronchioloalveolar cell carcinoma, a term now replaced by invasive mucinous adenocarcinomas (IMAs) of the lung. This condition can be extremely debilitating causing a significant impact on quality of life and can even cause respiratory failure in some cases. To our knowledge, an effective treatment option for this condition is not well established. Treatment of the underlying malignancy improves the symptoms, but results have been inconsistent. Other studies have looked at different treatment options including antibiotics, such as erythromycin, corticosteroids, inhaled indomethacin, octreotide, and tyrosine kinase inhibitors. Given the rarity of this symptom, especially in the intensive care unit (ICU) setting and its debilitating nature without any established standard of care, awareness of such cases should be made for pulmonologists, intensivists, and oncologists. We herein present a case of IMA presenting to the ICU with severe bronchorrhea.

*Corresponding author.

Disclosure: *The authors declare no conflict of interest.*

Address for correspondence: Milind Bhagat, M.B.B.S., The University of Tennessee Medical Center at Knoxville, The University of Tennessee Knoxville, 1924 Alcoa Highway, Knoxville, TN 37920. E-mail: mbhagat@utmck.edu

Cite this article as: Bhagat M, Singh A, Bazzi T, Green J. Bronchorrhea, a rare and debilitating symptom of lung cancer: case report and review of the treatment. *JTO Clin Res Rep.* 2022;3:100398.

© 2022 The Authors. Published by Elsevier Inc. on behalf of the International Association for the Study of Lung Cancer. This is an open access article under the CC BY-NC-ND license (<http://creativecommons.org/licenses/by-nc-nd/4.0/>).

ISSN: 2666-3643

<https://doi.org/10.1016/j.jtocr.2022.100398>

Case Presentation

A 51-year-old woman was admitted to the medical ICU of a tertiary care hospital as a transfer from a community hospital for worsening acute hypoxemic respiratory failure. She had presented to the outside hospital 4 days before with worsening shortness of breath and productive cough for a week. Of note, she had been diagnosed with having mucinous adenocarcinoma of the lung by computed tomography-guided biopsy of a right lower lobe lung mass a month before. At the outside hospital, she was intubated in the emergency department for worsening hypoxemia. She was initiated on broad-spectrum antibiotics and empirical therapeutic anticoagulation for presumed pulmonary embolism, before being transferred for worsening respiratory failure on mechanical ventilation. The rest of her past medical history was significant for an active 30-pack year smoking history, non-oxygen (O₂)-dependent chronic obstructive pulmonary disease, anxiety disorder, and vitamin B12 deficiency. Physical examination results on presentation to this hospital revealed a temperature of 99.1°F, heart rate of 115 beats/min, blood pressure of 108/53 mm Hg, O₂ saturation of 92% on 100% fraction of inspired oxygen (FiO₂), positive end-expiratory pressure of 12, respiratory rate at 30 breaths/min, and tidal volume of 280 mL. She was intubated, sedated, and paralyzed. The rest of her physical examination findings was significant for bilateral coarse rhonchi and clubbing of her upper extremities. Laboratory workup result was remarkable for lactic acid of 3.9 mmol/L. Arterial blood gas test result on presentation revealed pH of 7.178, partial pressure of CO₂ of 84.1 mm Hg, partial pressure of O₂ of 140 mm Hg, and O₂ saturations of 98% on 100% FiO₂. She had leukocytosis with white blood cell count of 14,500/μL and platelet count of 670,000/μL. Brain natriuretic peptide was 1942 pg/mL and troponin level at 3.97 ng/mL. Result of computed tomography angiogram of the chest with contrast was negative for pulmonary embolism (Fig. 1). It revealed the previously known right lower lobe lung mass along with new superimposed consolidation and ground-glass opacities throughout both lungs, reasons of which are equivocal, including possibility of rapid tumor progression with lepidic growth pattern.

Starting from the day of presentation, the patient was noted to have significant secretions from her endotracheal tube, ranging from clear to mucinous. An exchange of endotracheal tube was done on day 2 from 6.5 mm to 7.5 mm for easier pulmonary toileting. The patient was able to be weaned down on her ventilator settings to 40% FiO₂, with positive end-expiratory pressure of 10 in the next 24 hours. Nevertheless, subsequently, her significant secretion burden continued to get worse

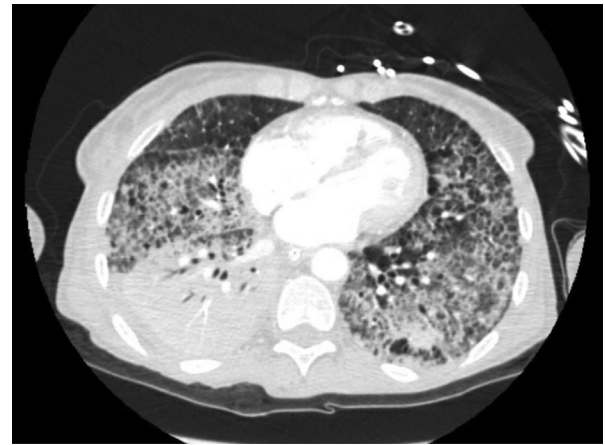


Figure 1. CT image of the lung bases showing the known right lower lobe lung mass and the diffuse ground glass opacities with septal thickening bilaterally.

exceeding 1000 mL/d (Fig. 2). Diuresis was started along with broadening of her antibiotics which did not significantly affect the volume of secretions. She failed daily spontaneous breathing trial attempts, primarily believed to be secondary to her copious secretions, which also precluded any further weaning. A diagnosis of bronchorrhea was made, resulting from her recently diagnosed mucinous adenocarcinoma and was believed to be the primary cause of her persistent hypoxemia at this

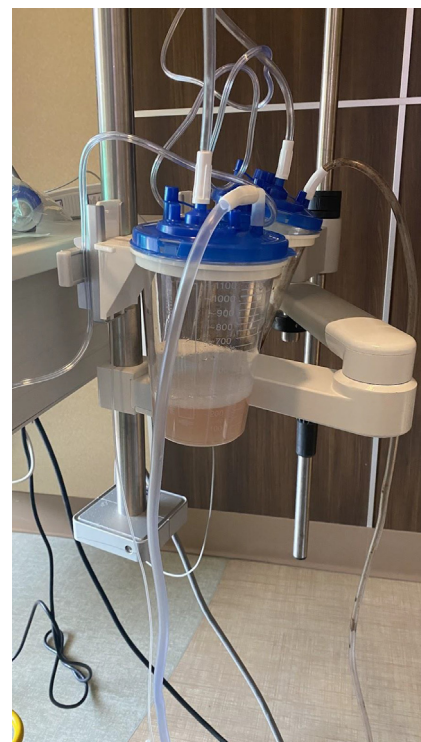

Figure 2. Image showing the secretion burden from the bronchorrhea.

point. She was started on an octreotide drip along with a scopolamine patch to help with the secretions. She was continued on aggressive diuresis as well, all of which did not significantly affect the bronchorrhea.

After further review of the literature and consultation with Pharmacy, Oncology, and Palliative Care Services, different agents were reviewed although their evidence was limited to case reports and case series in the setting of an ICU. These agents included a macrolide, atropine, and stress-dose hydrocortisone. These agents helped minimally, but her secretion output continued to be above 500 mL/d with worsening hypoxemia. Results of her programmed death-ligand 1 expression and other molecular markers, such as EGFR mutations, *ALK*, and *ROS-1* fusion, were negative. After discussion with Oncology Services and the family, a decision was made to start her on chemotherapy with carboplatin and pemetrexed with the aim of improving her bronchorrhea and hypoxemia. In the next 24 hours, however, her oxygen requirements continued to get worse with worsening leukocytosis and vasopressor requirements. Decision was made by the family for transition to comfort care as per the patient's previously expressed wishes. The patient was terminally extubated and passed away comfortably soon after.

Discussion

Bronchorrhea can be caused by both malignant and nonmalignant etiologies. First case in association with lung cancer was described in the 1960s. It is an uncommon symptom of lung cancer and almost always associated with IMA of the lung, previously known as invasive bronchoalveolar carcinoma.¹ A few cases of bronchorrhea associated with nonpulmonary mucin-producing adenocarcinomas have also been reported.² IMAs only account for 3% to 10% of lung adenocarcinomas, and therefore, bronchorrhea cases are seldom encountered in critical care practice, albeit found more frequently in end-of-life care.³ Most cases are associated with smoking and female sex.

Severe cases of bronchorrhea associated with extremely high output such as our patient are invariably caused by malignant etiologies.⁴ Clinical presentation varies from an asymptomatic nuisance to presentation with respiratory failure. Our patient required endotracheal intubation with mechanical ventilatory support because of impending respiratory failure and complications from bronchorrhea.

Secretory and transudative pathways underplay in the mechanism of bronchorrhea development.⁵ The bronchorrheal fluid is protein poor and isosmolar to serum suggestive of transudative nature of the fluid. It can contain markedly elevated lipase levels in cases

where pulmonary metastasis from nonpulmonary mucin-producing adenocarcinomas is the cause. Secretory cell hyperplasia and metaplasia of normal mucin-producing cells could potentially explain the pathogenesis of bronchorrhea in both cancer-associated cases and chronic pulmonary diseases. Under normal conditions, mucin-producing goblet cells form a very small percentage of airway epithelial cells. During airway inflammation, goblet cells increase in number and other non-mucin-secreting cells undergo metaplasia switching to a mucin-producing phenotype. This change is mediated by cells and molecules of inflammatory pathways, such as T helper 2 lymphocytes, which mediated release of cytokines interleukin (IL)-4, IL-5, IL-9, IL-10, and IL-13. In addition, EGF pathway has been found to play a critical role in mucus hypersecretion in chronic lung diseases. Experimental studies have found goblet cell hyperplasia and mucous metaplasia when airways were stimulated by external EGFR pathway ligands, such as transforming growth factor- β and tumor necrosis factor- α . Increased activity and number of rough endoplasmic reticulum have been noted in the neoplastic cells under electron microscope corroborating the increased mucin production activity. Similarly, in cases of IMAs, up-regulation of cyclooxygenase-2 enzyme and resultant synthesis of mediators of inflammatory pathways have been noted. The passive diffusion of water which is responsible for maintaining the liquid nature of the mucus secretion is believed to be controlled by trans-epithelial chloride secretion. Hypersecretion of this chloride with water accompanying it is considered one of the causes of excess mucus volume.

Hypoxia in severe bronchorrhea is likely caused by intrapulmonary shunting. With severe cases of bronchorrhea where the mucin completely fills the alveoli, severe ventilation-perfusion mismatch ensues, leading to refractory hypoxia such as in our case. In addition, lepidic growth of the tumor along the alveolar surface can itself lead to hypoxia in these cases.

Ground-glass opacities and consolidation confined to one lung or diffusely involving both lungs can be found on the radiologic images. It can mimic acute respiratory distress syndrome and a new infection in the ICU setting. In the appropriate setting, microbiological investigation of the bronchial fluid may reveal a treatable cause.

Various pharmacologic and nonpharmacologic modalities of treatment have been used for bronchorrhea.⁶ Owing to the rarity of this condition, there has been no clinical trial to our knowledge revealing the effectiveness of a particular treatment. Most of the evidence, therefore, is of low quality, having been limited to case series and reports. The cases of severe bronchorrhea are especially difficult to treat with little success, such as in our case.

Most pharmacologic modalities have attempted to inhibit the pathways responsible for goblet cell metaplasia and hyperplasia. Others have attempted to treat the underlying disease. A summary of modalities used in adenocarcinoma of the lung-associated bronchorrhea can be found in Table 1.

Anticholinergics, such as glycopyrrolate, scopolamine, and atropine, have been used in the palliative care setting for excessive oral secretions often as an off-label use and can be tried in this setting.

Indomethacin is a nonsteroidal anti-inflammatory drug that reduces the production of inflammatory mediators through inhibition of the cyclooxygenase pathway and has been found to be effective in controlling mucus hypersecretion. It has low water solubility making it an ideal nonsteroidal anti-inflammatory drug for aerosolized formulation. It has been successfully used for the treatment of bronchorrhea caused by IMAs, especially where neoplastic cells were found to have high cyclooxygenase-2 expression levels.

Macrolides antibiotics are immunomodulators and reduce respiratory glycoprotein and chloride secretion. Ease of availability and evidence of efficacy in other cases convinced us to try azithromycin in our case as well. Nevertheless, the agent reduced neither the mucin production nor the hypoxic symptoms in our case.

There has been one successful reported case each using inhaled and systemic corticosteroids. Although the exact underlying mechanism of corticosteroids reducing

sputum volume is not known, they have been previously found to reduce airway secretion of the submucosal glands through direct and indirect inhibition by gene-encoding inducible cyclooxygenase.

Similarly, octreotide, which inhibits secretin and is responsible for the shift of electrolytes across the membranes, has been used in some cases with success.

The role of the EGFR pathway in mucus hypersecretion is highlighted in the previous discussion, and it makes utmost sense to study the use of EGFR inhibitors in the treatment of bronchorrhea. In adenocarcinoma of the lung, overexpression of *MUC5AC*, one of the key mucin genes, is noted. Kitazaki et al.⁷ found the suppression of *MUC5AC* mRNA in both the constitutive state and EGF-stimulated state of A549 lung adenocarcinoma and NCI-H292 pulmonary mucoepidermoid carcinoma cell lines. Nevertheless, the effect was more prominent in the EGF-stimulated state. The EGF-stimulated state mimics the EGFR-mutated lung cancer. Therefore, the benefit of EGFR inhibitors for the treatment of bronchorrhea in EGFR-negative adenocarcinoma will likely not result in a great benefit. The reported cases⁸ of use of either gefitinib or erlotinib in literature are from the pre-next-generation sequencing era and do not offer any practical guide in management of bronchorrhea cases, which are most often found in mucinous adenocarcinomas that are rarely EGFR mutated. Lack of reported EGFR mutations in cases does not convince to use the EGFR inhibitors in negative cases, such as ours.

Table 1. Drugs Used in Cancer-Associated Bronchorrhea

Drugs	Dose
Anticholinergics	-IV/SQ Glycopyrrolate 0.2 mg every 4 to 8 h -IM/IV/SQ Atropine 0.5 to 1 mg every 4 to 6 h as needed -Scopolamine transdermal patch 1 mg/3 d behind ear for up to 72 h
Inhaled indomethacin (availability and use in current medical practice are questionable. The oral solution can be aerosolized.)	-75-150 mg/d for 1 mo -2 mL of indomethacin (1.2 µg/mL) three times a day for 14 d
Inhaled corticosteroids	Dosing for this specific indication is not provided in literature or package insert. Can be used per U.S. FDA package insert
Systemic corticosteroids	High-dose IV steroids (methylprednisolone 1000 mg/d) followed by slow taper of prednisolone 60 mg/d for a total of 1 mo
Macrolide antibiotics	Erythromycin 600 mg/d Clarithromycin 500 mg orally twice a day
Octreotide	300 µ/d to 500 µ/d or 200 µ twice a day
TKIs (authors recommend use only in EGFR-mutated lung cancer cases.)	-Gefitinib 250 orally once a day -Erlotinib 150 mg orally once a day -Authors prefer osimertinib 80 mg orally once a day over other TKIs in EGFR-mutated lung cancer

FDA, Food and Drug Administration; IM, intramuscularly; IV, intravenously; SQ, subcutaneously; TKI, tyrosine kinase inhibitor.

Furthermore, the acquisition of drugs owing to lack of approval, prohibitive cost, and the associated toxicity is a limiting factor in treatment of bronchorrhea in such cases. More studies are warranted to study the effect of these novel drugs on mucin production. The role of these drugs in confirmed EGFR-mutated cases is very dramatic.⁹

Conclusion

Bronchorrhea is an extremely rare and debilitating complication of lung cancer, most often associated with mucinous adenocarcinoma. Although the quality of evidence is low, multiple treatment options can be tried to reduce the volume of secretions for palliation.

CRediT Authorship Contribution Statement

Milind Bhagat: Conceptualization, Methodology, Writing-original draft preparation, Visualization, Supervision.

Aditi Singh, Talal Bazzi: Writing- original draft preparation.

Jason Green: Writing – review & editing, Supervision.

Acknowledgments

Informed consent was obtained from the patient's next of kin for this publication.

References

1. Hidaka N, Nagao K. Bronchioloalveolar carcinoma accompanied by severe bronchorrhea. *Chest*. 1996;110:281-282.
2. Lembo T, Donnelly TJ. A case of pancreatic carcinoma causing massive bronchial fluid production and electrolyte abnormalities. *Chest*. 1995;108:1161-1163.
3. Zyllicz Z. The challenge of bronchorrhea in advanced cancer - a case report with review of literature. *Adv Pall Med*. 2010;9:9-12.
4. Kurahara Y. Massive bronchorrhea. *Internal Med*. 2021;60:2155-2156.
5. Lundgren JD, Shelhamer JH. Pathogenesis of airway mucus hypersecretion. *J Allergy Clin Immun*. 1990;85:399-417.
6. Rémi C, Rémi J, Bausewein C. Pharmacological management of bronchorrhea in malignant disease: a systematic literature review. *J Pain Symptom Manag*. 2016;51:916-925.
7. Kitazaki T, Soda H, Doi S, Nakano H, Nakamura Y, Kohno S. Gefitinib inhibits MUC5AC synthesis in mucin-secreting non-small cell lung cancer cells. *Lung Cancer*. 2005;50:19-24.
8. Yano S, Kanematsu T, Miki T, et al. A report of two bronchioloalveolar carcinoma cases which were rapidly improved by treatment with the epidermal growth factor receptor tyrosine kinase inhibitor ZD1839 ("Iressa"1). *Cancer Sci*. 2003;94:453-458.
9. Rubiales AS, Cruz V de la, JÁ Berezo, Torres MÁ. Erlotinib or gefitinib as first-choice therapy for bronchorrhea in bronchioloalveolar carcinoma. *J Pain Symptom Manag*. 2014;47:e7-e9.