

Reconstructive periodontal therapy with simultaneous ridge augmentation. A clinical and histological case series report

Péter Windisch · Dóra Szendrői-Kiss · Attila Horváth ·
Zsuzsanna Suba · István Gera · Anton Sculean

Received: 26 November 2007 / Accepted: 25 February 2008 / Published online: 21 March 2008
© The Author(s) 2008

Abstract Treatment of intrabony periodontal defects with a combination of a natural bone mineral (NBM) and guided tissue regeneration (GTR) has been shown to promote periodontal regeneration in intrabony defects. In certain clinical situations, the teeth presenting intrabony defects are located at close vicinity of the resorbed alveolar ridge. In these particular cases, it is of clinical interest to simultaneously reconstruct both the intrabony periodontal defect and the resorbed alveolar ridge, thus allowing insertion of endosseous dental implants. The aim of the present study was to present the clinical and histological results obtained with a new surgical technique designed to simultaneously reconstruct the intrabony defect and the adjacently located resorbed alveolar ridge. Eight patients with chronic advanced periodontitis displaying intrabony defects located in the close vicinity of resorbed alveolar ridges were consecutively enrolled in the study. After local anesthesia, mucoperiosteal flaps were raised, the granulation tissue removed, and the roots meticulously scaled and planed. A

subepithelial connective tissue graft was harvested from the palate and sutured to the oral flap. The intrabony defect and the adjacent alveolar ridge were filled with a NBM and subsequently covered with a bioresorbable collagen membrane (GTR). At 11–20 months (mean, 13.9 ± 3.9 months) after surgery, implants were placed, core biopsies retrieved, and histologically evaluated. Mean pocket depth reduction measured 3.8 ± 1.7 mm and mean clinical attachment level gain 4.3 ± 2.2 mm, respectively. Reentry revealed in all cases a complete fill of the intrabony component and a mean additional vertical hard tissue gain of 1.8 ± 1.8 mm. The histologic evaluation indicated that most NBM particles were surrounded by bone. Mean new bone and mean graft area measured $17.8 \pm 2.8\%$ and $32.1 \pm 8.3\%$, respectively. Within their limits, the present findings indicate that the described surgical approach may be successfully used in certain clinical cases to simultaneously treat intrabony defects and to reconstruct the resorbed alveolar ridge.

Keywords Guided tissue regeneration · Intrabony defects · Ridge augmentation · Connective tissue graft · Resorbable membrane · Natural bone mineral · Histology

P. Windisch · D. Szendrői-Kiss · A. Horváth · I. Gera
Department of Periodontology,
Semmelweis University,
Budapest, Hungary

Z. Suba
Oral Pathology Unit,
Department of Oral and Maxillofacial Surgery,
Semmelweis University,
Budapest, Hungary

A. Sculean (✉)
Department of Periodontology,
Radboud University Medical Center,
P.O. Box 9101, 117, Philips van Leydenlaan 25,
6500 Nijmegen, The Netherlands
e-mail: a.sculean@dent.umcn.nl
e-mail: anton.sculean@gmx.de

Introduction

The most important goal in the treatment of periodontal disease is to stop and control disease progression by means of non-surgical therapy [12, 15]. Regenerative periodontal therapy aims at the restitution of the tooth's supporting periodontal tissues (i.e., new periodontal ligament, new cementum with inserting connective tissue fibers, and new bone), which have been lost after injury or periodontal disease [11]. Various materials and techniques have been employed with varying degrees of success to treat intrabony

and furcation defects [4–6, 8, 11, 17–21, 23–25, 27–29]. One method to facilitate periodontal regeneration implies the fill of the intrabony periodontal defects with a natural bone mineral (NBM) and subsequent coverage of the graft material and the defects by means of a bioresorbable collagen membrane [4–6, 17–19, 23–25, 28]. Histological studies in animals and humans have provided evidence that NBM possesses excellent osteoconductive properties, integrates well into bone tissue, and may enhance periodontal regeneration in intrabony defects [2, 5, 6, 9, 18, 19, 24, 34]. In addition to surgical techniques aiming to promote periodontal regeneration, the augmentation of the resorbed alveolar ridge constitutes also an important therapeutic goal to allow placement of endosseous dental implants [26]. While supraalveolar periodontal regeneration is still unpredictable, vertical ridge augmentation has been demonstrated after treatment with onlay autografts or particulated autogenous bone covered by non-bioresorbable barrier membranes [1, 7, 8, 13, 14, 27]. However, in most cases, vertical ridge augmentation has been performed in edentulous areas without teeth demonstrating advanced periodontitis [1, 7, 26]. It was suggested that in cases with advanced periodontitis, these procedures may comport the risk for an infection of the augmented site and of membrane exposure originating from the neighboring periodontally compromised teeth [33]. In certain clinical situations, teeth presenting deep intrabony defects are located in close vicinity of the compromised alveolar ridge. In these particular cases, it is of clinical interest to simultaneously reconstruct both the intrabony periodontal defect and the resorbed alveolar ridge, thus allowing insertion of endosseous dental implants.

Therefore, the aim of the present study was to present the clinical and histological results obtained with a new surgical technique designed to simultaneously reconstruct the intrabony defect and the adjacently located resorbed alveolar ridge.

Materials and methods

Patient population

Eight patients (aged 50–61 years; four female and four male) with advanced chronic periodontitis were included in the study. They were referred for treatment to the Department of Periodontology, Semmelweis University, Budapest. The study protocol was approved by the ethical committee of the Semmelweis University of Medicine, Budapest, Hungary and was performed in accordance with the Helsinki Declaration of 1975 (revised in Edinburgh 2000). All participants signed informed consent forms.

The inclusion criteria were (1) healthy adults between the age of 18 and 70 years, (2) periodontally compromised tooth with clinical attachment loss ≥ 5 mm displaying presence of an intrabony defect, and (3) neighboring edentulous alveolar ridge demonstrating vertical resorption requiring augmentation to allow implant placement. Exclusion criteria were (1) systemic disease and/or drug therapy that could lead to impaired wound healing, (2) smoking, (3) pregnancy, or (4) tooth extractions at augmentation sites in the past 3 months.

Three months before the study, all patients received non-surgical periodontal treatment, including oral hygiene instructions and subgingival scaling and root planing under local anesthesia. At baseline, all participants had to display full-mouth plaque scores (FMPS) and full-mouth bleeding scores (FMBS) $< 25\%$. Baseline values are summarized in Table 1.

Clinical measurements

The following parameters were measured at baseline (before the augmentation procedure) and after 11–20 months (mean, 13.9 ± 3.9 ; before the implant placement procedure) by a blinded and calibrated examiner: (1) FMPS, (2) FMBS,

Table 1 Baseline clinical characteristics (including intraoperative measurements)

Patient no.	Tooth no.	Clinical measurements			Intraoperative measurements	
		PD*	GR*	CAL ^a	INTRA ^{a,b}	SUPRA ^{a,c}
1	27	7.0	1.7	8.7	4.0	6.0
2	22	6.3	0.3	6.7	2.0	5.0
3	35	9.0	2.7	11.7	4.3	9.0
4	44	4.0	2.7	6.7	1.3	5.0
5a	44	4.7	1.7	6.3	2.7	5.0
5b	47	4.7	2.3	7.0	2.3	4.7
6	13	7.0	4.0	11.0	4.0	8.3
7a	32	6.0	0.0	6.0	0.3	6.0
7b	43	5.7	0.0	5.7	1.0	5.7
8	48	8.0	5.0	13.0	6.3	8.3
Mean \pm SD		6.2 \pm 1.7	2.0 \pm 1.7	8.3 \pm 2.6	3.0 \pm 2.1	6.3 \pm 1.9

^a Mean in mm

^b The mean distance from the bottom of the defect to the most coronal extension of the adjacent alveolar crest

^c The mean distance from the CEJ to the most coronal extension of the alveolar bone crest

(3) probing pocket depth (PD), (4) clinical attachment level (CAL), (5) gingival recession (GR) with a millimeter-calibrated periodontal probe (PCP-UNC 15, Hu-Friedy, Chicago, IL, USA) to the nearest millimeter. If the cemento-enamel junction (CEJ) was not visible because of the presence of a restoration (crown, filling), the margin of this restoration served as a reference point. The measurements were registered at all adjacent teeth around the grafted area on vestibular, oral, and central points of proximal site facing the edentulous ridge, and the average was calculated. Pre- and postoperative radiographs were taken with the long cone parallel technique (Figs. 1 and 7).

Intra-examiner reproducibility

Five patients, each showing ten teeth (single and multi-rooted) with probing depths > 6 mm on at least one aspect of each tooth, were used to calibrate the examiner. The examiner evaluated the patients on two separate occasions, 48 h apart. Calibration was accepted if measurements at baseline and at 48 h were similar to the millimeter at > 90% level.

Surgical procedure

Under local anesthesia a midcrestal incision was placed on the edentulous ridge and continuing with an intrasulcular incision at the neighboring periodontally compromised teeth. A full thickness flap was raised to exposed the intrabony defect. Close attention was paid to avoid any tension in the flap. If necessary, a vertical releasing incision was performed at a minimal distance of two to three teeth from the missing ones. After removal of granulation tissue, the roots were scaled and planed by means of hand and ultrasonic instruments (Fig. 2). During surgery, the follow-

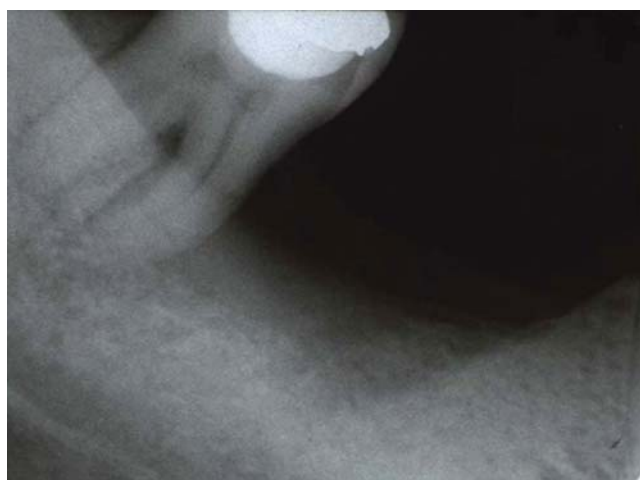


Fig. 1 The preoperative radiograph revealed a deep intrabony defect and a resorbed alveolar ridge

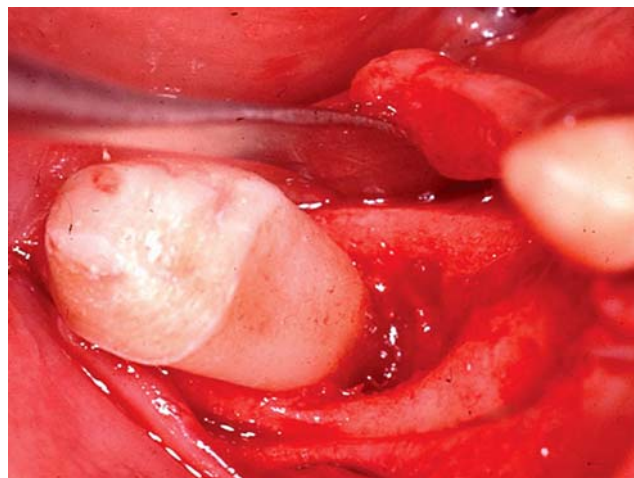


Fig. 2 The intraoperative situation revealed a deep intrabony defect mesially at tooth 47 and a resorbed alveolar ridge

ing measurements were made: (1) distance from the CEJ to the bottom of the defect (CEJ-BD) and distance from the CEJ to the most coronal extension of the alveolar bone crest (CEJ-BC). The intrabony component (INTRA) of the defects was defined as CEJ-BD–CEJ-BC, (2) the mean distance from the CEJ to the bottom most point of the defect (CEJ-BD). The mean distance from the CEJ to the most coronal extension of the alveolar bone crest (SUPRA) was calculated as CEJ-BD-INTRA.

Subsequently, an appropriate-sized connective tissue graft was removed from the palatal mucosa between the first molar and the canine by using a slight modification of the single incision technique [10, 16]. An approximately 2–3 mm wide epithelial collar was maintained on the occlusal side of the graft. The harvested tissue was trimmed and sutured (5.0 non-absorbable polyamide monofilament, Braun AG, Tuttlingen, Germany) to the inner surface of the lingual/palatal flap. The oral gingival flap overlapped the de-epithelized 4–6 mm wide part of the graft in such a way that only the epithelial collar was left uncovered (Fig. 3). The periodontal defect and the edentulous ridge were overfilled vertically and horizontally with NBM (Bio-Oss®, particle size 0.25 to 1.0 mm, Geistlich AG, Wolhusen, Switzerland; Fig. 4).

After grafting, a biodegradable collagen membrane of porcine origin (Bio-Gide®, Geistlich AG, Wolhusen, Switzerland) was trimmed and adapted over the NBM using a double-layer technique to retard the resorption of the barrier [3] (Fig. 5). Finally the buccal mucoperiosteal and the oral “CTG reinforced” flaps were re-positioned by avoiding any extra flap mobilizing procedure and tension and closed with vertical mattress sutures. The gingival surface of the temporary restoration was reduced, finished, and polished by taking into consideration the modified ridge height and width.

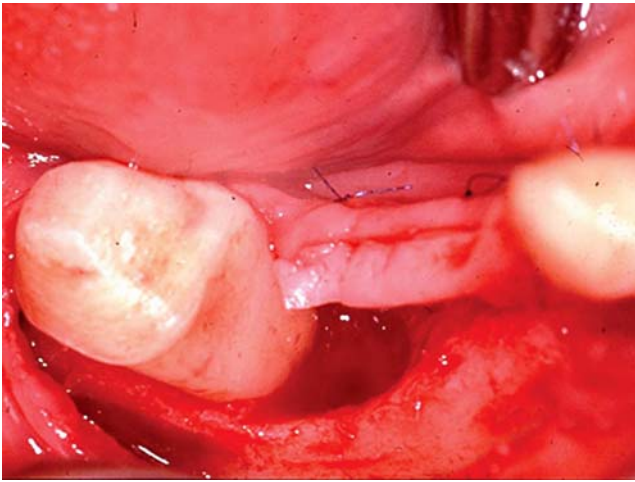


Fig. 3 A subepithelial connective tissue graft was sutured to the oral flap

Maintenance care

The postoperative care consisted of 0.2% chlorhexidine rinses twice a day for 4 weeks. Sutures were removed 10–14 days after surgery. Mechanical plaque control was carried out, and patients were recalled for professional tooth cleaning once a week for the first month and once a month for the period until implant placement. Neither subgingival instrumentation nor probing was performed during this period.

Reentry, biopsy procedures, and implant placement

At 11–20 months (mean, 13.9 ± 3.9 months), midcrestal and intrasulcular incisions were performed under local anesthesia, and mucoperiosteal flaps were raised buccally and lingually. Flap elevation was limited only to allow a direct view onto the horizontal dimension of the augmented ridge. The vertically and horizontally enlarged alveolar ridge displayed a similar clinical appearance to the neighboring bone.

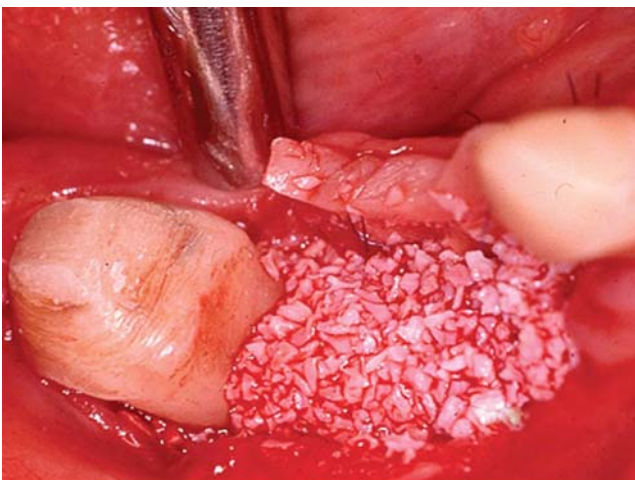

Fig. 4 The intrabony defect and the alveolar ridge were filled with NBM

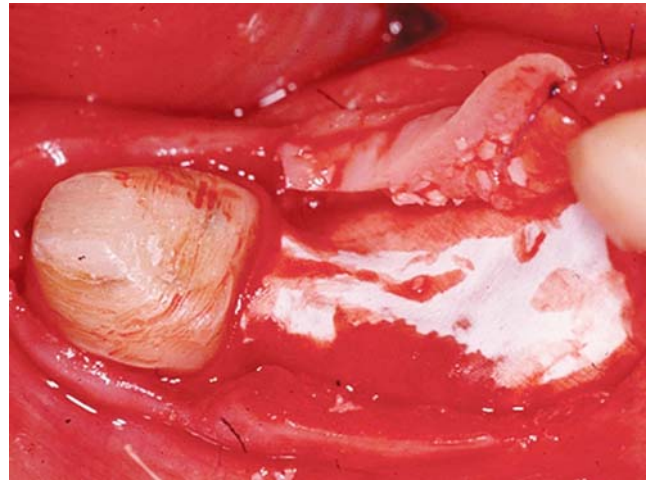


Fig. 5 A bioresorbable collagen membrane was adapted to completely cover the defects and the graft particles

The intraoperative parameters were measured and core biopsies retrieved with a trephine drill from the ridge area where implant insertion was planned.

The newly formed tissue, including also its superficial layer, was not possible to be scrapped off and appeared hard at probing and drilling. From each patient, one biopsy was removed and processed to histological evaluation. Subsequently, implants (ReplaceSelect®—Straight, Nobel Biocare, Göteborg, Sweden) were placed and the flaps closed by means of single interrupted sutures (Fig. 6).

Histologic and histomorphometric analysis

The biopsy was placed in 10% buffered formalin for fixation, decalcified in ethylenediaminetetraacetic acid, dehydrated, and embedded in paraffin. Mesio-distal sections were cut parallel to the long axes of the biopsy with

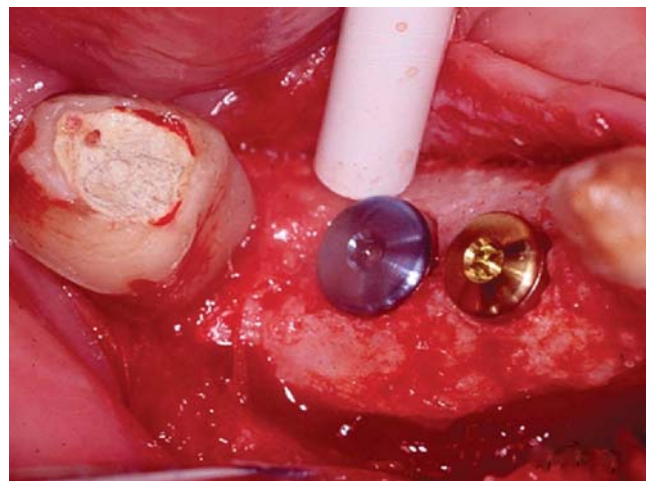


Fig. 6 The reentry revealed a complete fill of the intrabony component and a substantial improvement in vertical dimension of the alveolar ridge, thus allowing implant insertion. During preparation of the implant, bed core biopsies were retrieved and submitted for histological analysis

Table 2 Clinical results (in mm)

Patient no.	Tooth no.	PD reduction	Δ GR*	CAL gain	INTRA gain	SUPRA gain	Position of implant fixture (tooth no.)	Implant size
1	27	5.0	0.7	4.3	5.0	0.7	25 26	4×13 4×11.5
2	22	4.0	1.0	3.0	2.3	0.3	21	4.3×11.5
3	35	6.3	-2.3	8.7	4.3	5.3	36 37	4.3×13 4.3×11.5
4	44	2.3	-1.7	4.0	1.3	1.7	45 46	4.3×10 4.3×10
5a	44	3.0	-0.7	3.7	2.7	1.7	45	4.3×11.5
5b	47	1.3	0.3	1.0	1.3	0.7	46	4.3×11.5
6	13	3.3	-2.3	5.7	3.0	3.3	14	4.3×13
7a	32	3.7	0.3	3.3	0.3	2.3	31	3.75×13
7b	43	3.7	0.7	3.0	1.0	1.0	41	4×13
8	48	5.7	-0.7	6.3	6.3	0.7	46 47	4.3×10 5×10
Mean±SD (mm)		3.8±1.7	-0.5±1.4	4.3±2.2	2.8±2.1	1.8±1.8		
P value		<0.0001	n.s.	<0.0001	<0.001	<0.005		

the microtome set at 8 μ m and subsequently stained with hematoxylin and eosin, toluidine blue, and Goldner's trichrome stain. For the histological analysis, three sections 100 μ m apart and representing the central part of the biopsy were selected.

Tissue reactions, quantity of new bone formation around the graft particles, microscopic structure of the bone/graft interface, and graft bioresorption were histologically assessed.

Photomicrographs were taken with microscope (Olympus BH₂, Olympus Optical, Melville, NY, USA) equipped with a digital camera (Olympus DP50, Olympus Optical).

Histomorphometric analysis

Measurements on the histological sections and image processing (AnalySIS® Soft Imaging System, Münster, Germany) were performed by a calibrated examiner with a computerized technique (Windows XP operating system, Microsoft, Redmond, OR, USA). Automatic calculation of graft and bone areas as a percentage of the total area was achieved via pixel counting. The reproducibility of the measurements was tested by measuring the abovementioned parameters twice within a 2-week interval on the corresponding sections from six randomly selected specimens. The differences between the two sets of measurements were tested with the Wilcoxon test for paired observations.

Statistical analysis

The statistical analysis was performed with a commercially available statistical program (SPSS® 13.0, SPSS, Chicago, IL, USA). Mean values and standard deviations (mean±SD) for the clinical variables were calculated based on the

patient as the statistical unit. Differences between baseline clinical data and those recorded at second surgery were analyzed using the paired *t* test.

Results

Clinical results

The baseline clinical and intraoperative parameters are shown in Table 1. The postoperative healing was uneventful in all patients. At 4–5 days after surgery, the epithelial collar of the free connective tissue graft became white and

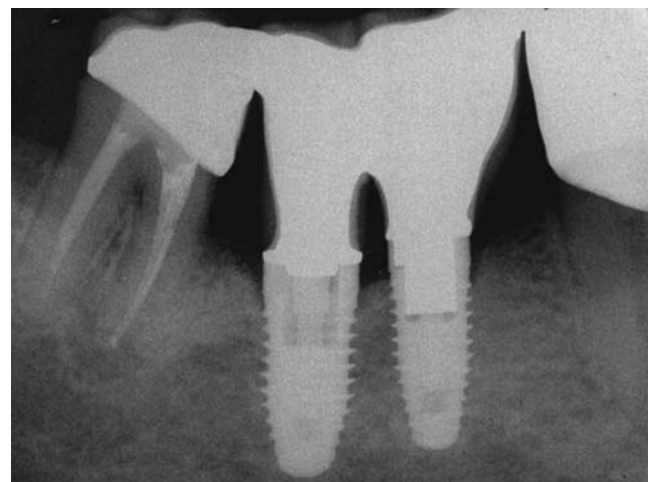


Fig. 7 The intraoral radiograph revealed a complete fill of the intrabony defect and a significant improvement in vertical dimension of the resorbed ridge. At 2 years after insertion of the implants, a stable periimplant condition can be observed

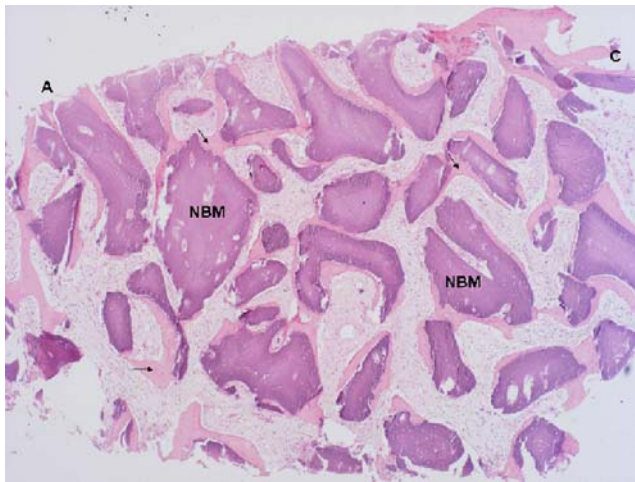


Fig. 8 Photomicrograph depicting the core biopsy retrieved from the vertically reconstructed ridge. Presence of osteoid tissue (arrows) around the NBM particles is evident throughout the entire length of the biopsy. *A* Apical part of the biopsy, *C* coronal part of the biopsy (original magnification $\times 2.5$; Goldner's trichrome staining)

was followed by a gradual desquamation of the epithelial layer. At 3–4 weeks, the free connective graft displayed the appearance of keratinized gingiva. No membrane exposure was observed in any of the eight patients. The clinical measurements revealed a mean PD reduction from 6.2 ± 1.7 to 2.4 ± 1.0 mm ($p < 0.0001$). The mean GR improved from 2.0 ± 1.7 mm at baseline to 1.6 ± 1.4 mm (n.s.). Mean CAL improved from 8.3 ± 2.6 to 4.0 ± 1.7 mm ($p < 0.0001$). Mean CEJ-BD decreased from 9.2 ± 3.2 to 4.7 ± 1.5 mm, while INTRA measured 3.0 ± 2.1 mm at baseline and it was almost completely reduced (0.2 ± 0.5 mm) at reentry. SUPRA decreased from 6.3 ± 1.9 to 4.5 ± 1.4 mm at reentry. Table 2 summarizes the differences between the data at baseline and after healing period. Improvements in clinical parameters (PD, CAL, INTRA, and SUPRA) were found to be statistically highly significant ($p < 0.0001$).

The newly formed hard tissue provided primary stability for all inserted implants (Figs. 6 and 7). No implants were lost during the entire study period of 2 years.

Histologic and histomorphometric results

In all biopsies, the majority of NBM particles were surrounded by newly formed bone and osteoid tissue (Fig. 8). Bone formation was also observed in the holes of the porous

graft particles (Fig. 8). The newly formed bone was a mixed type including both woven bone with irregular collagenous bundles and more matured lamellar bone structures. Bone remodeling with osteoblastic activity at one side and osteoclastic bone resorption at the other were observed in the vicinity of graft particles. The bone/graft interface showed accidentally concave surfaces with multinuclear osteoclastic cells. All sample biopsies contained mineralized material. The border between the pre-existing and the newly formed bone was recognized due to the presence of NBM particles. Mean new bone and mean graft (NBM) measured $17.8 \pm 2.8\%$ and $32.1 \pm 8.3\%$, respectively (Table 3). Most of the newly formed bone appeared to be continuous with the host bone at the recipient site. In the more peripheral areas of the graft, a new bone could also be detected. Such foci of de novo bone formation were found to be in direct contact with the NBM particles. In these areas demonstrating new bone formation, osteoclast-like cells could be observed on the surface of the NBM particles.

Discussion

The findings of this study have shown that reconstructive surgery with the described surgical technique resulted in clinically and statistically significant PD reduction and CAL gain and in complete resolution of the intrabony defects. At the same time, the treatment resulted also in vertical reconstruction of the resorbed ridge, which enabled insertion of endosseous implants. The clinical results obtained in the intrabony defects are in agreement with previous reports [4, 17, 23, 25, 28, 31]. In the mentioned studies, treatment with NBM+GTR resulted in a mean CAL gain varying from 3.2 to 4.1 mm, respectively. Slight variations in terms of CAL gain might be explained by differences in initial PD and INTRA values. It is well known that the CAL gain after regenerative periodontal therapy is strongly dependent upon initial PD and INTRA values (i.e., the deeper the initial defect, the greater the PD reduction and CAL gain) [30]. One important finding in the present study is the minimal change or even improved GR values following the employed surgical technique. This finding is different from those reported previously following regenerative surgery with NBM+GTR. While in all

Table 3 Histomorphometric results

Patient no.	1	2	3	4	5	6	7	8	Mean \pm SD
Position of core biopsy (tooth no.)	25	21	37	46	46	14	41	46	
Bone area ^a	21.6	14.2	20.6	18.9	15.9	14.7	16.7	19.7	17.8 \pm 2.8
Graft area ^a	27.7	28.1	25.5	34.5	37.1	20.4	46.5	37.0	32.1 \pm 8.3
Total hard tissue area (bone+graft area) ^a	49.3	42.3	46.1	53.4	53.0	35.1	63.2	56.7	49.9 \pm 8.8

^a In percentage

eight cases, mean GR showed either a minimal change or even an improvement compared to baseline (i.e., mean GR measured -0.5 ± 1.4 mm), in all previous studies, mean GR showed a marked increase varying from 0.3 to 1.4 mm [4, 17, 23, 25, 28, 31]. On the other hand, this finding should be interpreted with caution, since due to the limitations related to standardization of clinical measurements, the gain reported as SUPRA may not necessarily represent the gain in the middle of the ridge but what was recorded on the proximal surface of the involved teeth. Furthermore, randomized controlled clinical studies with a more accurate way of standardizing the clinical measurements are needed to confirm this result. Nevertheless, the positive outcome in terms of postoperative soft tissue changes could be explained by the location of the teeth with intrabony defects (i.e., all treated teeth were located at an edentulous ridge area, thus allowing optimal flap management and complete wound closure) and the use of CTG. The use of CTG has probably enabled tension-free closure of the wound area by avoiding large periosteal releasing incisions, which may compromise the blood supply of the flap. These factors coupled with the fact that the defects were filled with NBM and then covered with a GTR barrier have probably significantly influenced space provision and wound stability. Recent data have indicated that one of the main roles by which a biomaterial supports the regeneration process is related to its space-provision capacity [21, 22]. This view seems to be supported by the complete fill of the intrabony defects and by the substantial vertical improvements of the resorbed alveolar ridge (i.e., 1.8 ± 1.8 mm) measured at reentry in all eight cases. The histologic evaluation of the core biopsies revealed, in all eight cases, NBM particles surrounded by new bone. These histologic findings are in line with those made previously in sinus elevation and alveolar ridge augmentation studies [1, 32, 34]. The present histomorphometric results indicated a mean new bone formation of $17.8\pm 2.8\%$ of the total area. These values are somewhat higher compared to the those reported by others (i.e., $14.7\pm 5.0\%$) in maxillary sinus augmentation procedure where grafting was performed with NBM mixed with venous blood [32]. On the other hand, the histomorphometric results from another study revealed a mean new bone formation of $22.6\pm 11.0\%$ and a mean proportion of graft material of $30.5\pm 4.6\%$ after reconstructive surgery of maxillary alveolar ridge defects with NBM+GTR, which are higher than the values obtained in the present study [34]. In another study, severely resorbed alveolar ridges were treated with NBM and a configured titanium mesh [1]. At 9 months after surgery, the metal mesh was removed and root-form, screw-type implants were placed in the augmented area. The hard tissue measurements after metal mesh removal and implant insertion revealed a bone height gain varying between 4

and 6 mm (mean, 5.2 ± 0.79 mm) and a mean bone fill of $81.2\pm 7.98\%$). When comparing the findings from the present study to those mentioned previously, it has to be pointed out that the present study has evaluated a technique for simultaneous reconstruction of intrabony periodontal defects and of the resorbed alveolar ridge, while in the previous reports, the treated bony defects were located in edentulous areas. It is well known that vertical ridge augmentation has been demonstrated with various treatment protocols, while successful outcomes after regenerative therapy at periodontal supraalveolar defects are still unpredictable and limited to single case reports [1, 7, 8, 13, 14, 26, 27]. On the other hand, it should be kept in mind that although the present results are positive, they need to be confirmed in further randomized controlled clinical studies including a sufficient number of patients and defects to allow statistically and clinically ascertained conclusions.

Conclusion

Within their limits, the present findings indicate that the described surgical approach may be successfully used in certain clinical cases to simultaneously treat intrabony defects and to reconstruct the resorbed alveolar ridge.

Acknowledgments The authors would like to thank Professor Tibor Deutsch (Department of Information and Medical Technology, Faculty of Health Care, Semmelweis University, Budapest, Hungary) for his great help with the statistical analysis.

Open Access This article is distributed under the terms of the Creative Commons Attribution Noncommercial License which permits any noncommercial use, distribution, and reproduction in any medium, provided the original author(s) and source are credited.

References

1. Artzi Z, Dayan D, Alpern Y, Nemcovsky CE (2003) Vertical ridge augmentation using xenogenic material supported by a configured titanium mesh: clinicohistopathologic and histochemical results. *Int J Oral Maxillofacial Implants* 18:440–446
2. Berglundh T, Lindhe J (1997) Healing around implants placed in bone defects treated with Bio-Oss. An experimental study in the dog. *Clin Oral Implants Res* 8:117–124
3. Buser D, Martin W, Belser UC (2004) Optimizing esthetics for implant restorations in the anterior maxilla: anatomic and surgical considerations. *Int J Oral Maxillofac Implants* 19(Suppl):43–61
4. Camargo PM, Lekovic V, Weinlaender M, Nedic M, Vasilic N, Wolinsky LE, Kenney EB (2000) A controlled re-entry study on the effectiveness of bovine porous bone mineral used in combination with a collagen membrane of porcine origin in the treatment of intrabony defects in humans. *J Clin Periodontol* 27: 889–896
5. Camelo M, Nevins M, Schenk R, Simion M, Rasperini G, Lynch S, Nevins M (1998) Clinical, radiographic, and histologic

- evaluation of human periodontal defects treated with Bio-Oss® and Bio-Gide. *Int J Periodontics Restor Dent* 18:321–331
6. Camelo M, Nevins ML, Lynch S, Schenk RK, Simion M, Nevins M (2001) Periodontal regeneration with an autogenous Bone-Bio-Oss composite graft and a Bio-Gide membrane. *Int J Periodontics Restor Dent* 21:109–119
 7. Canullo L, Trisi P, Simion M (2006) Vertical ridge augmentation around implants using e-PTFE titanium-reinforced membrane and deproteinized bovine bone mineral (Bio-Oss): a case report. *Int J Periodontics Restor Dent* 26:355–361
 8. Dragoo MR, Sullivan HC (1973) A clinical and histological evaluation of autogenous iliac bone grafts in humans. I. Wound healing 2 to 8 months. *J Periodontol* 45:599–613
 9. Hämmerle CHF, Chiantella GC, Karring T, Lang NP (1998) The effect of a deproteinized bovine bone mineral on bone regeneration around titanium dental implants. *Clin Oral Implants Res* 9:151–162
 10. Hürzeler MB, Weng D (1999) A single-incision technique to harvest subepithelial connective tissue grafts from the palate. *Int J Periodontics Restor Dent* 19:279–287
 11. Karring T, Lindhe J, Cortellini P (1997) Regenerative periodontal therapy. In: Lindhe J, Karring T, Lang NP (eds) *Clinical periodontology and implant dentistry*. Munksgaard, Copenhagen, pp 597–646
 12. Kasaj A, Willershausen B, Berakdar M, Tekyatan H, Sculean A (2006) Effect of an oily calcium hydroxide suspension on early wound healing after nonsurgical periodontal therapy. *Clin Oral Invest* 10:72–76
 13. Kassolis JD, Bowers GM (1999) Supracrestal bone regeneration: a pilot study. *Int J Periodontics Restor Dent* 19:131–139
 14. Kotschy P, Laky M (2006) Reconstruction of supracrestal alveolar bone lost as a result of severe chronic periodontitis. Five-year outcome: case report. *Int J Periodontics Restor Dent* 26:425–431
 15. Kim TS, Schenk A, Lungeanu D, Reitmeir P, Eickholz P (2007) Nonsurgical and surgical periodontal therapy in single-rooted teeth. *Clin Oral Invest* 11:391–339
 16. Lorenzana ER, Allen EP (2000) The single-incision palatal harvest technique: a strategy for esthetics and patient comfort. *Int J Periodontics Restor Dent* 20:297–305
 17. Lundgren D, Slotte C (1999) Reconstruction of anatomically complicated periodontal defects using a bioresorbable GTR barrier supported by bone mineral. A 6-month follow-up study of 6 cases. *J Clin Periodontol* 26:56–62
 18. Mellonig J (2000) Human histologic evaluation of a bovine-derived xenograft in the treatment of periodontal osseous defects. *Int J Periodontics Restor Dent* 20:19–29
 19. Nevins ML, Camelo M, Lynch SE, Schenk RK, Nevins M (2003) Evaluation of periodontal regeneration following grafting intrabony defects with Bio-Oss collagen: a human histologic report. *Int J Periodontics Restor Dent* 23:9–17
 20. Noetzel J, Ozer K, Reissbauer BH, Anil A, Rössler R, Neumann K, Kielbassa AM (2006) Tissue responses to an experimental calcium phosphate cement and mineral trioxide aggregate as materials for furcation perforation repair: a histological study in dogs. *Clin Oral Invest* 11:391–339
 21. Polimeni G, Koo KT, Qahash M, Xiropadis AV, Albandar JM, Wikesjö UM (2004) Prognostic factors for alveolar regeneration: effect of a space-providing biomaterial on guided tissue regeneration. *J Clin Periodontol* 31:725–729
 22. Polimeni G, Albandar JM, Wikesjö UM (2005) Prognostic factors for alveolar regeneration: effect of space provision. *J Clin Periodontol* 32:951–954
 23. Sculean A, Berakdar M, Chiantella GC, Donos N, Arweiler NB, Brex M (2003) Healing of intrabony defects following treatment with a bovine derived xenograft and collagen membrane. A controlled clinical study. *J Clin Periodontol* 30:73–80
 24. Sculean A, Stavropoulos A, Windisch P, Karring T, Gera I (2004) Healing of human intrabony defects following regenerative periodontal therapy with a bovine-derived xenograft and guided tissue regeneration. *Clin Oral Invest* 8:70–74
 25. Sculean A, Chiantella GC, Windisch P, Arweiler NB, Brex M, Gera I (2005) Healing of intra-bony defects following treatment with a composite bovine-derived xenograft (Bio-Oss Collagen) in combination with a collagen membrane (Bio-Gide PERIO). *J Clin Periodontol* 32:720–724
 26. Simion M (2003) Procedures used to augment the deficient alveolar ridge. In: Lindhe J, Karring T, Lang NP (eds) *Periodontology and implant dentistry*. 4th edn. Blackwell, Oxford, pp 897–914
 27. Stahl S, Froum S (1991) Healing of human suprabony lesions treated with guided tissue regeneration and coronally anchored flaps. Case reports. *J Clin Periodontol* 18:69–74
 28. Stavropoulos A, Karring T (2005) Five-year results of guided tissue regeneration in combination with deproteinized bovine bone (Bio-Oss) in the treatment of intrabony periodontal defects: a case series report. *Clin Oral Invest* 9:271–277
 29. Stratul SI, Schwarz F, Becker J, Willershausen B, Sculean A (2006) Healing of intrabony defects following treatment with an oily calcium hydroxide suspension (osteoinductive). A controlled clinical study. *Clin Oral Invest* 10:55–60
 30. Tonetti MS, Pini Prato G, Cortellini P (1996) Factors affecting the healing response of intrabony defects following guided tissue regeneration and access flap surgery. *J Clin Periodontol* 23: 548–556
 31. Tonetti MS, Cortellini P, Lang NP, Suvan JE, Adriaens P, Dubravec D, Fonzar A, Fourmouis I, Rasperini G, Rossi R, Silvestri M, Topoll H, Wallkamm B, Zybutz M (2004) Clinical outcomes following treatment of human intrabony defects with GTR/bone replacement material or access flap alone. A multicenter randomized controlled clinical trial. *J Clin Periodontol* 31:770–776
 32. Yildirim M, Spiekermann H, Biesterfeld S, Edelhoff D (2000) Maxillary sinus augmentation using xenogenic bone substitute material Bio-Oss in combination with venous blood. A histologic and histomorphometric study in humans. *Clin Oral Implants Res* 11:217–229
 33. Zitzmann NU, Schärer P, Marinello CP (1999) Factors influencing the success of GBR. Smoking, timing of implant placement, implant location, bone quality and provisional restoration. *J Clin Periodontol* 26:673–682
 34. Zitzmann NU, Schärer P, Marinello CP, Schüpbach P, Berglundh T (2001) Alveolar ridge augmentation with Bio-Oss: a histologic study in humans. *Int J Periodontics Restorative Dent* 21:289–295