

Bilateral tuberculous psoas abscess

Mouhcine Miloudi^{1,*}, Lamiae Aarsalane¹, Anas Kharrab², Youssef El Kamouni¹ and Said Zouhair¹

Abstract

The unilateral psoas abscess is a rare disease that is often caused by common germs, including *Staphylococcus aureus*. Tuberculous origin and bilateral involvement are even rarer, especially in developed countries. It may be primary or secondary to a neighbourhood focus. We report a case of bilateral tuberculous abscess of psoas in an immunocompetent patient secondary to spondylodiscitis.

INTRODUCTION

Psoas muscle abscess is a relatively rare condition that is difficult to diagnose because of the polymorphism and non-specificity of clinical signs. It may be primary or secondary to intra-retroperitoneal or osteo-articular infection. The most frequently found germs are *Staphylococcus aureus* in primary abscesses and *Escherichia coli* [1] in secondary abscesses. Tuberculous origin is rare, especially in developed countries, and it is often unilateral; bilateral involvement is even rarer and mainly occurs in immunocompromised subjects [2]. We report a case of bilateral tuberculous abscess of psoas secondary to spondylodiscitis in an immunocompetent subject.

CASE PRESENTATION

The patient was 46 years old and had no pathological history, but 2 months before the consultation had inflammatory-type lumbar pain that developed in the context of deterioration of general condition. The interrogation revealed a possibility of tuberculous contagion 6 months before, and the clinical examination revealed lumbar pain on palpation and spinal stiffness without neurological attack. Abdominal–pelvic computed tomography (CT) showed spondylodiscitis at the level of the 10th, 11th and 12th dorsal vertebrae and the first lumbar vertebra with bilateral abscess collections at the expense of both psoas muscles (Fig. 1). The chest X-ray was normal. The biological assessment showed a C-reactive protein (CRP) level of 58 mg l⁻¹ and a sedimentation rate of 60 mm/first hour, while the HIV serology was negative and the interferon gamma release assay (IGRA) test (Quantiféron) was positive.

The patient benefited from scanned/guided drainage and the pus brought back was subjected to bacteriological study (culture on blood agar and chocolate agar incubated at 37 °C in an aerobic and anaerobic atmosphere). This culture remained sterile after 4 days of incubation. For direct examination after Ziehl–Armand staining in search of acid-fast bacilli, the result was negative. The real-time PCR-based *Mycobacterium tuberculosis* test on the GeneXpert MTB/RIF system (which also makes it possible to detect *rpoB* gene mutations associated with rifampicin resistance), the system did not detect any mutations, so the strain was sensitive to rifampicin. A culture grown on solid Lowenstein–Jensen medium developed a month later (Fig. 2), while a culture grown in liquid medium (VersaTREK broth Myco Broth) and incubated in the VersaTREK automaton, whose technology is based on the detection of oxygen levels consumed by the mycobacteria, became positive after 20 days. When the susceptibility of the isolated strain to rifampicin, isoniazid and ethambutol was studied using the liquid dilution method on the versaTREK automaton, the strain was found to be sensitive to these antibiotics.

Following these results, the patient was put on rifampin, isoniazid, ethambutol and pyrazinamide for a duration of 2 months and rifampin and isoniazid for 10 months. The evolution was favourable, with weight recovery, loss of pain and decrease in CRP and sedimentation rate.

DISCUSSION

Psoas abscess is a rare entity; the annual global incidence was estimated at 12 cases in 1992 [3], although the current incidence is unknown. This infection can be primitive by

Received 24 January 2020; Accepted 25 March 2020; Published 18 May 2020

Author affiliations: ¹Department of Microbiology, Avicenne Military Hospital, Marrakech, Morocco; ²Departement of Rheumatology, Avicenne Military Hospital, Marrakech, Morocco.

*Correspondence: Mouhcine Miloudi, miloudi_mouhcine@yahoo.fr

Keywords: psoas abscess; spondylodiscitis; tuberculosis.

Abbreviations: CRP, C-Reactive Protein; IGRA, Interferon Gamma Release Assay.

000135 © 2020 The Authors



This is an open-access article distributed under the terms of the Creative Commons Attribution License.

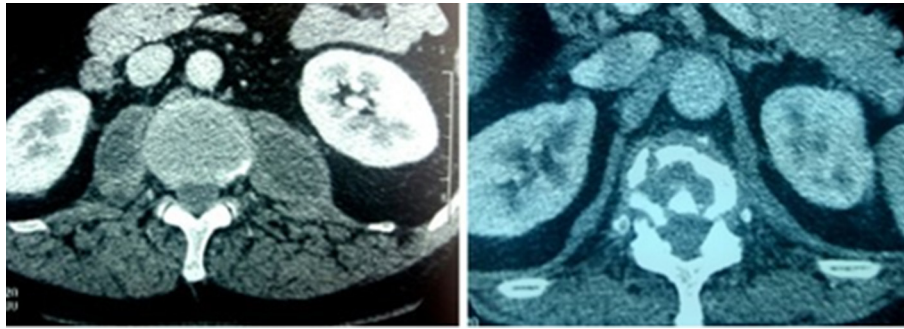


Fig. 1. Abscess of both psoas with spondylodiscitis on a cross-section (CT).

haematogenous dissemination from a distant focus, or secondary to retro, intraperitoneal (digestive, renal) or osteoarticular infection. Spondylodiscitis may be responsible for psoas abscess in 10% of cases [4]. The offending

organisms are often *S. aureus* and *Enterobacteriaceae* (*Escherichia coli*, *Klebsiella pneumoniae*), and tuberculous origin remains exceptional in developed countries but is still relevant in endemic countries such as Morocco, where tuberculosis is a major public health problem, with an incidence of 36000 cases in 2017.

Osteoarticular tuberculosis represents 3–5% of cases of tuberculosis and 15% of cases of extrapulmonary tuberculosis. It affects all segments, but lumbar spine involvement remains most common [5]. Psoas involvement in spondylodiscitis is seen in 5% of cases [6]; it is often unilateral and bilateral involvement is rare and mainly occurs in immunocompromised subjects. The clinical picture is insidious and nonspecific, which leads to delayed diagnosis and treatment; the fever triad, lumbar pain and hip stiffness are present in <50% cases [7].

CT is the key examination for positive diagnosis; the biological signs are not very contributive and show an inflammatory syndrome and confirmation is achieved by bacteriological study of drainage product without forgetting to search for *M. tuberculosis*, which must be systematic in our context where tuberculosis is still endemic.

The treatment consists of percutaneous or surgical drainage combined with antituberculous treatment for a minimum of 12 months, combining rifampicin, isoniazid, ethambutol and pyrazinamide for 2 months, followed by 10 months of rifampicin and isoniazid.



Fig. 2. Beige verrucous colonies of *M. tuberculosis* on Lowenstein-Jensen medium.

Funding information

This work received no specific grant from any funding agency.

Conflicts of interest

The authors declare that there are no conflicts of interest.

Ethical statement

Written consent has been provided by the patient for the publication of this case report and any accompanying image.

References

1. Miloudi M, Belabbes S, Sbaai M, Kamouni YE, Arsalane L et al. Psoas abscess due to *Candida tropicalis*: a case report. *Ann Biol Clin* 2018;76:571–573.

2. Goni V, Thapa BR, Vyas S, Gopinathan NR, Rajan Manoharan S et al. Bilateral psoas abscess: atypical presentation of spinal tuberculosis. *Arch Iran Med* 2012;15:253–256.
3. Gruenwald I, Abrahamson J, Cohen O. Psoas abscess: case report and review of the literature. *J Urol* 1992;147:1624–1626.
4. Audia S, Maetha B, Grappin M, Duong M, Buisson M et al. Les abcès pyogènes secondaires du psoas : propos de 06 cas et revue de la littérature. *Rev. Med interne* 2006;27:828–835.
5. Rafiqi K, Yousri B, Arihi M, Bjitro C, Aboumaarouf M et al. Unusual locations of osteoarticular tuberculosis in children: a report of 12 cases. *Orthop Traumatol Surg Res* 2013;99:347–351.
6. Özgüler M, Özden M. a rare case Bilateral psoas abscess due to tuberculosis and pyogenic superinfections. *ARC Journals of Immunology and Vaccines* 2016;1:23–27.
7. Kramer L, Geib V, Evison J, Altpeter E, Basedow J et al. Tuberculous sacroiliitis with secondary psoas abscess in an older patient: a case report. *J Med Case Rep* 2018;12:237.

Five reasons to publish your next article with a Microbiology Society journal

1. The Microbiology Society is a not-for-profit organization.
2. We offer fast and rigorous peer review – average time to first decision is 4–6 weeks.
3. Our journals have a global readership with subscriptions held in research institutions around the world.
4. 80% of our authors rate our submission process as 'excellent' or 'very good'.
5. Your article will be published on an interactive journal platform with advanced metrics.

Find out more and submit your article at microbiologyresearch.org.