

Available online at www.sciencedirect.com

ScienceDirect

journal homepage: www.elsevier.com/locate/radcr

Case Report

Heparin-bonded stent graft placement for treatment of massive epistaxis from ruptured radiation-induced internal carotid artery pseudoaneurysm: A case report[☆]

Bing Yuan, MD^{a,†}, Hai-nan Xin, MD^{a,†}, Kai Yuan, MD^a, Jin-long Zhang, MD^b,
Feng Duan, MD^{a,*}, Mao-Qiang Wang, MD^{a,*}

^aDepartments of Interventional Radiology, The First Medical Center of Chinese PLA General Hospital, Beijing, 100853, P.R. China

^bDepartment of Radiology, Beijing Tongren Hospital, Capital Medical University, Beijing, 100730, P.R. China

ARTICLE INFO

Article history:

Received 8 March 2022

Revised 14 March 2022

Accepted 20 March 2022

Keywords:

Arterial intervention

Endovascular treatment

Heparin-bonded stent graft

Internal carotid pseudoaneurysm

Radiotherapy

Stent graft

ABSTRACT

Rupture of an internal carotid artery (ICA) pseudoaneurysm is a rare but life-threatening complication of irradiation therapy for a nasopharyngeal carcinoma (NPC). A 36-year-old man had a history of NPC treated with radiotherapy 8 years previously. He was admitted to the hospital because of severe repetitive epistaxis with hemodynamically instability. An emergent angiography showed the left ICA pseudoaneurysm at the petrous portion (C2 segment). The patient was successfully treated by a new-generation heparin-bonded stent graft without any complication. Emergent stent graft placement is effective in stopping hemorrhage and is therefore a life-saving intervention. Long-term follow-up is necessary to look out for delayed post-treatment complications.

© 2022 The Authors. Published by Elsevier Inc. on behalf of University of Washington.

This is an open access article under the CC BY-NC-ND license (<http://creativecommons.org/licenses/by-nc-nd/4.0/>)

Introduction

Rupture of an internal carotid artery (ICA) pseudoaneurysm is an uncommon, life-threatening complication in patients with radiation therapy for nasopharyngeal carcinoma (NPC) that requires emergency treatment [1,2]. Since these aneurysms

commonly occur at the petrous and laceral carotid artery, they are rarely amenable to surgical clipping. Therefore, the endovascular intervention is the preferred treatment [3,4]. Currently, various endovascular options, including coil embolization with or without stents, covered stents or stent-grafts, are available for the treatment of ICA pseudoaneurysm. However, each technique has some limitations [5,6].

[☆] Competing Interests: There is no conflict of interest.

* Corresponding authors.

E-mail addresses: duanfeng@vip.sina.com (F. Duan), wangmq@vip.sina.com (M.-Q. Wang).

[†] Bing Yuan, Hai-nan Xin, contributed equally to this work as the first author.

<https://doi.org/10.1016/j.radcr.2022.03.070>

1930-0433/© 2022 The Authors. Published by Elsevier Inc. on behalf of University of Washington. This is an open access article under the CC BY-NC-ND license (<http://creativecommons.org/licenses/by-nc-nd/4.0/>)

Here, we report a case of rupture of the left ICA pseudoaneurysm after irradiation therapy for NPC, that was successfully treated by a new-generation heparin-bonded stent graft without any complication.

Case report

A 36-year-old man was transferred to our hospital with severe repetitive epistaxis that had been occurring for 1 week. He had a history of radiotherapy (a total dose of 64 Gy) for nasopharyngeal cancer 8 years previously. His tracheostomy was performed at other hospital. On admission to the emergency department, physical examination showed a blood pressure of 98/68 mmHg, pulse rate of 145 beats per minute, and nasal bleeding. Blood test results were normal, except values for hemoglobin (Hb) (6.8 g/dL), platelet count (87,000/ μ L), prothrombin time (17.7 s), and plasma fibrinogen (1.3 g/L). Nasoendoscopy by an otorhinolaryngologist revealed active oozing of blood from the nasopharynx with no evidence of NPC recurrence.

Despite performing anterior and posterior nasal packing, approximately 500 mL of blood discharged from his mouth and nasal cavity 3 h later. Wadding was compressed, but massive oral and nasal bleeding emerged again 10 h later. His blood pressure dropped to 85/45 mmHg and pulse rate rose to 155 beats per minute. The patient was stabilized by continuous oxygen and massive intravenous serum infusion.

Under local anesthesia with 5 mL 2% lidocaine, an emergent angiography was performed. A pseudoaneurysm approximately 7 mm \times 8 mm in size with irregularly shape was identified in the left petrous portion (C2 segment) of the ICA (Fig. 1).

As the bleeding was repetitive and massive, we decided to use stent-graft placement.

The patient did not have systemic heparinization since she was having massive bleeding and hemodynamically instability. An 8-French guiding sheath (Cordis Corporation, Miami Lakes, Florida) was introduced into the left common carotid artery through the right femoral approach, over a 0.035-inch guidewire. A 260 cm long 0.035-inch guidewire was then placed into the left ICA, with the distal end located at the left middle cerebral artery. A 5 \times 25-mm heparin-bonded stent graft (Viabahn Endoprosthesis with heparin bioactive surface; W. L. Gore & Associates, Flagstaff, Ariz) was then placed over the exchange wire under road-map guidance and was deployed across the corresponding segment with pseudoaneurysm. Angiography immediately after the procedure revealed total obliteration of the pseudoaneurysm (Fig. 2). The patient became hemodynamically stable and was discharged from the intensive care unit 1 day after the procedure. Antiplatelet agents were not given before and after the procedure. No further hemorrhage was noted.

Three-month follow-up CT angiography showed patency of the left ICA with no pseudoaneurysm depicted (Fig. 3). No sign of infarct was identified at the left cerebral hemisphere. No recurrent hemorrhage was reported on follow-up for 6 months. No evidence of neurologic deficit was found.

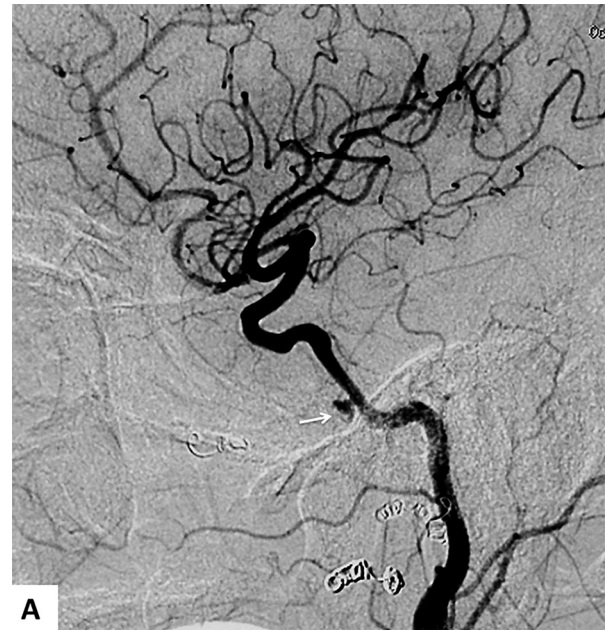


Fig. 1 – Digital subtraction angiography shows a pseudoaneurysm at the petrous portion of the left internal carotid artery (white arrow).

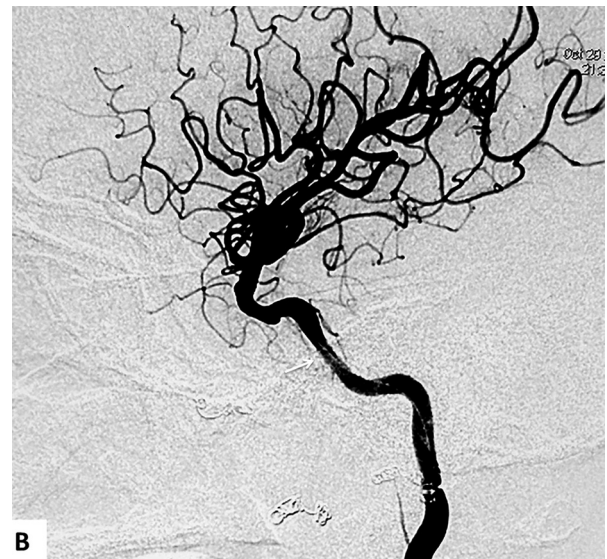

Fig. 2 – Digital subtraction angiography immediately after stent graft placement shows total obliteration of the pseudoaneurysm with patency of ICA (white arrow).

Discussion

The etiology of ICA pseudoaneurysm formation is believed to be multifactorial. Radiation damage is one important factor [1]. Subclinical infection from osteoradionecrosis of the skull base may also contribute to the formation [1,2]. Those with a second course of radiotherapy have higher radiation damage to surrounding tissue and are more prone to skull base oste-

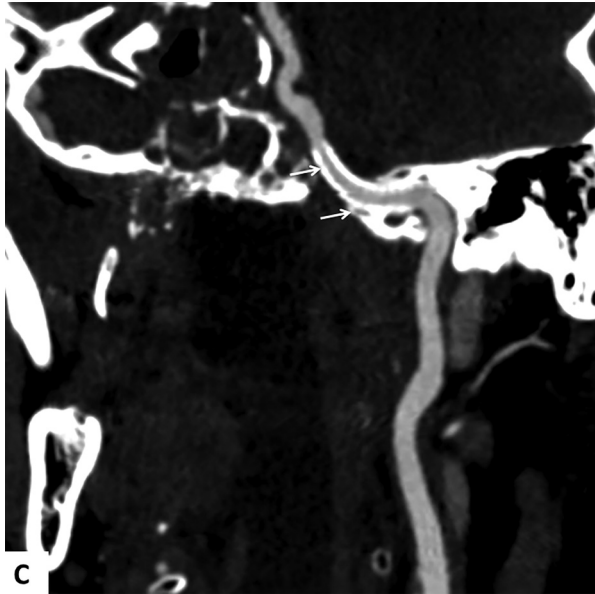


Fig. 3 – Follow-up CT angiography at 3 months after the stent graft placement shows patency of the left ICA with no pseudoaneurysm depicted (white arrows).

oradionecrosis. Although the incidence is low, this can be a potentially life-threatening complication.

Emergency surgical ligation has traditionally been the only therapeutic maneuver available for a rupture of ICA pseudoaneurysm. However, the mortality and morbidity rates of surgical ligation for acute hemorrhage patients are very high [2,4]. Moreover, the location of the pseudoaneurysm at the skull base made surgical treatment less possible.

Recently, endovascular treatment has provided an effective way to control the bleeding from ICA pseudoaneurysm [4–6]. This method mainly includes two approaches: one is embolizing the vessel with coils, and the other is preserving the vessel by stent, to cover the affected wall [3–5]. The use of coil embolization with or without stents have been advocated for the treatment of pseudoaneurysm [5–7]. However, the radiation-induced pseudoaneurysm differs from other aneurysms because there is no true wall. The surrounding osteonecrotic bone cannot offer enough support to the artery and pseudoaneurysm. Even initially the pseudoaneurysm could be obliterated, progressive enlargement of the pseudoaneurysm and re-bleeding may occur during follow-up [8]. In addition, embolizing the ICA may lead to severe cerebrovascular events [5].

Using stent graft or covered stents, commonly with expanded polytetrafluoroethylene (ePTFE), for reconstruction of the affected ICA is a more desirable treatment option, preserving patency of the carotid artery. However, the cerebral ischemic events associated with in-stent thrombosis have been reported using the stent graft for the treatment of the ICA pseudoaneurysm [9]. Dual antiplatelet therapy is required following the stent graft placement to minimize risks of stent thrombosis and distal emboli, but this treatment increases the risk of periprocedure hemorrhage [8,10].

In the present case, the patient was in an emergency situation with active bleeding and hemodynamically instabil-

ity a new-generation heparin-bonded stent graft was chosen to treatment of the rupture of ICA pseudoaneurysm. We did not use antiplatelet agents and anticoagulation therapy before and after the interventional procedure. No thrombosis events were observed at the procedure and during the follow-up. The heparin-bonded stent graft can lower platelet deposition and reduce thrombogenicity [11]. It has been demonstrated in animal studies that immobilized heparin on ePTFE vascular grafts may reduce platelet deposition and neointimal hyperplasia [12].

Ruptured ICA pseudoaneurysm following radiotherapy of NPC is a rare but life-threatening condition presenting with massive epistaxis. After initial hemodynamic stabilization, endovascular treatment with stent-graft provides immediate homeostasis and obliteration of pseudoaneurysms. Long-term follow-up is needed to look out for delayed complications after reconstruction treatment with the stent graft.

Author contributions

Conception and design: B.Y., M.Q.W., Analysis and interpretation: B.Y., F.D., Data collection: J.L.Z., H.N.X., Writing the article: B.Y., Statistical analysis: J.L.Z., K.Y., Obtained funding: Not applicable, Overall responsibility: B.Y.

Patient Consent

The patient agreed to this case report.

REFERENCES

- [1] Wei WI, Sham JS. Nasopharyngeal carcinoma. *Lancet* 2005;365(9476):2041–54.
- [2] Wong GK, Chan KK, Yu SC, Tsang RK, Poon WS. Treatment of profuse epistaxis in patients irradiated for nasopharyngeal carcinoma. *ANZ J Surg* 2007;77(4):270–4.
- [3] Farivar BS, Lee DH, Khalil A, Abrol S, Flores L. Carotid blowout syndrome: endovascular management of acute hemorrhage with tapering overlapped covered stents. *Ann Vasc Surg* 2014;28(8):1934 e7-1934.e11.
- [4] Wan WS, Lai V, Lau HY, Wong YC, Poon WL, Tan CB, et al. Endovascular treatment paradigm of carotid blowout syndrome: review of 8-years experience. *Eur J Radiol* 2013;82(1):95–9.
- [5] Chan SHV, Woo YMP, Wong KSA, Chan KY, Leung KM. The angiographic and clinical outcomes of intracranial aneurysms following irradiation in patients with nasopharyngeal carcinoma: a 13-year experience and literature review. *J Neuroradiol* 2018;45(4):224–9.
- [6] He CC, Si YF, Xie YA, Yu L. Management of intractable epistaxis in patients who received radiation therapy for nasopharyngeal carcinoma. *Eur Arch Otorhinolaryngol* 2013;270(10):2763–7.
- [7] Chang FC, Luo CB, Lirng JF, Lin CJ, Lee HJ, Wu CC, et al. Endovascular management of post-irradiated carotid blowout syndrome. *PLoS One* 2015;10(10):e0139821.

-
- [8] Haas RA, Ahn SH. Interventional management of head and neck emergencies: carotid blowout. *Semin Intervent Radiol* 2013;30(3):245–8.
- [9] Wu CJ, Lin WC, Hsu JS, Han IT, Hsieh TJ, Liu GC, et al. Follow up for covered stent treatment of carotid blow-out syndrome in patients with head and neck cancer. *Br J Radiol* 2016;89(1058):20150136.
- [10] Mak CH, Cheng KM, Cheung YL, Chan CM. Endovascular treatment of ruptured internal carotid artery pseudoaneurysms after irradiation for nasopharyngeal carcinoma patients. *Hong Kong Med J* 2013;19(3):229–36.
- [11] Schaarschmidt BM, Boos J, Buchbender C, Kröpil P, Kröpil F, Lanzman RS, et al. Heparin-bonded stent graft treatment for major visceral arterial injury after upper abdominal surgery. *Eur Radiol* 2018;28(8):3221–7.
- [12] Pedersen G, Laxdal E, Ellensen V, Jonung T, Mattsson E. Improved patency and reduced intimal hyperplasia in PTFE grafts with luminal immobilized heparin compared with standard PTFE grafts at six months in a sheep model. *J Cardiovasc Surg* 2010;51(3):443–8.