

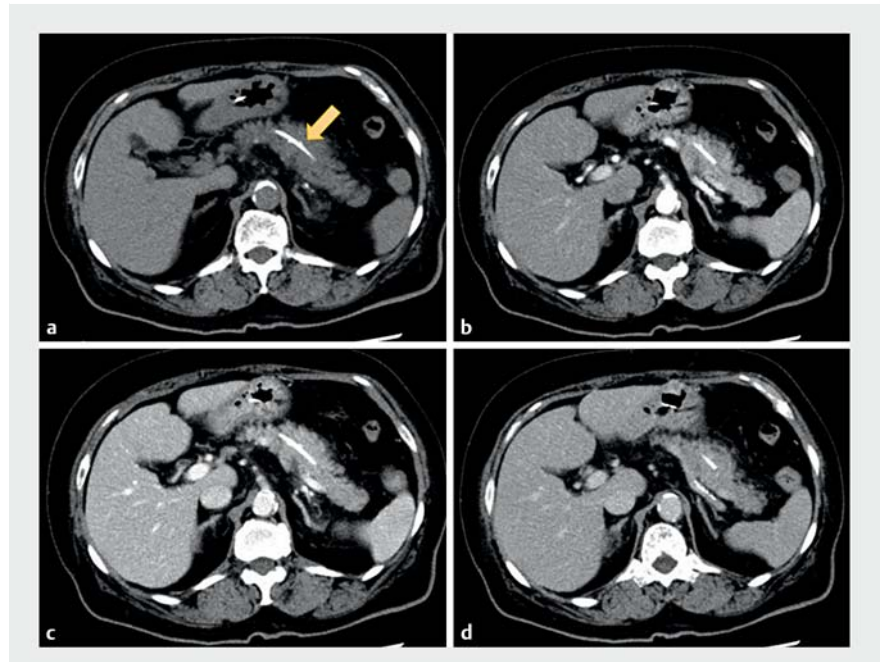
## Successful withdrawal of migrated pancreatic stent with a prototype guiding sheath

OPEN  
ACCESS

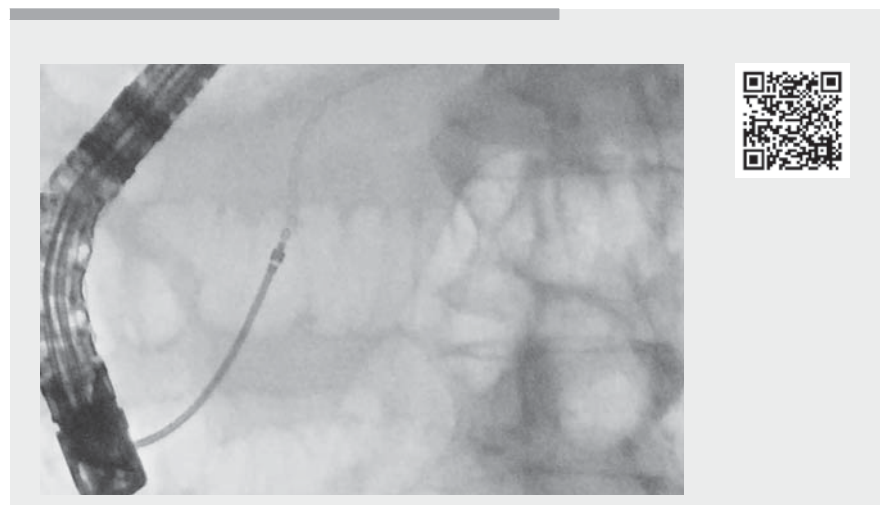
A prototype guiding sheath (UMIDAS Inc., Yokohama, Japan) is being developed for use in various procedures in pancreaticobiliary endoscopy. The guiding sheath can approach any area in the pancreaticobiliary duct that is difficult to approach through a stricture or tortuous duct and help with the insertion of various devices.

Migration of plastic stents has been reported to occur at a rate approximating 5% [1]. Various removal techniques have been published for difficult cases, including the wire-looping technique, the use of gooseneck snares and Soehendra stent retrievers, and cholangioscopy-assisted stent retrieval [2,3]. In this report, we have successfully withdrawn a migrated pancreatic plastic stent using biopsy forceps through the guiding sheath.

A 78-year-old woman was referred to our institution for the management of a migrated pancreatic stent that was prophylactically placed to prevent pancreatitis after the removal of common bile duct stones. She required hospitalization owing to prolonged pancreatitis, despite placement of an additional nasopancreatic drainage tube across the papilla. A computed tomography scan showed grade1 pancreatitis around the migrated stent, which was located in the pancreatic body (► Fig. 1). After obtaining informed consent for the possibility of a post-procedure exacerbation of pancreatitis, we tried to endoscopically remove the migrated stent. A stricture caused by irritation from the end of migrated pancreatic stent was found, so we employed the prototype guiding sheath to pass the stricture (► Video 1). Initially, a catheter was inserted into the pancreatic duct beside the nasopancreatic drainage tube. The guiding sheath system was inserted along the guidewire through the stricture to reach the migrated stent, and the inner catheter and guidewire were removed. Subsequently, a biopsy forceps (Radial Jaw; Boston Scientific Corporation, Marl-



► **Fig. 1** Contrast-enhanced computed tomography images showing: **a** grade1 pancreatitis around the migrated pancreatic duct stent (arrow); **b** the arterial phase; **c** the portal phase; **d** the equilibrium phase.



► **Video 1** A migrated pancreatic duct stent is removed using biopsy forceps passed through a prototype guiding sheath.

borough, Massachusetts, USA) was inserted through the guiding sheath and the end of the migrated stent was suc-

cessfully grasped. The stent was pulled out from the pancreatic duct within the guiding sheath.

Following the procedure, the patient's pancreatitis improved and she was discharged 4 days later. The guiding sheath was useful for inserting devices beyond the stricture.

Endoscopy\_UCTN\_Code\_TTT\_1AR\_2AZ

### Competing interests

Hiroyuki Isayama has received honoraria from Fujifilm Corporation. He has also received grants for commissioned/joint research from Fujifilm Corporation, Boston Scientific Japan Corporation and scholarship grants from Boston Scientific Japan Corporation.

### The authors

**Mako Ushio, Ko Tomishima, Shigeto Ishii, Yusuke Takasaki, Koichi Ito, Toshio Fujisawa, Hiroyuki Isayama**

Department of Gastroenterology, Graduate School of Medicine, Juntendo University, Tokyo, Japan

### Corresponding author

**Hiroyuki Isayama, MD, PhD**

Department of Gastroenterology, Graduate School of Medicine, Juntendo University, 2-1-1 Hongo, Bunkyo-ku, Tokyo 113-0033, Japan  
h-isayama@juntendo.ac.jp

### References

- [1] Price LH, Brandabur JJ, Kozarek RA et al. Good stents gone bad: endoscopic treatment of proximally migrated pancreatic duct stents. *Gastrointest Endosc* 2009; 70: 174–179
- [2] Ishigaki K, Hamada T, Isayama H et al. Endoscopic removal of a proximally migrated pancreatic stent using a gooseneck snare. *Endoscopy* 2014; 46: E283–E284
- [3] Takahara N, Isayama H, Sasahira N et al. Endoscopic removal of a piece of retained pancreatic stent with a novel new technique: turned guide-wire looping method. *Endoscopy* 2012; 44: E401

### Bibliography

*Endoscopy* 2023; 55: E5–E6  
DOI 10.1055/a-1907-4640  
ISSN 0013-726X  
published online 9.9.2022  
© 2022. The Author(s).

This is an open access article published by Thieme under the terms of the Creative Commons Attribution-NonDerivative-NonCommercial License, permitting copying and reproduction so long as the original work is given appropriate credit. Contents may not be used for commercial purposes, or adapted, remixed, transformed or built upon. (<https://creativecommons.org/licenses/by-nc-nd/4.0/>)

Georg Thieme Verlag KG, Rüdigerstraße 14, 70469 Stuttgart, Germany



### ENDOSCOPY E-VIDEOS

<https://eref.thieme.de/e-videos>



*Endoscopy E-Videos* is an open access online section, reporting on interesting cases and new techniques in gastroenterological endoscopy. All papers include a high quality video and all contributions are freely accessible online. Processing charges apply (currently EUR 375), discounts and waivers acc. to HINARI are available.

This section has its own submission website at <https://mc.manuscriptcentral.com/e-videos>