



Since January 2020 Elsevier has created a COVID-19 resource centre with free information in English and Mandarin on the novel coronavirus COVID-19. The COVID-19 resource centre is hosted on Elsevier Connect, the company's public news and information website.

Elsevier hereby grants permission to make all its COVID-19-related research that is available on the COVID-19 resource centre - including this research content - immediately available in PubMed Central and other publicly funded repositories, such as the WHO COVID database with rights for unrestricted research re-use and analyses in any form or by any means with acknowledgement of the original source. These permissions are granted for free by Elsevier for as long as the COVID-19 resource centre remains active.



## Short Communication

## Human metapneumovirus pneumonia in patients with hematological malignancies



Cendrine Godet<sup>a</sup>, Jérôme Le Goff<sup>b</sup>, Agnès Beby-Defaux<sup>c</sup>, Marie Robin<sup>d</sup>, Emmanuel Raffoux<sup>e</sup>, Bertrand Arnulf<sup>f</sup>, France Roblot<sup>a</sup>, Jean Pierre Frat<sup>g</sup>, Natacha Maillard<sup>h</sup>, Abdellatif Tazi<sup>i,j</sup>, Anne Bergeron<sup>i,j,\*</sup>

<sup>a</sup> Service de Maladies Infectieuses et de Médecine Interne, CHU Poitiers, France

<sup>b</sup> Univ Paris Diderot, Sorbonne Paris Cité, Laboratoire de microbiologie, AP-HP, Hôpital Saint Louis, Paris, France

<sup>c</sup> Service de Virologie, CHU Poitiers, Université de Poitiers, France

<sup>d</sup> Univ Paris Diderot, Sorbonne Cité, Service d'Hématologie-Greffe, AP-HP, Hôpital Saint Louis, Paris, France

<sup>e</sup> Univ Paris Diderot, Sorbonne Cité, Maladies du sang, AP-HP, Hôpital Saint Louis, Paris, France

<sup>f</sup> Univ Paris Diderot, Sorbonne Cité, Service d'Immuno-Hématologie, AP-HP, Hôpital Saint Louis, Paris, France

<sup>g</sup> Service de Réanimation Médicale, CHU Poitiers, France

<sup>h</sup> Service d'Hématologie, CHU Poitiers, France

<sup>i</sup> Biostatistics and Clinical Epidemiology Research Team (ECSTRA), UMR 1153 INSERM, Univ Paris Diderot, Sorbonne Paris Cité, France

<sup>j</sup> AP-HP, Hôpital Saint-Louis, Service de Pneumologie, F-75010 Paris, France

## ARTICLE INFO

## Article history:

Received 17 July 2014

Received in revised form 22 August 2014

Accepted 24 August 2014

## Keywords:

Metapneumovirus

Emerging virus

Respiratory infection

Immunocompromised

Hematological patients

## ABSTRACT

**Background:** Human metapneumovirus (HMPV) has recently emerged as a cause of respiratory infections in hematological patients. Clinical data are lacking to guide the management of HMPV pneumonias.

**Objectives:** To characterize the clinical and radiographic presentation and outcome of HMPV pneumonias diagnosed in hematological patients.

**Study design:** We screened the patients with a positive HMPV respiratory test in two French teaching hospitals between 2007 and 2011. Among them, the medical charts from the hematological patients who presented with HMPV pneumonia were reviewed.

**Results:** Among the 54 patients with several underlying hematological conditions who were positive for HMPV, we found 13 cases of HMPV pneumonias. HMPV could be the cause of pneumonia as a single pathogen without associated upper respiratory infection. Centrilobular nodules were constant on lung computed tomography scans. No patients died despite the absence of administration of antiviral treatments.

**Conclusions:** Our data provide further insights in the diagnosis and management of HMPV pneumonias in this setting.

© 2014 Published by Elsevier B.V.

## 1. Background

The development of molecular techniques has highlighted the role of emerging respiratory viruses (RV), particularly in immunocompromised patients. Human metapneumovirus (HMPV)

is a paramyxovirus identified in the early 2000s that is closely related to the respiratory syncytial virus (RSV). The clinical spectrum of HMPV infections ranges from asymptomatic carriage in the airways to upper respiratory tract infection disease (URTID) and severe pneumonia [1–6]. To date, the few published epidemiological or clinical data on HMPV pneumonias in hematological patients have focused on hematopoietic stem cell transplant (HSCT) recipients [2–6], and this virus is still poorly recognized. Due to the lack of clinical data on HMPV infections, the fourth European conference on infections in leukemia could not make any recommendations for the management of HMPV infections in hematological patients in recent guidelines [7].

**Abbreviations:** HMPV, human metapneumovirus; HSCT, hematopoietic stem cell transplant; URTID, upper respiratory tract infection disease; BAL, bronchoalveolar lavage; RV, respiratory virus; HRCT, high resolution computed tomography.

\* Corresponding author at: Service de Pneumologie, Hôpital Saint-Louis, 1, avenue Claude Vellefaux, 75475 Paris cedex 10, France. Tel.: +33 1 42 49 41 66; fax: +33 1 42 49 93 95.

E-mail address: [anne.bergeron@sls.aphp.fr](mailto:anne.bergeron@sls.aphp.fr) (A. Bergeron).

<http://dx.doi.org/10.1016/j.jcv.2014.08.019>

1386-6532/© 2014 Published by Elsevier B.V.

## 2. Objective

We sought to characterize the clinical and radiographic presentation and outcome of HMPV pneumonias diagnosed in hematological patients over a four-year period in two French teaching hospitals.

## 3. Study design

These cases were diagnosed in two French centers between January 1, 2007, and October 31, 2011. Hospital Saint Louis, Paris is a 650 bed teaching hospital that includes 350 beds dedicated to onco-hematology adult patients. The Poitiers teaching hospital has 1413 beds for both adults and children including 64 beds for onco-hematology. In both centers, RVs are screened in the nasopharyngeal aspirate and/or bronchoalveolar lavage (BAL) in all hematological patients who present with acute respiratory tract symptoms. In Hospital Saint Louis, Paris, from October 2007 to October 2009 HMPV was detected using immunofluorescence testing (Argene, Verniolle, France). Since November 2009, the detection of HMPV is performed using 200  $\mu$ L of respiratory specimen using a molecular multiplex assay, RespiFinder<sup>®</sup>, (Pathfinder, Maastricht, The Netherlands), which enables the detection and differentiation of 14 RVs including the following: influenza viruses A and B; parainfluenza viruses, RSV; rhinovirus; human coronaviruses, adenovirus and HMPV [8]. In the Poitiers teaching hospital, during the study period, HMPV and other respiratory pathogens (Influenza viruses A and B, parainfluenza viruses, RSV, rhinovirus, human coronaviruses 229E and OC43, adenovirus, *Chlamydia pneumoniae* and *Mycoplasma pneumoniae*) were detected using multiplex or monoplex nucleic acid amplification [9–11].

Pneumonia was defined as the presence of dyspnea and/or hypoxia with a new infiltrate on imaging. URTID was defined as the presence of coryza, pharyngitis, sinusitis and/or cough with or without fever, no hypoxemia and clear chest imaging. BAL samples were tested for bacteria (direct examination and culture) and fungi (immunofluorescence and molecular biology for *Pneumocystis jirovecii*; direct examination and culture for other species). When bronchoscopy could not be performed, the presence of bacteria and fungi was evaluated in induced sputum samples. To describe the initial high resolution computed tomography (HRCT) findings in patients with HMPV pneumonia, we reviewed the HRCT scans performed shortly (<5 days) after the onset of symptoms.

## 4. Results

During the study period, a total of 11267 HMPV tests were performed in both centers (1677 immunofluorescence HMPV tests and 9590 molecular HMPV tests). HMPV was detected in a total of 171 respiratory samples (1.5%) in 131 patients including 77 patients of the general hospital population and 54 hematological patients.

Thirteen of these hematological patients (24%) had a diagnosis of HMPV pneumonia whereas the diagnosis of URTID was retained for the others. All the nonhematological patients positive for HMPV were diagnosed with URTID. The clinical features of the patients with pneumonia are described in Table 1. Six patients were allogeneic HSCT recipients, with a median time of 4.3 months [1.8–5.8] after HSCT and two had previously experienced an autologous HSCT. Nine of the HMPV infections occurred during the winter (69%), one in spring, one in autumn and two in summer. The infection was considered to be community acquired in 10 patients and nosocomial in three. Eleven patients had HMPV as a single pathogen, and 2 patients had rhinovirus co-infection of the lung. No bacteria or fungus was found in the respiratory samples at the time of HMPV pneumonia diagnosis. Seven patients with HMPV

pneumonia presented no URTID (54%). However, among the seven patients who did not present with URTI symptoms, a nasopharyngeal aspirate was available for five patients that were all positive for HMPV. Six patients presented with both URTID and pneumonia. All of the six patients who initially presented with URTID progressed to pneumonia with a mean interval of 4 days (range, 3–5 days). The most frequent symptoms were cough and dyspnea in all patients, fever in 11 (85%), and wheezing in 11 (85%). In 12 patients, a lung HRCT scan was performed at a mean time of 2.5 days after the onset of symptoms (range, 1–5 days). HRCT findings were mainly small blurred ill-defined centrilobular nodules, branching centrilobular nodules and ground glass opacities (Table 1, Fig. 1). Bilateral involvement was observed in all patients, predominantly in the lower lobes. Nine patients (69%) had lymphopenia ( $\leq 0.6$  cells/ $\mu$ L), whereas 5 (38%) had neutropenia (<500 cells/ $\mu$ L). Two patients were admitted to an intensive care unit, but none required ventilation.

None of the patients were treated with any antiviral therapy, such as inhaled or oral ribavirin. All patients received broad-spectrum antibiotics. HMPV pneumonia resolved in all patients, and they were all alive three months after HMPV pneumonia diagnosis.

## 5. Discussion

We found that HMPV pneumonia may occur in several hematological conditions although previous studies have focused on HSCT. Whatever the underlying condition, the clinical and radiological presentation was similar. Contrary to previously described findings, half of our patients had no signs of URTID in the days that preceded the diagnosis of HMPV pneumonia.

Lung CT scan is a cornerstone in the management of respiratory infections in hematological patients [12]. The presence of centrilobular nodules was strikingly noted in almost all of our cases of HMPV pneumonia and should suggest the diagnosis, especially in the winter. The fact that only rhinovirus was detected as copathogens in only two patients suggests that the HPMV could by itself be the cause of respiratory infection and confirms previous data [2].

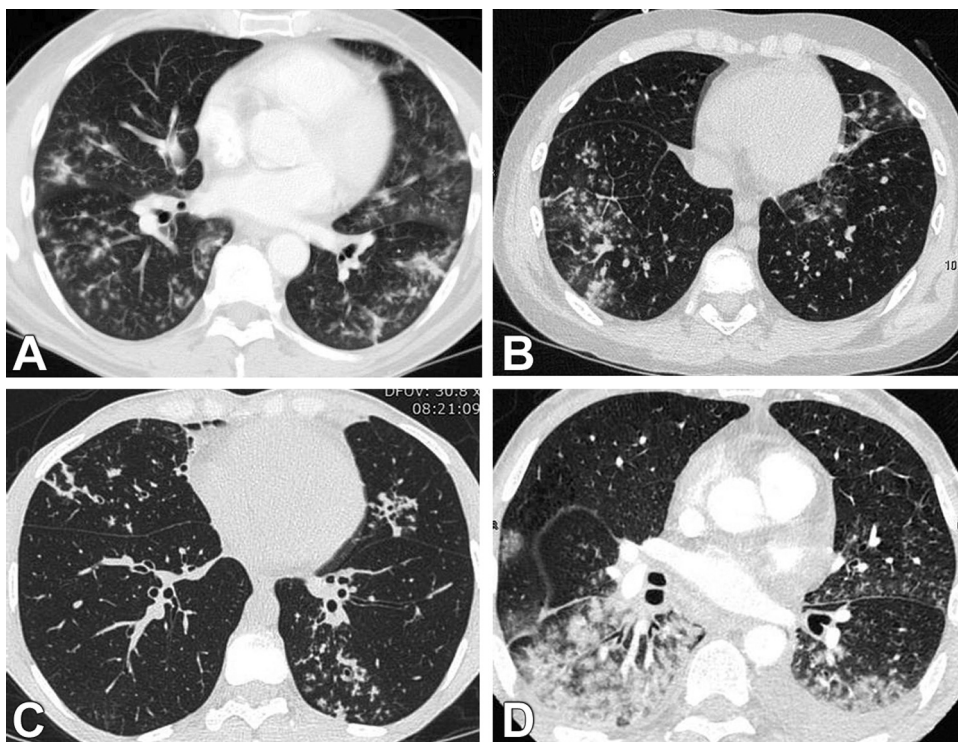
The striking feature of our study is the good prognosis of our patients. In previous series that focused on HSCT recipients, mortality has been reported to be between 10 and 40% [4,6]. In our series over a period of 4 years, including all consecutive hematological patients with a diagnosis of HMPV pneumonia, no patients died, even though 8/13 patients required oxygen and among them two needed intensive care. Our data are even more striking in that none of our patients had received any anti-viral treatment. There is little data to determine risk factors for mortality of HMPV pneumonia in hematological patients. When available individual data are analyzed, a number of deaths are not directly related to the virus: relapse of hematological disease, lung cancer, other severe infection, or, in a few cases, the patient's desire to limit care [4,6]. Other factors are likely to be involved such as an underlying lung disease, especially bronchiolitis obliterans in the case of allogeneic HSCT recipients. The very early onset of HMPV pneumonia after transplantation is also a factor likely to impact mortality. Renaud et al. identified several risk factors for HMPV-related mortality in a population of HSCT recipients including the severity of the pneumonia, peripheral blood stem cell or cord blood as stem cell sources and the use of corticosteroids [6].

Although some authors have suggested that ribavirin could be an effective option for treating HMPV infection, preliminary data regarding the effect of ribavirin on HMPV pneumonia do not support a significant effect [6,13]. In summary, we showed that HMPV pneumonia can occur in hematological patients other than HSCT recipients with a suggestive radiological pattern. Although

**Table 1**  
Clinical characteristics of patients at diagnosis of HMPV pneumonia.

Age (years)/sex	Underlying disease/stage of disease	Significant medications in the past 3 months	Type of conditioning allogeneic HSCT	GVHD	Time from HSCT to HMPV (months)	Immunosuppressive treatment	Lymphocytes count G/L	CT-scan findings	Co-pathogens	Treatment O2/ICU	Outcome at 3 months
66/F	CLL/progression	0					60.4	Ill-defined nodules, ground-glass opacities,	Rhinovirus	Supportive +/-	Alive
74/F	MDS	0					0.6	Ill-defined nodules, ground-glass opacities,	0	Supportive -/-	Alive
63/M	AML/induction	Aracytin, daunorubicin					<0.1	Ill-defined nodules, ground-glass opacities	0	Supportive +/-	Alive
62/M	CLL/progression	0					33.3	Confluent ill-defined nodules, ground-glass opacities	0	Supportive +/+	Alive
74/M	NHL/relapse	Rituximab Bendamustine					0.1	pleural effusion Reticulations, ground grass opacities	0	Supportive +/+	Alive
43/M	CLL/autologous				14	0	3.1	Ill-defined nodules, ground-glass opacities	0	Supportive -/-	Alive
62/M	MM/autologous				24	Dexamethasone, thalidomide	0.5	Ill-defined nodules, ground-glass opacities	0	Supportive -/-	Alive
55/F	AML/allogeneic related PBSC		NMA	+	5	Prednisone 5 mg/d, Cy	0.4	NA/diffuse alveolar opacities on chest X-ray	0	Ig -/-	Alive
59/M	NHL/allogeneic related PBSC		NMA	+	6	Prednisone 110 mg/d, Cy	0.4	Ill-defined nodules, ground-glass opacities	0	Supportive -/-	Alive
41/M	AML/allogeneic related PBSC		MA	-	1	Cy	0.6	Ill-defined nodules, ground-glass opacities	0	Supportive +/-	Alive
27/M	AML/allogeneic related PBSC		MA	+	4	Prednisone 2.5 mg/d, Cy	0.3	Ill-defined nodules, ground-glass opacities, coalescence of nodules	0	Supportive +/-	Alive
58/M	NHL/allogeneic related PBSC		NMA	+	36	Prednisone 5 mg/d, Cy	1.9	Ill-defined nodules, ground-glass opacities	0	Supportive +/-	Alive
14/M	ALL/allogeneic related BM		MA	-	<1	Cy	<0.1	Ill-defined nodules, ground-glass opacities	Rhinovirus	Supportive +/-	Alive

HSCT, hematopoietic stem cell transplant; HMPV, human metapneumovirus; M, male; F, female; GVHD, graft-versus-host disease; CLL, chronic lymphocytic leukemia; MDS, myelodysplastic syndrome; AML, acute myeloid leukemia; NHL, non Hodgkin lymphoma; ALL, acute lymphocytic leukemia; CLL, chronic lymphocytic leukemia; MM, multiple myeloma; PBSC, peripheral blood stem cell; BM, bone marrow; MA, myeloablative; NMA, non myeloablative; Cy, cyclosporine; CT, computed tomography; O2, need for oxygen; ICU, intensive care unit; Ig, immunoglobulins.



**Fig. 1.** Lung CT scans from four hematological patients with HMPV pneumonia. Ill-defined centrilobular nodules and ground glass opacities were most frequently noted and were predominantly located in the lower lobes (A–D). Centrilobular nodules could be extensive and confluent (D). Bilateral pleural effusion could be present (D).

the majority of our patients had a severe respiratory infection requiring oxygen, the clinical outcome was good despite the absence of a specific antiviral treatment. Randomized studies are needed to determine the effect of any antiviral drug on HMPV pneumonia.

#### Funding

None.

#### Competing interests

None declared.

#### Ethical approval

This study was approved by the institutional review board of the French Learned Society for Respiratory Medicine CEPRO 2013-20.

#### Authors' contribution

CG collected the data, analyzed the data and wrote the manuscript. JL and ABD performed and analyzed the virological testings, and wrote the manuscript. MR, ER, BA, FR, JPF, NM and AB participated in patients' recruitment and data collection. AT analyzed the data and critically revised the manuscript. AB supervised the study, analyzed the data and wrote the manuscript. All authors approved the final manuscript.

#### Acknowledgment

CG, AT and AB are members of the GREPI (French Group for Research and Education in Respiratory Infectious Diseases).

#### References

- [1] Martino R, Porras RP, Rabella N, Williams JV, Rámila E, Margall N, et al. Prospective study of the incidence, clinical features, and outcome of symptomatic upper and lower respiratory tract infections by respiratory viruses in adult recipients of hematopoietic stem cell transplants for hematologic malignancies. *Biol Blood Marrow Transplant* 2005;11:781–96.
- [2] Debur MC, Vidal LR, Stroparo E, Nogueira MB, Almeida SM, Takahashi GA, et al. Human metapneumovirus infection in hematopoietic stem cell transplant recipients. *Transpl Infect Dis* 2010;12:173–9.
- [3] Oliveira R, Machado A, Tateno A, Boas LV, Pannuti C, Machado C. Frequency of human metapneumovirus infection in hematopoietic SCT recipients during 3 consecutive years. *Bone Marrow Transplant* 2008;42:265–9.
- [4] Egli A, Bucher C, Dumoulin A, Stern M, Buser A, Bubendorf L, et al. Human metapneumovirus infection after allogeneic hematopoietic stem cell transplantation. *Infection* 2012;40:677–84.
- [5] Cane PA, van den Hoogen BG, Chakrabarti S, Fegan CD, Osterhaus AD. Human metapneumovirus in a haematopoietic stem cell transplant recipient with fatal lower respiratory tract disease. *Bone Marrow Transplant* 2003;31:309–10.
- [6] Renaud C, Xie H, Seo S, Kuypers J, Cent A, Corey L, et al. Mortality rates of human metapneumovirus and respiratory syncytial virus lower respiratory tract infections in hematopoietic cell transplantation recipients. *Biol Blood Marrow Transplant* 2013;19:1220–6.
- [7] Hirsch HH, Martino R, Ward KN, Boeckh M, Einsele H, Ljungman P. Fourth European Conference on Infections in Leukaemia (ECIL-4): guidelines for diagnosis and treatment of human respiratory syncytial virus, parainfluenza virus, metapneumovirus, rhinovirus, and coronavirus. *Clin Infect Dis* 2013;56:258–66.
- [8] Schnell D, Legoff J, Mariotte E, Seguin A, Canet E, Lemiale V, et al. Molecular detection of respiratory viruses in immunocompromised ICU patients: incidence and meaning. *Respir Med* 2012;106:1184–91.
- [9] Bellau-Pujol S, Vabret A, Legrand L, Dina J, Gouarin S, Petitjean-Lecherbonnier J, et al. Development of three multiplex RT-PCR assays for the detection of 12 respiratory RNA viruses. *J Virol Methods* 2005;126:53–63.
- [10] Stockton J, Ellis JS, Saville M, Clewley JP, Zambon MC. Multiplex PCR for typing and subtyping influenza and respiratory syncytial viruses. *J Clin Microbiol* 1998;36:2990–5.
- [11] Hierholzer JC, Halonen PE, Dahlen PO, Bingham PG, McDonough MM. Detection of adenovirus in clinical specimens by polymerase chain reaction and liquid-phase hybridization quantitated by time-resolved fluorometry. *J Clin Microbiol* 1993;31:1886–91.
- [12] Bergeron A. The pulmonologist's point of view on lung infiltrates in haematological malignancies. *Diagn Interv Imaging* 2013. pii:S2211-5684(12)00399-3.
- [13] Park SY, Baek S, Lee SO, Choi SH, Kim YS, Woo JH, et al. Efficacy of oral ribavirin in hematologic disease patients with paramyxovirus infection: analytic strategy using propensity scores. *Antimicrob Agents Chemother* 2013;57:983–9.