

## Unusual Variant of the Nutcracker Fracture of the Calcaneus and Tarsal Navicular

Varun K. Gajendran, M.S., Brad J. Yoo, M.D., and John C. Hunter, M.D.

A 62-year-old woman with severe seizure disorder presented with right ankle and foot pain after being found down, presumably following a seizure recurrence. Imaging showed an acute comminuted fracture of the anterolateral aspect of the right calcaneus, as well as an acute avulsion fracture of the right navicular tuberosity at the site of insertion of the tibialis posterior tendon. This fracture pattern suggests forced abduction of the midfoot or forefoot with severe compression of the lateral column and failure of the medial column under tension, an entity that has previously been described as the nutcracker fracture. This mechanism of injury should prompt particularly careful evaluation of the navicular, cuboid, and calcaneus for any signs of injury. Subtle fractures of the navicular and calcaneus may be overlooked in the emergency setting, leading to a delay in surgical treatment and ultimately chronic foot deformities that can result in significant functional disability.

### Introduction

Although nutcracker fractures of the foot are rare, they can lead to severe deformity and functional impairment following the injury [1-6]. Because they

are rarely encountered, the diagnosis can be challenging. The mechanism of injury has been described as forced abduction of the midfoot or forefoot, usually in combination with axial forces, resulting in simultaneous compression of the lateral column and tensile stretching of the medial column. This typically results in a compression fracture of the cuboid between the fourth and fifth metatarsals and calcaneus laterally, and a distraction-type avulsion fracture of the navicular at its tuberosity medially [2, 4-7].

Hermel et al. first reported a series of 5 cases of the nutcracker fracture, which is still the largest case series reported in the literature [7]. Since then, only a few additional cases have been reported, all of which have identified concomitant fractures of the cuboid and navicular [1-6, 8]. Here, we report a unique case of a nutcracker fracture in which an avulsion fracture of the navicular is seen in conjunction with a fracture of

---

Citation: Gajendran VK, Yoo BJ, Hunter JC. Unusual variant of the nutcracker fracture of the calcaneus and tarsal navicular. *Radiology Case Reports*. [Online] 2008;3:208.

Copyright: © 2008 The Authors. This is an open-access article distributed under the terms of the Creative Commons Attribution-NonCommercial-NoDerivs 2.5 License, which permits reproduction and distribution, provided the original work is properly cited. Commercial use and derivative works are not permitted.

Abbreviations: CT, computed tomography

Varun K. Gajendran, M.S. (Email: varun.gajendran@ucdmc.ucdavis.edu), and Brad J. Yoo, M.D., are in the Department of Orthopaedic Surgery, UC Davis, Sacramento, CA, USA.

John C. Hunter, M.D., is in the Department of Radiology, UC Davis, Sacramento, CA, USA.

Published: July 11, 2008

DOI: 10.2484/rcr.v3i3.208

## Unusual Variant of the Nutcracker Fracture of the Calcaneus and Tarsal Navicular

the anterior aspect of the calcaneus, with sparing of the cuboid. To our knowledge, this is the first reported case of this type of nutcracker fracture in the literature.

### Case Report

A 62-year-old woman with a history of severe seizure

disorder was found down in an awkward position by her husband, reportedly with brief loss of consciousness at the scene. She was brought into the emergency department by her husband the following day, with altered mental status and complaints of right ankle and foot pain. Due to her post-ictal state, she was unable to provide further details regarding the mechanism of injury. Initial imaging included computed tomography

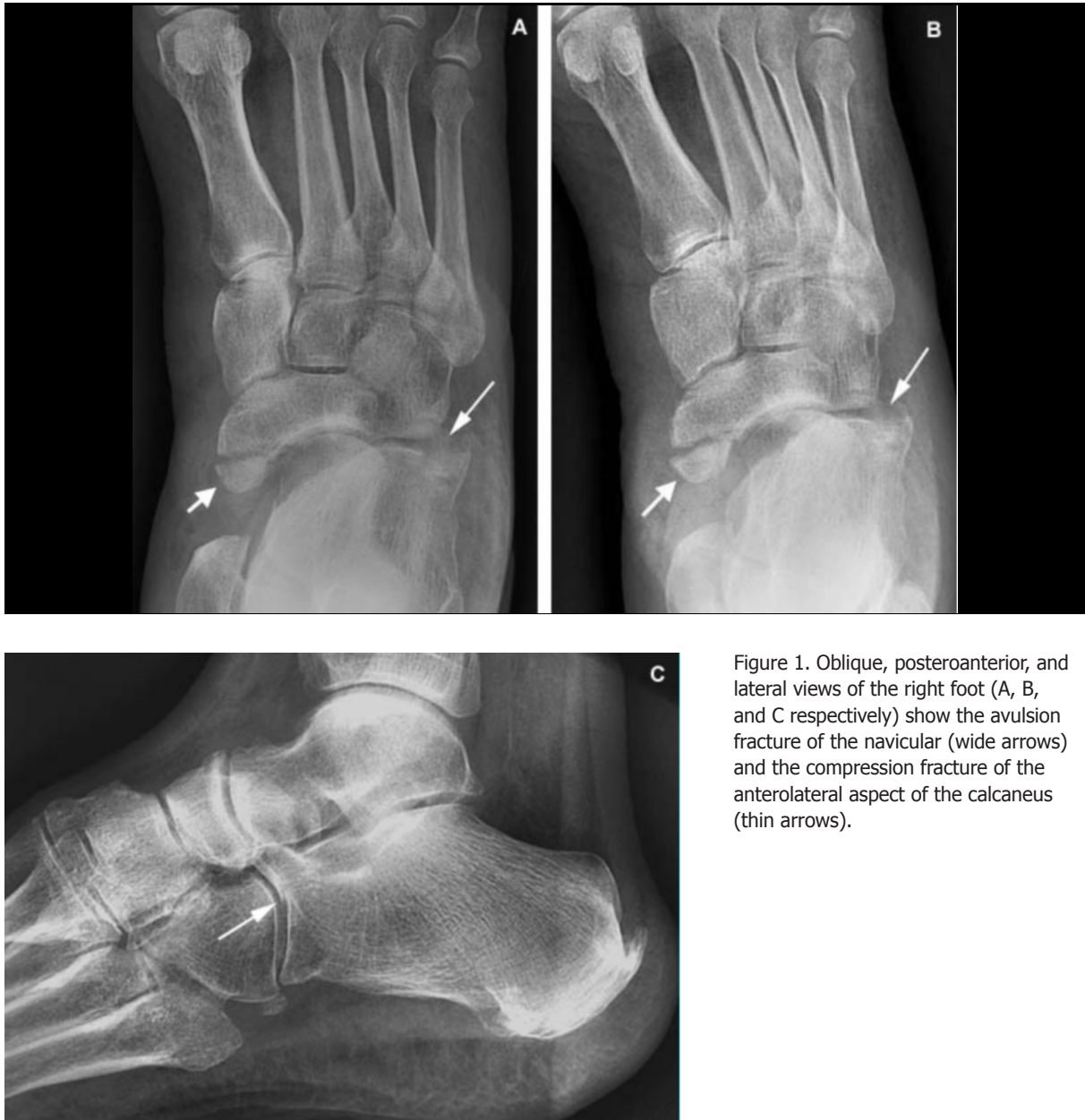

Figure 1. Oblique, posteroanterior, and lateral views of the right foot (A, B, and C respectively) show the avulsion fracture of the navicular (wide arrows) and the compression fracture of the anterolateral aspect of the calcaneus (thin arrows).

## Unusual Variant of the Nutcracker Fracture of the Calcaneus and Tarsal Navicular

(CT) of the head and cervical spine, which showed no acute abnormalities, and CT of the chest, which showed changes consistent with acute aspiration pneumonia. Radiographs of her right foot and ankle showed acute fractures of the navicular and calcaneus (Fig. 1). Because the fracture pattern on radiographs suggested a high-

energy injury to the midfoot and forefoot, a lower extremity CT was performed to detect any occult injuries and to further characterize the known fractures (Fig. 2). The CT demonstrated a comminuted fracture of the anterolateral aspect of the calcaneus with extension into the calcaneocuboid joint, an avulsion fracture of the

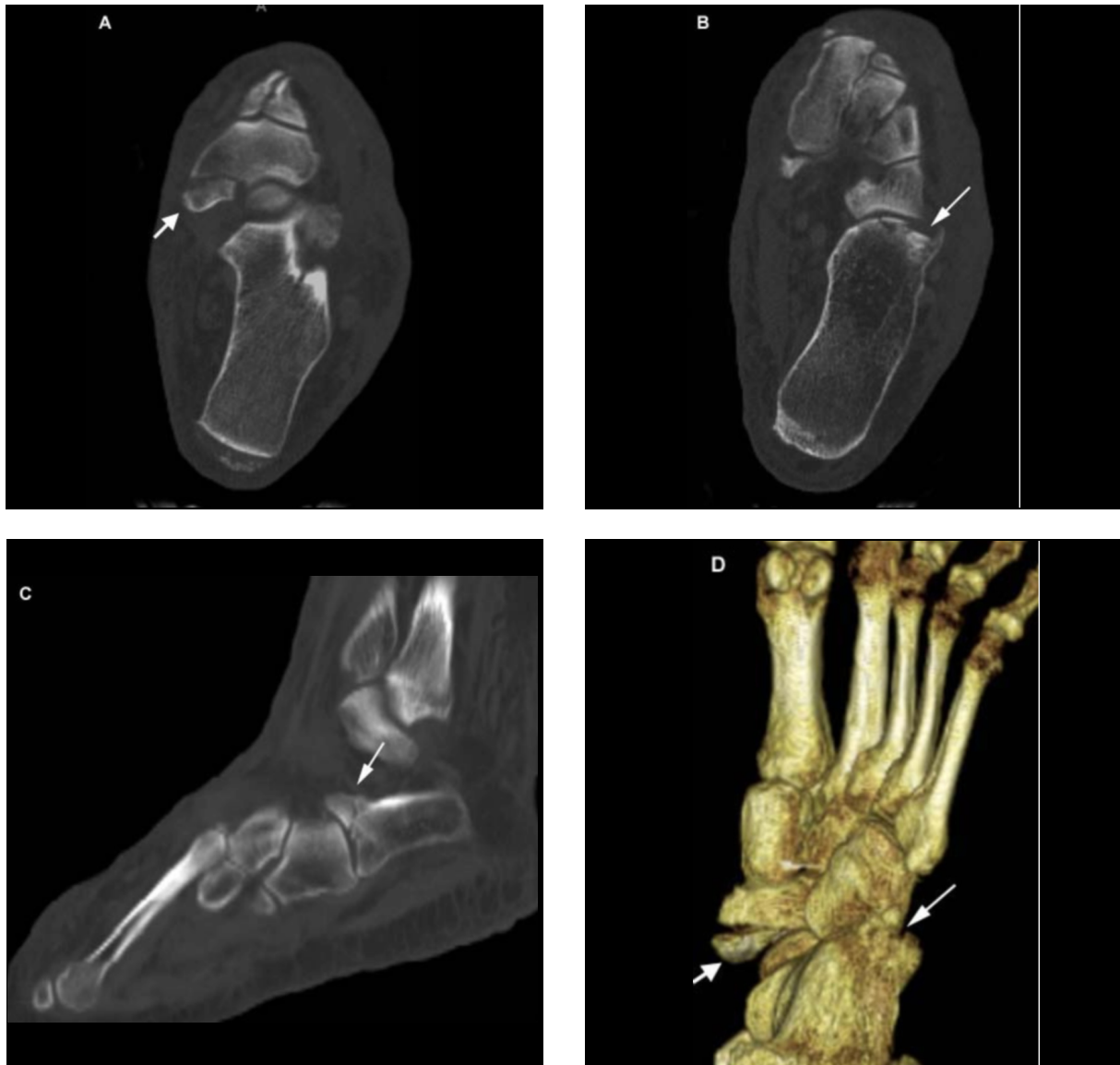


Figure 2. Axial CT of the right foot (A, B) with sagittal (C) and 3-D (D) reformations. Navicular avulsion fracture (wide arrows) and depressed intra-articular fracture of the calcaneus at the calcaneocuboid joint (narrow arrows) are noted.

## Unusual Variant of the Nutcracker Fracture of the Calcaneus and Tarsal Navicular

navicular tuberosity, a mildly displaced fracture of the inferior aspect of the lateral cuneiform, and a minimally displaced fracture of the anterolateral corner of the distal tibia.

Within a few hours after admission, the patient required endotracheal intubation for respiratory support. She was evaluated by orthopaedics, and a closed reduction was attempted and her right foot splinted in anticipation of early elective open reduction and internal fixation of the fractures of her right foot. Ultimately, however, she was unable to undergo surgery due to severe aspiration pneumonia necessitating ventilatory support for several weeks. Because of this crucial delay, the decision was made to immobilize her foot in a non-weightbearing cast and treat her non-operatively with regular follow-up in orthopaedic clinic. Follow-up radiographs obtained three months after the injury showed non-union of the navicular fracture with fragmentation, and persistent shortening of the lateral column (Fig. 3).

### Discussion

Among all extremity fractures in the emergency setting, Wei et al. reported that the foot is the most common location for missed radiological diagnoses. The primary reason cited for the missed diagnoses was subtlety of the fractures, with 70% of the fractures being diagnosed correctly on a subsequent review [9]. This suggests that foot injuries in the emergency setting in particular warrant a high degree of vigilance, and a better understanding of the underlying mechanisms of injury, as presented in this case, is likely to reduce the number of missed diagnoses on plain films and obviate potentially serious long-term consequences for the patient. Anterior calcaneal fractures and navicular avulsion fractures are particularly challenging to diagnose on plain radiographs [10, 11]. The anterior portion of the calcaneus is often obscured by the bones of the midfoot, and navicular avulsion fractures can be quite subtle.

The navicular is crucial for maintaining the medial longitudinal arch and Chopart joints of the foot. The tibialis posterior tendon, which inserts at the tuberosity of the navicular, also plays an important role in this regard. Therefore, the intact navicular and tibialis posterior tendon together play a vital role in the structural integrity and weight-bearing function of the foot,

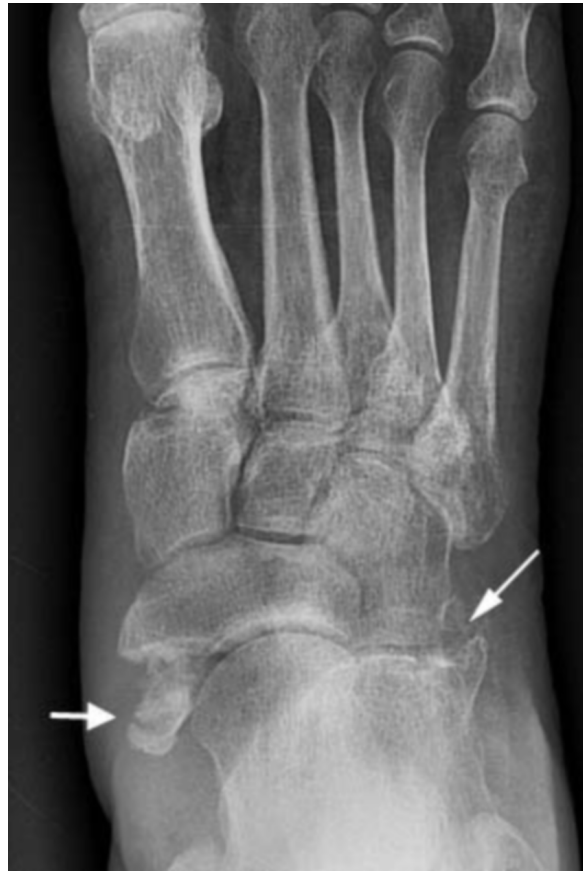

Figure 3. Posteroanterior view of the right foot at 3 months following the injury. The compression deformity of the calcaneus persists (wide arrow), and the navicular fracture is fragmented and further distracted, consistent with non-union (narrow arrow).

and any delay in the diagnosis and surgical reduction of navicular fractures can lead to chronic deformity, pes planus, arthrosis, and loss of motion of the foot [12]. Calcaneal fractures that are intra-articular or displaced are generally treated by open reduction and internal fixation, which can produce excellent anatomic and functional results in the long term [13, 14]. Failure to diagnose and surgically treat calcaneal fractures caused by lateral column compression in a timely manner can lead to severe chronic disability stemming from uncorrected lateral column shortening, valgus deformity, and malalignment of the foot. Additionally, delayed surgical treatment of intra-articular fractures of the anterior

## Unusual Variant of the Nutcracker Fracture of the Calcaneus and Tarsal Navicular

aspect of the calcaneus can disrupt and eventually lead to arthrosis of the calcaneocuboid joint [13].

The nutcracker fracture results from forced abduction of the midfoot or forefoot with lateral column compression and failure of the medial column under tension. Although this is an uncommonly seen mechanism of injury, it has been ascribed to forces from high-energy blunt trauma and specific types of injuries such as falls during horseback riding [1, 4-7, 15]. The case presented here, however, involves a fall from standing height, a strikingly different mechanism from those that have been classically described to cause nutcracker fractures. It emphasizes the important point that the nutcracker fracture should be considered as a possibility whenever forced abduction of the midfoot or forefoot occurs, irrespective of the specific type of injury or magnitude of the forces involved. In this setting, the navicular, cuboid, and calcaneus should all be carefully evaluated to rule out injuries. As discussed above, missing even one of the multiple findings seen in a nutcracker fracture can lead to suboptimal treatment and ultimately severe chronic deformities of the foot. Therefore, a fine-cut CT of the lower extremity may prove invaluable for a more complete evaluation.

When diagnosed promptly and accurately, the nutcracker fracture can be treated surgically to restore normal anatomic relationships and achieve good long-term functionality [1-3, 5, 6, 8]. Unfortunately, despite timely and accurate radiological diagnosis, the patient presented in this case could not undergo immediate surgical treatment. As a result, she was found at three-month follow-up to have non-union and fragmentation of her navicular fracture, as well as persistent lateral column shortening, both of which predispose her to severe long-term functional impairment even if healing is ultimately successful.

### References

1. Ceroni D, De Rosa V, De Coulon G, Kaelin A. Cuboid nutcracker fracture due to horseback riding in children: case series and review of the literature. *J Pediatr Orthop*. 2007 Jul-Aug;27(5):557-61. [PubMed]
2. Rammelt S, Grass R, Zwipp H. [Nutcracker fractures of the navicular and cuboid]. *Ther Umsch*. 2004 Jul;61(7):451-7. [PubMed]
3. Hsu JC, Chang JH, Wang SJ, Wu SS. The nutcracker fracture of the cuboid in children: a case report. *Foot Ankle Int*. 2004 Jun;25(6):423-5. [PubMed]
4. Hunter JC, Sangeorzan BJ. A nutcracker fracture: cuboid fracture with an associated avulsion fracture of the tarsal navicular. *AJR Am J Roentgenol*. 1996 Apr;166(4):888. [PubMed]
5. Koch J, Rahimi F. Nutcracker fractures of the cuboid. *J Foot Surg*. 1991 Jul-Aug;30(4):336-9. [PubMed]
6. Sangeorzan BJ, Swiontkowski MF. Displaced fractures of the cuboid. *J Bone Joint Surg Br*. 1990 May;72(3):376-8. [PubMed]
7. Hermel MB, Gershon-Cohen J. The nutcracker fracture of the cuboid by indirect violence. *Radiology*. 1953 Jun;60(6):850-4. [PubMed]
8. Kavros SJ, Puglisi AS, Guttmann GG. Nutcracker fracture of the foot. A case report. *J Am Podiatry Assoc*. 1983 Oct;73(10):527-8. [PubMed]
9. Wei CJ, Tsai WC, Tiu CM, Wu HT, Chiou HJ, Chang CY. Systematic analysis of missed extremity fractures in emergency radiology. *Acta Radiol*. 2006 Sep;47(7):710-7. [PubMed]
10. Newton EJ, Love J. Emergency department management of selected orthopedic injuries. *Emerg Med Clin North Am*. 2007 Aug;25(3):763-93, ix-x. [PubMed]
11. Trnka HJ, Zettl R, Ritschl P. Fracture of the anterior superior process of the calcaneus: an often misdiagnosed fracture. *Arch Orthop Trauma Surg*. 1998;117(4-5):300-2. [PubMed]
12. Penner MJ. Late reconstruction after navicular fracture. *Foot Ankle Clin*. 2006 Mar;11(1):105-19, ix. [PubMed]
13. Reddy V, Fukuda T, Ptaszek AJ. Calcaneus malunion and nonunion. *Foot Ankle Clin*. 2007 Mar;12(1):125-35. [PubMed]

## Unusual Variant of the Nutcracker Fracture of the Calcaneus and Tarsal Navicular

14. Grala P, Mankowski B, Machynska-Bucko Z. Complications of dislocated calcaneal fractures. *Ortop Traumatol Rehabil.* 2007 Mar-Apr;9(2):198-205. [PubMed]

15. Ceroni D, De Rosa V, De Coulon G, Kaelin A. The importance of proper shoe gear and safety stirrups in the prevention of equestrian foot injuries. *J Foot Ankle Surg.* 2007 Jan-Feb;46(1):32-9. [PubMed]