

Pyoderma Gangrenosum after Breast Cancer Resection: A Less-invasive and Early Treatment Using the Skin around Ulcers

Kotaro Hirai, MD*

Itaru Tsuge, MD, PhD*

Shunya Usui, MD†

Masahiro Takada, MD, PhD‡

Hiroki Yamanaka, MD, PhD*

Motoki Katsube, MD, PhD*

Michiharu Sakamoto, MD, PhD*

Naoki Morimoto, MD, PhD*

Summary: Surgical invasion is a risk factor of pyoderma gangrenosum (PG). A total of 25% of postoperative PG cases were reported to occur after breast surgeries, including bilateral breast reduction and breast reconstruction following cancer resection. Immunosuppressive therapy and less-invasive wound therapy are necessary; however, the complete healing of ulcers takes 5.1 months on average. We herein report a case of skin grafting under a surgical concept of less-invasive and short-term treatment. An 82-year-old woman complained of a high fever and severe pain at her breast wounds after bilateral breast cancer resection. Although we performed emergency debridement surgery to remove the necrotic tissue, suspecting surgical site infection and inflammation, her high fever persisted. She was diagnosed with PG because of the physical findings of characteristic painful, sterile ulcerations, bullae and pustules, and the pathological abundance of neutrophils in the absence of infection and vasculitis. Oral administration of prednisolone 30 mg/day improved the symptoms, and we applied negative-pressure wound therapy (NPWT) from day 16 following debridement surgery. After the gradual reduction of oral steroid intake to 12.5 mg/day, we performed skin grafting surgery. To limit the surgical invasion, we used the surplus skin around the ulcers. Split-thickness mesh skin grafts were fixed by NPWT to avoid the use of tie-over sutures. We achieved short-term treatment of PG with a less-invasive surgical strategy using skin around the ulcers and NPWT. (*Plast Reconstr Surg Glob Open* 2022;10:e4111; doi: 10.1097/GOX.0000000000004111; Published online 15 February 2022.)

Poderma gangrenosum (PG) is an uncommon ulcerative inflammatory skin disease characterized by a pathophysiological mechanism involving neutrophil dysfunction, but the detailed etiology is unclear.¹ Surgical invasion is a risk factor, and 25% of postoperative PG cases reportedly occur after breast surgeries, including bilateral breast reduction (45%), breast reconstruction following cancer resection (25%), and lumpectomy or mastectomy (11%).² Immunosuppressive therapy avoiding surgical debridement is the first-line treatment. After

the gradual reduction of immunosuppression, negative-pressure wound therapy (NPWT) and skin grafting can be applied to cure the painful ulcers quickly.³ However, there are two issues to consider: the timing of skin grafting surgery and the risk of creating another ulcer at the skin donor site. We herein report a case of skin grafting under a surgical concept of less-invasive and short-term treatment.

CASE

An 82-year-old woman with a history of chronic renal failure with hemodialysis therapy was introduced to our plastic surgery team because of a high fever and severe pain of the breast wounds after bilateral breast cancer resection performed 12 days earlier (Fig. 1). The symptoms began from postoperative day 4 and worsened.

A physical examination revealed the following: blood pressure, 81/46 mm Hg; pulse, 63 beats/min; body temperature 37.3°C. A blood test showed the following: WBC,

From the *Department of Plastic and Reconstructive Surgery, Graduate School of Medicine, Kyoto University, Kyoto, Japan; †Department of Dermatology, Graduate School of Medicine, Kyoto University, Kyoto, Japan; and ‡Department of Breast Surgery, Graduate School of Medicine, Kyoto University, Kyoto, Japan.

Received for publication October 12, 2021; accepted December 14, 2021.

Copyright © 2022 The Authors. Published by Wolters Kluwer Health, Inc. on behalf of The American Society of Plastic Surgeons. This is an open-access article distributed under the terms of the [Creative Commons Attribution-Non Commercial-No Derivatives License 4.0 \(CCBY-NC-ND\)](https://creativecommons.org/licenses/by-nc-nd/4.0/), where it is permissible to download and share the work provided it is properly cited. The work cannot be changed in any way or used commercially without permission from the journal.

DOI: 10.1097/GOX.0000000000004111

Disclosure: The authors have no financial interest to declare in relation to the content of this article.

Related Digital Media are available in the full-text version of the article on www.PRSGlobalOpen.com.

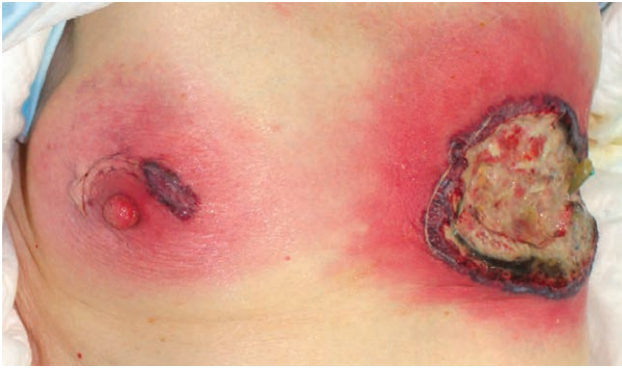

Fig. 1. Rapid development of painful bilateral ulcers along incision sites 12 days after breast cancer resection.

22,740/ μ L; PLT, 199,000/ μ L; CRP, 16.7 mg/dL; CK, 8 U/L; Cre, 5.7 mg/dL. On the day of introduction, we performed emergency surgery under general anesthesia, resecting the edges of necrotic ulcers, including the strongly reddish skin and subcutaneous necrotic tissue, until we reached the surface of the muscular layer. (See figure, Supplemental Digital Content 1, which shows intraoperative findings of surgical debridement: the findings on day 18, 25 and 30 after debridement surgery, the findings on day 6, 13 and 34 after skin grafting surgery, and the postoperative findings at 6 months. <http://links.lww.com/PRSGO/B924>.) The opened wounds were washed every day; however, a fever around 38°C persisted. All of the blood cultures and wound cultures, including the intraoperative samples, were negative, and a blood test on day 4 after debridement surgery showed WBC, 20,190/ μ L; PLT, 217,000/ μ L; CRP, 14.0 mg/dL; CK, 10 U/L; and Cre, 5.7 mg/dL. The clinical course differed markedly from those seen with the suspected bacterial infections and necrotizing soft tissue infections; therefore, we consulted dermatologists about the cause of the ulcers. They diagnosed the patient with PG because of the physical findings of characteristic painful, sterile ulcerations, bullae and pustules (Fig. 2), and pathological abundance of neutrophils in the absence of infection and vasculitis (See figure 2, Supplemental Digital Content 2, which shows histopathological examination [H&E] findings of massive neutrophil and inflammatory cell in the

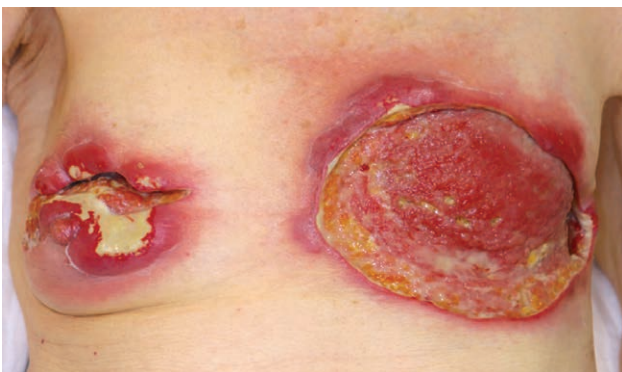

Fig. 2. The findings on day 9 after debridement surgery. The characteristic necrotic ulcer with an irregular, violaceous and undermined border indicated pyoderma gangrenosum.

dermis. Scale bar: 100 μ m. <http://links.lww.com/PRSGO/B925>.) Oral administration of prednisolone 30 mg/day from day 10 after debridement surgery improved the symptoms of erythema and pain while reducing the discharge from wounds. We performed NPWT (V.A.C. Ultra; KCI, San Antonio, Tex.) with a negative pressure of 125 mm Hg and instillation and dwelling every 4h from day 16 after debridement surgery. After gradually reducing the oral steroid intake to 12.5 mg/day, we planned to perform skin grafting surgery. (Supplemental Digital Content 1, <http://links.lww.com/PRSGO/B924>.) (Supplemental Digital Content 2, <http://links.lww.com/PRSGO/B925>.)

Two potential risks of surgical failure were of concern: (1) skin grafting failure because of the wound healing suppression induced by steroid intake, and (2) PG recurrence at the donor site, such as the abdominal or inguinal part. The patient's bilateral breast wounds indeed showed thin, shiny, and smooth granulation, which made us predict the difficulty of stable engraftment even after NPWT (Supplemental Digital Content 1, <http://links.lww.com/PRSGO/B924>). Therefore, we planned to limit the surgical invasion by obtaining a skin graft from the breast region near the PG ulcer and by avoiding the use of tie-over sutures to fix the skin grafts.

Skin grafting surgery was performed on day 38 after debridement surgery. First, we performed suture closure while obtaining surplus skin from the right breast and lateral left breast wounds after wound bed preparation using NPWT for 3 weeks (Fig. 3A). The skin grafts from the bilateral breast were thinned from full-thickness into split-thickness skin grafts 0.025 inches using Padgett-Hood dermatome. The residual left breast wound was then covered

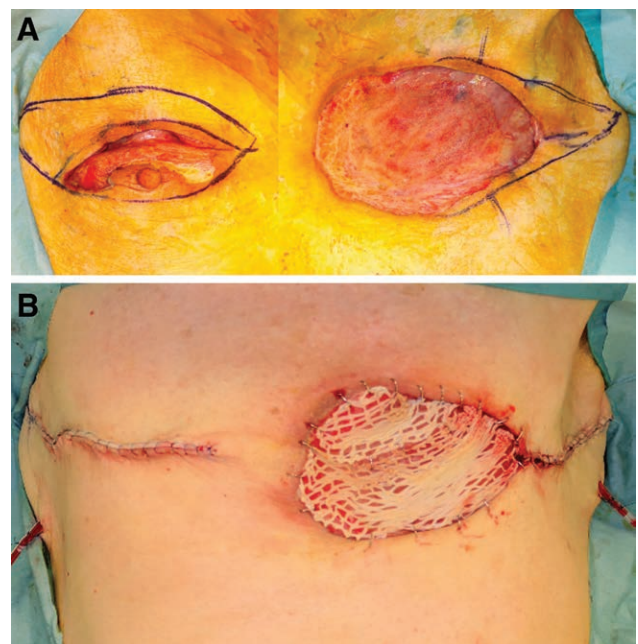


Fig. 3. Intraoperative findings on day 38 after debridement surgery. Skin grafts were obtained from the right breast and lateral part of the left breast (A). Split-thickness skin grafts of 0.025 inches were fixed by NPWT (B).

by the split-thickness skin grafts, which were processed by mesh dermatome to make multiple drainage pores. Finally, the skin graft was positioned to the wound area using skin staplers and fixed by V.A.C. Ultra without using a tie-over suture dressing to reduce the damage to the skin around the ulcer (Fig. 3B).

The postoperative course was excellent (Supplemental Digital Content 1, <http://links.lww.com/PRSGO/B924>), and she was discharged on day 74 after the first surgery for her breast cancer. Oral prednisolone intake was gradually reduced and ultimately finished two months after discharge. No recurrence of ulcers was detected for six months.

DISCUSSION

Treatment of PG can take a long time to complete because of the difficulty making a diagnosis and the need for low-invasiveness therapy with immunosuppressive therapy. A systematic literature review of PG after breast surgery indicated that complete wound healing took 5.1 months on average.⁴ Another systematic review showed a high skin grafting failure rate of 25% among cases of PG related to breast surgery; furthermore, the donor site of breast reconstruction resulted in abdominal PG ulcers in six cases.⁵

The key to successful short-term treatment is performing skin grafting surgery as early as possible; however, the risk of unsuccessful skin grafting and donor-site ulceration hamper surgeons' decisiveness. We used surplus skin around the ulcers to avoid the risk of creating further ulcers, such as in the abdominal and inguinal areas. Evidence supporting the utility of NPWT for PG is accumulating,^{3,6,7} and Eisendle et al insisted that the best surgical approach is a split-thickness skin graft fixed with NPWT.⁸ We also performed NPWT for the preoperative wound bed preparation and postoperative skin graft fixation. Surgical invasion of suturing procedures is reported to exacerbate PG ulceration⁹; therefore, a strategy of not using tie-over suture fixation is a good approach.

Surgical reconstruction of PG is indeed challenging, as the treatment itself has the severe risk to induce pathergy.¹⁰ Moreover, medication such as corticosteroids and immunosuppressants decrease the success rate of split-thickness skin grafting.¹¹ Our case showed thin, shiny, and smooth granulation even after 3-weeks NPWT under steroid medication. We recommend fail-safe surgical strategy in breast PG cases by minimizing the risk of creating new PG ulcers, which enables aggressive decision-making concerning skin grafting surgery and successful short-term treatment.

CONCLUSIONS

We performed short-term treatment with less-invasive skin grafting using NPWT and the skin around the breast ulcers as a donor. Minimizing the risk of another PG ulcer is essential in such cases.

Itaru Tsuge, MD, PhD

Department of Plastic and Reconstructive Surgery
Graduate School of Medicine, Kyoto University
54 Shogoin Kawahara-cho, Sakyou-ku
Kyoto 606-8507
Japan

E-mail: itsuge@kuhp.kyoto-u.ac.jp

REFERENCES

1. Braswell SF, Kostopoulos TC, Ortega-Loayza AG. Pathophysiology of pyoderma gangrenosum (PG): an updated review. *J Am Acad Dermatol.* 2015;73:691–698.
2. Zuo KJ, Fung E, Tredget EE, et al. A systematic review of post-surgical pyoderma gangrenosum: identification of risk factors and proposed management strategy. *J Plast Reconstr Aesthet Surg.* 2015;68:295–303.
3. Almeida IR, Coltro PS, Gonçalves HOC, et al. The role of negative pressure wound therapy (NPWT) on the treatment of pyoderma gangrenosum: a systematic review and personal experience. *Wound Repair Regen.* 2021;29:486–494.
4. Ehrl DC, Heidekrueger PI, Broer PN. Pyoderma gangrenosum after breast surgery: a systematic review. *J Plast Reconstr Aesthet Surg.* 2018;71:1023–1032.
5. Tuffaha SH, Sarhane KA, Mundinger GS, et al. Pyoderma gangrenosum after breast surgery: diagnostic pearls and treatment recommendations based on a systematic literature review. *Ann Plast Surg.* 2016;77:e39–e44.
6. Kostaras EK, Tansarli GS, Falagas ME. Use of negative-pressure wound therapy in breast tissues: evaluation of the literature. *Surg Infect (Larchmt).* 2014;15:679–685.
7. Pichler M, Thuile T, Gatscher B, et al. Systematic review of surgical treatment of pyoderma gangrenosum with negative pressure wound therapy or skin grafting. *J Eur Acad Dermatol Venereol.* 2017;31:e61–e67.
8. Eisendle K, Thuile T, Deluca J, et al. Surgical treatment of pyoderma gangrenosum with negative pressure wound therapy and skin grafting, including xenografts: personal experience and comprehensive review on 161 cases. *Adv Wound Care (New Rochelle).* 2020;9:405–425.
9. Long CC, Jessop J, Young M, et al. Minimizing the risk of post-operative pyoderma gangrenosum. *Br J Dermatol.* 1992;127:45–48.
10. Tay DZ, Tan KW, Tay YK. Pyoderma gangrenosum: a commonly overlooked ulcerative condition. *J Family Med Prim Care.* 2014;3:374–378.
11. Kaddoura IL, Amm C. A rationale for adjuvant surgical intervention in pyoderma gangrenosum. *Ann Plast Surg.* 2001;46:23–28.