



Original Research

Salvage of the Exposed Cardiac Pacemakers With Fasciocutaneous Local Flaps

Alper Aksoy,¹ Dağhan Dağdelen,² Selami Serhat Şirvan³

¹Department of Plastic Reconstructive and Aesthetic Surgery, Konur Hospital, Bursa, Turkey

²Department of Plastic Reconstructive and Aesthetic Surgery, Balıkesir State Hospital, Balıkesir, Turkey

³Department of Plastic Reconstructive and Aesthetic Surgery, Health Sciences University, Sisli Hamidiye Etfal Training and Research Hospital, Istanbul, Turkey

Abstract

Objectives: This study aims to investigate the efficacy of salvage of the mechanically exposed cardiac pacemakers with fasciocutaneous local flaps in elderly patients.

Methods: Between January 2014 and January 2018, ten patients (six females, four males; mean age 66.2 years) who were treated due to pacemaker exposition were retrospectively analyzed in this study. Exposed pacemaker and the wires were dissected, and capsulectomy was performed. The exposed pacemaker was covered with the fasciocutaneous flap.

Results: Only one patient had hematoma formation at early stage and revision was performed. All patients were treated successfully. No complication was observed during the follow-up period.

Conclusion: Reconstruction with fasciocutaneous local flaps is an effective treatment modality in case of mechanically cardiac pacemaker expositions in elderly patients.

Keywords: Elderly patient; fasciocutaneous local flap; mechanically exposed; pacemaker.

Please cite this article as "Aksoy A, Dağdelen D, Şirvan SS. Salvage of the Exposed Cardiac Pacemakers With Fasciocutaneous Local Flaps. Med Bull Sisli Etfal Hosp 2020;54(1):98–102".

Approximately 45 years pacemakers are being used in clinical practice. It has been reported that approximately 600.000 pacemakers are newly implanted each year.^[1] Important problems in monitorization of pacemakers include electrode replacement and battery infection. Although the infection usually develops in the area where the battery is placed, infections that stemmed from electrode catheter have also been identified.^[2] Infections are most common in the first eight weeks after implantation of the battery. It is thought that the cause of early infections encountered within these first eight weeks was contamination during placement of the implant. Long-term infections involving pacemakers may lead to complications, such as

erosion, fistula, battery exposure and even endocarditis related to electrode catheter.^[3,4]

Advanced age-related skin atrophies without any infection and mechanical exposures can be seen in pacemakers implanted in inappropriate sites.^[5] Considering the number of patients with pacemakers, we think that mechanical exposures, which are among the rare complications, are encountered more frequently than reported. When the literature is reviewed, a limited number of current articles on this complication are found, and many of them recommend different treatment methods.

In this study, we aimed to share the cases we have treated in our clinic and discuss the current literature.

Address for correspondence: Alper Aksoy, MD. Konur Hastanesi, Plastik Rekonstruktif ve Estetik Cerrahi Klinigi, Bursa, Turkey

Phone: +90 224 400 44 42 **E-mail:** aksoya@gmail.com

Submitted Date: April 24, 2018 **Accepted Date:** June 01, 2018 **Available Online Date:** March 24, 2020

©Copyright 2020 by The Medical Bulletin of Sisli Etfal Hospital - Available online at www.sislietfaltip.org

OPEN ACCESS This is an open access article under the CC BY-NC license (<http://creativecommons.org/licenses/by-nc/4.0/>).



Methods

Ten patients who underwent repair with fasciocutaneous flaps due to pacemaker exposure between January 2014 and January 2018 were examined retrospectively in this study. As an evaluation criteria, patient demographic data, time between implanted pacemaker and exposure, culture results obtained during the operation, flap sizes used in repair, early and late complications encountered in the post-operative period were determined. While evaluating the study findings, IBM 23.0 statistical analysis package program was used for statistical analysis. Descriptive statistical methods (mean, percent, median) were employed.

Surgical Technique

Following excision of a triangular area where the exposure of the pacemaker was detected, total capsulectomy was performed to remove the battery unit. The lodge of the extracted battery was irrigated with a solution containing rifamycin. Without making any change in the location where the pacemaker is to be placed, a fasciocutaneous rotation flap including the pectoral muscle fascia was elevated, and complete closure of the surgical wound was achieved. In the adaptation of the flap, for closure of subcutaneous tissue polyglactin circle round bodied 4/0 sutures, and for skin polypropylene 5/0 solid sutures were used. Active or passive drains were placed in the lodge. A sample from the extracted capsule was sent for microbiology for antimicrobial culture.

Results

All of the patients had mechanical exposure. In the cultures of the samples excised from the capsule taken the operation, skin flora grew. The period between the implantation of pacemaker and exposure ranged between 17-36 months (mean 23 months). The patients were followed up for 8 to 15 months (average nine months). Patients were followed up for two to four days (mean 2.5 days) in the service under 1st generation cephalosporin antibiotherapy until the growth of skin flora was observed in the culture. Then, the patient was discharged with recommendations concerning local wound care. In patients using acetylsalicylic acid as anticoagulant therapy, injection of low molecular weight heparin was started three days before the operation in accordance with the recommendation of cardiology. Acetylsalicylic acid treatment was resumed on the 3rd postoperative day.

In the follow-up of the patient, no problem was encountered except for a hematoma. In this patient, the hematoma was drained under local anesthesia. There was no problem during the follow-up of the patient.

Case 1

A 72-year-old female patient was referred to us because of the partial exposure of the pacemaker implanted five years ago (Fig. 1). Any findings of clinical infection, such as fever, purulent discharge or diffuse erythema, were not detected in the physical examination. White blood cell counts were within normal limits. Debridement of the wound and elevation of skin rotation flap under general anesthesia were planned (Fig. 2).

Intraoperatively total capsulectomy was performed to remove the pacemaker unit. The skin where the exposure was detected was excised in the form of a triangle. The tissue plan was irrigated with a solution containing rifamycin. The tissue plan of the pacemaker was not changed.

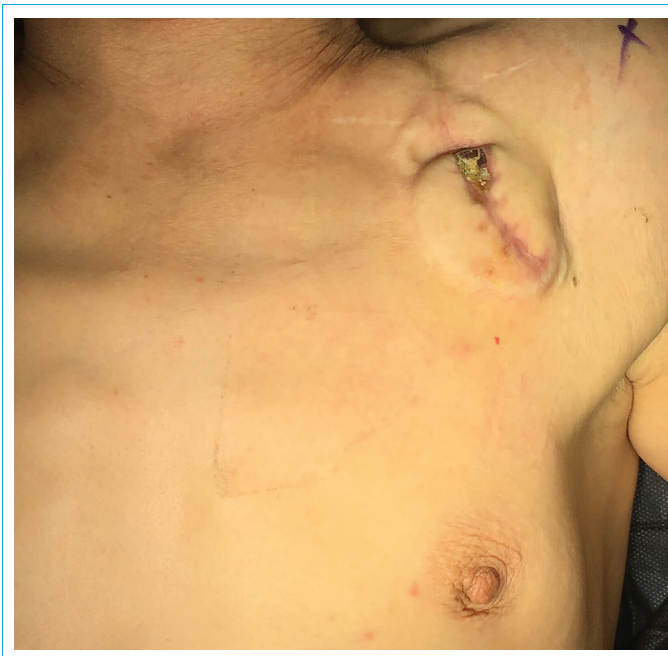

Figure 1. Exposed cardiac pacemaker.

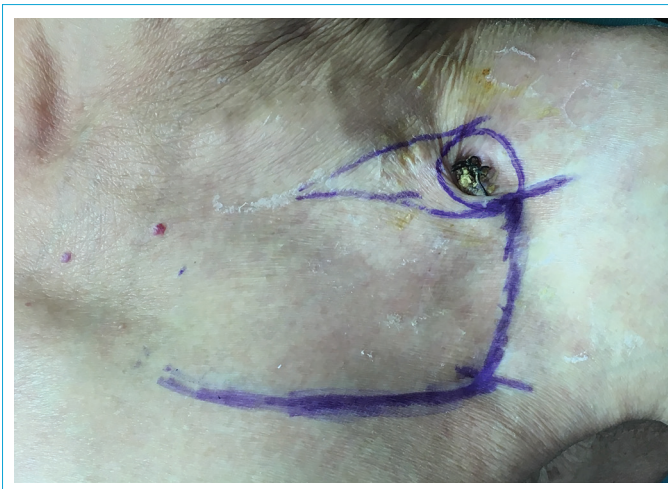


Figure 2. Illustration of a flap.

The application of a rotation flap was planned. The rotation fasciocutaneous flap containing the pectoral muscle fascia was elevated, and the pacemaker was covered completed. A sample excised from the extracted capsule was sent to microbiology for culture.

Case 2

A 78-year-old female patient consulted to our clinic due to the exposure of the pacemaker from the skin. There were limited erythema and tenderness in the area where the pacemaker was exposed from the skin. No purulent discharge was detected; the number of white blood cells was within normal limits. The proposal for adaptation of the pacemaker into a contralateral subclavian pocket was rejected by the cardiology clinic for technical reasons. The patient was then prepared for operation under local wound care and systemic antibiotherapy.

Under general anesthesia, the skin where the exposure was detected was excised. Total capsulectomy was performed on the parts of the pacemaker and cables exposed in the surgical field and samples excised from the capsule were sent for culture. The pacemaker lodge was irrigated with rifamycin containing a solution. Any change in the plan of the pacemaker was not made. To close the defect created, the rotation flap, which contained the pectoral muscle fascia, was elevated (Fig. 3) and adapted to the defect. Any problem was not experienced during postoperative follow-up (Fig. 4).

Discussion

Among the complications of the pacemaker, the rate of pacemaker exposure from the skin has been reported to

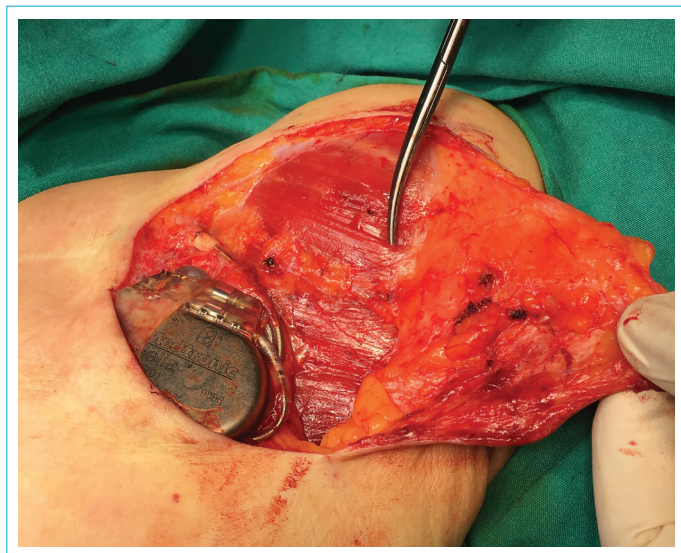


Figure 3. Elevation of latissimus muscle together with fasciocutaneous flap.

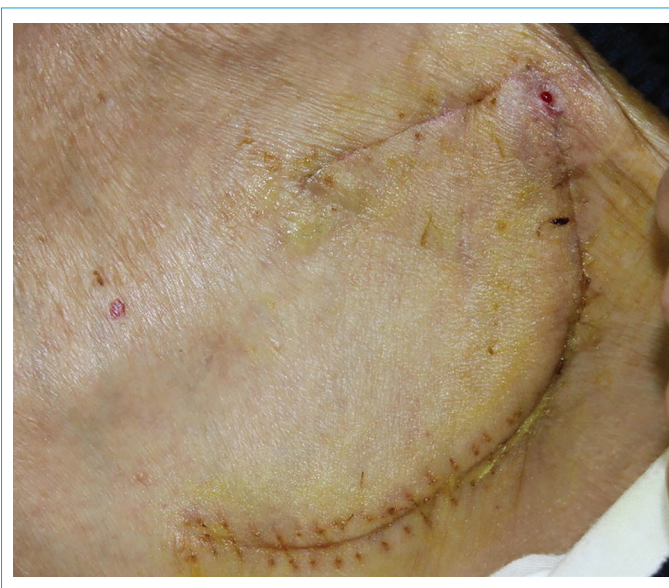

Figure 4. Immediate and early-stage postoperative follow-up.

range between 0% and 12.6% in different series.^[2] It is assumed that exposure develops as a result of mechanical forces or infection. We think that in the cases we shared these exposures occur as a result of atrophy developed as a consequence of aging and mechanical irritation of pacemaker.

When evaluating an exposed pacemaker, the presence of clinical infection should be excluded. Generally, the infection is manifested by pathologic changes in the skin. In cases accompanied by cutaneous changes or purulent discharge, rapid initiation of treatment is important in terms of reducing the risk of endocarditis that can progress through electrode cables.^[3] In these cases, there are solutions to this condition, such as taking the pacemaker unit into the contralateral subclavian area, using an external pacemaker until the clinical picture regresses. However, this approach has complications, such as rupture, bleeding, tamponade in the heart muscle.^[2-4]

In mechanical exposures not associated with infection, the main reason is unknown. In older people, with the decrease of subcutaneous adipose tissue, in skin elasticity and tone, the risk of mechanical exposure of batteries placed in the subcutaneous plan may increase.^[5] Another reason is that, as with breast implants, the capsule formed around the battery contracts, causing skin pressure and configurational changes.^[6, 7]

There are different opinions in the literature regarding the approach to exposure cases not accompanied by clinical infection. The pacemaker and electrode cables are taken into an intrafascial or intramuscular pocket and primary repair of the skin is a commonly used method.^[8, 9]

Although muscular flaps are recommended for the prevention of infection and using a hyperemic and thicker tissue in the exposures caused by the infection, it has been stated that the twitches of pectoral muscle in the submuscular location are quite uncomfortable for the patients.^[2] There is also a series where the partial latissimus dorsi muscle is passed through a subcutaneous tunnel over the thoracoacromial pedicle, along with the skin island, to cover the pacemaker.^[10] The long operation time and the use of a secondary surgical field can be considered as negative aspects of this method.

In breast surgery, in the exposures developed in the implants used, preventive approaches for the recovery of the implant are becoming more common.^[11] In chronic osteomyelitis and diabetic foot wounds, the use of muscle flaps has been discussed. It has been argued that free/perforating fasciocutaneous flaps can provide a safe coverage and resistance to infection.^[12] In parallel with these trends, we think that covering the exposed pacemakers with fasciocutaneous flaps can be a safe approach.

With the introduction of lithium iodine batteries in pacemakers, there has been a reduction in the size of the main unit. Although different manufacturers have units of different sizes, the average dimensions are 45 mmx52 mmx7 mm.^[1] When a flap option is planned for the exposed pacemaker, these sizes should be considered for safe covering. We preferred to use the rotation flap, which is translated from the same area. Another point to note is the use of electrocautery. Pacemakers contain a titanium coating to reduce subcutaneous irritation and protect technical equipment.^[1, 2]

This coating provides sufficient insulation for both monopolar and bipolar cauters.^[13] However, we recommend that cautery use to be planned with the cardiology clinic before the scheduled surgical procedure.

Although in their series Bonawitz et al., idealize covering the pacemaker within 48 hours in exposure cases not accompanied by infection.^[2] It is quite difficult for us to complete the patient's preparation for the operation within this period, especially due to the presence of other concomitant diseases in the geriatric population. In his series, Toia et al. performed the post-exposure repair on the 27th day^[13] and Kim at the 7th week.^[10] In exposures that are not accompanied by clinical infection, it has been stated that reproduction in culture is not related to recurrence and has no effect on the success of the result.^[2, 10, 13] An extended capsulectomy and irrigation of the region are the main determining steps. Before the procedure, the wound should be considered clean-contaminated and appropriate surgical prophylaxis should be performed.

In our series, skin flora grew in the wound culture. Concerning surgical approach, although we recommend sending all capsulectomy materials for culture, how this approach will change the treatment in the postoperative period is open to discussion. Toia et al. did not use antibiotherapy after surgery in any one of the 17 patients with different subcutaneous pacemakers and stated that they did not detect any infection during follow-ups and reported that they encountered recurrence in only one case.^[13]

Conclusion

With the increasing elderly population and the increase in the number of patients with permanent implants, the frequency of such cases in plastic surgery practice will increase. It is important to exclude the presence of clinical infections when planning the treatment of these cases. Capsulectomy, irrigation of the lodge, compliance with surgical wound care and prophylaxis is a critical step. Subsequently, it is preferable to use non-complex, durable (preferably fasciocutaneous flaps) covering options. There is a lack of an inclusive algorithm in the literature. Relevant studies should be conducted.

Disclosures

Ethics Committee Approval: Retrospective study.

Peer-review: Externally peer-reviewed.

Conflict of Interest: None declared.

Authorship Contributions: Concept – A.A., D.D.; Design – A.A., D.D., S.S.S.; Supervision – A.A., D.D.; Materials – A.A., S.S.S.; Data collection &/or processing – D.D., S.S.S.; Analysis and/or interpretation – A.A., D.D., S.S.S.; Literature search – D.D., S.S.S.; Writing – A.A., D.D., S.S.S.; Critical review – A.A., S.S.S.

References

1. Mallela VS, Ilankumaran V, Rao NS. Trends in cardiac pacemaker batteries. *Indian Pacing Electrophysiol J* 2004;4:201–12.
2. Bonawitz SC. Management of exposure of cardiac pacemaker systems. *Ann Plast Surg* 2012;69:292–5.
3. Chua JD, Wilkoff BL, Lee I, Juratli N, Longworth DL, Gordon SM. Diagnosis and management of infections involving implantable electrophysiologic cardiac devices. *Ann Intern Med* 2000;133:604–8.
4. Farooqi FM, Talsania S, Hamid S, Rinaldi CA. Extraction of cardiac rhythm devices: indications, techniques and outcomes for the removal of pacemaker and defibrillator leads. *Int J Clin Pract* 2010;64:1140–7.
5. Griffith MJ, Mounsey JP, Bexton RS, Holden MP. Mechanical, but not infective, pacemaker erosion may be successfully managed by re-implantation of pacemakers. *Br Heart J* 1994;71:202–5.
6. Arciola CR, Campoccia D, Speziale P, Montanaro L, Costerton JW. Biofilm formation in *Staphylococcus* implant infections. A review

- of molecular mechanisms and implications for biofilm-resistant materials. *Biomaterials* 2012;33:5967–82.
7. Rieger UM, Mesina J, Kalbermatten DF, Haug M, Frey HP, Pico R, et al. Bacterial biofilms and capsular contracture in patients with breast implants. *Br J Surg* 2013;100:768–74.
 8. Garcia-Rinaldi R, Revuelta JM, Bonnington L, Soltero-Harrington L. The exposed cardiac pacemaker. Treatment by subfascial pocket relocation. *J Thorac Cardiovasc Surg* 1985;89:136–41.
 9. Fayman MS, Chait LA, Orak F. A subpectoral pocket in the management of a patient with impending extrusion of a pulse generator. *Plast Reconstr Surg* 1986;78:182–5.
 10. Kim SW, Thorat TS, Kim JT, Kim YH. Delayed management of exposed pacemaker with partial latissimus dorsi myocutaneous flaps. *J Thorac Cardiovasc Surg* 2016;152:1450–1.
 11. Prince MD, Suber JS, Aya-Ay ML, Cone JD Jr, Greene JN, Smith DJ Jr, et al. Prosthesis salvage in breast reconstruction patients with periprosthetic infection and exposure. *Plast Reconstr Surg* 2012;129:42–8.
 12. Hong JPJ, Goh TLH, Choi DH, Kim JJ, Suh HS. The Efficacy of Perforator Flaps in the Treatment of Chronic Osteomyelitis. *Plast Reconstr Surg* 2017;140:179–88.
 13. Hong JPJ, Goh TLH, Choi DH, Kim JJ, Suh HS. The Efficacy of Perforator Flaps in the Treatment of Chronic Osteomyelitis. *Plast Reconstr Surg* 2017;140:179–88.