


## CLINICAL ARTICLE

# Original Designed Uniportal-Bichannel Spinal Endoscopic System (UBiSES) for Foraminoplasty in Percutaneous Endoscopic Transforaminal Discectomy

Zhi Zhou<sup>1,2#</sup>, Hai-jian Ni<sup>1#</sup>, Shuo Hu<sup>3</sup>, Yun-shan Fan<sup>1,2</sup>, Chuan-feng Wang<sup>1</sup>, Xin Chen<sup>1,2</sup>, Yan-jie Zhu<sup>1,2</sup>, Gang Li<sup>2</sup>, Fei Liu<sup>1</sup>, Chao-bo Feng<sup>1,2</sup>, Shi-sheng He<sup>1,2</sup> 

<sup>1</sup>Orthopaedics Department, Shanghai Tenth People's Hospital and <sup>2</sup>Spinal Pain Research Institute, Tongji University School of Medicine and

<sup>3</sup>Orthopaedics Department, Shanghai General Hospital, Shanghai Jiao Tong University, School of Medicine, Shanghai, China

**Objective:** The study introduced uniportal-bichannel spinal endoscopic system (UBiSES) and explored the feasibility of applying UBiSES to conduct lumbar foraminoplasty in percutaneous endoscopic transforaminal discectomy (PETD).

**Methods:** This is a cohort study. 36 patients confirmed as L5/S1 lumbar disc herniation (LDH) in our hospital from March, 2019 to November, 2019 were enrolled. 36 patients were divided into two groups named the UBiSES group (n = 18, male: female = 8:10) and the TESSYS group (n = 18, male: female = 10:8). The average age of the UBiSES group and the TESSYS group were 40.94 ± 12.39 years old and 39.78 ± 13.02 years old respectively. PETD via uniportal-bichannel foraminoplasty assisted by UBiSES was adopted on the UBiSES group while PETD via conventional foraminoplasty was performed on the TESSYS group. One experienced surgeon with more than 4000 cases of lumbar surgery performed PETD on all patients. The demographic data, the duration of working cannula placement (minutes), decompression time (minutes), radiation exposure time (seconds), complications, Visual Analogue Scale (VAS), Oswestry Disability Index (ODI) scores and modified MacNab criteria were recorded and analyzed. The magnetic resonance imaging (MRI) and computed tomography (CT) were conducted to evaluate the radiographic improvement.

**Results:** PETD via lumbar foraminoplasty was successfully performed in all cases. The follow-up points were 3 months, 6 months, and 12 months. The average follow-up period of all patients was 15.78 ± 2.29 months. There was no statistic difference in age (P = 0.81), sex (P = 0.51) and follow-up (P = 0.14) between two groups. The duration of working cannula placement was 19.08 ± 2.30 min in the UBiSES group and 24.90 ± 4.71 min in the TESSYS group and there was significant difference between two groups (P < 0.05). There was no statistic difference in decompression time between the UBiSES group (44.18 ± 5.70 min) and the TESSYS group (47.46 ± 5.96 min) (P = 1.70). The radiation exposure time was 28.00 ± 4.70 s in the UBiSES group and 40.50 ± 5.73 s in the TESSYS group respectively, and has significant difference between two groups (P < 0.05). Furthermore, there was significant different in the duration of working cannula placement and radiation exposure time in male or female between the UBiSES group and the TESSYS group (P < 0.05). For male or female, no difference observed in decompression time and follow-up period between two groups. Postoperative VAS of low back and leg at every follow-up point (1 day, 3 months, 6 months, 12 months) was improved significantly in both groups compared with their preoperative VAS (P < 0.05). The postoperative ODI (3 months, 6 months, 12 months) has decreased significantly in both the UBiSES group and the TESSYS group compared with their preoperative ODI (P < 0.05). 94.44% patients received an excellent or good

**Address for correspondence** Shi-sheng He, Orthopaedics Department, Shanghai Tenth People's Hospital, Tongji University School of Medicine, Shanghai, China 200070 Tel: 13761645238; Fax: 66307270; Email: tjhss7418@tongji.edu.cn

<sup>#</sup>Zhi Zhou and Hai-jian Ni contributed equally to this work.

**Authorship declaration:** All authors listed meet the authorship criteria according to the latest guidelines of the International Committee of Medical Journal Editors and are in agreement with the manuscript.

**Disclosure statement:** There were no any potential conflicts of interest among all authors.

Received 28 November 2020; accepted 17 April 2021

recovery in the UBiSES group and 88.89% for the TESSYS group. There was no poor result reported in both groups. The radiographic images showed satisfactory foraminoplasty and sufficient decompression of nerve in both groups. No postoperative complications were observed during follow-ups in the UBiSES group. Two patients in the TESSYS group experienced postoperative dysesthesia and the symptom was disappeared in 5 days and 7 days respectively with dexamethasone and neurotrophic drugs treatment.

**Conclusions:** The original designed UBiSES could effectively and safely enlarge the foramen with an extensive surgical view and space under full-time and real-time visualization and get satisfactory efficacy.

**Key words:** Minimally invasive spinal surgery; Percutaneous endoscopic transforaminal discectomy; Radiation exposure; Uniportal-bichannel endoscopic foraminoplasty; Visualization

## Introduction

Lumbar disc herniation (LDH) is one of the main culprits that cause low back pain and leg pain, which is a worldwide common health problem and increases a heavy economic burden to individuals, families and society<sup>1</sup>. The treatment for LDH includes surgery and conservative therapy. Lumbar surgery is recommended when conservative therapy failed after at least 3 months. Lumbar surgery mainly divides into traditional open surgery and minimally invasive spinal surgery (MISS). According to the rapid development of surgical instruments, surgical techniques and surgical concept, MISS becomes more and more popular compared with traditional open surgery these years. As a representative MISS, percutaneous endoscopic lumbar discectomy (PELD) has become a promising surgical option for LDH, due to several merits such as less paraspinous muscle injury, less bleeding, short hospital stay, rapid recovery and low risks of iatrogenic instability<sup>2</sup>. PELD refers to percutaneous endoscopic interlaminar discectomy (PEID) and percutaneous endoscopic transforaminal discectomy (PETD). PEID was proposed by Ruttens in 2006 and employs interlaminar approach<sup>3</sup>. PETD utilizes transforaminal approach and mainly includes two surgical strategies, Yeung endoscopic spine system (YESS) reported by Yeung and transforaminal endoscopic spine system (TESSYS) reported by Hoogland<sup>4,5</sup>. TESSYS is an “outside-in” technique while YESS is an “inside-out” technique, and TESSYS has more extensive indications compared with YESS<sup>6</sup>. In clinic, TESSYS is often adopted for PETD. TESSYS allows the surgeon to perform surgery through a single-channel working cannula, however, the placement of working cannula is difficult in some L5/S1 LDH cases with high iliac crest and hypertrophic transverse process, especially for young surgeons<sup>2,7</sup>. The failure of working cannula placement may lead to surgical failure and the superior articular process (SAP) is the main obstacle of placing the working cannula. To address this, foraminoplasty is developed to enlarge the narrow foramen to obtain a clear view of the disc fragments and get extensive operative space for decompression<sup>8</sup>. Foraminoplasty could facilitate placement of the working cannula. Actually, as a crucial procedure, foraminoplasty is recommended as a routine step in PETD<sup>9,10</sup>.

The conventional PETD supported by TESSYS technique uses sequential trephines and reamers to cut part of

SAP step by step assisted by fluoroscopy to achieve foraminoplasty<sup>11</sup>. However, there are some defects should be noticed. First, TESSYS requires an accurate puncture and surgical trajectory that needs the tip of the puncture needle to reach the middle line on the anteroposterior fluoroscopy and the vertebral posterior superior margin on the lateral fluoroscopy. It means TESSYS is an experience-relied and fluoroscopy-relied technique, which leads to a steep learning curve of PETD, massive radiation exposure to surgeons and long operation time<sup>12</sup>. Second, the articular face of lumbar facet joints is an oblique slope, trephines and reamers applied in TESSYS are difficult to control the direction of foraminoplasty, which may make the direction of foraminoplasty deviated into ventral side that may cause neural injury and surgical failure. Also, the single-channel working cannula used in TESSYS limits surgical view and space, which makes dorsal foraminoplasty challenging and may lead to unsatisfactory foraminoplasty. Then, foraminoplasty conducted by sequential trephines and reamers could not be visualized. Blinded foraminoplasty may lead to some unexpected complications like neural injury, massive bone-cutting and massive bleeding<sup>13, 14</sup>. There is some research aiming to overcome these disadvantages. For example, graded duck mouth-like cannula proposed by Li *et al.*<sup>15</sup>, Kiss-Hug maneuver utilized by Gu *et al.*<sup>16</sup> and eccentric technique for foraminoplasty introduced by Ba *et al.*<sup>17</sup> But these techniques all have their own disadvantages, respectively. Besides, endoscopic drills and lasers are applied to realize foraminoplasty<sup>18, 19</sup>. Laser for foraminoplasty is a time consuming procedure and it could not achieve satisfactory enlargement of the foramen sometimes<sup>15, 20</sup>. Percutaneous bichannel endoscopic surgery could expand surgical space and it was first introduced by Kambin in 1987<sup>21</sup>. There are many studies about bichannel surgery. For example, Zhou *et al.* presented a targeted foraminoplasty device named ZESSYS with double-cannulas<sup>2</sup>. Heo *et al.* researched percutaneous unilateral biportal endoscopic technique for lumbar interbody fusion<sup>22</sup>. Wu *et al.* put forward two working cannulas for far-migrated disc herniation<sup>23</sup>. These studies proposed many new strategies, but could not realize full-time and real-time visualized endoscopic foraminoplasty. Also, the dorsal foraminoplasty remains a surgical difficulty.

As far as we know, there is no research about uniportal-bichannel foraminoplasty under monitor in just one incision. In this cohort study, we proposed UBiSES which could realize full-time and real-time visualized endoscopic foraminoplasty and it also provides more extensive surgical view and operative space for surgeons compared with TESSYS. Foraminoplasty assisted by UBiSES is an “outside-in” step by step procedure, which is accordance with surgical thought and surgical operation. UBiSES increases surgical indications of PETD, especially some cases need dorsal foraminoplasty. This study aimed to: (1) introduce our original designed UBiSES for assisting foraminoplasty in PETD; (2) explore UBiSES’s clinical efficiency and safety compared with TESSYS technique; and (3) share some early experience of applying UBiSES for PETD.

## Methods and Materials

### Inclusion and Exclusion Criteria

The research was approved by our local institutional review board (IRB). From March 2019 to November 2019, 36 L5/S1 LDH patients (18 females and 18 males) were enrolled in this research. The inclusive criterions were: (i) 18 years old  $\leq$  age  $\leq$  65 years old; (ii) typical radicular symptoms last more than 3 months; (iii) L5/S1 LDH confirmed by lumbar magnetic resonance imaging (MRI) and computed tomography (CT); (iv) symptoms were irresponsive to conservative treatment at least 3 months. The exclusive criterions were: (i) the patient had accepted L5/S1 surgery before; (ii) multiple-segmental LDH; (iii) LDH combined with lumbar spondylolisthesis; (iv) LDH with severe lumbar central stenosis; (v) the general comorbidities of the patient limited lumbar surgery such as severe cardiopulmonary diseases; and (vi) unwilling to participate in this research. Details of the study have been informed to the patients clearly. All patients had signed the consent forms before PETD and divided into two groups named the UBiSES group who accepted PETD *via* foraminoplasty assisted by UBiSES and the TESSYS group who underwent PETD *via* conventional foraminoplasty. We selected one experienced surgeon who has lumbar surgery experience of more than 4000 cases to perform PETD for all these 36 patients.

### Uniportal-Bichannel Spinal Endoscopic System (UBiSES)

UBiSES consists of spinal endoscopic system that was applied routinely in TESSYS and a bichannel cannula. The general appearance of bichannel cannula is wedge-shaped to facilitate its placement. The bichannel cannula includes main working channel (length: 175mm; outer diameter: 7.5mm; inner diameter: 6.5mm) with the bevel tip and deputy working channel (length: 165mm; outer diameter: 4.2mm; inner diameter: 3.7mm) with the bevel tip. There is accurate scale (range, 6–15cm) of length besides the main working channel (Fig. 1). The extension lines of the deputy working channel and the main working channel are intersected so the surgical instruments could be full-time and real-time visualized to ensure safety. The design of bichannel cannula provides surgeon a more extensive surgical view and operative

space that allows surgeon performs foraminoplasty easier and safer. Also, we can apply two surgical instruments simultaneously to improve surgical efficiency, high-speed drill or tip-flexible electrode bipolar radiofrequency in the endoscopic system placed in the main working channel while forceps in the deputy working channel to realize lumbar foraminoplasty under full-time and real-time visualization (Fig. 2). The spinal endoscopic system applied in the main working channel is the regular endoscope same with TESSYS with an outer diameter of 6.3mm (Joimax GmbH, Germany).


### Surgical Processes

#### UBiSES Group

The patient got a prone position on a radiolucent operating table. Lumbar anteroposterior and lateral fluoroscopy were conducted to confirm the surgical target and draw the surficial projection of bony landmarks like iliac crest, intervertebral space, vertebral pedicle and so on. Then, the surgeon drew the surficial projection of puncture trajectory relying on fluoroscopy and preoperative lumbar MRI. Next, local anesthesia was performed. UBiSES just required the needle tip reached the anterolateral area of S1’s SAP in Kambin’s triangle under fluoroscopy, rather than an accurate target point required in TESSYS (Fig. 3A,B). Sequential dilators were then used to expand the soft tissue carefully. The bichannel cannula was introduced, following the tapered obturator engaged into the satisfactory area, which means the tip of bichannel cannula reached the anterolateral area of S1’s SAP in Kambin’s triangle under fluoroscopy (Fig. 3C,D). The deputy working channel should keep dorsal side in the whole procedure of bichannel cannula placement to avoid neural injury (Fig. 3E,F). Next, a 6.3mm regular spinal endoscopic system was placed into the main working channel. Tip-flexible electrode bipolar radiofrequency system (Elliquence LLC, Baldwin, NY, USA) was applied into the deputy working channel to remove some soft tissue around the SAP under endoscopic monitoring and achieve a clear appearance of SAP to determine the position of foraminoplasty (Fig. 4A,B). Then, the high-speed drill was placed into the deputy working channel to conduct foraminoplasty under full-time and real-time endoscopic monitoring (Fig. 4C,D). The position and quantity of bone resected depended on the surgeon’s judgment and the criterion was to get a satisfactory working cannula placement. After a satisfactory foraminoplasty, the bichannel cannula was drawn out after the tapered obturator was introduced. Then, the conventional working cannula was placed along the tapered obturator to conduct decompression and the following processes were the same as the conventional PELD. The removed herniated disc tissue was shown in Fig. 4E.

#### TESSYS Group

The patient got a prone position on a radiolucent operating table. Lumbar fluoroscopy was conducted to confirm the surgical target and draw the surficial projection of bony



**Fig. 1** Bichannel cannula of Uniportal-bichannel Spinal Endoscopic System (UBiSES). (A, B) The schematic diagram of the original designed bichannel cannula. The wedge-shaped bichannel cannula consists of main working channel and deputy working channel. (C, D) The general view of the bichannel cannula.

landmarks. Then, the surgeon drew the surficial projection of puncture trajectory relying on fluoroscopy and preoperative lumbar MRI. Then, local anesthesia was performed. Accurate puncture was crucial in TESSYS, required the tip of needle reached the middle line on the anteroposterior fluoroscopy and the vertebral posterior superior margin on the lateral fluoroscopy. After soft tissue expansion, graded reamers and trephines were applied to perform blind foraminoplasty very carefully rely on fluoroscopy due to limit view and space. When the working cannula was placed, the following decompression was identical to that in the routine PELD procedure<sup>24</sup>.

#### Outcome Measures

The demographic data included age and sex, the duration of working cannula placement (minutes), decompression time (minutes), radiation exposure time (seconds) and complications were recorded and analyzed. All patients accepted MRI and CT at 3 days after the surgery. All patients were followed up for at least 12 months. 10 points visual analogue scale (VAS) was used to assess low back pain (VAS-low back) and leg pain (VAS-leg). VAS-low back and VAS-leg were recorded on the day before surgery, 1 day, 3 months, 6 months and 12 months after the surgery. Oswestry disability index (ODI) scores and modified MacNab criteria were adopted as functional evaluation methods. ODI scores

were recorded on the day before surgery, 3 months, 6 months and 12 months after the surgery. Modified MacNab criteria was recorded at the last follow-up.

#### Demographic Data

The demographic data including age and sex of 36 patients were recorded.

#### The Duration of Working Cannula Placement

The duration of working cannula placement began with the first fluoroscopy until there was satisfactory placement of the working cannula.

#### Decompression Time

Decompression time was calculated from the working cannula placement to skin closure.

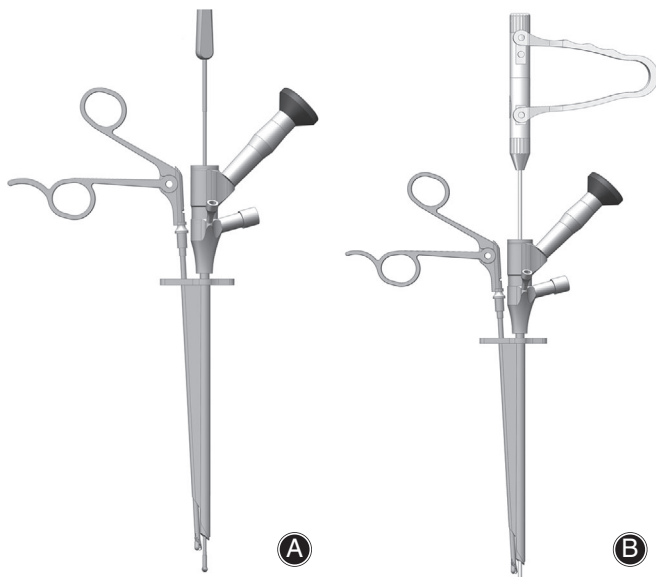
#### Radiation Exposure Time

Radiation exposure time was recorded by the C-arm fluoroscopy machine.

#### Complications

Complications like postoperative bleeding, neural injury, dysesthesia, dural laceration, scar tissue formation etc. were recorded after the surgery.





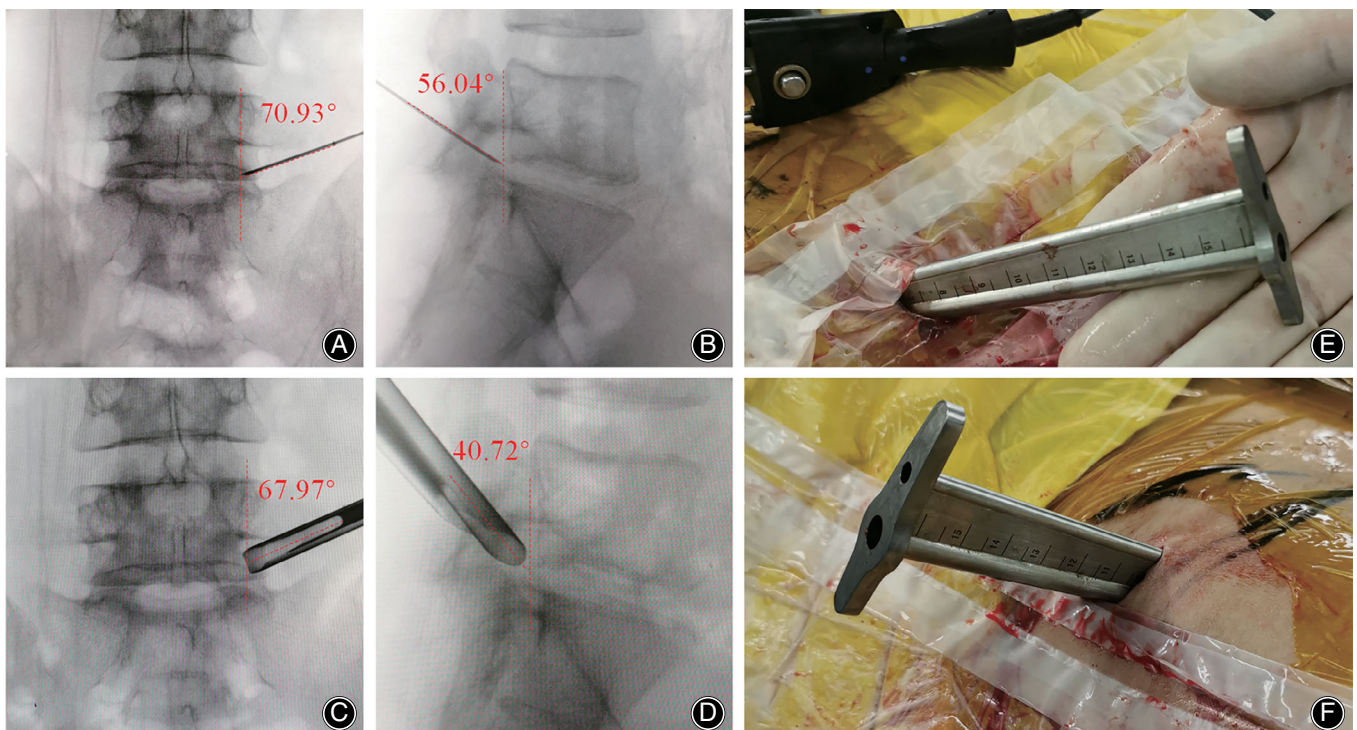
**Fig. 2** The schematic diagram: Bichannel cannula could accommodate surgical instruments and spinal endoscopic system simultaneously to realize full-time and real-time visualized operation. (A) The high-speed drill is applied in the regular spinal endoscopic system placed in the main working channel while forceps is applied in the deputy working channel. (B) The tip-flexible electrode bipolar radiofrequency system is applied in the regular spinal endoscopic system placed in the main working channel while forceps is placed in the deputy working channel.

### Visual Analogue Scale (VAS)

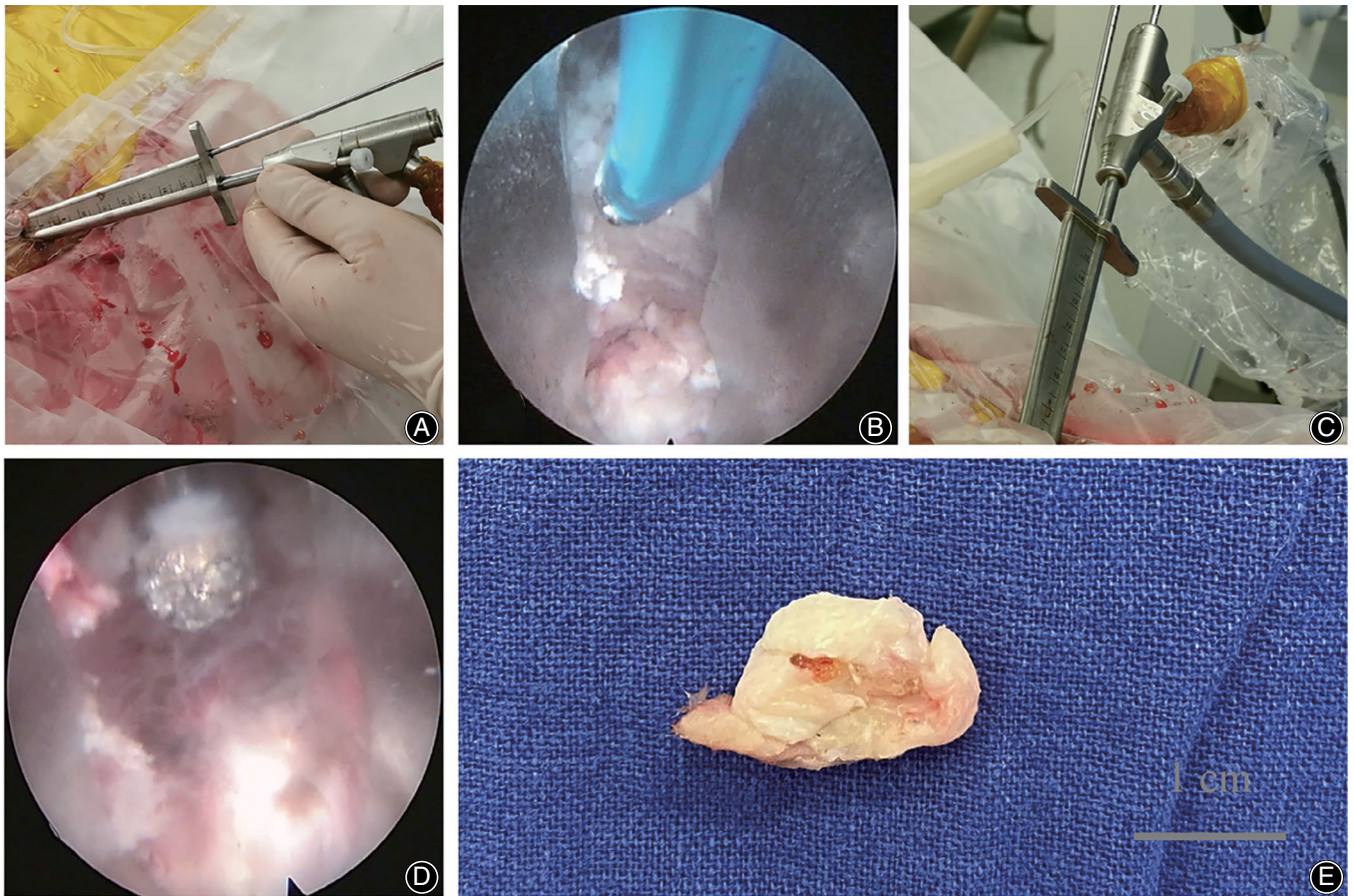
The VAS is the most commonly used questionnaire for quantification of pain. It is a continuous scale comprised of a horizontal or vertical line, usually 10 cm in length. For pain intensity, the scale is most commonly anchored by “no pain” (score of 0) and “pain as bad as it could be” (score of 10). A score of 0 is considered no pain, 1–3 mild pain, 4–6 moderate pain, and 7–10 severe pain.

### Oswestry Disability Index (ODI)

The Oswestry disability index (ODI) is a principal condition-specific outcome measures used in the management of spinal disorders, and to assess patient progress in routine clinical practice. The ODI score system includes 10 sections: pain intensity, personal care, lifting, walking, sitting, standing, sleeping, sex life, social life and traveling. For each section of six statements the total score is 5. Intervening statements are scored according to rank. If more than one box is marked in each section, take the highest score. If all 10 sections are completed the score is calculated as follows: total scored out of total possible score  $\times 100$ . If one section is missed (or not applicable) the score is calculated:  $(\text{total score} / (5 \times \text{number of questions answered})) \times 100\%$ . 0%–20% is considered mild dysfunction, 21%–40% is moderate dysfunction, 41%–60% is severe dysfunction, and 61%–80% is considered as disability. For cases with score of 81%–100%, either long-term bedridden, or exaggerating the impact of pain on their life.



**Fig. 3** The placement of the bichannel cannula. (A, B) Lumbar anteroposterior and lateral fluoroscopy revealed that the needle tip reached the anterolateral area of S1's superior articular process (SAP) in Kambin's triangle. (C, D) Lumbar anteroposterior and lateral fluoroscopy confirmed that the bichannel cannula tip reached the anterolateral area of S1's superior articular process (SAP) in Kambin's triangle. (E-F) The general view of the placed bichannel cannula.



**Fig. 4** Surgical instruments were applied in Uniportal-bichannel Spinal Endoscopic System (UBiSES) under visualization and the removed disc tissue. (A, B) Tip-flexible electrode bipolar radiofrequency system was applied into the deputy working channel to remove some soft tissue around the SAP under endoscopic monitoring and achieve a clear appearance of SAP to determine the position of foraminoplasty. (C, D) The high-speed drill was placed into the deputy working channel to conduct foraminoplasty under full-time and real-time endoscopic monitoring. (E) It showed the removed herniated disc tissue in the UBiSES group.

**TABLE 1** Demographic data of the UBiSES group and the TESSYS group (Mean  $\pm$  SD)

Parameters	UBiSES	TESSYS	P value
Age (years old)	40.94 $\pm$ 12.39	39.78 $\pm$ 13.02	0.81
Sex (male: female)	8:10	10:8	0.51
Follow-up time (months)	15.22 $\pm$ 2.07	16.33 $\pm$ 2.47	0.14

**TABLE 2** Comparisons of surgical outcomes between the UBiSES group and the TESSYS group (Mean  $\pm$  SD)

Parameters	UBiSES	TESSYS	P value
The duration of working cannula placement (min)	19.08 $\pm$ 2.30	24.90 $\pm$ 4.71	<0.05*
Decompression time (min)	44.18 $\pm$ 5.70	47.46 $\pm$ 5.96	0.17
Radiation exposure time (s)	28.00 $\pm$ 4.70	40.50 $\pm$ 5.73	<0.05*

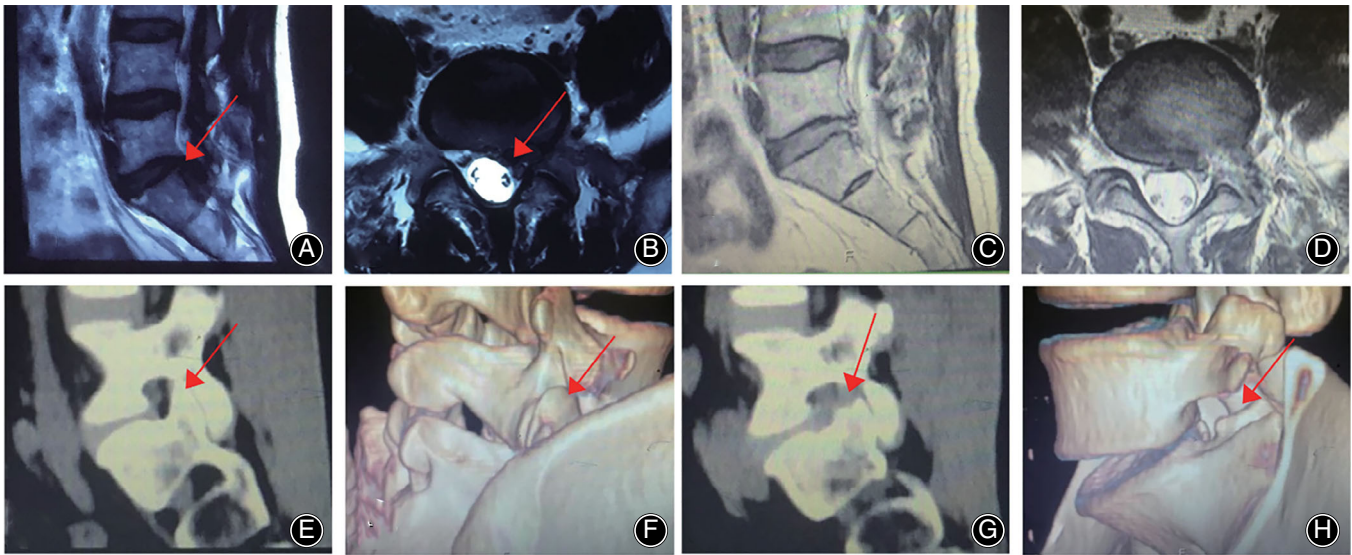
\*Stands for statistical significance.

#### Modified MacNab Criteria

The modified MacNab criteria were used to evaluate the efficacy of surgery. The modified MacNab criteria include four grades: excellent, good, fair, and poor. Excellent: symptoms disappear completely, return to the original work and life; good: mild symptoms, activity is slightly limited, no impact on work and life; fair: symptoms are

relieved, activities are limited, affecting normal work and life; poor: there is no difference before and after treatment, even aggravated.





**Fig. 5** Radiologic performances in the UBiSES group. (A, B) Preoperative lumbar MRI revealed L5/S1 LDH and the nerve was compressed severely. The arrow indicated the herniated L5/S1 disc (Left). (C, D) Postoperative lumbar MRI showed a sufficient decompression. There was enough space around the nerve and the herniated disc tissue was removed clearly. (E, F) The postoperative lumbar CT showed the S1's right SAP was intact (arrow). (G, H) The postoperative lumbar CT showed the S1's left SAP was tiny removed to achieve foraminoplasty (arrow). It was clearly observed that the right L5/S1 intervertebral foramen has been enlarged effectively.

### Statistical Analysis

All the data were analyzed by the software package SPSS 21.0 (IBM Corp., Chicago, IL, USA). The statistics were presented as Mean  $\pm$  SD. Student *t* test was used to compare the continuous variables. Categorical parameters were analyzed by Chi-square test.  $P < 0.05$  was regarded as statistical significance.

### Results

#### Follow-up

All 36 patients accepted PETD *via* lumbar foraminoplasty successfully. Patients were followed up in our out-patient department for at least 12 months (time points: 3 months, 6 months, 12 months). The average follow-up period of the UBiSES group was  $15.22 \pm 2.07$  months, which was  $16.33 \pm 2.47$  months for the TESSYS group ( $P = 0.14$ ) (Table 1). Furthermore, follow-up period shows no difference in male patients ( $P = 0.52$ ) or female patients ( $P = 0.16$ ) between the UBiSES group and the TESSYS group.

#### General Results

the UBiSES group contains eight males and 10 females while the TESSYS group contains 10 males and eight females and there was no difference in sex between two groups ( $P = 0.51$ ) (Table 1). There was no difference in average age between the UBiSES group,  $40.94 \pm 12.39$  years old (range, 24–63 years old) and the TESSYS group,  $39.78 \pm 13.02$  years old (range, 19–65 years old) ( $P = 0.81$ ) (Table 1). The duration of working cannula placement was  $19.08 \pm 2.30$  and  $24.90 \pm 4.71$  in UBiSES and TESSYS respectively and has significant difference

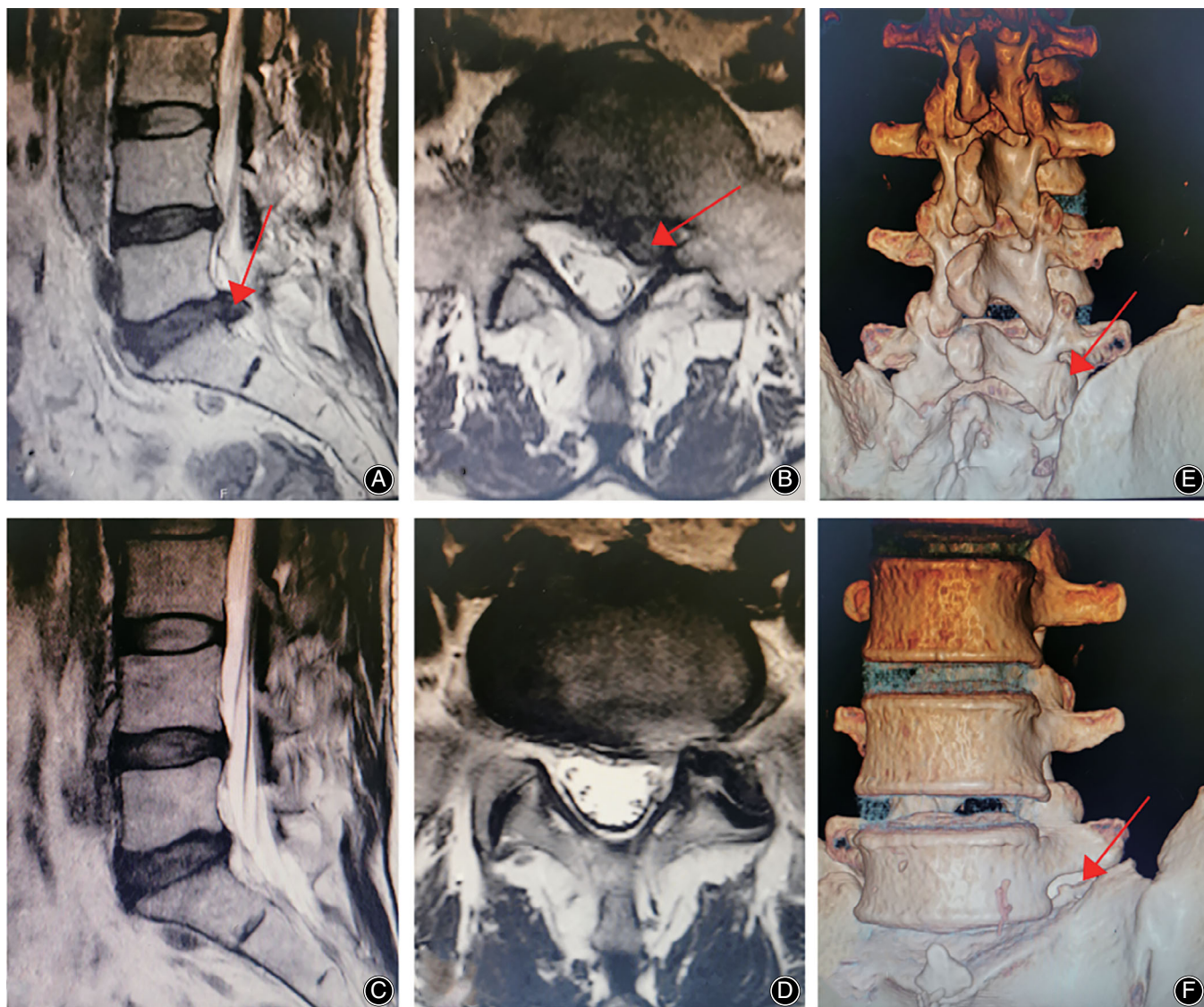
( $P < 0.05$ ) (Table 2). And for male ( $P < 0.05$ ) or female ( $P < 0.05$ ) patients, there was also statistic difference in the duration of working cannula placement between two groups. There was no statistic difference in decompression time between UBiSES ( $44.18 \pm 5.70$ ) and TESSYS ( $47.46 \pm 5.96$ ) ( $P = 0.17$ ) (Table 2). Analyzing sex, there was also no difference in decompression time in male ( $P = 0.12$ ) or female ( $P = 0.54$ ) between two groups. The radiation exposure time of the UBiSES group ( $28.00 \pm 4.70$ ) was decreased significantly compared with that of the TESSYS group ( $40.50 \pm 5.73$ ) ( $P < 0.05$ ) (Table 2). Furthermore, the radiation exposure time in male patients ( $P < 0.05$ ) or female patients ( $P < 0.05$ ) in UBiSES decreased significantly compared with that in the TESSYS group.

#### Radiographic Improvement

The postoperative MRI in the UBiSES group showed there was sufficient space surrounding the nerve and the herniated disc tissue was removed that means a satisfactory decompression compared with preoperative images. The postoperative CT in the UBiSES group revealed that the SAP of S1 was tiny resected for enlarging the foramen (Fig. 5). The postoperative MRI and CT in the TESSYS group revealed sufficient decompression compared with preoperative image (Fig. 6). Another two cases' radiographic performance in the UBiSES group were shown in Figs 7 and 8.

#### Visual Analogue Scale (VAS)

All patients in both groups received a significant pain relief at every follow-up point compared with preoperative



**Fig. 6** Radiologic performances in the TESSYS group. (A, B) Preoperative lumbar MRI revealed L5/S1 LDH. The arrow indicated the herniated L5/S1 disc (Left). (C, D) Postoperative lumbar MRI showed a sufficient decompression for nerve and the cerebrospinal fluid was filling around the nerve. (E) The postoperative lumbar CT showed the S1's right SAP was intact (arrow). (F) The postoperative lumbar CT showed the S1's left SAP was partial removed to enlarge the intervertebral foramen for facilitating the placement of cannula (arrow).

situation ( $P < 0.05$ ). The VAS-low back of the UBiSES group decreased from preoperative  $6.22 \pm 0.73$  to  $3.39 \pm 0.61$  (1 day),  $2.50 \pm 0.71$  (3 months),  $2.11 \pm 0.58$  (6 months),  $1.28 \pm 0.46$  (12 months). And the VAS-leg of the UBiSES group decreased from preoperative  $6.94 \pm 1.11$  to  $3.94 \pm 0.80$  (1 day),  $2.83 \pm 0.79$  (3 months),  $2.06 \pm 0.54$  (6 months),  $1.17 \pm 0.38$  (12 months). In the TESSYS group, VAS-low back changed from  $6.28 \pm 1.18$  to  $3.83 \pm 0.71$  (1 day),  $2.72 \pm 0.75$  (3 months),  $2.06 \pm 0.80$  (6 months),  $1.33 \pm 0.49$  (12 months) while VAS-leg improved from  $6.78 \pm 1.06$  to  $3.72 \pm 1.23$  (1 day),  $2.78 \pm 0.65$  (3 months),  $2.11 \pm 0.58$  (6 months),  $1.22 \pm 0.43$  (12 months). (Table 3).

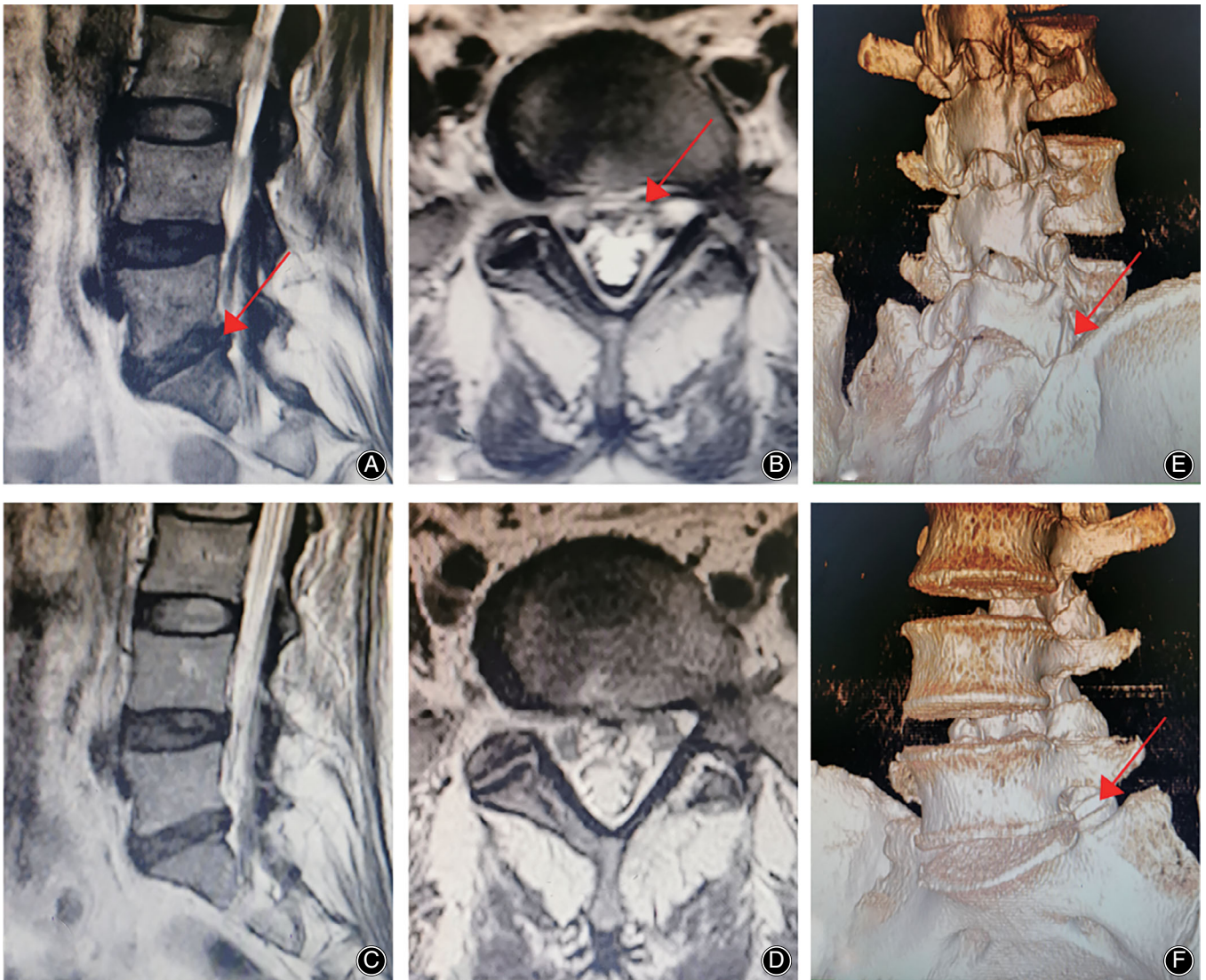
#### Oswestry Disability Index (ODI)

The ODI of the UBiSES group significantly improved from preoperative  $55.06 \pm 5.67$  to  $17.94 \pm 3.56$  (3 months,  $P < 0.05$ ),  $14.50 \pm 3.17$  (6 months,  $P < 0.05$ ),  $12.28 \pm 3.27$  (12 months,  $P < 0.05$ ). And the ODI of the TESSYS group significantly decreased from preoperative  $56.67 \pm 5.59$  to  $19.22 \pm 3.14$  (3 months,  $P < 0.05$ ),  $15.67 \pm 2.89$  (6 months,  $P < 0.05$ ),  $12.44 \pm 1.98$  (12 months,  $P < 0.05$ ). The result of ODI showed a significant functional improvement in both groups. (Table 3).

#### Modified MacNab Criteria

Modified MacNab criteria was recorded at the last follow-up. 94.44% patients in the UBiSES group received





**Fig. 7** A 53 years old female patient in the UBiSES group. (A, B) Preoperative lumbar MRI revealed L5/S1 LDH. The arrow indicated the herniated L5/S1 disc (Left). The herniated disc tissue compressed the nerve and the nerve could not show clearly. (C, D) Postoperative lumbar MRI showed a sufficient decompression and the nerve was surrounded by cerebrospinal fluid. (E) The postoperative lumbar CT showed the S1's right SAP was intact (arrow). (F) The postoperative lumbar CT revealed the S1's left SAP was tiny removed to achieve foraminaloplasty (arrow).

an excellent or good recovery while 88.89% in the TESSYS group and showed no statistic difference ( $P = 0.82$ ). There was no poor result reported in both groups. (Table 4).

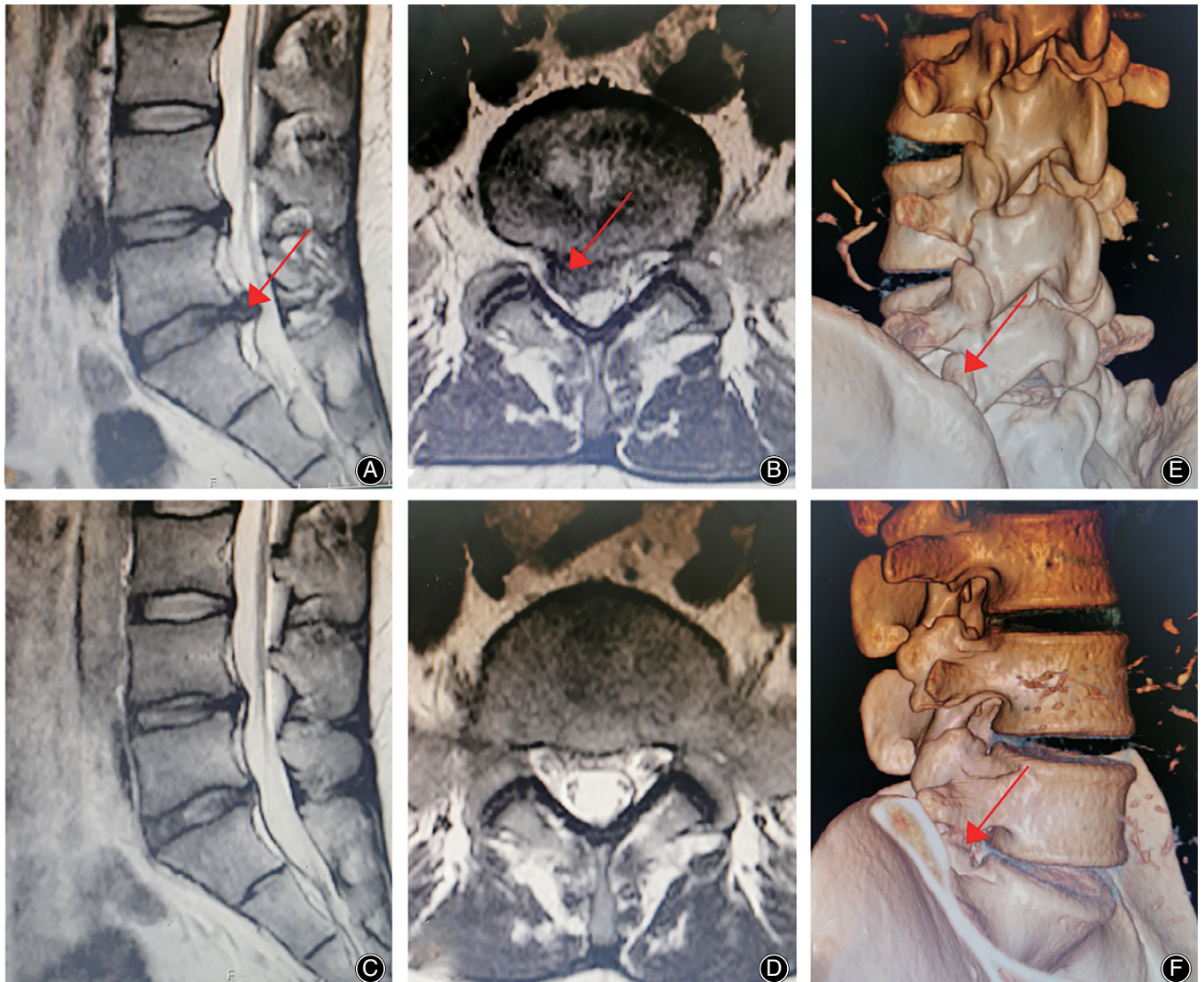
#### Complications

There was no complication observed in the UBiSES group. 2 cases in the TESSYS group underwent postoperative dysesthesia and the symptom disappeared in 5 days and 7 days respectively with application of dexamethasone and neurotrophic drugs.

#### Discussion

##### *The UBiSES group was More Efficient and Safer Compared with the TESSYS Group*

In this cohort study, we designed two groups, PETD assisted by UBiSES and PETD supported by conventional TESSYS. The results suggested that UBiSES could improve the surgical efficiency such as decrease the duration of working cannula placement and improve surgical security such as decrease the radiation exposure time significantly compared with conventional TESSYS. Equivalent pain relief and functional improvement were observed in the UBiSES group compared



**Fig. 8** A 36 years old male patient in the UBises group. (A, B) Preoperative lumbar MRI demonstrated severe L5/S1 LDH. The arrow indicated the herniated L5/S1 disc (Right). (C, D) Postoperative lumbar MRI showed a sufficient decompression and the herniated tissue was removed well. (E) The postoperative lumbar CT showed the S1's left SAP was intact (arrow). (F) The postoperative lumbar CT showed the S1's right SAP was tiny removed to achieve foraminaloplasty (arrow).

**TABLE 3** Pain relief and functional improvement in two groups (mean  $\pm$  SD)

Groups	Variables	Preoperative	1 day	3 months	6 months	12 months
UBiSES	VAS-low back	6.22 $\pm$ 0.73	3.39 $\pm$ 0.61*	2.50 $\pm$ 0.71*	2.11 $\pm$ 0.58*	1.28 $\pm$ 0.46*
	VAS-leg	6.94 $\pm$ 1.11	3.94 $\pm$ 0.80*	2.83 $\pm$ 0.79*	2.06 $\pm$ 0.54*	1.17 $\pm$ 0.38*
	ODI (%)	55.06 $\pm$ 5.67	—	17.94 $\pm$ 3.56*	14.50 $\pm$ 3.17*	12.28 $\pm$ 3.27*
TESSYS	VAS-low back	6.28 $\pm$ 1.18	3.83 $\pm$ 0.71*	2.72 $\pm$ 0.75*	2.06 $\pm$ 0.80*	1.33 $\pm$ 0.49*
	VAS-leg	6.78 $\pm$ 1.06	3.72 $\pm$ 1.23*	2.78 $\pm$ 0.65*	2.11 $\pm$ 0.58*	1.22 $\pm$ 0.43*
	ODI (%)	56.67 $\pm$ 5.59	—	19.22 $\pm$ 3.14*	15.67 $\pm$ 2.89*	12.44 $\pm$ 1.98*

\* Stands for statistical significance compared with preoperative data ( $P < 0.05$ ).



**TABLE 4** The results of modified MacNab criteria at the last follow-up of the UBiSES group and the TESSYS group

Variables	UBiSES	TESSYS	P value
Excellent: Good: Fair: Poor	9: 8: 1: 0	8: 8: 2: 0	0.82
Percentage (Excellent + Good)	94.44%	88.89%	—

with the TESSYS group. The VAS-low back, VAS-leg and ODI improved significantly in both the UBiSES group and the TESSYS group after PETD ( $P < 0.05$ ). At the last follow-up, 94.44% patients received an excellent or good recovery in the UBiSES group while 88.89% in the TESSYS group, and no poor result was reported in both groups. The UBiSES group patients' postoperative lumbar MRI and CT showed a sufficient decompression of the nerve compared with preoperative image. There was no complication observed during 12 months' follow-up in the UBiSES group. Two cases underwent postoperative dysesthesia and the symptom disappeared rapidly with application of dexamethasone and neurotrophic drugs in the TESSYS group. The study confirmed that UBiSES was feasible to assist PETD and realized more efficient and safer consequences compared with conventional TESSYS.

#### **Lumbar Foraminoplasty was a Crucial but Challenged Step in PETD**

As a typical MISS, PELD has got more and more attention by spine surgeon these years because of obvious advantages such as less damage, rapid recovery and so on<sup>25</sup>. PELD mainly refers to PETD and PEID, transforaminal approach for PETD and interlaminar approach for PEID. The learning curve of PELD is very steep due to the challenging placement of working cannula and unskilled endoscopic decompression, especially PETD<sup>2, 26</sup>. A 12-years single center research of 10,228 cases indicated that nonideal working cannula placement was a main reason for unsuccessful PETD<sup>27</sup>. For some L5/S1 LDH patients with hypertrophic facet joint or high iliac crest, it is a huge challenge to placement the working cannula at an appropriate location because of the anatomic barriers and narrow foramen. The SAP is the main anatomic barrier of placing the working cannula in PETD<sup>7, 8</sup>. In such cases, some studies proposed percutaneous endoscopic interlaminar discectomy (PEID). However, PEID requires general anesthesia and may cause dural tearing and traction to nerve<sup>3, 28</sup>. Percutaneous endoscopic ventral facetectomy (PEVF) was developing recently. As the SAP should be completely removed, PEVF may cause iatrogenic spinal instability<sup>7</sup>. Lumbar foraminoplasty, enlargement of the foramen, was proposed to help surgeons access the epidural space to achieve a clear visualization of the anatomy and target disc fragments<sup>8</sup>. In fact, foraminoplasty has become a routine step in TESSYS proposed by Hoogland<sup>29</sup>. Unsatisfactory foraminoplasty may lead to more fluoroscopy, which means more radiation exposure<sup>26</sup>. Blinded

foraminoplasty was a challenged procedure for many surgeons, especially young surgeons.

#### **UBiSES Could Realize Full-Time and Real-Time Visualized Endoscopic Foraminoplasty with Wider Surgical View and More Extensive Operative Space**

In most situations, foraminoplasty is a very important surgical step in PETD. Traditionally, surgeons use bone reamers or graded trephines to achieve foraminoplasty gradually<sup>24, 30</sup>. Surgeons could not get a direct view of the anatomic structure around the foramen during foraminoplasty with bone reamers or trephines, which is difficult to control the direction and may cause some unexpected complications including neural injury and bleeding. Also, the articular surface of facet joints is not in a sagittal plane or coronal plane, and the oblique articular surface makes reamers and trephines easily deflected to the ventral direction, which leads to unsatisfactory foraminoplasty<sup>13, 14, 29</sup>. Li *et al.* designed a graded duck mouth-like cannula to avoid damages to the nerve and articular surface of SAP<sup>15</sup>. Gu *et al.* presented another technique for foraminoplasty named Kiss-Hug. In the Kiss-Hug technique, the bevel tip of the working cannula used commonly in TESSYS was applied as a bone reamer to undercut the SAP. The study indicated that the best use of the Kiss-Hug maneuver was at the beginning stage of foraminoplasty, which means the application of the Kiss-Hug technique was limited. It should be noticed that the bevel tip of the working cannula could break when it was used as a bone reamer<sup>16</sup>. Ba *et al.* proposed an eccentric technique that used the largest diameter trepan under protection of cannulated dilator after dilation to decrease surgical time and radiation exposure rather than apply trepan sequentially. The eccentric technique requires foraminoplasty blindly and it is not that safe<sup>17</sup>. Bone reamers and trephines could enlarge the foramen rapidly, but they require plentiful fluoroscopy that increases radiation exposure to surgeons and patients<sup>26</sup>. With the development of endoscopic techniques and microsurgical instruments, endoscopic high-speed drill, endoscopic reamer and laser were used for foraminoplasty<sup>18, 19, 31</sup>. These devices could accomplish foraminoplasty safer with low risk of neural injury and bleeding, but they were time consuming and a little bit expensive<sup>8, 16</sup>. There was research about laser for foraminoplasty that showed that low efficiency for enlargement of the foramen and it could not get a satisfactory foraminoplasty sometimes<sup>20</sup>. Conventional TESSYS applied a single-channel cannula to accommodate the endoscopic system and surgical instruments to conduct foraminoplasty, which causes a limited surgical view and narrowed operative space. In some cases, dorsal foraminoplasty is necessary but difficult to realize in conventional TESSYS. To address this, percutaneous bichannel endoscopic surgery was first introduced by Kambin in 1987<sup>21</sup>. Zhou *et al.* proposed a novel targeted foraminoplasty device named ZESSYS. In ZESSYS, the previous operations were the same as TESSYS until the puncture and dilation was accomplished. Then, the double-cannula device with appropriate size was placed with the

thinner cannula along the rod/K wire until the larger cannula docked on the SAP. Since the thinner cannula and inside rod located between the SAP and exiting nerve root, nerve injury could be avoided during foraminoplasty. ZESSYS also did not require a precise puncture as TESSYS, but it did not realize endoscopic foraminoplasty<sup>2</sup>. Heo *et al.* researched percutaneous unilateral biportal endoscopic technique for lumbar interbody fusion. But there were two skin incisions made for endoscopic portal and instrumental portal respectively<sup>22</sup>. Wu *et al.* put forward two working cannulas for percutaneous endoscopic lumbar discectomy. Two working cannulas required two skin incisions and was beneficial for far-migrated disc herniation not foraminoplasty<sup>23</sup>. As an original technique, UBiSES designed a practical bichannel cannula. UBiSES did not require a very accurate puncture as TESSYS that needs the tip of needle to reach the middle line on the anteroposterior fluoroscopy and the vertebral posterior superior margin on the lateral fluoroscopy, which means less fluoroscopy and less radiation exposure to surgeons and patients. UBiSES allows operation with two surgical instruments simultaneously under full-time and real-time visualization in just one incision, which could be less invasive and more efficient. Uniportal-bichannel foraminoplasty assisted by UBiSES could control the direction easier and get a satisfactory bone resect at the dorsal side of foramen with extensive view and space. Clinical application showed that with rotation of the uniportal-bichannel cannula, UBiSES could realize foraminoplasty in a range of 0–270°.

### Limitations

There were some limitations should be clarified in this cohort study. First, there were just 36 patients and a single

experienced surgeon enrolled in the study. However, since the purpose of this study was to demonstrate the application of uniportal-bichannel foraminoplasty for PETD, further study should be conducted to include more patients and surgeons, especially young surgeons. As the study only compared UBiSES with TESSYS, more current techniques should be enrolled in further study to explore the clinical valuable of UBiSES. Next, longer follow-up data should be recorded and analyzed to research the efficacy and security of UBiSES.

### Conclusions

UBiSES allows operation with two surgical instruments simultaneously under full-time and real-time visualization in just one incision. The design of uniportal-bichannel cannula provides a more extensive surgical view and operative space for surgeons. UBiSES assisted foraminoplasty could efficiently enlarge the foramen and decrease the radiation exposure and it was a promising technique in PETD. Further study should be conducted to explore the clinical value of UBiSES.

### Acknowledgments

The author thanks to all the people who have contributed to the study. We specially thank Dragon Crown Medical Company for helping in designing and producing UBiSES. Shi-sheng He, Hai-jian Ni and Zhi Zhou have made contributions to the conception and design of the study. Zhi Zhou drafted the article and Chuan-feng Wang subsequently revised it critically. Shuo Hu, Xin Chen, Fei Liu and Zhi Zhou were involved in the acquisition of data. Yun-shan Fan, Chao-bo Feng, Yan-jie Zhu and Gang Li were involved in analysis and interpretation of data. All authors read and approved the final manuscript.

### References

- Deyo RA, Loeser JD, Bigos SJ. Herniated lumbar intervertebral disk. *Ann Intern Med*, 1990, 112: 598–603.
- Ao S, Wu J, Zheng W, Zhou Y. A novel targeted foraminoplasty device improves the efficacy and safety of foraminoplasty in percutaneous endoscopic lumbar discectomy: preliminary clinical application of 70 cases. *World Neurosurg*, 2018, 115: e263–e271.
- Ruetten S, Komp M, Godolias G. A new full-endoscopic technique for the interlaminar operation of lumbar disc herniations using 6-mm endoscopes: prospective 2-year results of 331 patients. *Minim Invasive Neurosurg*, 2006, 49: 80–87.
- Yeung AT, Tsou PM. Posterolateral endoscopic excision for lumbar disc herniation: surgical technique, outcome, and complications in 307 consecutive cases. *Spine*, 2002, 27: 722–731.
- Hoogland T, Schubert M, Miklitz B, Ramirez A. Transforaminal posterolateral endoscopic discectomy with or without the combination of a low-dose chymopapain: a prospective randomized study in 280 consecutive cases. *Spine*, 2006, 31: E890–E897.
- Xin G, Shi-Sheng H, Hai-Long Z. Morphometric analysis of the YESS and TESSYS techniques of percutaneous transforaminal endoscopic lumbar discectomy. *Clin Anat*, 2013, 26: 728–734.
- Sairyo K, Chikawa T, Nagamachi A. State-of-the-art transforaminal percutaneous endoscopic lumbar surgery under local anesthesia: discectomy, foraminoplasty, and ventral facetectomy. *J Orthop Sci*, 2018, 23: 229–236.
- Choi KC, Shim HK, Park CJ, Lee DC, Park CK. Usefulness of percutaneous endoscopic lumbar foraminoplasty for lumbar disc herniation. *World Neurosurg*, 2017, 106: 484–492.
- Tsou PM, Yeung AT. Transforaminal endoscopic decompression for radiculopathy secondary to intracanal noncontained lumbar disc herniations: outcome and technique. *Spine J*, 2002, 2: 41–48.
- Ruetten S, Komp M, Godolias G. An extreme lateral access for the surgery of lumbar disc herniations inside the spinal canal using the full-endoscopic uniportal transforaminal approach-technique and prospective results of 463 patients. *Spine*, 2005, 30: 2570–2578.
- Pan Z, Ha Y, Yi S, Cao K. Efficacy of transforaminal endoscopic spine system (TESSYS) technique in treating lumbar disc herniation. *Med Sci Monit*, 2016, 22: 530–539.
- Wang H, Huang B, Li C, *et al.* Learning curve for percutaneous endoscopic lumbar discectomy depending on the surgeon's training level of minimally invasive spine surgery. *Clin Neurol Neurosurg*, 2013, 115: 1987–1991.
- Ahn Y, Lee SH, Lee JH, Kim JU, Liu WC. Transforaminal percutaneous endoscopic lumbar discectomy for upper lumbar disc herniation: clinical outcome, prognostic factors, and technical consideration. *Acta Neurochir*, 2009, 151: 199–206.
- Lee HJ, Kim JS, Ryu KS. Transforaminal percutaneous endoscopic lumbar discectomy with percutaneous epidural neuroplasty in lumbar disc herniation: technical note. *World Neurosurg*, 2017, 98: 876 e823–e831.
- Li Z, Hou S, Shang W, Song K, Zhao H. New instrument for percutaneous posterolateral lumbar foraminoplasty: case series of 134 with instrument design, surgical technique and outcomes. *Int J Clin Exp Med*, 2015, 8: 14672–14679.
- Gu S, Hou K, Jian W, Du J, Xiao S, Zhang X. Working cannula-based endoscopic foraminoplasty: a technical note. *Biomed Res Int*, 2018, 2018: 4749560.
- Ba Z, Li Z, Liu Z, Li H, Wu D, Zhu J. Eccentric technique for foraminoplasty in percutaneous endoscopic transforaminal procedure: a technical note. *Int J Surg*, 2017, 46: 110–113.
- Knight MT, Vajda A, Jakab GV, Awan S. Endoscopic laser foraminoplasty on the lumbar spine-early experience. *Minim Invasive Neurosurg*, 1998, 41: 5–9.



- 19.** Ruetten S, Komp M, Merk H, Godolias G. Use of newly developed instruments and endoscopes: full-endoscopic resection of lumbar disc herniations via the interlaminar and lateral transforaminal approach. *J Neurosurg Spine*, 2007, 6: 521–530.
- 20.** Hafez MI, Zhou S, Coombs RR, McCarthy ID. The effect of irrigation on peak temperatures in nerve root, dura, and intervertebral disc during laser-assisted foraminoplasty. *Lasers Surg Med*, 2001, 29: 33–37.
- 21.** Kambin P, Brager MD. Percutaneous posterolateral discectomy. Anatomy and mechanism. *Clin Orthop Relat Res*, 1987, 223:145–154.
- 22.** Heo DH, Son SK, Eum JH, Park CK. Fully endoscopic lumbar interbody fusion using a percutaneous unilateral biportal endoscopic technique: technical note and preliminary clinical results. *Neurosurg Focus*, 2017, 43: E8.
- 23.** Wu X, Fan G, Guan X, et al. Percutaneous endoscopic lumbar discectomy for far-migrated disc herniation through two working channels. *Pain Physician*, 2016, 19: E675–E680.
- 24.** Schubert M, Hoogland T. Endoscopic transforaminal nucleotomy with foraminoplasty for lumbar disk herniation. *Oper Orthop Traumatol*, 2005, 17: 641–661.
- 25.** Wang D, Xie W, Cao W, He S, Fan G, Zhang H. A cost-utility analysis of percutaneous endoscopic lumbar discectomy for L5-S1 lumbar disc herniation: transforaminal versus interlaminar. *Spine*, 2019, 44: 563–570.
- 26.** Ahn Y, Kim CH, Lee JH, Lee SH, Kim JS. Radiation exposure to the surgeon during percutaneous endoscopic lumbar discectomy: a prospective study. *Spine*, 2013, 38: 617–625.
- 27.** Choi KC, Lee JH, Kim JS, et al. Unsuccessful percutaneous endoscopic lumbar discectomy: a single-center experience of 10,228 cases. *Neurosurgery*, 2015, 76: 372–380.
- 28.** Koga S, Sairyo K, Shibuya I, et al. Minimally invasive removal of a recurrent lumbar herniated nucleus pulposus by the small incised microendoscopic discectomy interlaminar approach. *Asian J Endosc Surg*, 2012, 5: 34–37.
- 29.** Hoogland T, van den Brekel-Dijkstra K, Schubert M, Miklitz B. Endoscopic transforaminal discectomy for recurrent lumbar disc herniation: a prospective, cohort evaluation of 262 consecutive cases. *Spine*, 2008, 33: 973–978.
- 30.** Ahn Y, Lee SH, Park WM, Lee HY. Posterolateral percutaneous endoscopic lumbar foraminotomy for L5-S1 foraminal or lateral exit zone stenosis. *J Neurosurg*, 2003, 99: 320–323.
- 31.** Ahn Y. Percutaneous endoscopic decompression for lumbar spinal stenosis. *Expert Rev Med Devices*, 2014, 11: 605–616.