

Received: 2020.11.05

Accepted: 2020.12.27

Available online: 2021.01.09

Published: 2021.02.21

# Orbital Compressed Air and Diesel Explosion Injury Resembling Orbital Cellulitis: An Unusual Case

Authors' Contribution:

Study Design A  
Data Collection B  
Statistical Analysis C  
Data Interpretation D  
Manuscript Preparation E  
Literature Search F  
Funds Collection G

ABCDEF 1 **Yunia Irawati**  
CDEF 2 **Florentina Priscilia**  
CDEF 2 **Hindun Zakiyah**

1 Division of Plastic and Reconstructive Surgery, Department of Ophthalmology, Faculty of Medicine, Universitas Indonesia, Dr. Cipto Mangunkusumo Hospital, Jakarta, Indonesia

2 Research Assistant, Department of Ophthalmology, Dr. Cipto Mangunkusumo Hospital, Jakarta, Indonesia

**Corresponding Author:** Yunia Irawati, e-mail: [yunia\\_irawati@yahoo.com](mailto:yunia_irawati@yahoo.com)

**Conflict of interest:** None declared

**Patient:** Male, 44-year-old  
**Final Diagnosis:** Orbital cellulitis with multiple abscesses and pneumo-orbita of the right eye caused by orbital-compressed air and diesel explosion  
**Symptoms:** Worsening of the right upper eyelid swelling • accompanied by pain • fever • redness  
**Medication:** —  
**Clinical Procedure:** Ophthalmology examination • CT Scan • microorganism culture • laboratory test  
**Specialty:** Ophthalmology

**Objective:** Unusual clinical course


**Background:** In this observational case report, we describe a case of orbital cellulitis caused by blunt trauma from an orbital compressed air and diesel explosion injury.

**Case Report:** A 44-year-old man presented to our emergency department with a marked clinical worsening of right upper eyelid swelling, accompanied by pain, fever, and redness. Four days prior, the patient's right eye was struck by a pressurized diesel engine explosion. He sought treatment at another hospital, where an initial examination was conducted and a small laceration was found and immediately treated with irrigation and medication. The wound became progressively worse, and on examination at our hospital, we diagnosed orbital cellulitis, multiple abscesses, and pneumo-orbital formations. There was no indication of infection from the ears, nose, throat, and oral cavity, which usually causes orbital cellulitis. Drainage, debridement, incision, and necrotomy with orbital decompression (canthotomy and cantholysis procedure) was then performed on the patient.

**Conclusions:** Diesel explosion injury can cause orbital cellulitis which can appear to be a simple case at first but has a poor prognosis. Therefore, evaluating the patient's trauma history, computed tomography scan, and histopathological examination are essential in establishing the diagnosis. As early as possible, a diagnosis should be made to prevent tissue damage due to inflammation. Surgical debridement and the administration of a corticosteroid and antibiotic were key to managing the presented case.

**Keywords:** Compressed Air • Explosions • Orbital Diseases

**Full-text PDF:** <https://www.amjcaserep.com/abstract/index/idArt/929671>




1566



—



2



12



## Background

Orbital cellulitis is defined as a significant tissue infection behind the orbital septum. The most common pathological signs seen in clinical examination are limited ocular motility, proptosis, chemosis, and conjunctival hyperemia. Vision loss and afferent pupillary defects can occur from severe orbital congestion and involvement of the optic nerve. Orbital cellulitis is generally caused by the expansion of sinus disease, penetrating trauma, or adjacent infected structures. Therefore, computed tomography (CT) scans are an important modality to rule out other possible causes, such as sinusitis [1,2].

Orbital cellulitis caused by high-pressure diesel explosion injury is rare, and these cases are sporadically reported in the literature. Also, the initial diagnosis of these cases is often neglected. At first, the clinical appearance of this trauma appears harmless, but then it can progressively worsen, becoming a serious condition that can result in vision loss. Despite the application of adequate irrigation, antibiotic, steroid, and surgical therapies, the prognosis of this type of trauma still varies [2,3].

This study presents a rare case of orbital cellulitis caused by a compressed air and diesel explosion and aims to highlight the importance of initial diagnosis, severity of progression, and variable prognosis, despite prompt management.

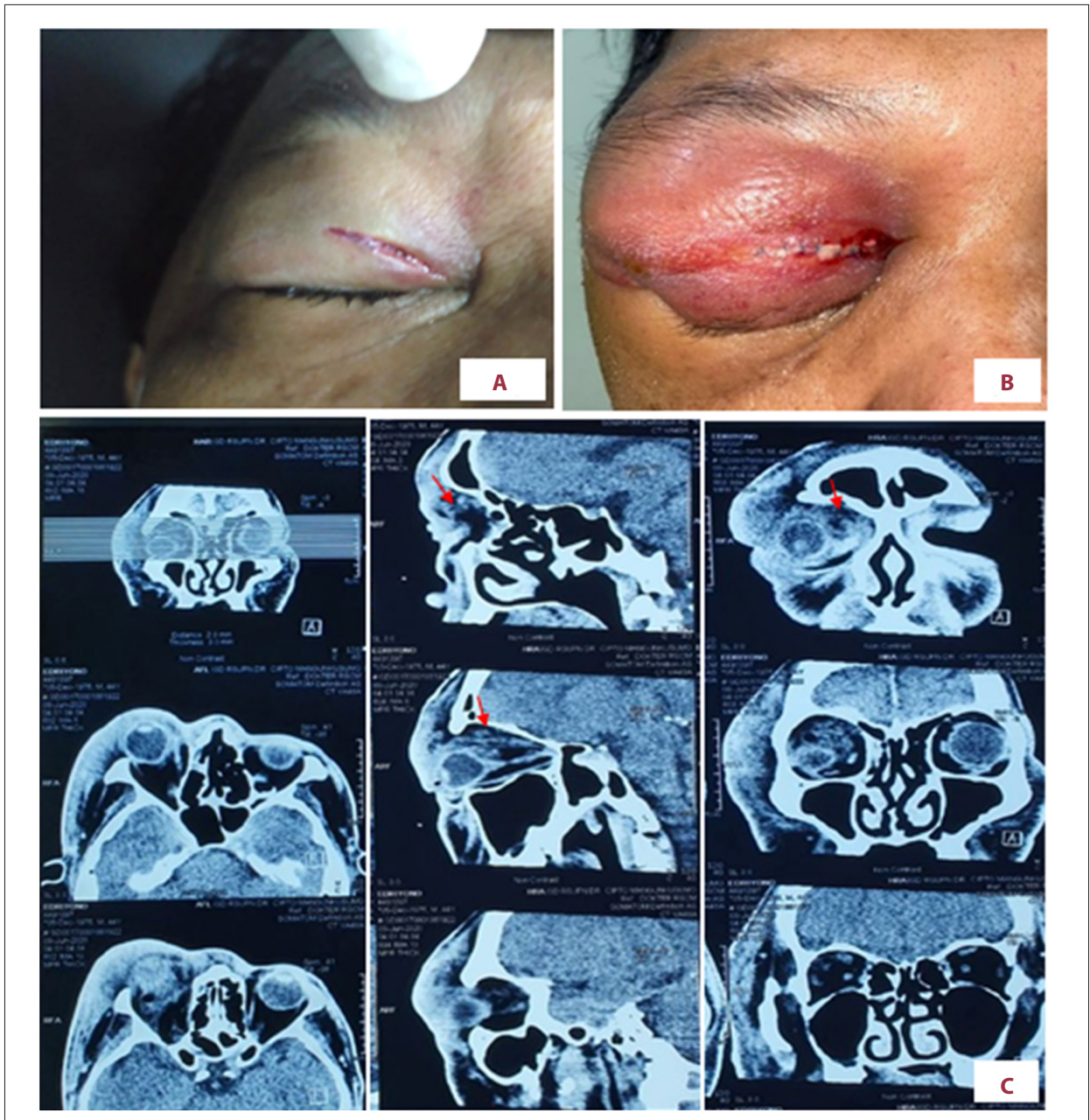
## Case Report

A 44-year-old man came to the emergency department showing a marked clinical worsening of right upper eyelid swelling, which was accompanied by pain, fever, and redness. Four days prior, the patient's right eye was struck by a pressurized diesel engine explosion. Before presenting to our hospital, he was treated at another hospital with saline irrigation, debridement, a simple eyelid laceration wound repair, an antiinflammatory, and an oral and topical antibiotic (Figure 1A). On the ophthalmology examination of the right eye, the patient had visual acuity of 6/12, non-axial proptosis to inferior displacement, and restricted eye movements to all directions. On the superior palpebral muscle, we found dehiscence of the wound, hyperemia, edema, and spasm, and it was warm and firm on palpation. There were multiple Prolene sutures which started 10 mm from the medial canthal, extended 25 mm to the temporal site and 14 mm from the margo, with pus and maceration (Figure 1B). The conjunctiva was chemosis in all quadrants and there was subconjunctival hemorrhage. From a slit lamp and fluorescent examination, no abnormalities in the cornea or other anterior and posterior segments were found. The left eye visual acuity was 6/6 and other segments were within the normal limit.

An orbital CT scan showed inflammatory features involving the soft tissue of the right frontomaxillary region, periorbita, and superomedial intra/extracellular soft-tissue structure of the right ocular bulb, with multiple abscesses and pneumo-orbital formations (Figure 1C). This condition caused proptosis of the right ocular bulb to the inferolateral side. The laboratory test results showed leukocytosis and increased C-reactive protein as markers of inflammation. Results from a microorganism culture of pus from the palpebral wound found gram-positive cocci and no hyphae on the potassium hydroxide examination.

We diagnosed orbital cellulitis with multiple abscesses, pneumo-orbital formations of the right eye, and post-repair of the superior palpebra rupture on the right eye. The patient was hospitalized and treated with normal saline compresses for the right palpebra, ampicillin/sulbactam 1 g IV given 4 times, metronidazole 500 mg IV given 3 times, prednisolone acetate eye drop (ED), levofloxacin ED, artificial tears ED, and chloramphenicol eye ointment. To identify the source of infection, we consulted the departments of internal medicine, dentistry, and ear nose and throat. Nevertheless, there were no abnormalities in the ear, nose, throat, and oral cavity that were thought to be associated with the etiology of this orbital cellulitis.

On the first day of hospitalization, the patient felt an increased pain in his right eye followed by an increased intraocular pressure, to 34 mmHg. Therefore, we gave additional therapy of timol 0.5% ED, mydriatil 1% ED, and natrium diclofenac tablets. Three days later, the intraocular pressure had been successfully lowered to 8 mmHg. There was undulation on the superior palpebra; therefore, we immediately performed an incision, drainage, necrotomy, debridement of the wound and orbital decompression with lateral canthotomy and cantholysis. Samples of necrotic tissue and pus were taken during the procedure for further culture and histological examination. The results revealed *Staphylococcus epidermidis*, which is sensitive to ampicillin/sulbactam. Additionally, the histological samples showed fragments of orbital tissue including globules of adipose tissue, which were infiltrated by blood and a number of largely necrotic polymorphonuclear (PMN) leukocytes, plasma cells, histiocytes, and datia cells with many nuclei, having some clear vacuoles in different sizes and "swiss cheese" appearance in between (Figure 2A, 2B). There was no sign of malignancy. The histological findings concluded that there was acute inflammation and chronic suppurative granulomatous as a result of a foreign body reaction. We continue to manage this patient with coamoxiclav, methylprednisolone, omeprazole, and chloramphenicol eye ointments for 1-month post-operative. The condition had significantly improved at the 4-month follow-up; however, ptosis still existed and the eye movement to superior was limited (Figure 2C, 2D).

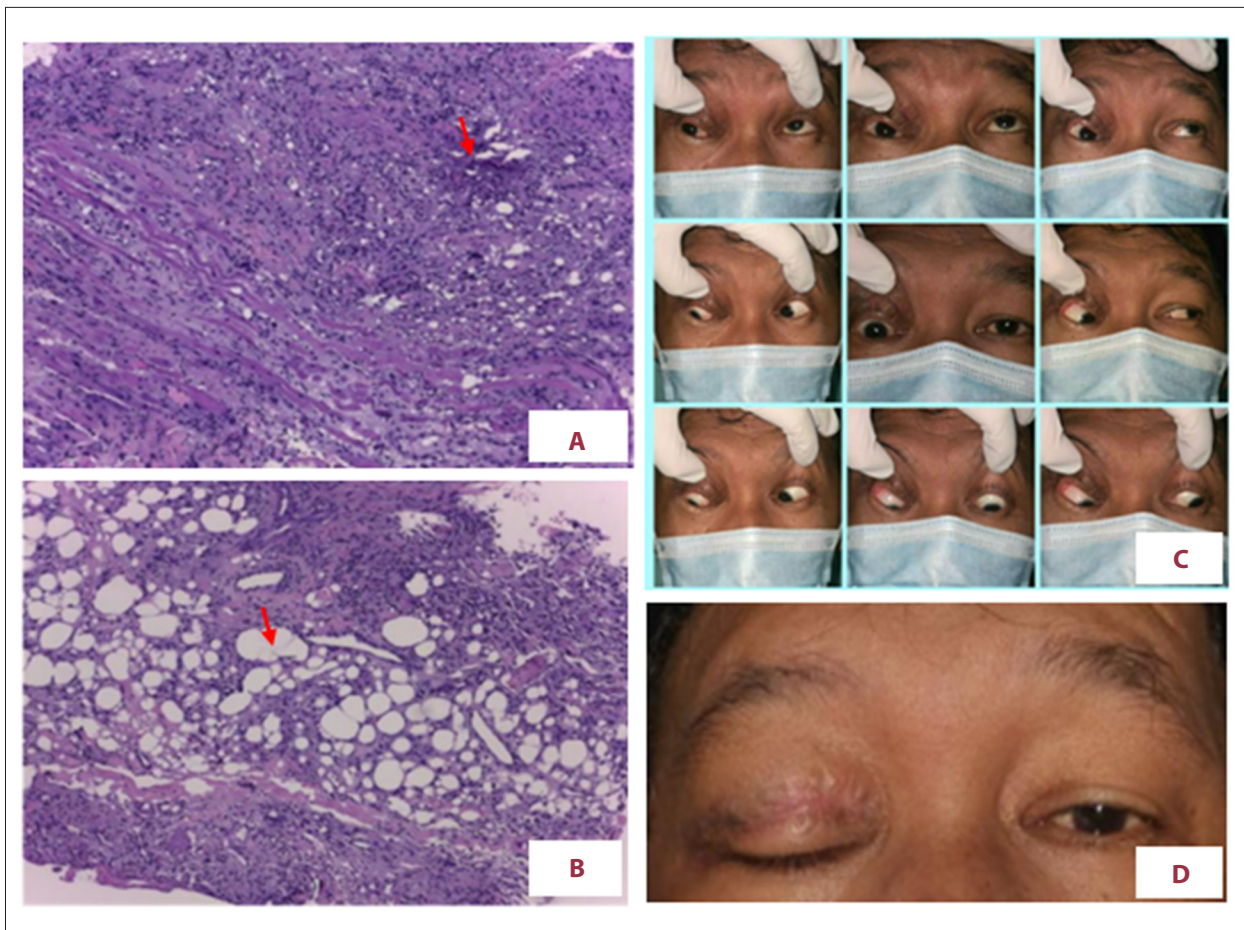


**Figure 1.** Preoperative photographs and computed tomography (CT) images of the patient: (A) The day of injury, saline irrigation and a simple eyelid repair was performed. (B) Four days after initial treatment, worsening of the right upper eyelid swelling occurred. (C) Orbital CT scan on the fourth day after injury, showing multiple abscesses and pneumo-orbital formations.

## Discussion

The etiology for acute orbital cellulitis is broad. A complete history should include the onset and duration of pain and orbital symptoms, details of the associated trauma or foreign body exposure, and the presence of fever and constitutional symptoms. Predisposing factors such as sinusitis, thyroid disease, vascular entities, immunosuppressive conditions, medications, and malignancy must be further explored [1].

The present case was caused by blunt trauma from an orbital compressed air and diesel explosion. The typical features, which should be considered as the warning signs, are burn or necrotic injury of the skin, corneal epithelial defects, inflammation at the anterior chamber, and an increase in intraocular pressure. These symptoms should be considered at the initial diagnosis, should be identified through a physical examination at the time of admission, and should be followed by evaluation and radiologic examination [2].



**Figure 2.** (A) Histological samples showed fragments of orbital tissue including globules of adipose tissue, infiltrated by blood and a number of largely necrotic PMN leukocytes. (B) Some clear vacuoles in different sizes with swiss cheese appearance in between. (C) Four months after surgery, there were upward temporal, central, and nasal gaze restrictions. (D) There was slight ptosis with periorbital edema, which gradually improved.

In the present case, the rapid progressive of symptoms within the first 4 days began as slight periorbital edema and partial thickness laceration and worsened to swelling and erythema on the right eyelid, accompanied by the other clinical signs and symptoms including fever, ophthalmoplegia, and proptosis. There was no focal infection found in the ears, nose, throat, and oral cavity that could have caused the orbital cellulitis [2,3].

Furthermore, the modality of choice for identifying suspected ocular foreign bodies is CT scan, which commonly shows hypointense lesions for air, fuel, or vegetative matter, with multiple low-frequency bubbles. The study by Chemma et al, which addressed orbital granulomatous inflammation caused by explosive hydraulic oil, reported preseptal intraconal inflammation and atypical hypodense loculated spaces on CT scan, which raised concern for gas-forming anaerobic organisms [3]. These findings are similar those found in our patient, who appeared with multiple abscesses and pneumo-orbital formations.

In the present case, orbital biopsy results revealed evidence of multiple clear vacuoles, which were remarkably observed forming a swiss cheese appearance. This is the characteristic histologic feature of a reaction to a foreign body that led to the diagnosis of orbital cellulitis related to the compressed air and diesel explosion. Foreign body reaction is the last step of the inflammation and wound healing process following the implantation of various materials into human tissue. This is supported by Shin et al, who reported similar findings in their case, which presented a cellulitis-like foreign body reaction after a hyaluronic acid dermal filler injection [4].

Diesel fuels are a complex hydrocarbon mixture made from the distillation of crude oil. Diesel fuels contain all the classes of hydrocarbons: paraffins, naphthenes, and aromatics, and in small concentrations, olefins. It was noted that hydrocarbons damage the tissue by dissolving the lipid-rich membranes of the microvasculature and act as a defatting agent, similar in action to liquefaction necrosis [5,6]. Based on the studies of

Rabinowitz et al and McCallum et al, there may be a mechanism of tissue destruction from petroleum-based products which is corrosive and toxic and leads to acute physical trauma. The high pressure causes a compartment syndrome of retrobulbar spaces, and the mechanisms of inflammation, thrombosis, vasospasm, or optic nerve ischemia [7,8].

The management of orbital cellulitis due to diesel explosion injury ranges from the close observation of asymptomatic patients to the immediate surgical exploration and removal of the chemical oil [9,10]. Our present case demonstrates that atypical features should prompt an orbital biopsy and surgical debridement. Initial therapy begins with thorough irrigation and debridement and, according to Chemma et al, if debridement is inadequate, the residual foreign material may give rise to similar inflammatory episodes in the future, after reduction of inflammation by corticosteroid therapy [3].

In our present case, the administration of corticosteroids followed by orbital decompression was a similar therapy to that used in the cases of Mellington et al and Park et al, who

reported orbital damage due to a compressed air and petroleum-based carburetor cleaner injury and a grease gun injury, respectively [11,12]. Our patient's vision and lesion improved 1 month after the operation and significantly improved to a good clinical condition after 4 months.

## Conclusions

Diesel explosion injury can cause orbital cellulitis that appears to be a simple case at first but can progressively worsen and have a poor prognosis. Exploring the patient's trauma history, detailed physical examination, and radiological and pathological results are essential to establish a diagnosis, and early diagnosis is key to preventing progression. Surgical debridement and the administration of corticosteroids and antibiotics were key in managing the presented case of orbital cellulitis.

## Conflict of Interest

None.

## References:

1. Chaudhry I, Al-Rashed W, Arat Y. The hot orbit: Orbital cellulitis. *Middle East Afr J Ophthalmol*, 2012;19(1):34-42
2. Bae K, Cho N, You I, Ahn M. Orbital cellulitis from an orbital compressed air and diesel explosion injury. *Korean J Ophthalmol*, 2018;32(2):158-59
3. Cheema M, Roelofs K, Jivraj I, et al. A rare case of orbital granulomatous inflammation from explosive hydraulic oil masquerading as orbital cellulitis. *Orbit*, 2017;37(2):154-56
4. Shin Y, Kwon W, Cho E, et al. A case of cellulitis-like foreign body reaction after hyaluronic acid dermal filler injection. *Dermatologica Sinica*, 2018;36(1):46-49
5. McKee, RH, White R. The mammalian toxicological hazards of petroleum-derived substances: An overview of the petroleum industry response to the high production volume challenge program. *Int J Toxicol*, 2014;33:4-16
6. Hai N, Levi Y, Golan J. Subcutaneous injection of household spray insecticide: A rare cause of soft tissue damage. *Eur J Plast Surg*, 2003;25(7-8):421-23
7. Rabinowitz M, Goldstein S. Diesel fuel injury to the orbit. *Ophthalmic Plast Reconstr Surg*, 2013;29(1):e31-33
8. McCallum E, Keren S, Lapira M, Norris J. Orbital compartment syndrome: An update with review of the literature. *Clin Ophthalmol*, 2019;13:2189-94
9. Woher JR, Nelson CC. Eyelid lipogranuloma after hydraulic oil injury. *Ophthalm Plast Reconstr Surg*, 1991;7:133-37
10. Doneker D, Paridaens D, Mooy C, van den Bosch W. Blepharoptosis and upper eyelid swelling due to lipogranulomatous inflammation caused by silicone oil. *Am J Ophthalmol*, 2005;140:934-36
11. Mellington FE, Bacon AS, Abu-Bakra MA, et al. Orbital compressed air and petroleum injury mimicking necrotizing fasciitis. *J Emerg Med*, 2014;47:e69-72
12. Park JH, Jang JW, Kim SJ, Lee YJ. Traumatic optic neuropathy accompanying orbital grease gun injury. *Korean J Ophthalmol*, 2010;24:134-38