



Taibah University

Journal of Taibah University Medical Sciences

www.sciencedirect.com



Original Article

Histomorphology of enteric neurons and enteric ganglia in different layers of human fetal colon

Chacchu Bhattarai, Ph.D. Scholar^{a,b}, Phanindra P. Poudel, Ph.D. Scholar^{a,b},
Arnab Ghosh, MD^c and Sneha G. Kalthur, MS^{a,*}

^a Department of Anatomy, Kasturba Medical College, Manipal, Manipal Academy of Higher Education, Karnataka, India

^b Department of Anatomy, Manipal College of Medical Sciences, Pokhara, Nepal

^c Department of Pathology, Manipal College of Medical Sciences, Pokhara, Nepal

Received 22 September 2021; revised 11 January 2022; accepted 22 January 2022; Available online 9 February 2022



المخلص

أهداف البحث: تُظهر المؤلفات عددًا قليلاً جدًا من الدراسات التي تشرح مورفولوجيا الخلايا العصبية المعوية والعقد في البشر. هدفت هذه الدراسة إلى تحديد النسيج المورفولوجي للخلايا العصبية المعوية والعقد في القولون الجنيني البشري.

طرق البحث: تم تلوين المقاطع النسيجية لقولون الجنين البشري بالهيماتوكسيلين وبيوزين، فضية بيلشوفسكي وبقع ماسون ثلاثية الألوان لدراسة التشكل النسيجي للأمعاء والخلايا العصبية والعقد.

النتائج: الخلايا العصبية المعوية تكون مبعثرة في الأسابيع الأولى من التطور وتتكون العقد مع تقدم عمر الجنين. كانت هجرة الخلايا العصبية المعوية أقل وفي شكل متباعد خلال الأسابيع الأولى ومع تقدم العمر كانت أكثر وفي شكل عقدي. كانت الخلايا العصبية المعوية مستديرة وبيضاوية وهرمية ومسطحة في جميع طبقات القولون. كانت العقد المعوية في المصل ببيضاوية في الأسابيع الأولى واستطالت في أواخر الأسابيع بينما كانت قليلة وبيضاوية وغير منتظمة وممدودة بين طبقات العضلات وتحت المخاطية. زادت المسافة بين العقد المعوية في الطبقة المصلية، ولكن تقلبت في الطبقات المتبقية مع تقدم عمر الحمل. عدد الخلايا العصبية المعوية والعقد كانت أكثر في الطبقة المصلية وأقل في الطبقات الأخرى خلال الأسابيع الأولى وكلما تقدم عمر الجنين انخفضت في الطبقة المصلية ولكن زادت في الطبقات الأخرى.

الاستنتاجات: هناك أشكال وأعداد مختلفة من الخلايا العصبية المعوية والعقد والمسافات بين العقد في الطبقات المختلفة من القولون الجنيني.

الكلمات المفتاحية: القولون؛ العقد المعوية؛ عصب معوي؛ أنبوب الأمعاء؛ القياس النسيجي

Abstract

Objective: Literature shows very few studies explaining morphology of enteric neurons and ganglia in humans. This study was aimed at determining the morpho-histology of enteric neurons and ganglia in human fetal colon.

Methods: Histological sections of human fetal colon were stained with hematoxylin and eosin, Bielschowsky's silver and Masson's trichrome stains to study the morpho-histology of enteric neurons and ganglia.

Results: Enteric neurons scattered in the early weeks of development and ganglionated as the fetal age progresses. Migration of enteric neurons was less and in scattered form during early weeks and as the age progresses it was more and in ganglionated form. Enteric neurons were round, oval, pyramidal and flat in all layers of colon. Enteric ganglia in serosa were oval in early weeks, oval and elongated in late weeks whereas in between the muscle layers and submucosa they were few and oval, irregular and elongated. Distance between the enteric ganglia increased in serosa but fluctuated in the remaining layers as the gestational age progressed. Number of enteric neurons and ganglia was more in serosa and less in other layers during early weeks and as the fetal age progressed they decreased in serosa but increased in other layers.

Conclusion: There are various shapes and numbers of enteric neurons and ganglia and distances between the ganglia in different layers of fetal colon.

* Corresponding address: Department of Anatomy, Kasturba Medical College, Manipal, Manipal Academy of Higher Education (MAHE), Karnataka, 576104, India.

E-mail: sneha.guruprasad@manipal.edu (S.G. Kalthur)

Peer review under responsibility of Taibah University.



Production and hosting by Elsevier

Keywords: Colon; Enteric ganglia; Enteric neuron; Gut tube; Histomorphology

© 2022 The Authors.

Production and hosting by Elsevier Ltd on behalf of Taibah University. This is an open access article under the CC BY-NC-ND license (<http://creativecommons.org/licenses/by-nc-nd/4.0/>).

Introduction

Literature describes mostly the morphometric studies of the enteric neurons and ganglia in several animal models¹ and several diseased conditions² in the human gastrointestinal tract. These studies have reported variations in enteric neurons and ganglia of myenteric and submucosal plexuses with respect to their shape and number.³ However, there are no studies found in the literature that explains arrangement, shape, migration pattern and numbers of enteric neurons and ganglia at different gestational ages. The morphological study of enteric neurons and ganglia in the human fetal colon gives the basic information regarding histogenesis which can have developmental and clinical value. Therefore, the main aim of our research was to observe the developmental pattern of enteric neurons and ganglia in the fetal colon at different gestational ages.

Materials and Methods

Study design and settings

This is a quantitative, descriptive observational study. Study population is stillbirth and spontaneously aborted human fetuses (n = 36) collected by using the convenience sampling method. Fetuses with gut tube and neural tube defects were excluded. Sturge's rule " $k = 1 + 3.322 \log_{10} N$ " was used for grouping the fetuses into eight groups: 10–14, 14–18, 18–22, 22–26, 26–30, 30–34, 34–38 and >38 weeks.

Fetuses were fixed in 10% neutral buffered formalin for 2 days. Colon tissue was taken and processed in automatic rotatory tissue processor (LEICA TP 1020). Paraffin blocks were prepared by using Leuckhart's brass moulds. Hematoxylin and eosin, Masson's trichrome and Bielschowsky's silver stains were used to study the histomorphology,

migration and confirmation of enteric neurons and ganglia respectively.

Observations

Sections of the colon were observed in a Labomed compound microscope under eyepiece 10x, field number (FN) 18 and objectives 10x, 40x and 100x. Number of enteric ganglia and enteric neurons and distance between the enteric ganglia in different layers of colon were observed in a Field of View (FOV)/focus by using ocular (Erma) and stage (Unilab) micrometers. Micrometers were calibrated by using the reference slide of peripheral blood smear (Table 1).⁴ Field of View was calculated as: Field number (FN)/Total magnification i.e 18/Total magnification.⁵ Total magnification (×) was calculated by multiplying the magnification of objective lens with the magnification of eyepiece. Number of enteric neurons were counted in Field of View 18 μm and area of view 254.34 μm² of the sections under 100x (oil immersion). Number of enteric ganglia and distance between the enteric ganglia were observed in Field of View 45 μm and area of view 1.58 μm² of the sections under 40x. Counting of neurons and ganglia was performed manually by two observers blinded to samples.

Statistical analysis

Data obtained were analyzed in SPSS 16.0 version. Nominal data were calculated in percentage, and their comparison was performed by using Chi-square test. Quantitative data were calculated in mean ± S.E of mean and their comparison was performed by using one-way-ANOVA test for normally distributed data and Kruskal Wallis test for non-normally distributed data in 95% confidence interval (CI) and 5% level of significance (p < 0.05). Graphs were plotted using Microsoft Excel version 2013.

Results

Enteric neurons were arranged in ganglionated form in majority of cases in serosa and in between the muscle layers whereas in submucosa (p = 0.01) they were scattered in early weeks and arranged in ganglionated form in mid and late weeks of gestation (Graph 1).

Table 1: Calibration of ocular and stage micrometers.

Objectives	Marks in ocular micrometer	Marks in stage micrometer	1 ocular mark = x stage marks (Calculation: stage marks/ocular marks)	1 stage mark = 10 μm; 1 ocular mark = x μm
4×	16	50	3.125 marks	31.25 μm
10×	15	20	1.333 marks	13.33 μm
40×	16	5	0.312 marks	3.12 μm
100×	39	5	0.128 marks	1.28 μm

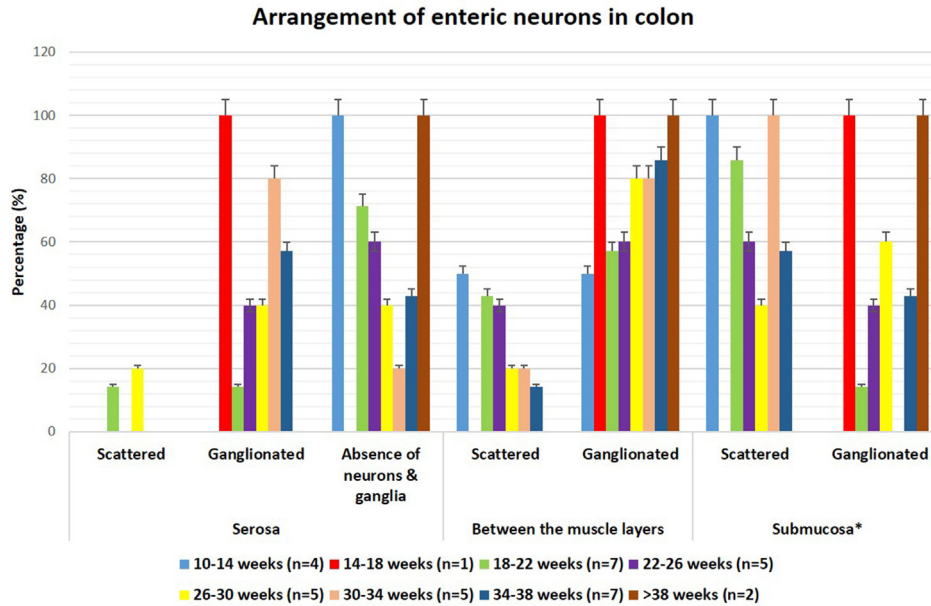
Migration of enteric neurons was observed in ganglionated form in majority of cases in 14–18 weeks and 30–38 weeks from serosa to muscle layers ($p = 0.01$) and in 10–14 weeks and 30–>38 weeks from muscle layers to submucosa ($p = 0.02$) (Graph 2, Figure 1).

Shape of enteric ganglia was predominantly oval in serosa. In between the muscle layers, they were oval, irregular and elongated. In submucosa, neurons were in scattered form whereas a few oval and elongated ganglia were also observed (Graph 3, Figure 2). Shape of enteric neurons in serosa,

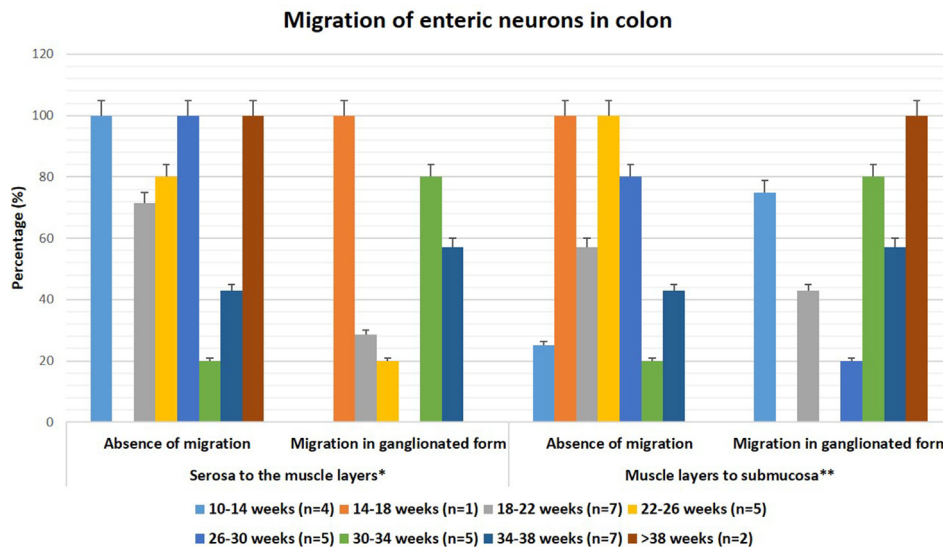
between the muscle layers and submucosa were predominantly multiple in shape i.e. round, oval, pyramidal and flat (Graph 4, Figures 3 and 4).

Distance between the enteric ganglia increased from $3.12 \mu\text{m}$ to $49.4 \pm 26.58 \mu\text{m}$ in serosa and from $10.2 \pm 6.29 \mu\text{m}$ to $96.1 \pm 18.01 \mu\text{m}$ in between the muscle layers ($p = 0.01$) whereas in submucosa it fluctuated ($p = 0.003$) as the gestational age progressed (Table 2).

Number of enteric ganglia in serosa increased from 18 to 34 weeks then it decreased up to >38 weeks. In



Graph 1: Arrangement of enteric neurons in serosa, between the muscle layers and submucosa of colon observed in H&E stained sections of different gestational weeks in 400× magnification (*p-value = 0.01, n = 36).



Graph 2: Migration of enteric neurons from serosa to muscle layers and muscle layers to submucosa in colon in H&E stained sections of different gestational weeks in 400× magnification (p-value = *0.01, **0.02, n = 36).

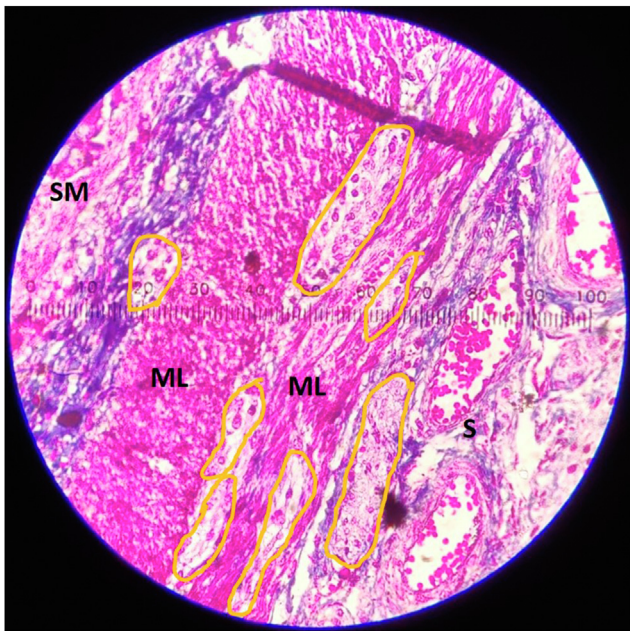


Figure 1: Masson Trichrome stained section of colon showing migration of enteric neurons and ganglia (yellow colored outline) from serosa (S) to muscle layers (ML) and muscle layers (ML) to submucosa (SM) through connective tissue fibers (blue) and muscle layers (pink) in a compound microscope in 400× magnification picture taken by One plus 9 pro, LE2121. Each mark of ocular micrometer equals 3.12 μm.

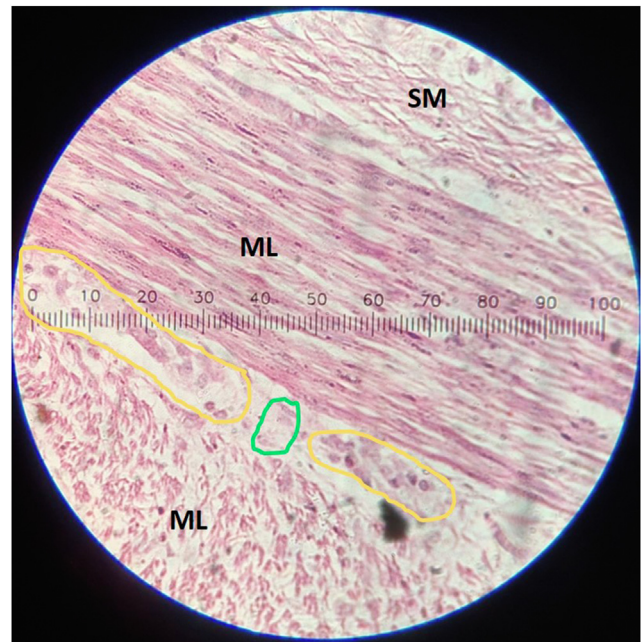
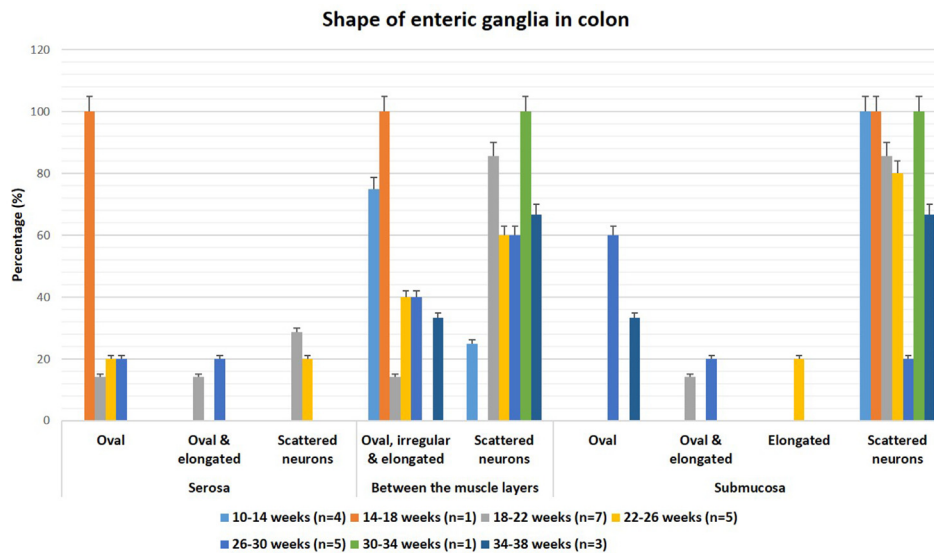
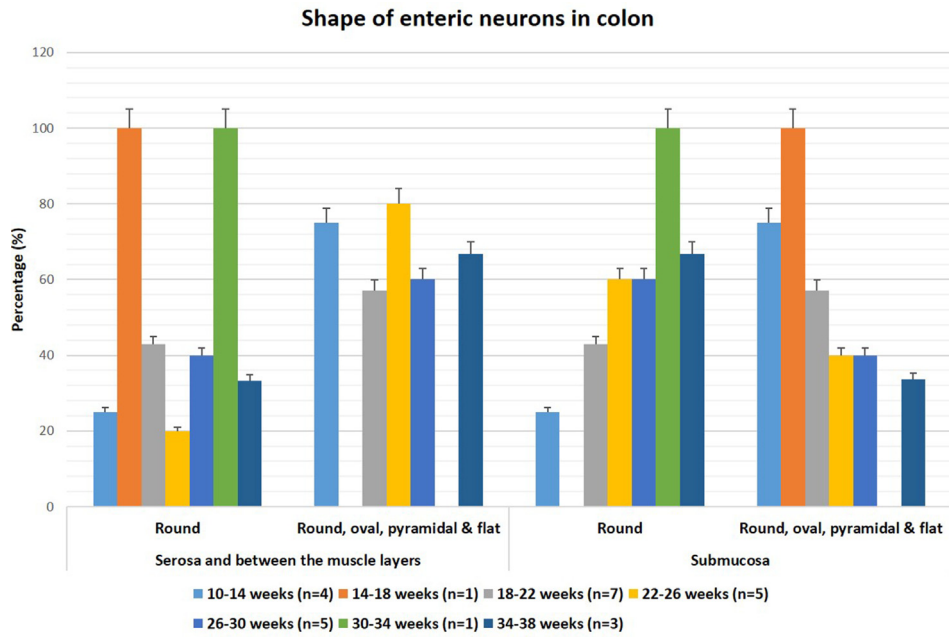


Figure 2: H&E stained section of colon showing different shapes of enteric ganglia (yellow outline-elongated ganglia, green outline-oval ganglia) in a compound microscope in 400× magnification picture taken by One plus 9 pro, LE2121. Each mark of ocular micrometer equals 3.12 μm. ML-muscle layers, SM-submucosa.



Graph 3: Shape of enteric ganglia in serosa, between the muscle layers and submucosa of colon in H&E stained sections of different gestational weeks in 400× magnification (n = 26).



Graph 4: Shape of enteric neurons in serosa, between the muscle layers and submucosa of colon in H&E stained sections of different gestational weeks in 1000× magnification, oil immersion (n = 26).

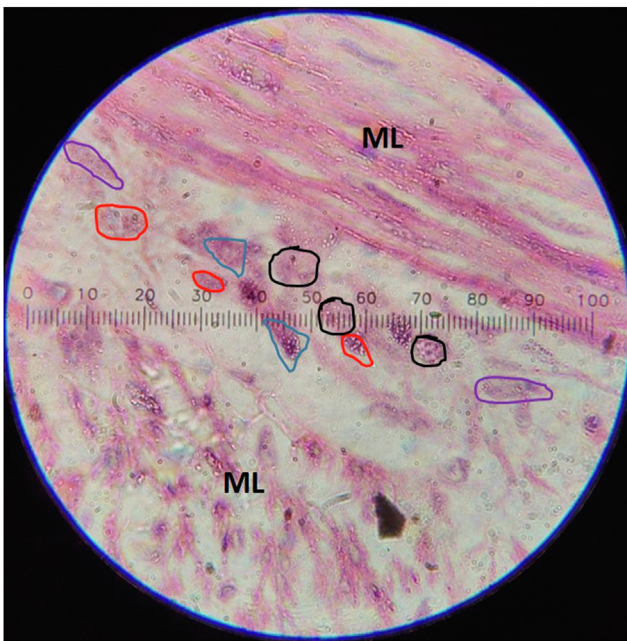


Figure 3: H&E stained section of colon showing different shapes of enteric neurons (black outline-round, red outline-oval, blue outline-pyramidal, purple outline-flat) in a compound microscope in 1000× magnification, oil immersion picture taken by One plus 9 pro, LE2121. Each mark of ocular micrometer equals 1.28 μm. ML-muscle layers.

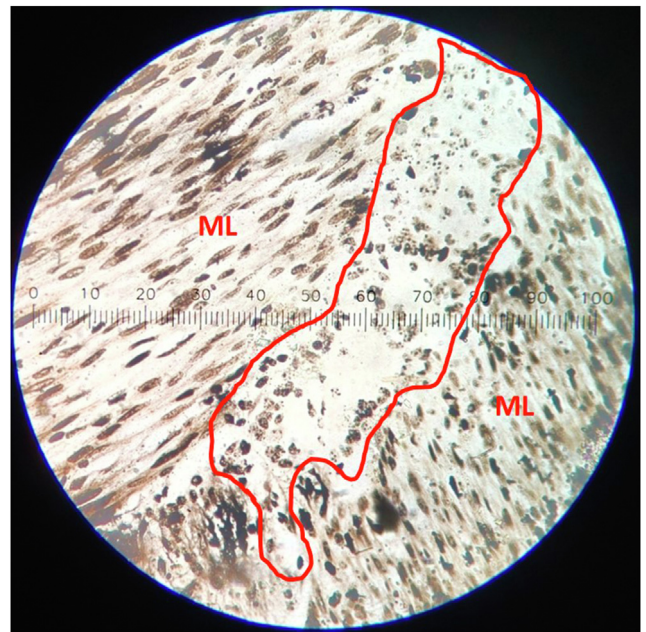


Figure 4: Bielchowsky's silver stained section of colon confirming the enteric neurons (within red colored outline) and ganglia in a compound microscope in 400× magnification picture taken by One plus 9 pro, LE2121. Each mark of ocular micrometer equals 3.12 μm. ML-muscle layers.

Table 2: Distance between the enteric ganglia. p-value indicates comparison between the mean distance between the enteric ganglia among different gestational age groups in different layers of colon. Asterisk denotes the obtained value is statistically significant between the gestational age groups. Observations in 400× magnification in field of view 45 μm and area of view 1.58 μm² in H&E stained sections.

Gestational age	Serosa (Mean ± S.E) μm	Between the muscle layers (Mean ± S.E) μm	Submucosa (Mean ± S.E) μm
10–14 weeks (n = 4)	0	15.9 ± 6.4	0
14–18 weeks (n = 1)	15.6	0	43.7
18–22 weeks (n = 7)	11.7 ± 7.67	10.9 ± 7.12	9.7 ± 9.65
22–26 weeks (n = 5)	3.12 ± 3.12	10.2 ± 6.29	12.5 ± 12.48
26–30 weeks (n = 5)	13.31 ± 9.2	16.4 ± 7.89	40.1 ± 12.12
30–34 weeks (n = 5)	41.92 ± 15.17	38.4 ± 11.56	0
34–38 weeks (n = 7)	49.4 ± 26.58	56.6 ± 20.98	13.4 ± 9.27
>38 weeks (n = 2)	0	96.1 ± 18.09	88.3 ± 36.5
p-value	0.26	0.013*	0.003*

Table 3: Number of enteric ganglia. p-value indicates comparison between the mean number of enteric ganglia among different gestational age groups in different layers of colon. Asterisk denotes the obtained value is statistically significant between the gestational age groups. Observations in 400× magnification in field of view 45 μm and area of view 1.58 μm² in H&E stained sections.

Gestational age	Serosa (Mean ± S.E)	Between the muscle layers (Mean ± S.E)	Submucosa (Mean ± S.E)
10–14 weeks (n = 4)	0	1 ± 1	0
14–18 weeks (n = 1)	1	4	2
18–22 weeks (n = 7)	0.1 ± 0.14	1.3 ± 0.47	0.14 ± 0.14
22–26 weeks (n = 5)	0.4 ± 0.24	1.2 ± 0.58	0.6 ± 0.4
26–30 weeks (n = 5)	0.4 ± 0.24	2 ± 0.7	0.8 ± 0.37
30–34 weeks (n = 5)	1 ± 0.31	2 ± 0.54	0
34–38 weeks (n = 7)	0.57 ± 0.2	2 ± 0.43	0.28 ± 0.18
>38 weeks (n = 2)	0.4	1.7 ± 1	1
p-value	0.06	0.4	0.01*

Table 4: Number of enteric neurons. p-value indicates comparison between the mean number of enteric neurons among different gestational age groups in different layers of colon. Asterisk denotes the obtained value is statistically significant between the gestational age groups. Observation in 1000× magnification in field of view 18 μm and area of view 254.34 μm² in H&E stained sections.

Gestational age	Serosa (Mean ± S.E)	Between the muscle layers (Mean ± S.E)	Submucosa (Mean ± S.E)
10–14 weeks (n = 4)	0	11 ± 1.58	4.5 ± 1.19
14–18 weeks (n = 1)	35	31	18
18–22 weeks (n = 7)	2.28 ± 1.53	14 ± 2.97	4.14 ± 0.98
22–26 weeks (n = 5)	3 ± 2	10 ± 3.01	2.8 ± 0.91
26–30 weeks (n = 5)	3.8 ± 1.74	12.6 ± 3.72	4.8 ± 1.2
30–34 weeks (n = 1)	0	5	4
34–38 weeks (n = 3)	0	4.67 ± 0.88	3.33 ± 1.45
p-value	0.00*	0.07	0.002*

between the muscle layers, it was maximum in 14–18 weeks then it decreased up to 22–26 weeks and then increased and became constant value during 26–38 weeks. In submucosa ganglia numbers fluctuated ($p = 0.01$) (Table 3). Number of enteric neurons was maximum in serosa, in between the muscle layers and submucosa in 14–18 weeks. Then it decreased in serosa ($p = 0.00$) whereas in between the muscle layers and submucosa ($p = 0.002$) it fluctuated in the remaining weeks (Table 4).

Discussion

Animal studies described that enteric neuroblasts at first arrange in serosa, migrate through muscle layers to submucosa,⁶ and second wave of migration occurs back from submucosa to muscle layers to form myenteric plexus and remigrate to submucosa to form submucosal plexus.⁷ Whereas in our study, enteric neurons were scattered in early weeks (18–22 weeks) and as the age progresses (22–38 weeks) they were arranged in the ganglionated form in

all layers of colon. In late weeks (34–38 weeks) serosa has no neurons and ganglia. This implied that enteric neuroblasts were scattered in the beginning in serosa but as age progresses they form ganglia and undergo migration into the muscle layers forming myenteric plexus and into submucosa forming submucosal plexus. There was no evidence of second wave of migration from submucosa back to muscle layers in this study.

Shape of enteric ganglia are elongated, oval and polygonal in rodents,⁸ ovoid, oval, elongated, polygonal, round and irregular in cattle,^{9,10} circular, oval, egg-shaped, polygonal and rectangular in adult rats^{1,11} and enteric neurons are arranged in rows without forming ganglia in embryonic rats.¹² Whereas in our human fetal study showed, in early weeks, they were oval in serosa, oval, irregular and elongated in between the muscle layers and scattered neurons and absence of ganglia in submucosa. As the gestational age progressed, they were oval and elongated in serosa, oval, irregular and elongated in between the muscle layers and oval and elongated in submucosa.

Shape of enteric neurons are round, oval, pyramidal, fusiform and stellate in myenteric plexus¹¹ and round, oval and elliptical in the submucosal plexus in rats.¹³ Guinea-pigs study showed elliptical and round neurons,¹⁴ whereas cattle study showed round, oval, elongated and irregular neurons in myenteric plexus.⁹ Our study showed round, oval, pyramidal and flat enteric neurons in the early weeks and predominantly round as the gestational age progresses. The shape of neurons observed in this human fetal study was similar to the animal studies.

In their study, Kim HK et al. found $90.77 \pm 36.07 \mu\text{m}$ distance in between the enteric ganglia in thirteen-week human fetuses,² whereas in our study in 10 to >38 weeks human fetuses distance between the ganglia was less in serosa in all weeks but it was closer to the observation of Kim HK et al. in between the muscle layers ($96.1 \pm 18.09 \mu\text{m}$) and submucosa ($88.3 \pm 36.5 \mu\text{m}$) in >38 weeks fetuses (Table 2). In our study, distance between the enteric ganglia in serosa was $15.6 \mu\text{m}$ in the early weeks (14–18 weeks). As the gestational age progresses, the distance decreased in 18–26 weeks and increased in 26–38 weeks. In between the muscle layers, it was $15.9 \pm 6.4 \mu\text{m}$ in early weeks (10–14 weeks), decreased in 18–26 weeks and increased in 26–>38 weeks ($p = 0.013$). In submucosa, it was $43.7 \mu\text{m}$ in early weeks (14–18 weeks) and fluctuated as the age progressed ($p = 0.003$). It was observed that as the gestational age progresses the distance between ganglia increases.

Human study showed $174.5 \pm 93/100 \text{ mm}$ myenteric ganglia and $123 \pm 98.50/100 \text{ mm}$ submucosal ganglia¹⁵ and animal studies showed $19.21 \pm 0.99/\text{mm}^2$, $25.54 \pm 3.03/\text{mm}^2$ and $6.48 \pm 0.33/\text{mm}^2$ enteric ganglia in histochemical techniques (Giemsa stain, NADH-diaphorase and NADPH-diaphorase)¹³ and 51 ± 5 myenteric and 31 ± 2 submucosal ganglia per circumferential tissue section in immunohistochemistry.¹⁶ Whereas, in our study in 10 to > 38 weeks human fetuses in $1.58 \mu\text{m}^2$ area of colon, number of ganglia was observed more (Table 3) in comparison to the given human and animal studies. In our study, in serosa number of enteric ganglia was decreased in early weeks, increased in midweeks and decreased in late weeks, in between the muscle layers they were increased in early and midweeks and decreased in late weeks whereas in

submucosa ($p = 0.01$) they were decreased in early weeks and increased in mid and late weeks. Our study showed that there is fluctuation in the number of enteric ganglia as the gestational age progresses but age-related studies described that there are empty ganglia with less number of neurons^{17,18} and studies in gastrointestinal diseases described that there is decrease in the number of ganglia.¹⁹

Animal studies showed that enteric neurons are $11.78 \pm 2.89/\text{mm}^2$ in mesenteric border, $12.06 \pm 2.69/\text{mm}^2$ in intermediate part and $10.67 \pm 1.89/\text{mm}^2$ in antimesenteric border of jejunum in rats²⁰ and 1271 ± 227.54 neurons/ 6.64 mm^2 , 530 ± 92.97 neurons/ 6.64 mm^2 , and 417 ± 34.42 neurons/ 6.64 mm^2 in different stains in rats²¹ and 1600 neurons/ mm^2 in guinea pigs.²² Whereas, our study in human fetuses showed more number of the enteric neurons counted in $254.34 \mu\text{m}^2$ area of colon in 10 to >38 gestational weeks (Table 4) as compared to the animal studies. In our study, in serosa it was $35/254.34 \mu\text{m}^2$ in 14–18 weeks, decreased in 18–22 weeks, increased in 18–30 weeks ($p = 0.00$), in between the muscle layers it was $11 \pm 1.58/254.34 \mu\text{m}^2$ in 10–14 weeks, increased in 14–18 weeks, decreased in 18–26 weeks, increased in 26–30 weeks and decreased in 30–38 week whereas in submucosa ($p = 0.01$) it was $4.5 \pm 1.19/254.34 \mu\text{m}^2$ in 10–14 weeks then it fluctuated as the age progresses. Our study observed that there is fluctuation in the number of enteric neurons as the gestational age progresses but studies in adult animals²³ and humans¹⁷ described that there will be decreases in number of enteric neurons as age increases.

Outcomes of this study described the arrangement, migration and shape of enteric neurons and ganglia and distance between the enteric ganglia in human fetal colon to give a standard view of morpho-histology of enteric neurons and ganglia in human during development and it can be further studied in large sample groups.

Conclusion

As the gestational age progresses, various shapes of scattered enteric neurons arrange in various forms of ganglia. These at first lie in serosa, then penetrate the muscle layers to form the myenteric plexus and finally migrate into the submucosa to form the submucosal plexus in the colon with variation in the number of enteric neurons, ganglia and distance between the ganglia.

Recommendations

The knowledge regarding the morphology of fetal enteric neurons and ganglia of colon may provide information to clinicians regarding their role in the peristalsis and to understand the associated gut abnormalities.

Source of funding

This study was supported by the Department of Science and Technology (DST), India by providing India Science and Research Fellowship (ISRF) with grant number DO/CCSTDS/197/2019 and the University Grants Commission (UGC), Nepal by providing a partial Ph.D. fellowship/2021.

Conflict of interest

The authors have no conflict of interest to declare.

Ethical approval

Ethical approval was taken from the Institutional Review Committee of Manipal College of Medical Sciences, Nepal with registration code MEMG/IRC/GA (i) on 1 March 2017 and from the Institutional Ethics Committee (IEC) of Kasturba Medical College and Kasturba Hospital (KMC & KH), India with registration number IEC: 192/2020 on 11 March 2020.

Authors contributions

CB conceived and designed the study, conducted research, provided research material, collected and organized data, wrote an initial draft of the article. PPP, AG analyzed and interpreted data. SGK wrote the final drafts of the manuscript and critically reviewed it, and provided logistic support. All authors have critically reviewed and approved the final draft and are responsible for the content and similarity index of the manuscript.

Acknowledgment

We acknowledge DC Agarwal, BM Nagpal, Shyamala Hande, BS Satish Rao, Niranjan Nayak, BP Powar, Kana-kata Iyer, Surjit Singh and Guruprasad Kalthur for their constant support to complete this study.

References

1. Maifrino LBM, Liberti EA, De Souza RR. Morphological and quantitative study of the myenteric plexus of the mouse colon. *J Morphol Sci* 2017; 24: 192–195.
2. Kim HK, Cheong H, Kang H, Bae JY, Song DE, Cho MS, et al. Histopathological evaluation of pediatric intestinal pseudo-obstruction: quantitative morphometric analysis of pathological changes in the enteric nervous system. *Korean J Pathol* 2010; 44: 162–172.
3. Bhukya S, Sing S, Sarwar S, Quadri JA, Ahmed A, Rani N, et al. Morphological changes of the myenteric plexus at different gut segments of human fetuses. *J Histotechnol* 2021; 43: 1–10.
4. Ocular and Stage micrometers. http://fire.biol.wvu.edu/cmoyer/ztemp_fire/biol346_W06/labman_week2.pdf.
5. How to Calculate the Field of View in a Microscope. Sciencing. <https://sciencing.com/calculate-field-microscope-7603588.html> (accessed 14 Nov 2021).
6. Obermayr F, Hotta R, Enomoto H, Young HM. Development and developmental disorders of the enteric nervous system. *Nat Rev Gastroenterol Hepatol* 2013; 10: 43–57.
7. Rao M, Gershon MD. Enteric nervous system development: what could possibly go wrong? *Nat Rev Neurosci* 2018; 19: 552–565.
8. Nowak E. Organization of the innervation of the oesophagus and stomach in chinchilla (*Chinchilla laniger*, Molina). *Folia Histochem Cytobiol* 2013; 5: 115–120.
9. Mazzuoli G, Mazzoni M, Albanese V, Clavanzani P, Lalatta-Costerbosa G, Lucchi ML, et al. Morphology and neurochemistry of descending and ascending myenteric plexus neurons of sheep ileum. *Anat Rec Adv Integr Anat Evol Biol* 2007; 290: 1480–1491.
10. Teixeira AF, Vives P, Krammer HJ, Kühnel W, Wedel T. Structural organization of the enteric nervous system in the cattle esophagus revealed by wholemount immunohistochemistry. *Ital J Anat Embryol Arch Ital Anat Ed Embriologia* 2001; 106: 313–321.
11. Kirov T, Atanasova D, Malinova L, Jeleu L, Lazarov N. Morphological characteristics and cytoarchitecture of the myenteric ganglia in the rat proximal colon. *Acta Morphol Anthropol* 2019; 26: 3–4.
12. de Vries P, Soret R, Suply E, Heloury Y, Neunlist M. Postnatal development of myenteric neurochemical phenotype and impact on neuromuscular transmission in the rat colon. *Am J Physiol Gastrointest Liver Physiol* 2010; 299: G539–G547.
13. Góis MB, Hermes-Uliana C, Paltanin A, Pontes W, Araújo EJDA, Miranda Neto MH, et al. Morphoquantitative study of *Rattus norvegicus* submucosal plexus by different neuronal evidentiating histochemical techniques. *Int J Morphol* 2016; 34: 1487–1493.
14. Ceregrzyn M, Woliński J, Kuch B. A three-dimensional analysis of jejunal myenteric ganglia: a tool for interpretation of the optical recording of membrane potential. *Arch Med Sci* 2006; 2: 226–234.
15. Wedel T, Büsing V, Heinrichs G, Nohroudi K, Bruch HP, Roblick UJ, et al. Diverticular disease is associated with an enteric neuropathy as revealed by morphometric analysis. *Neurogastroenterol Motil* 2010; 22: 407–e94.
16. Jabaji Z, Stark R, Dunn JCY. Regeneration of enteric ganglia in mechanically lengthened jejunum after restoration into intestinal continuity. *J Pediatr Surg* 2013; 48: 118–123.
17. Mandić P, Lestarević S, Filipović T, Savić S, Stević S, Kostić M. Age-related changes in the myenteric plexus of the human jejunum. *Folia Morphol* 2015; 75: 188–195.
18. Mandić P, Lestarević S, Filipović T, Đukić-Macut N, Đukić N, Saranović M. Age-related structural changes in the myenteric nervous plexus ganglion along the anterior wall of the proximal human duodenum—a morphometric analysis. *Vojnosanit Pregl* 2013; 70: 177–181.
19. Boschetti E, Malagelada C, Accarino A, Malagelada JR, Cogliandro RF, Gori A, et al. Enteric neuron density correlates with clinical features of severe gut dysmotility. *Am J Physiol-Gastrointest Liver Physiol* 2019; 317: G793–G801.
20. De Britto Mari R, Scoz J, De Melo Germano R, Pereira J, De Toledo E, De Faria H, et al. Quantification and morphometry of myenteric neurones in the jejunum of Holtzman rats (*Rattus norvegicus*). *Anat Histol Embryol* 2011; 40: 256–262.
21. Araújo EJ de A, Sant’Ana D de MG, Molinari SL, Miranda Neto MH de. Regional differences in the number and type of myenteric neurons in the descending colon of rats. *Arq Neuropsiquiatr* 2003; 61: 220–225.
22. Peck C, Samsuria S, Harrington A, King S, Hutson J, Southwell B. Fall in density, but not number of myenteric neurons and circular muscle nerve fibres in Guinea-pig colon with ageing. *Neurogastroenterol Motil* 2009; 21: 1075–e90.
23. Yuhui G, Zhihao C, Jie L, Yumin H, Zhengguo X, Ding Y, et al. Protective effects of saponins from *Panax japonicus* on neurons of the colon myenteric plexus in aging rats through reduction of α -synuclein through endoplasmic reticulum stress. *Geriatr Gerontol Int* 2021; 21: 85–93.

How to cite this article: Bhattarai C, Poudel PP, Ghosh A, Kalthur SG. Histomorphology of enteric neurons and enteric ganglia in different layers of human fetal colon. *J Taibah Univ Med Sc* 2022;17(4):556–563.