

Make Your Own Deep Inferior Epigastric Artery Perforator Flap: Perforator Delay Improves Deep Inferior Epigastric Artery Perforator Flap Reliability

Sameer Shakir, MD
Amy B. Spencer, PA-C
Geoffrey M. Kozak, MD
Eric M. Jablonka, MD
Suhail K. Kanchwala, MD

Background: Abdominal-based autologous breast reconstruction remains a conflict between blood supply and donor site complication. Optimizing esthetics and minimizing recovery and postoperative pain add further complexity. We present a 2-stage technique of deep inferior epigastric artery perforator flap reconstruction to (1) reliably harvest single-vessel flaps while minimizing fat necrosis, (2) decrease abdominal wall morbidity, and (3) improve breast and donor site esthetics.

Methods: Female subjects presenting between August 2017 and January 2019 to the senior surgeon for abdominal-based breast reconstruction were included. After mastectomy, the subjects underwent subcutaneous placement of tissue expanders and in situ selection of a low, centrally located perforator based on preoperative computed tomographic angiography imaging through an infraumbilical “T” incision with ligation of all other perforators and superficial system. Subjects underwent tissue expander explant and flap transfer at a second stage.

Results: One hundred thirty-five subjects undergoing 215 free flaps met criteria. Mean age and body mass index were 52.1 years and 29.3 kg/m², respectively. Seven perforator complications (3.3%) occurred with 2 (0.9%) total and 5 (2.3%) partial flap losses. There were 20 (14.8%) readmissions and 26 (19.3%) reoperations. Breast complications included arterial thrombosis (0.5%), venous congestion (1.9%), and fat necrosis (5.1%). The mastectomy skin flap necrosis rate decreased from 14.9% to 2.3% following staged reconstruction. Abdominal donor site complications included delayed healing (11.1%), seroma (5.9%), and hematoma (2.2%).

Conclusions: The 2-stage delayed deep inferior epigastric artery perforator flap technique represents a safe, efficacious modality to allow for reliable harvest of single-vessel flaps with low rates of fat necrosis while improving donor site esthetics and morbidity. (*Plast Reconstr Surg Glob Open* 2019;7:e2478; doi: [10.1097/GOX.0000000000002478](https://doi.org/10.1097/GOX.0000000000002478); Published online 27 November 2019.)

INTRODUCTION

Autologous breast free flap reconstruction remains a conflict between blood supply and abdominal wall morbidity. Early pedicled and free transverse rectus abdominal myocutaneous¹ flap techniques pioneered by Hartrampf et al and Holmstrom favored blood supply at the cost of donor site.^{1,2} Later modifications including the deep inferior epigastric artery perforator (DIEP) free flap

described by Koshima and Soeda³ and Allen and Trece⁴ minimized donor site morbidity at the cost of bloody supply, with DIEP free flap breast reconstruction fat necrosis rates—presumably from vascular insufficiency—averaging 14.4% compared with 6.9% for the free TRAM variant.⁵

The vascular delay phenomenon in plastic surgery can be credited to Gaspare Tagliacozzi's early descriptions of nasal reconstruction using the arm flap in the 16th century.⁶ This phenomenon results in transient tissue ischemia which stimulates vascular changes whether it be from metabolic changes, neovascularization, or dilation of choke vessels.⁷ Although the idea of vascular delay has been previously studied in selected patient populations in pedicled and free TRAM-based autologous breast reconstruction (ABR),^{8–11} the indications and efficacy in

From the Division of Plastic Surgery, Department of Surgery, University of Pennsylvania, Philadelphia, Pa.

Received for publication July 14, 2019; accepted August 6, 2019.

Copyright © 2019 The Authors. Published by Wolters Kluwer Health, Inc. on behalf of The American Society of Plastic Surgeons. This is an open-access article distributed under the terms of the [Creative Commons Attribution-Non Commercial-No Derivatives License 4.0 \(CCBY-NC-ND\)](https://creativecommons.org/licenses/by-nc-nd/4.0/), where it is permissible to download and share the work provided it is properly cited. The work cannot be changed in any way or used commercially without permission from the journal.

DOI: [10.1097/GOX.0000000000002478](https://doi.org/10.1097/GOX.0000000000002478)

Disclosure: Dr. Suhail K. Kanchwala is a consultant for Allergan Inc. and Axogen Inc. The other authors have no financial disclosures.

DIEP-based reconstruction remain largely unknown. Can vascular delay mitigate blood supply issues inherent to DIEP flap reconstruction while maximizing abdominal wall functionality?

We present a novel 2-stage vascular delay technique of DIEP flap breast reconstruction to explore the flap and nonflap benefits associated with this technique. We hypothesized that DIEP delay (1) allows for reliable harvest of single-vessel flaps while minimizing fat necrosis, (2) decreases abdominal wall morbidity, and (3) improves breast and donor site esthetics.

METHODOLOGY

The investigators designed a retrospective case series. The study sample was derived from a population of patients presenting to the senior surgeon (SKK) for abdominal-based ABR in the setting of newly diagnosed breast cancer between August 2017 and January 2019. Subjects eligible for study inclusion were female, at least 18 years old, underwent ABR with preoperative computed tomographic angiography (CTA) imaging, and returned for at least 6 months of postoperative follow-up. Subjects were excluded from study enrollment if they were younger than 18 years or failed to return for follow-up. The primary outcome variables studied were flap success and rate of fat necrosis. Descriptive variables included demographic information, medical comorbidities, smoking status, and prior abdominal surgeries. Additional variables studied included various perioperative characteristics (eg, reconstruction type, perforator location, anesthesia details, concurrent procedures, anticoagulation regimen, and perforator/pedicle injury), postoperative characteristics (eg, pain regimen, antibiotic therapy, anticoagulation regimen, readmission, reoperation, length of stay, and length of follow-up), and postoperative complications (eg, wound-healing issues, arterial thrombosis, venous congestion, and operative revision). Descriptive statistics were computed for each study variable using StataSE 15.0 (College Station, TX).

Operative Technique

Operative technique included a 2-stage approach (Fig. 1). After mastectomy, the subjects underwent subcutaneous placement of tissue expanders and in situ selection of single-vessel DIEP flap based on CTA imaging. Perforator selection was based on a low, central position above the arcuate line with a short intramuscular course which not only allows for a low abdominal scar but also minimizes fascial dissection and subsequent myofascial insult and pain. Perforator dissection occurred through an infraumbilical “T” incision with ligation of all other perforators and the superficial system. The incisions were closed over bulb suction drain. Subjects then underwent tissue expander explant and single-vessel DIEP flap transfer through a minimal fascial incision at a second stage approximately 2 weeks thereafter, based on previous studies of vascular delay¹² (Fig. 2). The inferior epigastric pedicle was harvested with small fascial incisions through the use of a small lighted retractor (Invuity Inc, San Francisco,

CA) for pedicle dissection (Fig. 3). Fascial incisions were closed primarily without mesh reinforcement and 3-way anchoring stitches secured to the abdominal wall fascia maintain a low donor scar to optimize esthetics.

ERAS Protocol

The specific ERAS breast free flap protocol follows the general principles outlined by the ERAS society including preoperative hydration, nutrition optimization, narcotic-sparing analgesia, and early ambulation.¹³ Subjects are hydrated with Gatorade and are preloaded with ibuprofen and acetaminophen in anticipation of surgery the night before. Single-dose antibiotics, subcutaneous heparin, and sequential compression devices are applied before induction. Peripheral nerve blocks are performed in the pectoralis and serratus anterior musculature in addition to the transversus abdominis plane. Surgical incisions are preinfiltrated with a lidocaine and bupivacaine mixture. Continuous vecuronium infusions are maintained during flap harvest and dissection to allow for greater myofascial laxity during pedicle dissection. After stage 1, patients are maintained on a narcotic-sparing pain regimen of IV acetaminophen, ibuprofen/ketorolac, gabapentin, and breakthrough tramadol and admitted for a 23-hour stay. After stage 2, patients are continued on this pain regimen, advanced to a regular diet immediately without postoperative IV fluids or urinary catheterization, and encouraged to ambulate. Notably, inpatient stay is limited only by flap monitoring, with postoperative stay typically lasting 36–48 hours.

RESULTS

Demographics

One hundred thirty-five subjects underwent 215 single perforator DIEP flaps during the study period (Table 1). Mean age and body mass index were 52.1 years and 29.3 kg/m², respectively. The most common comorbidities were hypertension (27.2%), former tobacco use (19.1%), diabetes mellitus (10.3%), and thyroid disease (9.6%). Subjects (18.5%) had prior cesarean sections via Pfannenstiel incision. Subjects underwent neoadjuvant and adjuvant chemotherapy at rates of 22.2% and 25.9%, respectively. Subjects underwent prior and adjuvant radiation at rates of 10.5% and 26.9%, respectively. Subjects underwent prior and adjuvant hormonal therapy at rates of 4.4% and 33.0%, respectively.

Perioperative Characteristics

Subjects underwent delayed transfer of flaps approximately 18.2 days after their stage 1 procedures (Table 2). Subjects underwent unilateral and bilateral free flap reconstruction at rates of 40.7% and 59.3%, respectively. Hundred percent of subjects underwent delay of single-vessel DIEP flaps. Pedicle dissection was performed using a lighted retractor or similar method to reduce fascial incision. Average fascial length for flap harvest was 3.5 cm (range 1.3–6.0 cm). The selected perforator distance below the umbilicus on computed tomography imaging

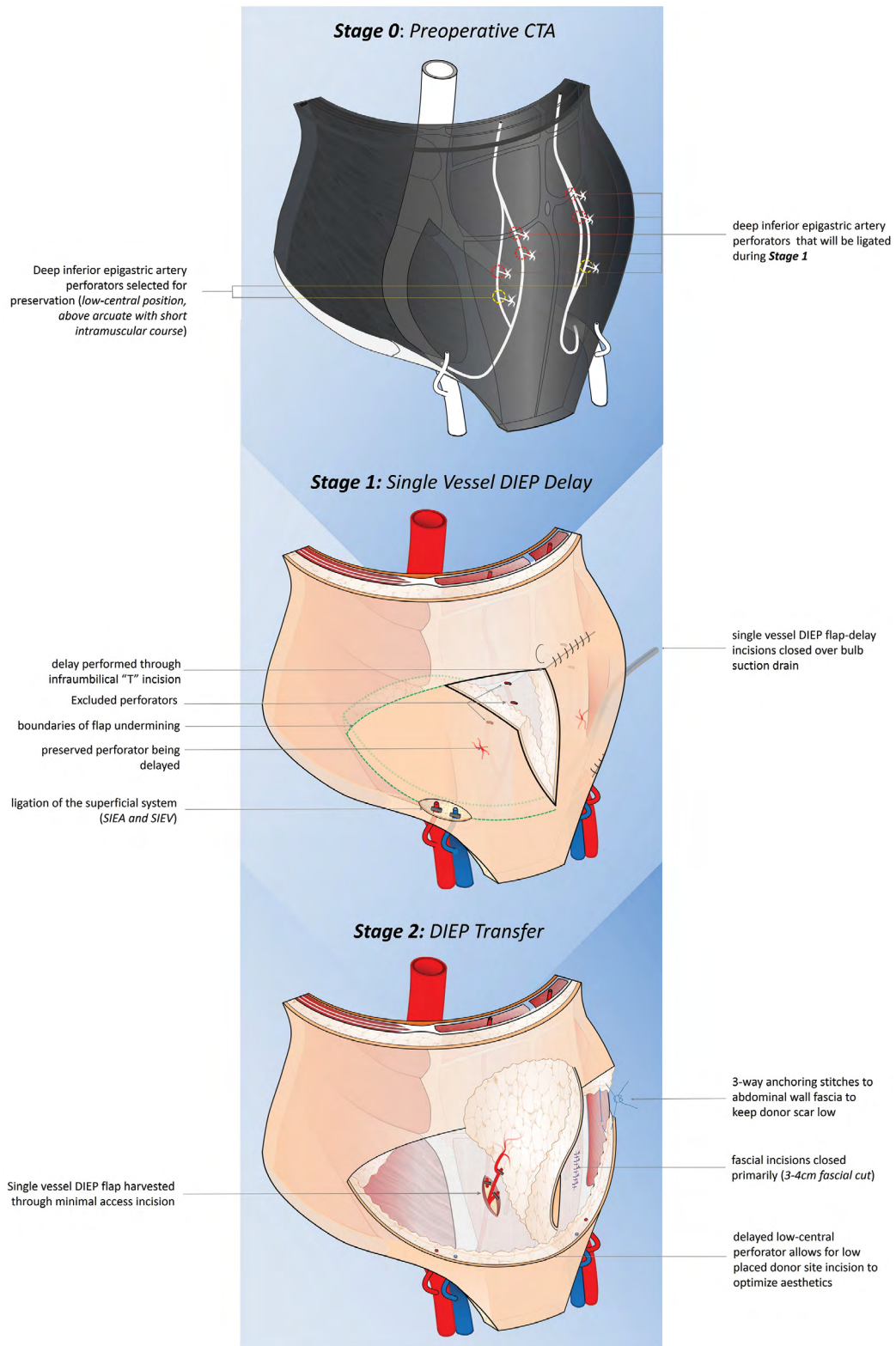


Fig. 1. Two-stage delayed DIEP harvest. Preoperative CTA imaging used to optimize single perforator selection in a low, central position with minimal intramuscular course. During stage 1, an infraumbilical "T" incision allows for in situ flap dissection, preservation of single perforator, and ligation of superficial system. During stage 2, the single perforator DIEP flap is delivered through a minimal 3–4-cm fascial incision for breast reconstruction.

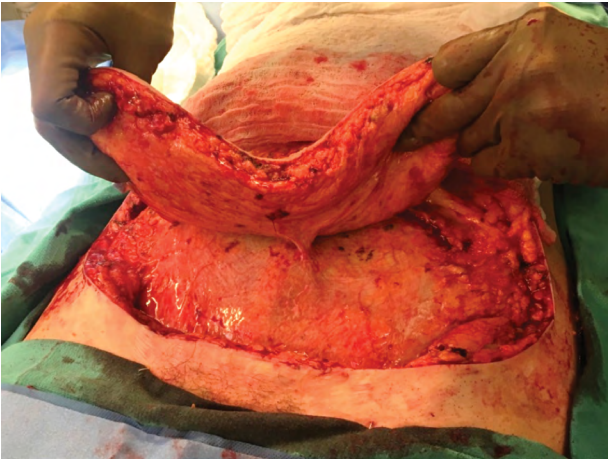


Fig. 2. Single-vessel DIEP can be reliably harvested through staged vascular delay. This subject underwent unilateral single-vessel DIEP reconstruction. During staged vascular delay, a low, central perforator was selected. Note the fibrofatty rind around the perforator, which must be dissected to prevent issues with kinking. The abdominal delay results in iatrogenic creation of a seroma cavity, which must be excised before abdominal closure to prevent postoperative seroma.

was 5.2 cm on average, whereas the selected perforated distance below the dominant, periumbilical perforator was 4.0 cm on average. Concurrent procedures included total abdominal hysterectomy and bilateral salpingo-oophorectomy (4.4%) and gastric wedge resection (0.7%). The majority of subjects underwent preoperative subcutaneous heparin chemoprophylaxis (88.2%), whereas 15 (11.1%) and 1 (0.7%) subjects required systemic intravenous heparin and localized tissue plasminogen activator for intraoperative arterial malperfusion. During perforator and pedicle harvest, inadvertent traction (0.9%), thermal (0.5%), and transection (1.9%) injuries occurred in 7 subjects requiring perforator to pedicle anastomosis. Two of these subjects (0.9%) experienced total flap loss. Average length of procedure was 263 and 446 minutes for unilateral and bilateral reconstructions, respectively.

Postoperative Care

Average length of stay following stage 2 transfer of flaps was 2.7 days (Table 3). Postoperative antibiotic duration

averaged 10.5 days with the majority of patients managed with first-generation cephalosporins (83.9%). The majority of subjects were postoperatively anticoagulated with subcutaneous heparin and aspirin 81 mg (80.0%) or aspirin 325 mg (14.8%). Non-narcotic pain regimens included intravenous and oral acetaminophen (97.0%), intravenous ketorolac and oral ibuprofen (95.6%), and gabapentin (74.8%). Two-thirds of subjects avoided narcotic pain medication entirely. Average length of follow-up was 234 days. Figure 4 depicts a subject at the time of preoperative evaluation, following completion of stage 1, and 2 weeks postoperatively after stage 2 transfer of flaps.

Postoperative Complications

Subjects underwent 20 (14.8%) readmissions and 26 (19.3%) reoperations in total (Table 4). There was 1 (0.5%) intraoperative and 1 (0.5%) postoperative total flap loss. Five subjects (2.3%) experienced partial flap loss due to venous congestion and/or debridement of fat necrosis. The operative breast revision rate following stage 1 and stage 2 was 3.0% and 8.9%, respectively. Approximately 14.9% of subjects developed mastectomy skin flap necrosis (MSFN) following mastectomy, which was subsequently debrided during stage 2 flap transfer, resulting in a postoperative MSFN rate of 2.3%. The fat necrosis rate following single-vessel DIEP as determined by clinical examination was 5.1%. The operative abdominal revision rate following stage 1 and stage 2 was 0.7% and 4.4%, respectively.

DISCUSSION

The history of ABR began with the pedicled TRAM flap popularized by Hartrampf et al and has now evolved into sophisticated perforator free flaps such as the DIEP flap. Although questions surrounding abdominal donor site morbidity in breast free flap reconstruction have been largely debunked through the use of muscle-sparing and perforator-based flaps,^{14,15} controversy surrounding blood supply remains. Examples of vascular delay in abdominal-based breast reconstruction parallel evolutionary refinements made to the TRAM flap with generally favorable outcomes.^{8-10,16} Yet, this mutual evolution seems to abruptly end with the description and widespread adoption of muscle-sparing and perforator free flaps, such as the DIEP flap. We hypothesized that 2-stage vascular delay

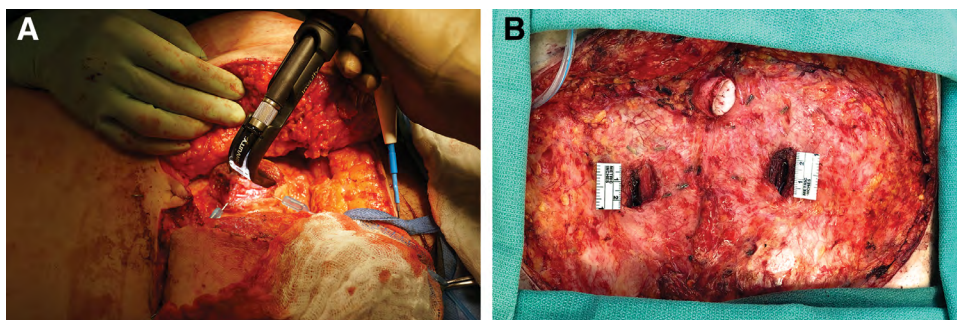


Fig. 3. Pedicle harvest through a minimally invasive technique. A, Lighted retractor dissection of DIEP pedicle under deep paralysis using IV vecuronium infusion. B, 2.5-cm incisions were created bilaterally through which the DIEP pedicle was dissected.

Table 1. Demographic Information

Demographics (n = 135)	
Age, y (mean ± SD)	52.1 ± 11.0
BMI, kg/m ² (mean ± SD)	29.3 ± 6.3
Race (n, %)	
White	95 (69.9)
African American	34 (25.0)
Asian	5 (3.7)
Others	2 (1.5)
Smoking (n, %)	
Never	101 (74.3)
Former	26 (19.1)
Current	9 (6.6)
Cardiovascular history (n, %)	
HTN	37 (27.2)
CAD	1 (0.7)
CHF	1 (0.7)
Arrhythmia	3 (2.2)
Endocrine history (n, %)	
Diabetes	14 (10.3)
Thyroid disease	13 (9.6)
Coagulopathy (n, %)	
DVT/PE	4 (3.0)
Prothrombotic	1 (0.7)
Autoimmune history (n, %)	
SLE	2 (1.5)
Prior abdominal surgeries (n, %)	
None	73 (53.7)
Pfannenstiel (Cesarean section)	30 (18.5)
Open appendectomy	6 (4.4)
Laparoscopic appendectomy	8 (5.9)
Open cholecystectomy	1 (0.7)
Laparoscopic cholecystectomy	10 (7.4)
Open hysterectomy	7 (5.2)
Laparoscopic/robotic hysterectomy	14 (10.3)
Preoperative anticoagulation use (n, %)	
Aspirin	2 (1.5)
Coumadin	0 (0.0)
Lovenox	0 (0.0)
Novel oral anticoagulant	3 (2.2)
Plavix	1 (0.7)
Corticosteroid use (n, %)	2 (1.5)
Chemotherapy (n, %)	
None	70 (51.9)
Neoadjuvant	30 (22.2)
Adjuvant	35 (25.9)
Radiotherapy (n, %)	
None	84 (62.7)
Prior	14 (10.5)
Adjuvant	36 (26.9)
Hormone therapy (n, %)	
None	84 (62.2)
Prior	6 (4.4)
Adjuvant	45 (33.0)

One hundred three subjects underwent 154 single perforator DIEP and 2 SIEA flaps during the study period.

BMI, body mass index; CAD, coronary artery disease; CHF, congestive heart failure; DVT/PE, deep vein thrombosis/pulmonary embolus; HTN, hypertension; SIEA, superficial inferior epigastric artery; SLE, systemic lupus erythematosus.

of the DIEP flap in breast reconstruction (1) allows for reliable harvest of single-vessel flaps with decreased rates of fat necrosis, (2) minimizes abdominal wall morbidity, and (3) improves breast and donor site esthetics.

The results of this study confirm the hypothesis that 2-stage vascular delay in DIEP free flap breast reconstruction allows for reliable harvest of single-vessel flaps with decreased rates of fat necrosis and acceptable rates of flap loss when compared with existing data. Single-vessel DIEP flap reconstruction using CTA imaging was performed in all 135 consecutive cases. Criteria for perforator selection included low, central position above the arcuate line and minimal intramuscular course (Fig. 1). During the first stage

Table 2. Perioperative Characteristics

Perioperative Characteristics (n = 135)	
Time between stages (d)	18.2 ± 15.5
Reconstruction type (n, %)	
Unilateral	55 (40.7)
Bilateral	80 (59.3)
Length of procedure, stage 2 (min)	372.0 ± 123.9
Unilateral reconstruction (n = 55)	262.8 ± 73.3
Bilateral reconstruction (n = 80)	446.1 ± 92.4
Wound class (n, %)	
Clean	134 (99.3)
Clean-contaminated	1 (0.7)
ASA class (n, %)	
II	110 (80.9)
III	25 (18.4)
Concurrent procedures, stage 2 (n, %)	
TAHBSO	6 (4.4)
Gastric wedge resection	1 (0.7)
Intraoperative anticoagulation (n, %)	
Subcutaneous heparin	119 (88.2)
Intravenous heparin	15 (11.1)
TPA	1 (0.7)
Perforator/pedicle injury, stage 2 (n = 215) (n, %)	
None	151 (96.7)
Traction	2 (0.9)
Thermal	1 (0.5)
Transection	4 (1.9)
Perforator distance from umbilicus, cm (mean, SD)	5.2 ± 1.9
Distance from dominant perforator, cm (mean, SD)	4.0 ± 1.6
Fascial incision, cm (mean, range)	3.5 (1.3, 6.0)

TAHBSO, total abdominal hysterectomy and bilateral salpingo-oophorectomy; TPA, tissue plasminogen activator.

Table 3. Postoperative Care

Postoperative Care (n = 135)	
Length of stay, stage 2 (d)	2.7 ± 1.2
2	79 (59.0)
3	33 (24.6)
4	18 (13.4)
5	1 (0.8)
6	2 (1.5)
12	1 (0.8)
Length of follow-up (d)	233.7 ± 158.5
Antibiotic duration, stage 1 (d)	10.5 ± 5.0
Antibiotic type (n, %)	
Cephalexin	104 (83.9)
Clindamycin	17 (13.7)
Levofloxacin	2 (1.6)
TMP/SMX	1 (0.8)
Anticoagulation regimen (n, %)	
Subcutaneous heparin	128 (94.8)
Aspirin 81 mg	108 (80.0)
Aspirin 325 mg	20 (14.8)
Intravenous heparin	9 (6.7)
Enoxaparin	3 (2.2)
Pain regimen (n, %)	
Acetaminophen	131 (97.0)
Ibuprofen/ketorolac	129 (95.6)
Gabapentin	101 (74.8)
Diazepam	9 (6.7)
Tramadol	46 (34.1)
Oxycodone	27 (20.0)
Morphine	1 (0.7)
Hydromorphone	9 (6.7)

Sixty-six percent of subjects avoided narcotics entirely.

TMP/SMX, trimethoprim/sulfamethoxazole.

of the vascular delay, all other perforators including the “ideal” periumbilical perforators (ie, large caliber, palpable pulse) traditionally utilized for single-stage flap reconstruction and the superficial system are ligated. This results in selection of a “nonideal” perforator that is ideally centered over the flap and ideally located within the abdominal wall

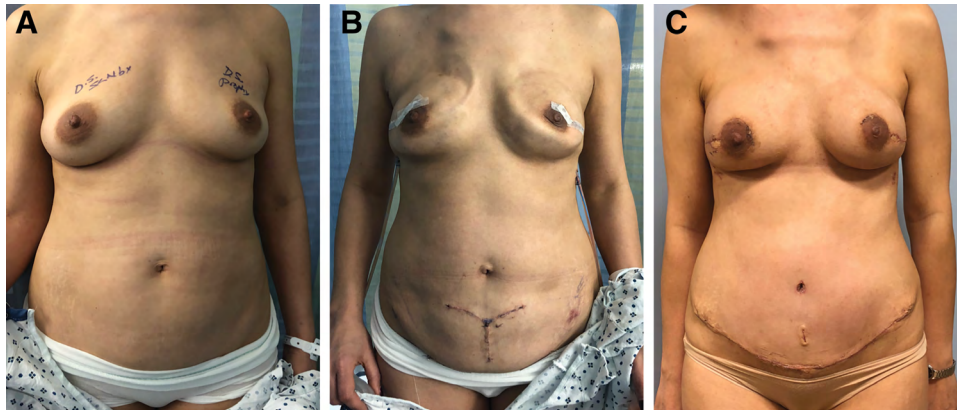


Fig. 4. Staged DIEP reconstruction with vascular delay improves abdominal esthetics. A, Preoperative AP view of subject undergoing bilateral nipple-sparing mastectomy with plan for the delay of bilateral single-vessel DIEP flaps. B, Following completion of stage 1, subject presents for the transfer of free flaps. Note the subcutaneous tissue expanders maintaining the breast envelope for eventual free flap placement as the infraumbilical “T” incision utilized to isolate the CTA-based low, centrally located perforators. C, The subject returns 2-week postoperatively after stage 2 transfer of free flaps. Note the low, esthetic placement of the abdominal donor site scar. AP, anteroposterior.

Table 4. Postoperative Complications

Complications (n, %)	
Readmission (n = 135)	20 (14.8)
Reoperation (n = 135)	26 (19.3)
Abdomen, stage 1	1 (0.7)
Abdomen, stage 2	6 (4.4)
Breast, stage 1	4 (3.0)
Breast, stage 2	12 (8.9)
Flap loss (n = 215)	
Total	2 (0.9)
Partial	5 (2.3)
Stage 1: breast (n = 215)	
Cellulitis	2 (0.9)
Abscess	1 (0.5)
Seroma	1 (0.5)
Hematoma	4 (1.9)
MSFN	32 (14.9)
Stage 2: breast (n = 215)	
Arterial thrombosis	1 (0.5)
Venous congestion	4 (1.9)
Cellulitis	4 (1.9)
Abscess	2 (0.9)
Seroma	3 (1.4)
Hematoma	1 (0.5)
Fat necrosis	11 (5.1)
Delayed healing	4 (1.9)
MSFN	5 (2.3)
Stage 1: abdomen (n = 135)	
Cellulitis	1 (0.7)
Abscess	1 (0.7)
Hematoma	2 (1.5)
Stage 2: abdomen (n = 135)	
Cellulitis	4 (3.0)
Seroma	8 (5.9)
Hematoma	1 (0.7)
Delayed healing	15 (11.1)

Flap loss rate was 1.9%. Reoperation rate was 19.4%. All 4 subjects with postoperative venous congestion or thrombosis eventually had partial flap loss.

(ie, minimal intramuscular course) for straightforward second-stage flap elevation. During the ensuing 2 weeks, relative tissue ischemia results in dilation of the selected perforator, which is readily apparent at the time of second-stage flap elevation. We have clinically observed submillimeter perforators and 2-mm deep inferior epigastric artery

pedicles dilating to twice their initial caliber at the time of staged flap harvest, indicative of pathophysiologic changes inherent to vascular delay^{17,18} (Fig. 5).

Staged DIEP reconstruction with vascular delay not only optimizes abdominal donor site esthetics but also optimizes breast esthetics (Fig. 6). Selection of a low, centrally located perforator allows for the donor site incision to be significantly lower than traditional single-stage periumbilical DIEP flap reconstruction (Figs. 7 and 8). Specifically, the delayed perforator was on average 4.0cm below the dominant, periumbilical perforator, which allows for a lower scar. This lowered donor site scar produces an abdominoplasty-like scar that can be reliably hidden in the underwear, when compared with the transabdominal scar associated with selection of a traditional high, periumbilical perforator. With regard to breast esthetics, temporary tissue expanders placed in the subcutaneous plane maintain the breast envelope until flap transfer occurs during second stage. In the setting of nipple-sparing mastectomies, staged reconstruction allows for recovery of any delayed healing noted after initial mastectomy that would not occur in a single-stage procedure due to weight and stretch constraints inherent to flap inset. In our series, we report only 1 partial nipple loss. Furthermore, 2-stage reconstruction allows for debridement of MSFN at the time of flap transfer, which would otherwise occur as a secondary reoperation following traditional single-stage reconstruction. We report an MSFN rate of 14.9% following initial mastectomy, which decreased to 2.3% after staged flap transfer.

Staged DIEP free flap reconstruction with vascular delay confirms our secondary hypothesis of lowered flap fat necrosis rates when compared with traditional single-stage procedures while minimizing abdominal wall donor site morbidity. Although we do not investigate the pathophysiologic changes associated with vascular delay, our low necrosis rate clinically corroborates Taylor et al's experimental findings of choke vessel dilation that links surrounding perforasomes that would otherwise undergo

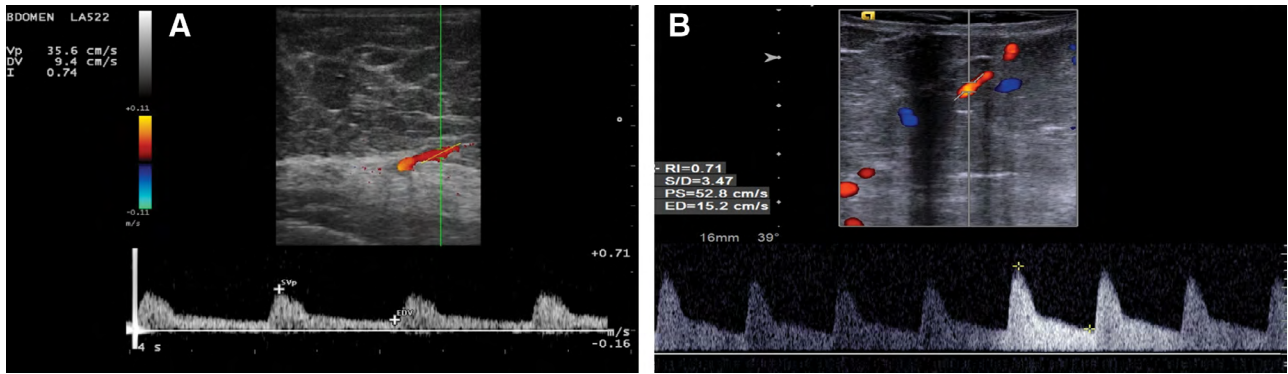


Fig. 5. Doppler US confirms increased flow following vascular delay. A, Preoperative Doppler US of “nonideal” CTA-based DIEP (decreased amplitude). B, Increased blood flow (increased amplitude) through delayed DIEP. US, ultrasound.

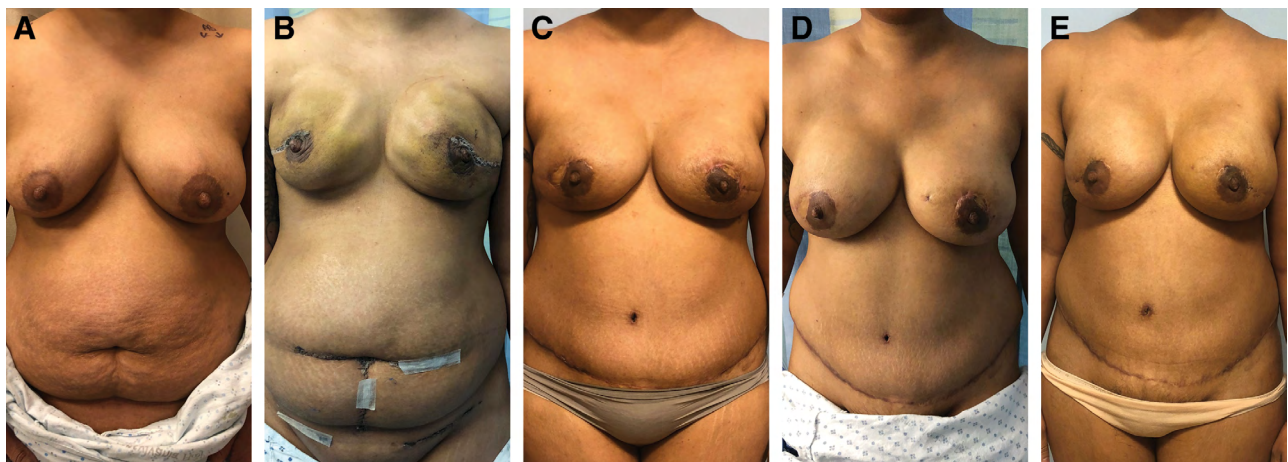


Fig. 6. Staged DIEP reconstruction with vascular delay. A, A 35-year subject with the history of BRCA1 mutation presenting with left breast cancer, electing for bilateral mastectomy with immediate autologous reconstruction. B, Following mastectomy, prepectoral tissue expander placement, and abdominal delay of single-vessel DIEP flaps via infraumbilical “T” incision. C, Following stage 2 transfer of DIEP flaps to chest. Note the monitoring skin paddles in the periareolar regions. D, Six months following staged reconstruction, the subject presented for laparoscopic TAHBSO. E, Seven-month postoperative follow-up after skin paddle excisions and superior pole fat grafting.

necrosis.¹⁹ Figure 5 demonstrates increased flow through the delayed perforator using Doppler ultrasonography. In our series, fat necrosis was postoperatively assessed through physical examination by the senior surgeon and microsurgical fellow (SKK and EJ). Importantly, 4 subjects whose postoperative course was complicated by venous congestion or thrombosis ultimately developed partial flap loss requiring debridement. Venous congestion etiologies in this series included intrinsic (ie, failure to ligate the SIEV during stage 1) and extrinsic flap issues (ie, pedicle kinking). Failure to initially ligate the SIEV represents a technical error that we corrected early in the series, whereas pedicle kinking remains a technical error inherent to DIEP flap reconstruction and not specific to the 2-stage technique described. We report a fat necrosis rate of 5.1% and operative total and partial flap loss rates of 0.9% and 2.3%, respectively, following staged reconstruction, which is significantly lower than published studies of traditional, single-stage DIEP free flap breast reconstruction.^{5,20} Khansa et al reported a DIEP flap fat necrosis rate of 14.4% in a recent 2013 meta-analysis.⁵ Prior attempts to delay pedicled TRAM flap breast reconstruction in

various high-risk patient populations (ie, obese, smokers, radiotherapy) have demonstrated lowered rates of partial flap loss or fat necrosis.^{9,10} Erdmann et al's experience with delay of unipedicled TRAM flap reconstruction led to a postoperative fat necrosis rate of 6.6%, which was significantly lower than the 12.3% fat necrosis rate in traditional pedicled TRAM and more comparable with the established 6.9% fat necrosis rate associated with free TRAM flap reconstruction.^{5,9} Yet, the benefits of vascular delay have not been applied to DIEP free flap reconstruction despite the inherent and unpredictable higher rates of fat necrosis when compared with free (muscle-sparing) TRAM flap reconstructions.^{21,22} These data substantiate the claim that vascular delay lowers rates of operative partial flap loss and fat necrosis in perforator-based (ie, DIEP) flaps.

In addition to decreased rates of fat necrosis, 2-stage DIEP reconstruction with vascular delay was performed using a minimally invasive fascial incision associated with less myofascial dissection, less pain, and less abdominal wall morbidity. Subjects underwent pedicle harvest through an average 3.5-cm (1.3–6 cm) fascial incision using a lighted retractor or similar fascial sparing method. There was no

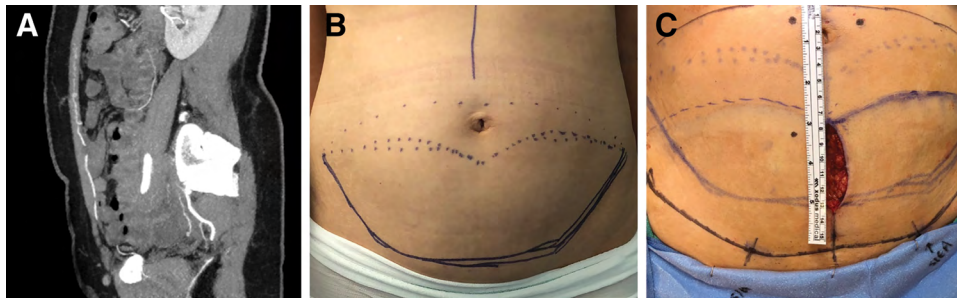


Fig. 7. DIEP delay improves abdominal donor site esthetics. A, Sagittal view of a CTA image illustrating a large, periumbilical DIEP traditionally used in single-stage flap reconstruction (white arrow). B, Staged delay allows for the inferior aspect of the donor site incision to be indistinguishable from a cosmetic abdominoplasty incision due to selection of a low perforator. (Solid purple line = inferior aspect of incision. Dotted purple line = superior aspect of incision). C, Superimposition of traditional single-stage DIEP flap incisions (solid purple) and 2-stage DIEP flap incisions (solid purple hash marks) demonstrating 3–4-cm scar lowering. Note the high, periumbilical perforators typically used in single-stage reconstruction (superior dots) vs the low perforator used in the 2-stage reconstruction with vascular delay (inferior dot).

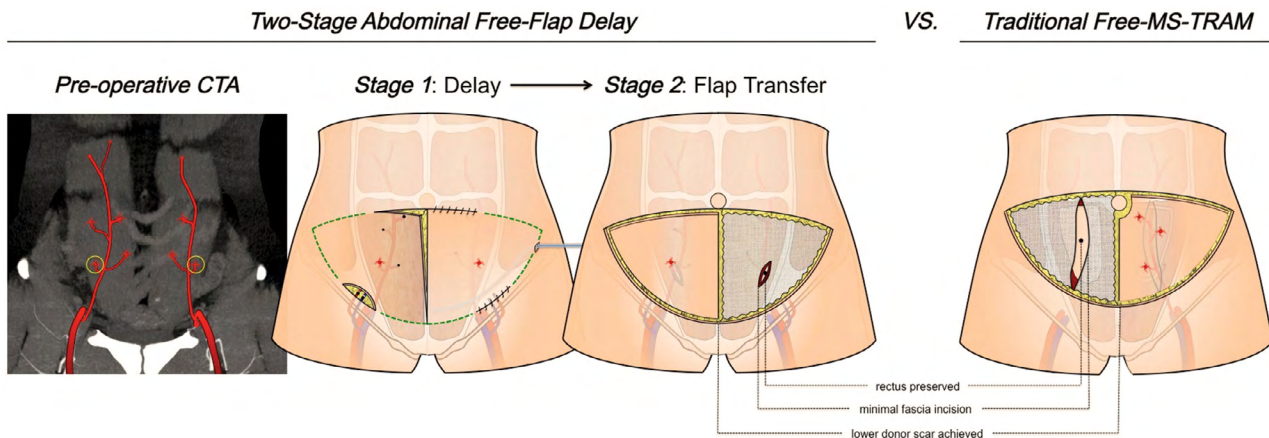


Fig. 8. Two-stage DIEP reconstruction with vascular delay using a minimal fascial incision with minimal myofascial dissection. A 3.5-cm fascial incision is created at second stage through which pedicle dissection occurs via a lighted retractor. Compared with muscle-sparing techniques (right), this allows for less myofascial dissection leading to less postoperative pain and decreased abdominal wall morbidity with preservation of rectus muscle and innervation.

need for mesh reinforcement of the abdominal wall after flap harvest and no instances of postoperative bulge or hernia within the 234-day average follow-up period. The most common operative abdominal complication following staged flap transfer was delayed healing (11.1%) most often requiring office debridement. This rate of delayed donor site healing is not unsurprising, however, given the overall patient demographics included in this series (ie, overweight, history of diabetes, smoking history, and need for adjuvant therapies).

In an era of cost containment and an opioid epidemic, 2-stage DIEP flap reconstruction with vascular delay was associated with favorable patient outcomes along an ERAS pathway. Average length of stay following stage 2 flap transfer was 2.7 days. Narcotic-free recovery occurred in approximately 66% of subjects, with 20% of subjects requiring narcotic therapy stronger than tramadol. Upon further examination, the majority of these subjects requiring narcotic medications postoperatively

presented with a preoperative opioid requirement or preoperative antidepressant or anxiolytic use. These findings corroborate successful implementation of ERAS pathways in microvascular breast reconstruction.^{23–25} In comparing these results with traditional microvascular breast postoperative pathways implemented at our institution, the average length of stay decreased by 1.5 days and the overall narcotic requirement decreased by 66%,^{26,27} although this is confounded by simultaneous adoption of an ERAS pathway along with a theoretically less morbid donor site procedure. The major difference noted between the experimental and historic cohorts related to overall flap loss. Reported flap loss following microvascular reconstruction at our institution is less than 1%, whereas the experimental cohort's total and partial flap loss rates following staged reconstruction were 0.9% and 2.3%, respectively, which is well within the accepted national range of 1%–4% following microvascular reconstruction.²⁷

Limitations

The context of this study's findings cannot be viewed without addressing several limitations. First, this study outlines a single-surgeon experience and consequently may be subject to implicit bias that may be better addressed in a multi-surgeon experience. Yet, this single-surgeon experience allows for consistency in technique and postoperative care in addition to standardized evaluation of outcomes. The readmission and reoperation rates of nearly 15% and 19%, respectively, are skewed toward the early experience with this novel technique. There is certainly a steep learning curve with 2-stage DIEP flap reconstruction with vascular delay that cannot be understated. The nuances of perforator dissection through a fibrofatty rind during stage 2 flap transfer led to early instances of pedicle kinking, venous congestion, and subsequent fat necrosis and partial flap loss. The rise of postoperative abdominal seromas following stage 2 flap transfer similarly required excision of the existing seroma capsule with and without quilting sutures to mitigate clinically relevant seroma formation. Nevertheless, these results honestly represent 215 consecutive single perforator DIEP flaps performed by a single surgeon utilizing a radically new approach to microvascular breast reconstruction for the ultimate benefit of the patient.

Fat necrosis rates were measured by clinical examination, which is more subjective and may represent an underreported value. We plan on a more complete assessment via ultrasound and ICG imaging in a future study. The focus of this study was to demonstrate flap loss and fat necrosis rates that were acceptable with 100% single perforator DIEP flaps in 135 consecutive subjects. Even if the reported fat necrosis rate were 2–3 times greater—albeit based on subjective assessment—this would still be in the range of reported fat necrosis rates for conventional DIEP flap reconstruction.

We do not provide a comparison cohort of subjects undergoing conventional, single-stage DIEP flap reconstruction as the senior surgeon exclusively performed muscle-sparing techniques before adoption of this staged technique to avoid increased rates of fat necrosis. Staged approaches to breast reconstruction (eg, expander-based, latissimus + expander, delayed–immediate autologous reconstruction) are inherently costlier than single-stage procedures (direct-to-implant, conventional autologous reconstruction), yet allow for control of variables and may enhance esthetic results (eg, expander reconstruction versus direct-to-implant, latissimus expander versus immediate implant). Are these procedures inherently less valuable because they are staged and therefore costlier approaches? We will subsequently examine cost/comparisons in future studies.

Finally, the reported readmission and reoperation rates do not typically affect timing of adjuvant therapy as these occurrences happen early in the postoperative period and are dealt with in a timely manner with adjuvant therapies in mind. One of the main reasons for delays in adjuvant therapy at our institution is MSFN. Our data suggest a skin flap necrosis rate of 15% following mastectomy. Using conventional single-stage DIEP flap reconstruction, we often wait weeks for breast wounds to heal before initiation of radiotherapy. This new approach has allowed us to minimize MSFN rates dramatically from 15% to 2% following

staged reconstruction, which helps to decrease delays in adjuvant treatment times. Furthermore, one of the bigger issues with adjuvant therapy is not time from mastectomy to adjuvant therapy but rather time from the plastic surgery appointment to adjuvant therapy. Our approach allows for the mastectomy to be performed with only a minimal procedure done by the plastic surgeon. This allows patients to receive their mastectomy several weeks earlier.

CONCLUSIONS

Two-stage DIEP breast flap reconstruction with vascular delay allows the surgeon to select the ideal perforator location and course. This flexibility allows for less myofascial dissection and better scar location. Perforator delay mitigates the trade-off of blood supply and abdominal wall morbidity in free flap breast reconstruction.

Suhail K. Kanchwala, MD

Division of Plastic Surgery
University of Pennsylvania
14th Floor, South Pavilion
3400 Civic Center Blvd
Philadelphia, PA 19104

E-mail: Suhail.Kanchwala@uphs.upenn.edu

ACKNOWLEDGMENT

The authors would like to acknowledge Ms. Iaina S. Moyer, PA-C, for her contributions in data collection.

REFERENCES

1. Hartrampf CR, Schefflan M, Black PW. Breast reconstruction with a transverse abdominal island flap. *Plast Reconstr Surg.* 1982;69:216–225. 10.1097/00006534-198202000-00006
2. Holmstrom H. The free abdominoplasty flap and its use in breast reconstruction. An experimental study and clinical case report. *Scand J Plast Reconstr Surg.* 1979;13:423–427.
3. Koshima I, Soeda S. Inferior epigastric artery skin flaps without rectus abdominis muscle. *Br J Plast Surg.* 1989;42:645–648.
4. Allen RJ, Treece P. Deep inferior epigastric perforator flap for breast reconstruction. *Ann Plast Surg.* 1994;32:32–38.
5. Khansa I, Momoh AO, Patel PP, et al. Fat necrosis in autologous abdomen-based breast reconstruction: a systematic review. *Plast Reconstr Surg.* 2013;131:443–452.
6. Zimble MS. Gaspare Tagliacozzi (1545-1599): Renaissance surgeon. *Arch Facial Plast Surg.* 2001;3:283–284.
7. Ghali S, Butler PE, Tepper OM, et al. Vascular delay revisited. *Plast Reconstr Surg.* 2007;119:1735–1744.
8. Codner MA, Bostwick J 3rd, Nahai F, et al. TRAM flap vascular delay for high-risk breast reconstruction. *Plast Reconstr Surg.* 1995;96:1615–1622.
9. Erdmann D, Sundin BM, Moquin KJ, et al. Delay in unipedicled TRAM flap reconstruction of the breast: a review of 76 consecutive cases. *Plast Reconstr Surg.* 2002;110:762–767.
10. Wang HT, Hartzell T, Olbrich KC, et al. Delay of transverse rectus abdominis myocutaneous flap reconstruction improves flap reliability in the obese patient. *Plast Reconstr Surg.* 2005;116:613–618; discussion 619.
11. Millard DR Jr. Breast reconstruction after a radical mastectomy. *Plast Reconstr Surg.* 1976;58:283–291.
12. Milton SH. The effects of “delay” on the survival of experimental pedicled skin flaps. *Br J Plast Surg.* 1969;22:244–252.
13. Beverly A, Kaye AD, Ljungqvist O, et al. Essential elements of multimodal analgesia in enhanced recovery after surgery (ERAS) guidelines. *Anesthesiol Clin.* 2017;35:e115–e143.

14. Selber JC, Fosnot J, Nelson J, et al. A prospective study comparing the functional impact of SIEA, DIEP, and muscle-sparing free TRAM flaps on the abdominal wall: part II. Bilateral reconstruction. *Plast Reconstr Surg*. 2010;126:1438–1453.
15. Selber JC, Nelson J, Fosnot J, et al. A prospective study comparing the functional impact of SIEA, DIEP, and muscle-sparing free TRAM flaps on the abdominal wall: part I. Unilateral reconstruction. *Plast Reconstr Surg*. 2010;126:1142–1153.
16. Christiano JG, Rosson GD. Clinical experience with the delay phenomenon in autologous breast reconstruction with the deep inferior epigastric artery perforator flap. *Microsurgery*. 2010;30:526–531.
17. Ribuffo D, Muratori L, Antoniadou K, et al. A hemodynamic approach to clinical results in the TRAM flap after selective delay. *Plast Reconstr Surg*. 1997;99:1706–1714.
18. Restifo RJ, Ahmed SS, Rosser J, et al. TRAM flap perforator ligation and the delay phenomenon: development of an endoscopic/laparoscopic delay procedure. *Plast Reconstr Surg*. 1998;101:1503–1511.
19. Taylor GI, Corlett RJ, Caddy CM, et al. An anatomic review of the delay phenomenon: II. clinical applications. *Plast Reconstr Surg*. 1992;89:408–416; discussion 417.
20. Man LX, Selber JC, Serletti JM. Abdominal wall following free TRAM or DIEP flap reconstruction: a meta-analysis and critical review. *Plast Reconstr Surg*. 2009;124:752–764.
21. Acarturk TO, Glaser DP, Newton ED. Reconstruction of difficult wounds with tissue-expanded free flaps. *Ann Plast Surg*. 2004;52:493–499; discussion 500.
22. Moghari A, Emami A, Sheen R, et al. Lower limb reconstruction in children using expanded free flaps. *Br J Plast Surg*. 1989;42:649–652.
23. Bartlett EL, Zavlin D, Friedman JD, et al. Enhanced recovery after surgery: the plastic surgery paradigm shift. *Aesthet Surg J*. 2018;38:676–685.
24. Batdorf NJ, Lemaine V, Lovely JK, et al. Enhanced recovery after surgery in microvascular breast reconstruction. *J Plast Reconstr Aesthet Surg*. 2015;68:395–402.
25. Davidge KM, Brown M, Morgan P, et al. Processes of care in autogenous breast reconstruction with pedicled TRAM flaps: expediting postoperative discharge in an ambulatory setting. *Plast Reconstr Surg*. 2013;132:339e–344e.
26. Carney MJ, Weissler JM, Tecce MG, et al. 5000 free flaps and counting: A 10-year review of a single academic institution's microsurgical development and outcomes. *Plast Reconstr Surg*. 2018;141:855–863.
27. Serletti JM, Fosnot J, Nelson JA, et al. Breast reconstruction after breast cancer. *Plast Reconstr Surg*. 2011;127:124e–135e.
28. Callegari PR, Taylor GI, Caddy CM, et al. An anatomic review of the delay phenomenon: I. Experimental studies. *Plast Reconstr Surg*. 1992;89:397–407; discussion 417.