

Original Article

Tibetan Medicated-Bath Therapy may Improve Adjuvant Arthritis in Rat

Huayue Chen¹, Shizuko Shoumura², Shoichi Emura³ and Hideo Isono⁴

¹Department of Anatomy, Gifu University Graduate School of Medicine, 1-1 Yanagido, Gifu, 501-1194, ²Chubu Gakuin University Faculty of Rehabilitation, Gifu 501-3993, ³Nursing Course, Gifu University School of Medicine, Gifu 501-1194 and ⁴Heisei College of Medical Technology, 182 Kurono, Gifu, 501-1131, Japan

Tibetan medicated-bath therapy has been applied to patients with rheumatoid arthritis for centuries. However, the detailed action mechanism of Tibetan medicated-bath therapy on the morphology and function of joints remains unknown. We designed our investigation to evaluate the efficacy of Tibetan medicated-bath therapy on adjuvant arthritis (AA) of rats in comparison with water-bath and dexamethasone administration. AA was induced by intradermal injection of *Mycobacterium butyricum* suspended in sterile mineral oil. The control animals were similarly injected with sterile vehicle. Eight days after injection, rats were treated with fresh-water bath, Tibetan medicated-bath (40°C, 15 min) or intramuscular injection with dexamethasone for 21 consecutive days after which we evaluated the severity of arthritis visually and microscopically and measured serum interleukin (IL)-6 and tumor necrosis factor (TNF)- α levels. While arthritis did not significantly change after water-bath treatment, the Tibetan medicated-bath and dexamethasone groups showed diminished joint swelling and alleviation of, inflammatory cell infiltration and the destruction of bone and cartilage. Serum IL-6 and TNF- α levels significantly decreased. Our results demonstrated that Tibetan medicated-bath therapy exerted a reliable effect on rat adjuvant arthritis, which may be involved in the inflammatory cytokines, IL-6 and TNF- α . Our data provide evidence for clinical use of Tibetan-medicated bath therapy for arthritis patients.

Keywords: adjuvant arthritis – interleukin-6 – morphology – rats – Tibetan medicated-bath therapy – tumor necrosis factor- α

Introduction

Rheumatoid arthritis (RA) is a chronic and systemic inflammatory disease of unknown etiology and is characterized by the accumulation and proliferation of inflammatory cells in the synovial lining, resulting in the formation of pannus tissue, which invades and destroys adjacent cartilage and bone. RA affects 0.5–1% of the world's population with more women being afflicted than men (1). Despite optimal use of currently available

anti-rheumatic agents, most RA patients live with chronic pain and severe functional decline because these therapies focus primarily on preventing joint inflammation and soft tissue swelling, but are not effective in preventing cartilage breakdown and joint destruction associated with RA. Recently, efforts have been focused on using the class of drugs called biologics for treating RA. Although these agents reduce inflammation and joint destruction, their long-term risks and benefits are not yet clear. Because of these and other limitations, the use of complementary and alternative medicine (CAM) therapies, such as acupuncture, medicinal herbs and bath therapy, is on the rise and according to reports 60–90% of dissatisfied arthritis patients are likely to seek CAM therapy (2–4).

For reprints and all correspondence: Huayue Chen, Department of Anatomy, Gifu University Graduate School of Medicine, 1-1 Yanagido, Gifu, 501-1194, Japan. Tel: +81-58-230-6295; Fax: +81-58-230-6298; E-mail: huayue@gifu-u.ac.jp

© 2007 The Author(s).

This is an Open Access article distributed under the terms of the Creative Commons Attribution Non-Commercial License (<http://creativecommons.org/licenses/by-nc/2.0/uk/>) which permits unrestricted non-commercial use, distribution, and reproduction in any medium, provided the original work is properly cited.

Balneotherapy or spa therapy emerged as an important European treatment modality during the 1800s (5) and is still practiced in many countries today. Records of clinical observations about the effects of spa therapy on human subjects have accumulated, including RA and osteoarthritis (5–7). Tibetan medicated-bath therapy has been applied to patients with RA and osteomyelitis since ancient times. The main components of Tibetan medicated-bath therapy are alpine plants, which grow in the Tibetan plateau and are considered beneficial for health. Clinical data suggest that Tibetan medicated-bath therapy has a positive effect on RA patients by improving immune function (8). However, the detailed mechanism of Tibetan medicated-bath therapy on the morphology and function of the joints remains unknown because of ethical restrictions on clinical research.

Adjuvant arthritis (AA) in rat has been widely used as an experimental model that shares some features with human RA, such as swelling, cartilage degradation and loss of joint function (9). We evaluated Tibetan medicated-bath therapy for AA in comparison with water-bath and administration of adrenal cortex hormone, dexamethasone.

Methods

Reagents and Drugs

Mycobacterium butyricum was obtained from Difco Laboratories (Detroit, MI, USA). Dexamethasone was purchased from Sigma (St Louis, MO, USA). ELISA kits for rat interleukin (IL)-6 and tumor necrosis factor (TNF)- α were obtained from Biosource International, Inc. (Camarillo, CA, USA). All other reagents were of biochemical grade. The dried extract powder of Tibetan medicine, Ganlu-Yaoyu-Keli was kindly provided by Arura Tibetan Medicine Group (Jinghai, China).

Rats and Experimental Design

We used 5-week-old female Sprague–Dawley rats (Japan SLC, Inc., Hamamatsu, Japan) with an average body weight of 157.4 g. Rats were maintained under conventional condition with free access to tap water and commercial diet (CE-2, CLEA Japan). All experiments were undertaken in accordance with the guidelines for care and use of laboratory animals, Gifu University Graduate School of Medicine.

Rats were randomly divided into five groups of eight animals each: control (C), adjuvant arthritis (AA), AA and water bath (W), AA and Tibetan medicated-bath (T) and AA and dexamethasone (D) groups. AA was induced by a single intradermal injection of 25 mg kg⁻¹ heat-inactivated *M. butyricum* suspended in sterile mineral oil,

at the base of the tail. Control animals were similarly injected with sterile vehicle.

Eight days after the injection, animals of D group were injected with dexamethasone of 0.5 mg kg⁻¹, intramuscularly once a day for 21 consecutive days. Rats of W and T groups underwent successive bath therapy at 40°C for 15 min, once a day for 21 consecutive days. The bathtub was constant in temperature with the size of 40 × 25 × 10 cm. The lower half of the rat was immersed into fresh warm water (W) or water containing Tibetan medicine (T). For the Tibetan medicated-bath, 2.5 g of Ganlu-Yaoyu-Keli, dry powdered Tibetan medicine was dissolved in 10 l of fresh warm water.

Visual Evaluation of Arthritis Severity

During the experimental period, body weight was regularly measured by digital balance after adjuvant injection. Average visual arthritis scores, indicating the severity of arthritis, were assigned to every joint by a single observer blinded to the group of animals as described previously (10). Rats were scored for arthritis using the following visual scoring system: grade 0, no swelling or erythema; grade 1, mild swelling and erythema or digit inflammation; grade 2, moderate swelling and erythema confined distal to the mid-paw; grade 3, more pronounced swelling and erythema with extension to the ankle; grade 4, severe swelling, erythema and joint rigidity of the ankle, foot and digits. Each limb was graded with a score of 0–4, with a maximum possible score of 16 for each individual rat.

IL-6 and TNF- α levels in Rat Serum

All animals were sacrificed under Nembutal anesthesia on the 28th day after adjuvant injection. The blood samples were collected in sterile tubes by cardiac puncture and centrifuged. The serum IL-6 and TNF- α levels were measured using ELISA kits specific for rat IL-6 and TNF- α .

Histopathological Examination of Joints

Hind limbs were removed and immersed in 10% neutral formalin solution overnight. The specimens were decalcified in 10% EDTA solution for 3 weeks. After decalcification, the specimens were dehydrated and embedded in paraffin. Sections of 6 μ m were stained with hematoxylin and eosin, and observed with a light microscope, evaluated for synovitis, pannus formation and bone and/or cartilage destruction based on a previously described scoring system: grade 0, normal; grade 1, mild inflammation, mild hyperplasia of the synovial lining layer, mild cartilage destruction without bone erosion; grade 2–4, increasing degrees of inflammatory cell infiltrates, synovial lining

hyperplasia and pannus formation and cartilage and bone destruction (10).

Some legs were processed for scanning electron microscopy (SEM). Soft tissues were removed from the bones by immersion in 0.5% papain solution at 37°C for 3 days. Residual debris was washed off using 5% sodium hypochlorite. After washing with distilled water, the specimens were dehydrated with ethanol and critical-point dried, mounted on stubs and coated with gold/palladium using an ion sputter. The distal epiphyses of the fibula-tibia complex were examined with a Hitachi S-3500 N scanning electron microscope.

Statistics

All values are expressed as means \pm standard errors. Statistical analysis was done using StatView J-4.5 (Abacus Concepts). Significance of the results was determined by analysis of variance (ANOVA) and Fisher's Protected Least Significant Difference test. A P -value <0.05 was considered statistically significant.

Results

Evaluation of Body Weight and Arthritis Score

To evaluate the arthritic progression of adjuvant-induced arthritis, body weight and the arthritis score were exploited as apparent indicators of arthritis. It is known that redness and swelling of the joints and body weight loss usually appear at the onset of arthritis. We found that while the body weight of control rats increased steadily during the experimental period, the AA rats showed significantly lowered body weight from day 12 after adjuvant injection (Fig. 1). From the 16th day after adjuvant injection, the body weight of T and D groups was significantly higher than that of AA and W groups (Fig. 1). The redness and swelling of the joints appeared around day 12 and peaked on day 24 after adjuvant injection. The mean arthritis score of AA and W groups began to increase around 12th day and reached 12 from day 20 to 28 (Fig. 2). The arthritis score for the D group was significantly lower than that of AA and W groups after day 16. From day 20, the arthritis score of the T group was significantly below that of AA and W groups (Fig. 2).

IL-6 and TNF- α levels in Rat Serum

IL-6 and TNF- α levels in rat serum are shown in Figs 3 and 4. The levels in the control animals were 11 and 14 pg ml⁻¹ while the serum IL-6 level increased to 36 pg ml⁻¹ and the serum TNF- α level rose to 72 pg ml⁻¹ in the AA group. In the D group, the levels decreased to those of the control. The serum levels of the T group

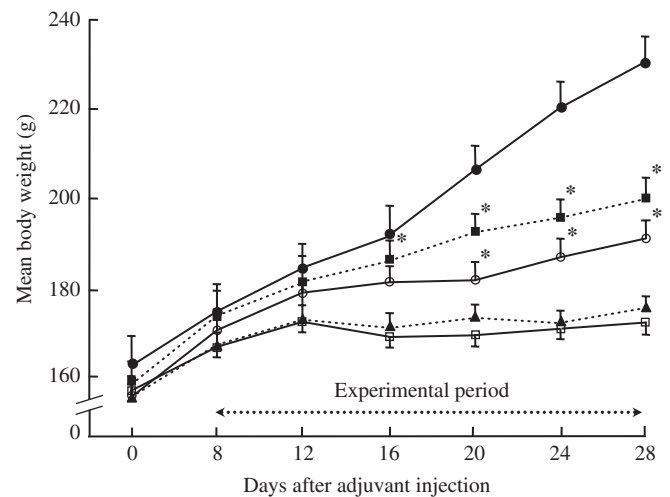


Figure 1. Changes in body weight of rats. Normal control (closed circles), adjuvant arthritis (open squares), adjuvant arthritis with water bath (closed triangles), adjuvant arthritis with Tibetan medicated bath (open circles), adjuvant arthritis with dexamethasone (closed squares). Each point represents the mean \pm SE. * $P < 0.05$, significant difference from the adjuvant arthritis group at the respective time.

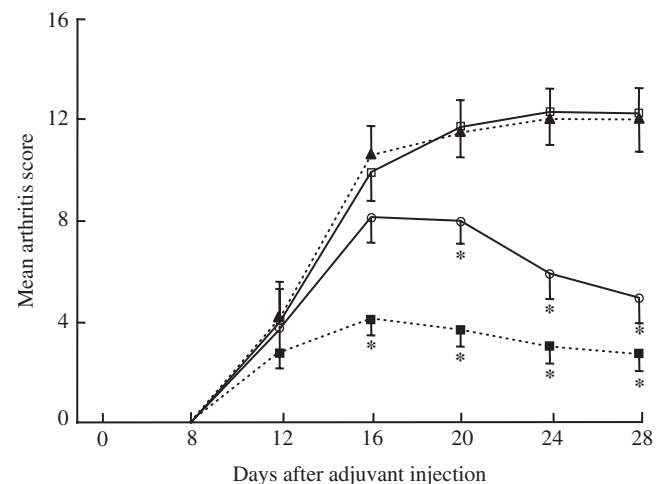


Figure 2. Changes in mean arthritis score of rats. Adjuvant arthritis (open squares), adjuvant arthritis with water bath (closed triangles), adjuvant arthritis with Tibetan medicated bath (open circles), adjuvant arthritis with dexamethasone (closed squares). Each point represents the mean \pm SE. * $P < 0.05$, significant difference from the adjuvant arthritis group at the respective time.

decreased by 28 and 24% ($P < 0.05$), in comparison with the AA group (Figs 3 and 4).

Histopathological Examination of Joints

In the AA and W groups, LM revealed severe hyperplasia of the synovial lining cells, many inflammatory cells infiltrated into the synovial membranes, accompanied by the destruction of articular cartilage and bone. In D and T groups, mild to moderate hyperplasia of the synovial lining cells and the infiltration

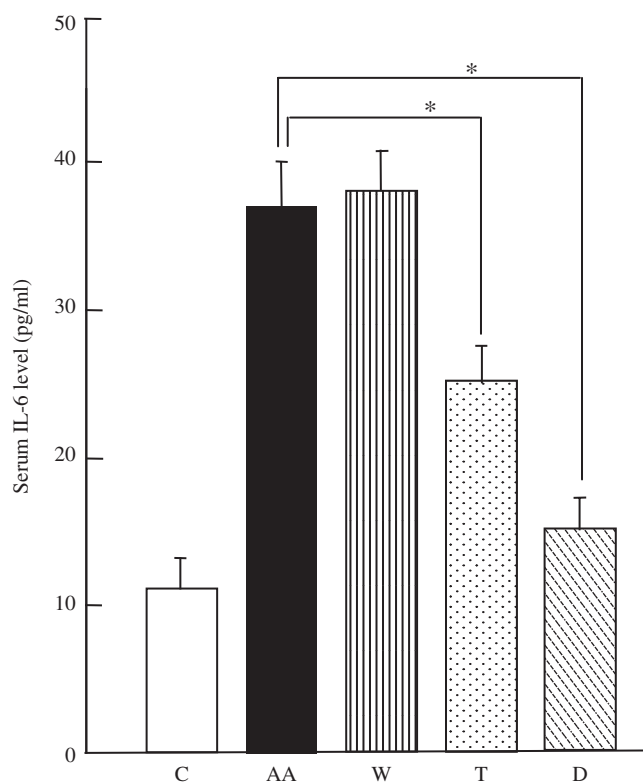


Figure 3. Changes of serum IL-6 level. Rats were divided into five groups, control (C), adjuvant arthritis (AA), adjuvant arthritis with water bath (W), adjuvant arthritis with Tibetan medicated bath (T), adjuvant arthritis with dexamethasone (D), each having eight rats. *Significant difference ($P < 0.05$) when compared with the adjuvant arthritis group.

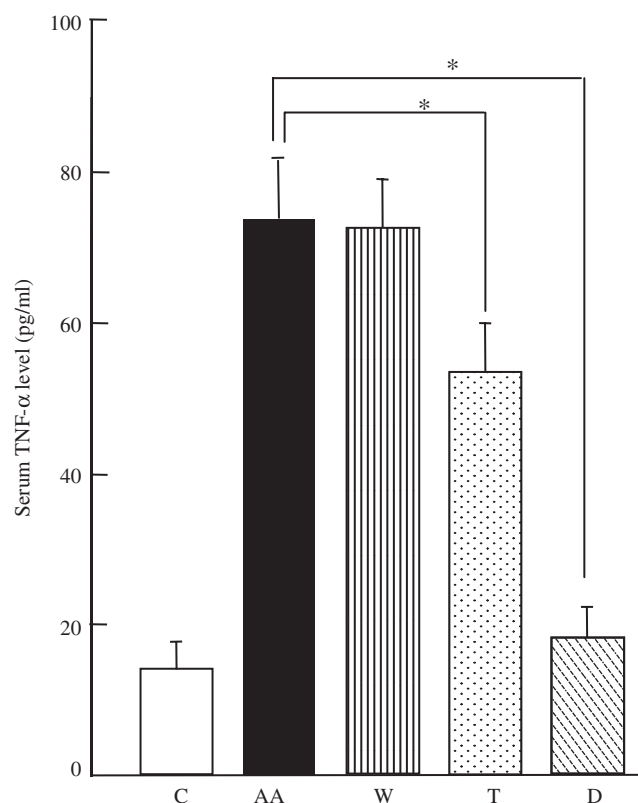


Figure 4. Changes of serum TNF- α level. Rats were divided into five groups, control (C), adjuvant arthritis (AA), adjuvant arthritis with water bath (W), adjuvant arthritis with Tibetan medicated bath (T), adjuvant arthritis with dexamethasone (D), each having eight rats. *Significant difference ($P < 0.05$) when compared with the adjuvant arthritis group.

of inflammatory cells into the synovial membranes were observed, with no marked destruction of the articular joint or bone erosion (Fig. 5). Compared with AA and W groups, the inflammatory cells and the synovial lining cells were reduced in D and T groups (Fig. 5). SEM showed that the surfaces of the distal epiphyses of tibia and fibula in the control rats were smooth. Rough surfaces of the distal epiphyses of the tibia and fibula indicated the occurrence of the bone destruction and abnormal bone (osteophyte) formation were observed in the synovia of the ankle joints of AA and W groups (Fig. 6), while in D and T groups, there was little bone destruction or osteophyte formation at the distal epiphyses of the tibia and fibula (Fig. 6). Histopathological evaluation demonstrated that dexamethasone or Tibetan medicated-bath therapy resulted in statistically significant reductions in synovitis, pannus and erosion scores in AA rats (Fig. 7).

Discussion

We found that after adjuvant injection, the ankle joints of both sides showed remarkable swelling, many

inflammatory cells infiltrated into the synovial membranes, articular cartilage and bone were destroyed and abnormal bone formation was evident. Serum IL-6 and TNF- α levels increased significantly. In the water-bath group, we did not find any significant change in the arthritis. The Tibetan medicated-bath and dexamethasone groups showed diminished swelling of ankle joints and alleviation of the infiltration of inflammatory cells and cartilage destruction, demonstrating that Tibetan medicated-bath therapy was beneficial for AA rats and could therefore be considered as a useful treatment for arthritis.

Although the role of balneotherapy has been subject to much debate, it has been applied to patients with various rheumatic conditions since ancient times. Reports of patients with active and widespread RA, treated at the Dead Sea area with hot sulfur baths, mud packs or combination of bath, showed statistically significant improvements for a period of up to 3 months (11). Another study showed that Dead Sea water was effective in reducing objective and subjective parameters of RA activity and severity (12). The mechanisms by which immersion in spa water or mud pack therapy affect inflammatory and non-inflammatory joint diseases are

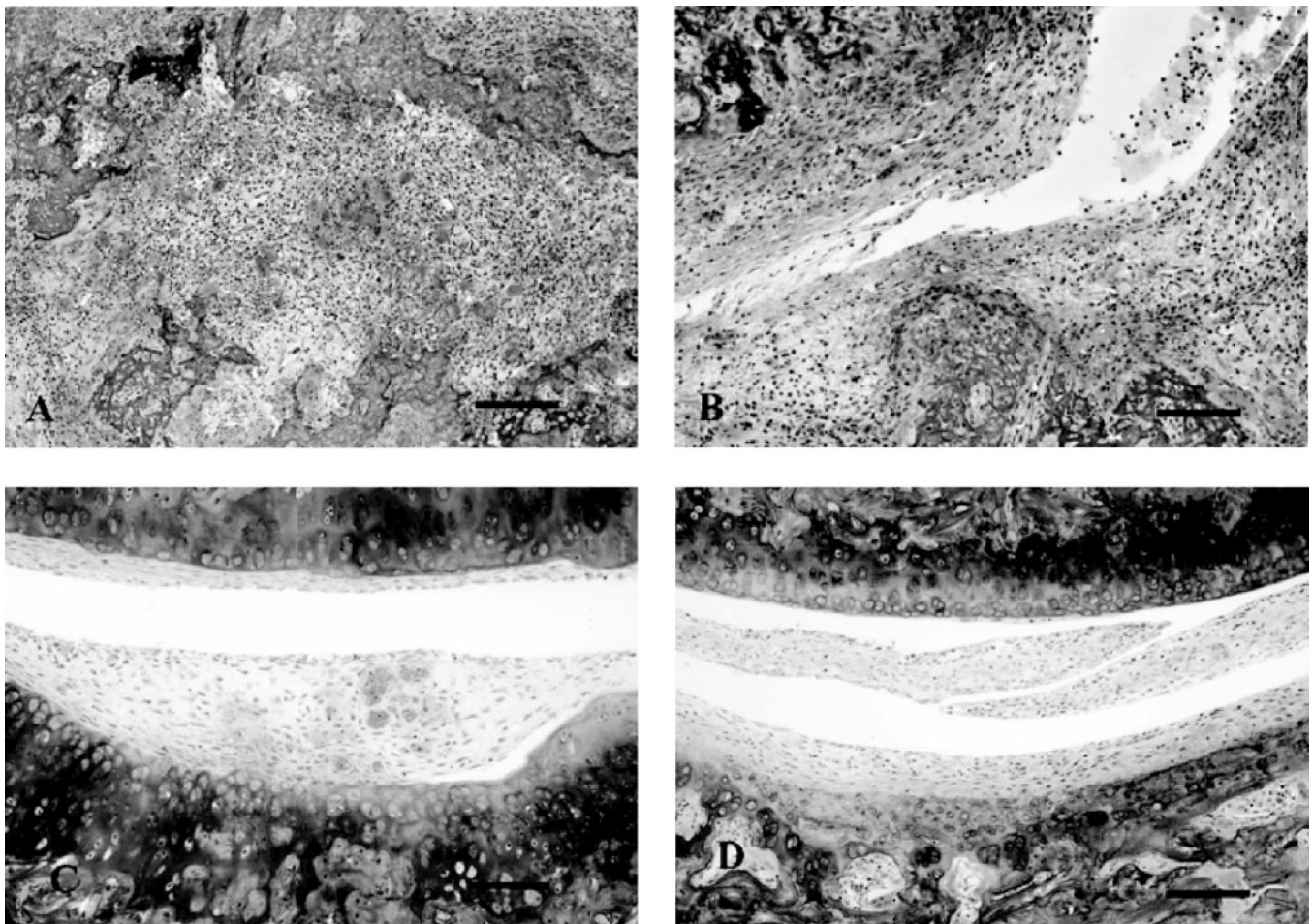


Figure 5. Representative light micrographs of rat ankle joints. Infiltration of many inflammatory cells and destruction of articular cartilages are present in (A) adjuvant arthritis and (B) adjuvant arthritis with water-bath rats. No marked cartilage erosion is observed in (C) adjuvant arthritis with Tibetan medicated bath and (D) adjuvant arthritis with dexamethasone rats. Bar=0.1 mm. Magnification, $\times 100$.

not fully understood. It has been shown that muscle-tone, joint mobility and pain intensity are influenced by hydromechanical and thermal stimuli. O'Hare *et al.* (7) showed that 2 h of immersion in spa water at a temperature of 35°C could induce significant diuresis and natriuresis in normal subjects, which may constitute part of the scientific rationale for spa treatment for various diseases. When analyzing rat spleen cellular composition after water-bath of 36–37°C, Garunova and Aminova (13) found that the number of plasma cells increased in the structural components of the spleen, which may indicate the activation of humoral immunity. We, however, did not find any significant changes in arthritis or serum cytokine levels after water-bath treatment and propose that 40°C warm water-bath does not improve arthritic symptoms.

Recent reports of mud-baths on rat AA have shown that after mud-bath application improved arthritis and lowered increased serum IL-1 β and TNF- α levels. This result suggests mud-baths have an anti-inflammatory effect on AA in rats via the down-regulation of IL-1 β and TNF- α (14).

Tibetan medicated-bath therapy has been known to relieve symptoms of RA for centuries and is widely used in Tibet. However, the reported scientific evidence for its efficacy is poor and the pharmacological mechanism remains unidentified. The main components of Tibetan medicine are *Rhododendron anthopogonoides Maxim.*, *Myricaria germanica* (L.) Desv., *Artemisia sieversiana Ehrhart ex Willd.*, *Rhamnus parvifolia Bunge*, *Sabina chinensis* (L.) Antoine and *Ephedra sinica*. Almost all of these plants are native to the Tibetan plateau. They grow in a special environment, with low oxygen, strong ultraviolet light and low temperatures and are considered to be effective for RA. Clinical investigations have reported that the rheumatoid factor titer of RA patients, who underwent Tibetan medicated-bath, is markedly lower. It was also demonstrated that Tibetan medicated-bath had an immunomodulating effect on RA patients through increasing CD8 cells and decreasing CD4 cells (8). No reports have elucidated the action mechanism of Tibetan medicated-bath therapy on arthritis.

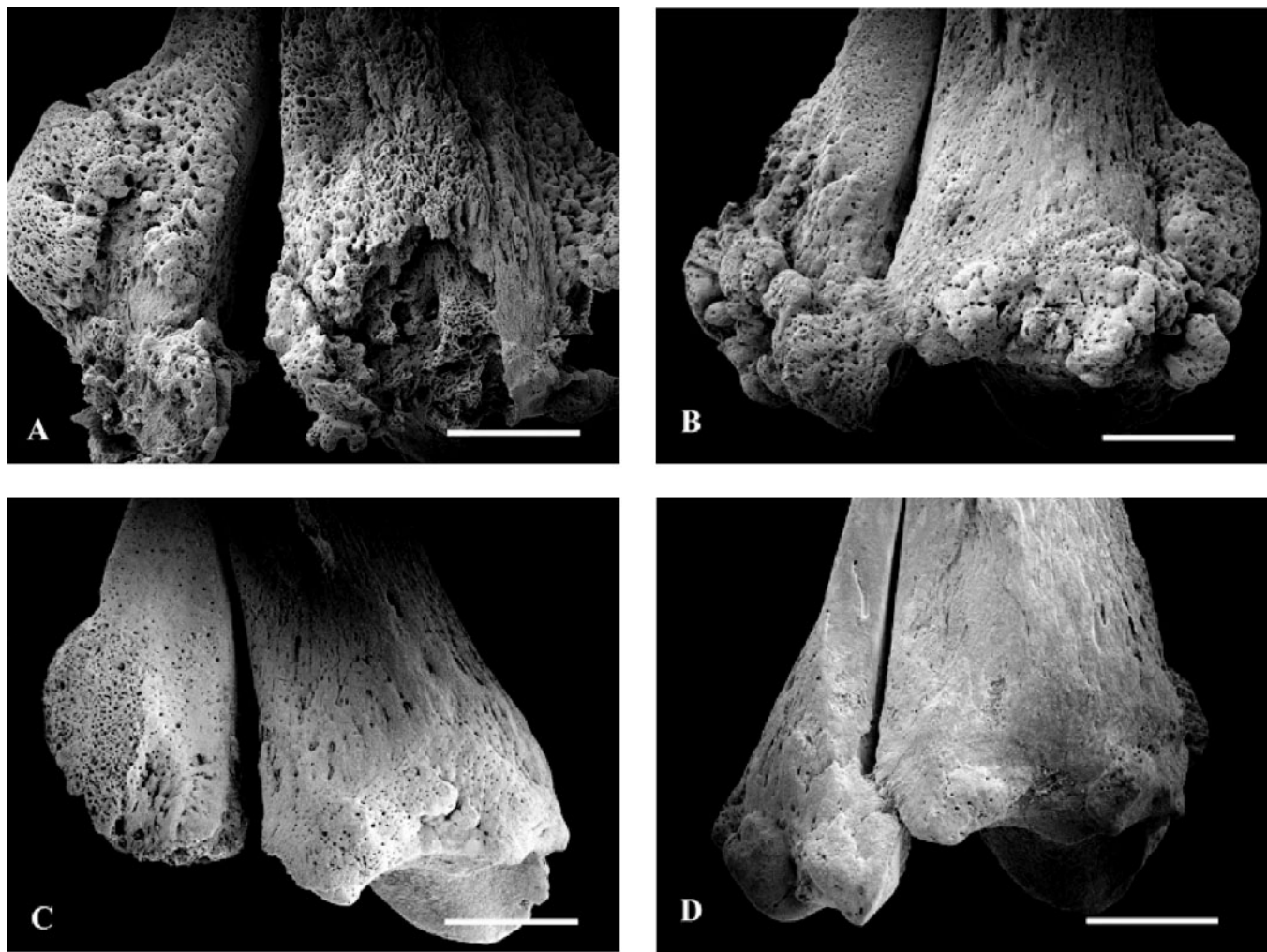


Figure 6. Representative scanning electron micrographs of rat distal epiphyses of tibia and fibula. Apparent bone destruction and osteophyte formation are observed in (A) adjuvant arthritis and (B) adjuvant arthritis with water-bath rats. There is slight bone destruction or osteophyte formation in (C) adjuvant arthritis with Tibetan medicated bath and (D) adjuvant arthritis with dexamethasone rats. Bar = 2 mm. Magnification, $\times 9$.

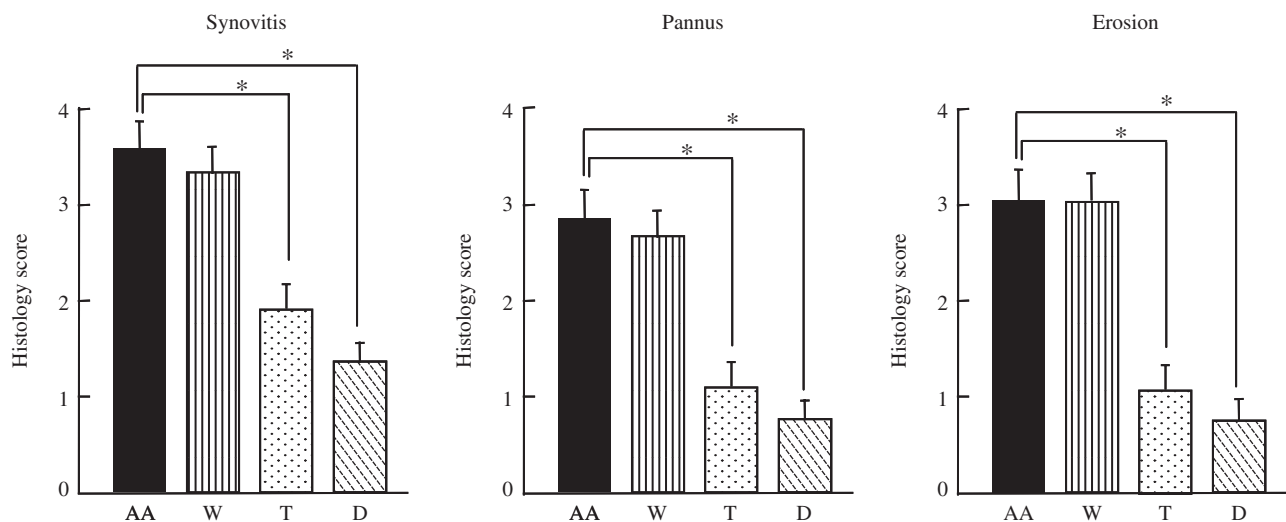


Figure 7. Quantitation of histopathological analysis of synovitis, pannus and erosion of bone and cartilage. Rats were divided into five groups, control (C), adjuvant arthritis (AA), adjuvant arthritis with water bath (W), adjuvant arthritis with Tibetan medicated bath (T), adjuvant arthritis with dexamethasone (D), each having eight rats. *Significant difference ($P < 0.05$) when compared with the adjuvant arthritis group.

We found that increased IL-6 and TNF- α levels in AA rats significantly decreased after Tibetan medicated-bath therapy, as seen in dexamethasone-treated animals. Previous studies revealed key roles for inflammatory cytokines, such as IL-6 and TNF- α , in the pathogenesis of RA (15). Elevated levels of IL-6 and TNF- α were found both in serum and synovial fluid of RA patients (16). It has been suggested that those inflammatory cytokines are produced through continuous activation of T cells and interaction of activated T cells and monocytes/macrophages in RA. Moreover, anti-IL-6 and anti-TNF have been reported to be effective in the treatment of RA (17). It is conceivable that IL-6 and TNF- α possess an important function for arthritis at the level of destroying joints at local inflammation sites and we consider that IL-6 and TNF- α may play an important part in the pharmacological mechanism of Tibetan medicated-bath therapy for adjuvant arthritis. Although IL-6 and TNF- α play a crucial role in the pathogenesis of arthritis, the inhibition of pro-inflammatory cytokines is probably only one of the complex action mechanisms of balneotherapy and further study is needed to clarify the action mechanism of Tibetan medicated-bath therapy on articular inflammatory processes. Clinically, controlled trials are mandatory to test the efficacy of Tibetan medicated-bath therapy in RA patients.

References

1. Firestein GS. Evolving concepts of rheumatoid arthritis. *Nature (London)* 2003;423:356–61.
2. Yim YK, Lee H, Hong KE, Kim YI, Lee BR, Son CG, et al. Electro-acupuncture at acupoint ST36 reduces inflammation and regulates immune activity in collagen-induced arthritic mice. *Evid Based Complement Alternat Med* 2007;4:51–7.
3. Engel LW, Straus SE. Development of therapeutics: opportunities within complementary and alternative medicine. *Nat Rev Drug Discov* 2002;1:229–37.
4. Ahmed S, Anuntiyo J, Malemud CJ, Haqqi TM. Biological basis for the use of botanicals in osteoarthritis and rheumatoid arthritis: a review. *Evid Based Complement Alternat Med* 2005;2:301–8.
5. Matz H, Orion E, Wolf R. Balneotherapy in dermatology. *Dermatol Ther* 2003;16:132–40.
6. Elkayam O, Wigler I, Tishler M, Rosenblum I, Caspi D, Segal R, et al. Effect of spa therapy in Tiberias on patients with rheumatoid arthritis and osteoarthritis. *J Rheumatol* 1991;18:1799–803.
7. O'Hare JP, Heywood A, Summerhayes C, Lunn G, Evans JM, Walters G, et al. Observations on the effects of immersion in bath spa water. *Bri Med J (Clin Res Ed)* 1985;291:21–8.
8. Zhao SL, Geng PL, Sang J. Immune function of rheumatoid arthritis treated by medicated-bath therapy in Tibetan medicine. *Zhongguo Zhong Xi Yi Jie He Za Zhi* 1993;13:452–3.
9. Jacobson PB, Morgan SJ, Wilcox DM, Nguyen P, Ratajczak CA, Carlson RP, et al. A new spin on an old model: In vivo evaluation of disease progression by magnetic resonance imaging with respect to standard inflammatory parameters and histopathology in the adjuvant arthritic rat. *Arthritis Rheum* 1999;42:2060–73.
10. Paniagua RT, Sharpe O, Ho PP, Chan SM, Chang A, Higgins JP, et al. Selective tyrosine kinase inhibition by imatinib mesylate for the treatment of autoimmune arthritis. *J Clin Invest* 2006;116:2633–42.
11. Sukenik S, Buskila D, Neumann L, Kleiner-Baumgarten A, Zimlichman S, Horowitz J. Sulphur bath and mud pack treatment for rheumatoid arthritis at the Dead Sea area. *Ann Rheum Dis* 1990;49:99–102.
12. Sukenik S, Neumann L, Buskila D, Kleiner-Baumgarten A, Zimlichman S, Horowitz J. Dead Sea bath salts for the treatment of rheumatoid arthritis. *Clin Exp Rheumatol* 1990;8:353–7.
13. Garunova KA, Aminova GG. Rat spleen cellular composition after water baths. *Morfologiya* 2004;125:55–8.
14. Cozzi F, Carrara M, Sfriso P, Todesco S, Cima L. Anti-inflammatory effect of mud-bath applications on adjuvant arthritis in rats. *Clin Exp Rheumatol* 2004;22:763–6.
15. Magari K, Miyata S, Ohkubo Y, Mutoh S. Inflammatory cytokine levels in paw tissues during development of rat collagen-induced arthritis: Effect of FK506, an inhibitor of T cell activation. *Inflamm Res* 2004;53:469–74.
16. Feldmann M, Brennan FM, Maini RN. Role of cytokines in rheumatoid arthritis. *Annu Rev Immunol* 1996;14:397–440.
17. Maini RN, Taylor PC. Anti-cytokine therapy for rheumatoid arthritis. *Annu Rev Med* 2000;51:207–29.

Received February 20, 2007; accepted June 6, 2007