

The morphological relationship between lumbosacral transitional vertebrae and lumbosacral pedicle asymmetry

Teruaki Ono¹⁾, Kiyoshi Tarukado¹⁾, Osamu Tono¹⁾, Katsumi Harimaya²⁾, Yuichiro Morishita³⁾, Yasuharu Nakashima²⁾ and Toshio Doi¹⁾

1) Department of Orthopedic Surgery, Kyushu University Beppu Hospital, Oita, Japan

2) Department of Orthopedic Surgery, Kyushu University, Fukuoka, Japan

3) Department of Orthopedic Surgery, Spinal Injuries Center, Iizuka, Fukuoka, Japan

Abstract:

Introduction: The clinical significance of lumbosacral transitional vertebrae (LSTV) has been reported. However, the association between LSTV and lumbosacral pedicle anatomical anomaly has not been investigated. We hypothesized that LSTV might be associated with lumbosacral anatomical anomaly. The purpose of this study was to examine the morphological association between LSTV and lumbosacral pedicle asymmetry (PA) using computed tomography (CT).

Methods: A retrospective review of CT images of 347 lumbosacral degenerative disease patients was performed. We divided the subjects into two groups: the normal and LSTV groups. LSTV was classified based on Castellvi's classification. PA was defined as a difference of more than 20° between the right and left angles of the pedicle.

Results: Seventy out of 347 lumbosacral degenerative disease patients (20.17%) were diagnosed with LSTV. In the normal group, only a 0.54% incidence of PA was seen; however, with respect to the LSTV group, a 9.29% incidence of PA was seen. A significant difference in PA incidence was observed between the groups ($p < 0.001$). Type IIIa and Type IV in the LSTV group showed a statistically significant PA incidence rate ($p = 0.004$ and $p = 0.039$, respectively).

Conclusions: Our study demonstrated that there was a significant difference in the incidence of PA between LSTV subjects and normal subjects. Moreover, the incidence of PA was significantly higher in LSTV subjects with severe anomaly. These results suggested that lumbosacral spine anomaly might have a close relationship with the incidence of PA and lumbosacral nerve root asymmetry. Therefore, morphological evaluation of the pedicle is important for preoperative surgical management, especially in cases using pedicle screws. This information could lower the incidence of pedicle screw malposition when pedicle screws are inserted at the lumbosacral spine.

Keywords:

Lumbosacral transitional vertebrae, Pedicle asymmetry, Pedicle screw malposition, Castellvi's classification, Computed tomography

Spine Surg Relat Res 2018; 2(1): 77-81
dx.doi.org/10.22603/ssrr.2017-0019

Introduction

Lumbosacral transitional vertebrae (LSTV) are the most common congenital anomaly of the lumbosacral spine and manifest L5 sacralization and S1 lumbarization¹⁾. We previously experienced a case that required reoperation resulting from postoperative lumbosacral nerve root irritation due to pedicle screw malposition during insertion by the percutaneous pedicle screw technique. The pedicle screw malposition occurred in a lumbosacral pedicle asymmetry (PA) with

LSTV patient (Fig. 1).

The clinical significance of LSTV has been reported and is associated with low back pain, lumbar disc herniation, or degenerative spondylolisthesis and appropriate treatments. However, to the best of our knowledge, the association between LSTV and lumbosacral pedicle anatomical anomaly has not been previously investigated. We hypothesized that LSTV might be associated with lumbosacral anatomical anomaly. The purpose of this study was to examine the morphological association between LSTV and PA using com-

Corresponding author: Teruaki Ono, teruohno013@yahoo.co.jp

Received: March 13, 2017, Accepted: June 6, 2017

Copyright © 2018 The Japanese Society for Spine Surgery and Related Research

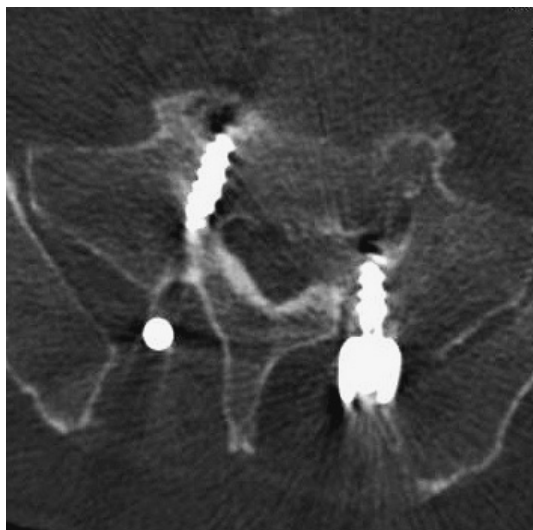


Figure 1. The axial view of CT shows pedicle screw malposition.

puted tomography (CT).

Materials and Methods

Study population

From June 2011 to August 2015, the lumbosacral spines of a total of 347 lumbosacral degenerative disease patients (214 males and 133 females with a mean age of 65 years [range 13-91]) were evaluated using CT. Patients who had previous lumbar surgery, spinal tumor, adolescent idiopathic scoliosis and vertebral fractures, vertebral malformation, or lumbosacral severe degeneration were excluded from the study.

Institutional Review Board approval was granted and informed consent was obtained from all patients.

CT analysis

Three senior spine surgeons assessed the presence of LSTV and the measured the pedicle angles using CT images, and each observer assessed twice on different occasions.

We divided the subjects to two groups: the normal and LSTV groups. Patients were classified as LSTV based on Castellvi's classification²⁾ using CT images: Type I, there is a large transverse process; Type II, there is a diarthrodial joint between the transverse process and the sacrum (a, unilateral; b, bilateral); Type III, there is a true bony union between the transverse process and the sacrum (a, unilateral; b, bilateral); and Type IV consists of Type II on one side and Type III on the other side (Fig. 2). Castellvi *et al.* reported that there were no clinical differences between patients with Type I LSTV and the normal population. Therefore, patients with Type I LSTV were classified as normal in this study.

The adjacent LSTV, lowest lumbar and sacral, paired pedicle angles were measured using CT and a 3D worksta-

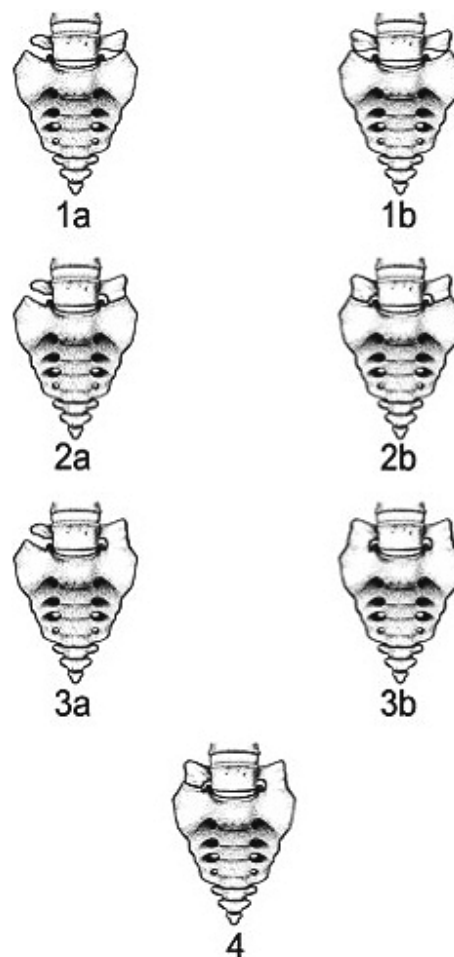


Figure 2. Illustration of Castellvi's classification for LSTVs.

1a. Type Ia with unilaterally enlarged L5 transverse processes and no articulation with the sacrum.

1b. Type Ib with bilaterally enlarged L5 transverse processes and no articulation with the sacrum.

2a. Type IIa with unilateral pseudarthrosis.

2b. Type IIb with bilateral pseudarthroses.

3a. Type IIIa with unilateral fusion of the enlarged transverse process to the sacral ala.

3b. Type IIIb with bilateral fusion.

4. Type IV with fusion on the one side and a pseudarthrosis on the other side.

tion (Aquarius iNtuition Server) (Fig. 3). This workstation made it possible to identify the true axial, coronal and sagittal images of the vertebral body. The pedicle angle (α and β) was defined from the line of the pedicle inner wall to the vertical line (Fig. 4). PA was defined as a difference that was more than 20° between the right and left angles of the pedicle based on a previous report³⁾.

Statistical analysis

The interobserver and intraobserver agreement was assessed using the interclass correlation coefficient. Differ-

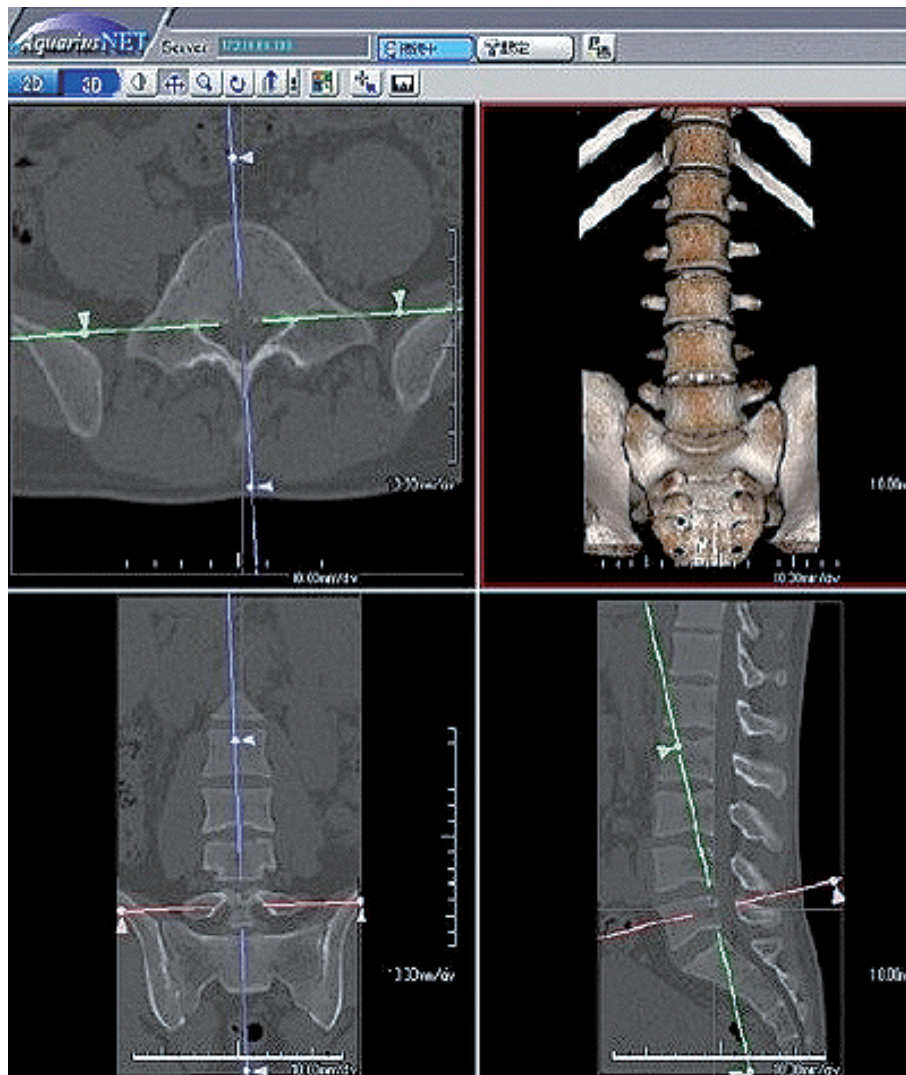


Figure 3. 3D workstation (Aquarius iNtuition Server).

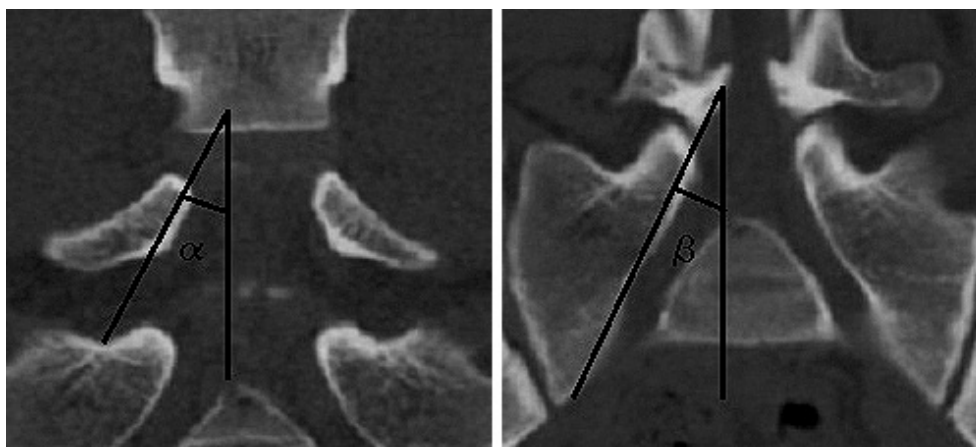


Figure 4. α and β indicate the pedicle angle. The pedicle angle was defined between the lines of the pedicle inner wall to the vertical line.

ences in the incidence of PA between the normal and LSTV groups, and the incidence of PA in Castellvi's classification among the group with LSTV were analyzed using Fisher's exact test. All statistical analyses were conducted using JMP® 11 software (SAS Institute Inc., Cary, NC, USA) with

a p value <0.05 being considered statistically significant.

Results

The interclass correlation coefficient for the interobserver

reliability of the pedicle angle assessments using CT images was 0.96 (0.93-0.98). The interclass correlation coefficients for the intraobserver reliability of the pedicle angle assessments using CT images were 0.93 (0.87-0.97) between observer 1 and 2 and 0.92 (0.67-0.97) between observer 1 and 3. Consistent agreement was noted among the three independent observers.

Seventy out of 347 lumbosacral degenerative disease patients (20.17%) were diagnosed with LSTV. Table 1 shows the incidence of PA in both groups. There was a 2.31% incidence of PA in all of the subjects. In the normal group, a PA incidence of only 0.54% was seen; however, with respect to the LSTV group, a PA incidence of 9.29% was seen. A significant difference in PA incidence was observed between the groups ($p < 0.001$).

Table 2 shows the distribution of Castellvi's classification and the relationships of the classification with PA in the LSTV group. More than 75% of the LSTV subjects demonstrated Type II (a and b). Type IIIa and Type IV showed statistically significant PA incidence rates ($p = 0.004$ and $p = 0.039$, respectively).

Discussion

Since Bertolotti described the clinical significance of LSTV in 1917⁴), the results of several studies about LSTV have reported^{1,2,5}). Currently, given its superior spatial resolution, CT is the best imaging technique for the characterization of LSTV. In addition, CT was used for a more accurate determination of LSTV because it is regarded as the "gold standard" for the diagnosis of bony lesion⁶). Robertson *et al.* previously evaluated the lumbar and S1 pedicle angles; however, it was difficult to evaluate the S1 pedicle using only plain radiographs due to rotation of the sacrum⁷). Pedicle angle measurement using CT and 3D workstation might be a

more accurate method because we could adjust the flexion-extension and rotation of the lumbar vertebrae and sacrum using the 3D workstation. Therefore, we could evaluate the pedicle angle using the true coronal view.

The prevalence of LSTV has been said to vary between 7% and 30% in previous studies^{8,9}). In our results, the incidence of LSTV was 20.17%, which is thought to be in agreement with the previous studies.

The clinical significance of LSTV in relation to anatomy and nerve root symptoms at lumbosacral vertebrae lesions has been debated¹⁰⁻¹³). Tulder *et al.* have reported that the incidence of LSTV is equal in patients with and without back pain, rendering it only an incidental finding on imaging¹⁰). Suzuki reported the relationship between LSTV and lumbosacral plexuses in an anatomical study¹²). He also reported that LSTV influences the branch point among lumbosacral plexuses. On the other hand, Mahato *et al.* reported that S1 pedicle anatomy differs from the normal anatomy in cases of L5-S1 transitions¹³). However, they did not discuss PA with LSTV. In this study, we found a significant difference in PA incidence between LSTV subjects and normal subjects; 9.29% of LSTV subjects had PA, while only 0.54% of normal subjects had PA. Moreover, the incidence of PA was significantly higher in Castellvi's classification Type IIIa and IV subjects with LSTV. These results suggested that anomaly at the lumbosacral spine might have a close relationship with the incidence of PA and lumbosacral nerve root asymmetry. Moreover, PA with LSTV might affect the abnormality of lumbosacral plexuses.

Usually, the lumbosacral nerve root transits just below the inner wall of the pedicle. The transition of the lumbosacral nerve root might be greatly affected by a bulging disc or conjoined nerve roots. However, we believe that the most important risk factor for lumbosacral nerve root asymmetry is anatomical anomaly of the vertebrae and pedicle. Therefore, morphological evaluation of the pedicle is important for preoperative surgical management, especially in cases involving the use of pedicle screws. We would prevent screw malposition by checking the safe lesion of the pedicle screw insertion when finding an anatomic anomaly of the vertebrae. This information could lower the incidence of pedicle screw malposition when pedicle screws are inserted at the lumbosacral spine.

Table 1. The Incidence of Pedicle Asymmetry (PA).

	Total n = 347 (694 pedicles)	Normal n = 277 (554 pedicles)		LSTV n = 70 (140 pedicles)
PA	16 (2.31%)	3 (0.54%)	***	13 (9.29%)

* $p < 0.05$, ** $p < 0.01$, *** $p < 0.001$ (Fisher's exact test)

Table 2. The Distribution of Castellvi's Classification and Incidence of Pedicle Asymmetry (PA) in the LSTV Group.

Castellvi's classification	Incidence of PA	p-value
Type IIa (n = 29; 58 pedicles; 41.43%)	2 (3.4%)	ns
Type IIb (n = 24; 48 pedicles; 34.29%)	2 (4.1%)	ns
Type IIIa (n = 8; 16 pedicles; 11.43%)	5 (31.2%)	$p = 0.004$
Type IIIb (n = 5; 10 pedicles; 7.14%)	2 (20.0%)	ns
Type IV (n = 4; 8 pedicles; 5.71%)	2 (25.0%)	$p = 0.039$

ns, not significant (Fisher's exact test)

Some issues remain unaddressed in the current study. We did not discuss the differences between L5 sacralization and S1 lumbarization. Therefore, the current investigation can be considered a pilot study, and further research using a larger patient population may help to resolve several unclear issues in this study. Moreover, the morphological differences of the pedicle and lumbosacral nerve root transition in LSTV should be clarified in more detail.

Conclusions

Our study demonstrated that there was a significant difference in PA incidence between LSTV subjects and normal subjects. Moreover, the incidence of PA was significantly higher in LSTV subjects with severe anomaly. These results suggested that anomaly of the lumbosacral spine might have a close relationship with the incidence of PA and lumbosacral nerve root asymmetry. Therefore, the morphological evaluation of the pedicle is important for preoperative surgical management, especially in cases involving the use of pedicle screws. This information could lower the incidence of pedicle screw malposition when pedicle screws are inserted at the lumbosacral spine.

Conflicts of Interest: The authors declare that there are no conflicts of interest.

References

1. Konin GP, Walz DM. Lumbosacral transitional vertebrae: classification, imaging findings, and clinical relevance. *AJNR Am J Neuroradiol.* 2010;31(10):1778-86.
2. Castellvi AE, Goldstein LA, Chan DP. Lumbosacral transitional vertebrae and their relationship with lumbar extradural defects. *Spine.* 1984;9(5):493-5.
3. Postacchini F. *Lumbar disc herniation.* Rome: Springer-Verlag Wien; 1999. 43 p.
4. Bertolotti M. Contributo alla conoscenza dei vizi differenziazione regionale del rachide con special riguardo all assimilazione sacrale della V. lombare. *La Radiologia Medica* 1917;4:113-144.
5. Elster AD. Bertolotti's syndrome revisited. Transitional vertebrae of the lumbar spine. *Spine.* 1989;14(12):1373-7.
6. Lee CS, Ha JK, Kim DG, et al. The clinical importance of lumbosacral transitional vertebra in patients with adolescent idiopathic scoliosis. *Spine.* 2015;40(17):E964-70.
7. Robertson P.A, Stewart N.R. The radiologic anatomy of the lumbar and lumbosacral pedicles. *Spine.* 2000;25(6):709-15.
8. Delport EG, Cucuzzella TR, Kim N, et al. Lumbosacral transitional vertebrae: incidence in a consecutive patient series. *Pain Physician.* 2006;9(1):53-6.
9. French HD, Somasundaram AJ, Schaefer NR, et al. Lumbosacral transitional vertebrae and its prevalence in the Australian population. *Global Spine J.* 2014;4(4):229-32.
10. Van Tulder MW, Assendelft WJ, Koes BW, et al. Spinal radiographic findings and nonspecific low back pain. A systematic review of observational studies. *Spine.* 1997;22(4):427-34.
11. Otani K, Konno S, Kikuchi S. Lumbosacral transitional vertebrae and nerve-root symptoms. *J Bone Joint Surg Br.* 2001;83(8):1137-40.
12. Suzuki N. An anatomical study of the root sleeve emergence and its relation to segmental anomalies of the lumbo-sacral spine. *Nihon Seikeigeka Gakkai Zasshi* 1987;61(12):1379-87. Japanese.
13. Mahato NK. Pedicular anatomy of the first sacral segment in transitional variations of the lumbo-sacral junction. *Spine.* 2011;36(18):E1187-92.

Spine Surgery and Related Research is an Open Access article distributed under the Creative Commons Attribution - NonCommercial - NoDerivatives 4.0 International License. To view the details of this license, please visit (<https://creativecommons.org/licenses/by-nc-nd/4.0/>).