

CASE REPORT

Mean medial canthal and differential hemangioma temperatures provide objective infantile facial hemangioma measurements

Afieharo I. Michael ^{1,2,*}¹Department of Surgery, Faculty of Clinical Sciences, College of Medicine, University of Ibadan, Ibadan, Nigeria²Department of Plastic, Reconstructive and Aesthetic Surgery, University College Hospital, Ibadan, Nigeria

*Correspondence address. Department of Surgery, College of Medicine, University of Ibadan, Ibadan P.M.B. 1156, Oyo State, Nigeria.

Tel: +234-7059238585; E-mail: afiemichael@gmail.com

Abstract

Infrared thermography is a useful adjunct for the clinical monitoring of infantile hemangioma (IH) activity with or without treatment. There is a dearth or reporting on the ideal tissue for standardizing temperature readings from IH. This case illustrates the use of mean medial canthal temperatures and the differential hemangioma temperatures for monitoring of facial IH.

INTRODUCTION

Infantile hemangiomas (IHs) are the commonest infantile neoplasm with an incidence of 1–3% in Caucasians [1]. A lower incidence is reported in Blacks [2]. They are benign vascular tumors appearing shortly after birth as a herald reddish patch. The diagnosis of IH is clinical in 90% of cases [1, 2]. The natural history of IH is characterized by rapid proliferation up to 6–12 months, a plateau phase and subsequent involution [1–3]. This natural history lends itself to conservative management in most cases of IH. Treatment is necessary where the hemangiomas are functionally debilitating such as affecting the visual field in periorbital hemangiomas or causing respiratory obstruction when located anywhere along the respiratory tract [1, 4, 5]. Hemorrhage, ulceration or serious disfigurement are other indications for treatment [1, 2]. Adjuncts to aid diagnosis and management include color doppler ultrasonography, magnetic resonance imaging (MRI), computed tomography (CT) scan and infrared (IR) thermography [2, 6]. IR thermography is useful in the assessment and monitoring of IH [6, 7]. Studies utilizing IR thermography have used the visual analog scale or subjective clinician and patient reports to validate its use. This case presentation illustrates the use of the mean medial canthal and differential hemangioma temperatures (DHTs) for IR thermographic monitoring of facial IH.

CASE REPORT

A 7-month-old child was brought to our clinic by her mother with complaints of a reddish disfiguring large lesion on her lower lip. There had been a reddish hue at birth. This was followed by a rapid increase in size over the subsequent weeks to become disfiguring and prevented the child from closing her mouth (Fig. 1a). There were no lesions anywhere else. Examination revealed a hyperemic disfiguring lesion on the lower lip, which was soft, doughy with differential warmth. It was compressible but not pulsatile. A diagnosis of IH was made. With the use of a Flir One Camera, a thermographic temperature reading of the lesion, as well as that of the medial canthal vessels, was taken on the day of presentation (Fig. 2a). She was commenced on oral propranolol at 1 ml/kg/day after ensuring normal electrocardiogram and blood profile. Thermographic temperature readings were taken at every subsequent visit (Fig. 2a, Table 1). A steep drop in the DHT was seen after the commencement of propranolol therapy, pointing to its efficacy (Fig. 3). On her third visit after the commencement of oral propranolol, there was an increase in the DHT (Fig. 3). The mother informed that she had run out of the drug 5 days prior to that visit. The patient was recommenced on oral propranolol. At the follow-up visit 10 months after commencement of propranolol, she was able to close her mouth (Fig. 1b), and the DHT was appreciably low (Fig. 3).

Received: January 21, 2022. Accepted: February 15, 2022

Published by Oxford University Press and JSCR Publishing Ltd. All rights reserved. © The Author(s) 2022.

This is an Open Access article distributed under the terms of the Creative Commons Attribution Non-Commercial License (<https://creativecommons.org/licenses/by-nc/4.0/>), which permits non-commercial re-use, distribution, and reproduction in any medium, provided the original work is properly cited. For commercial re-use, please contact journals.permissions@oup.com

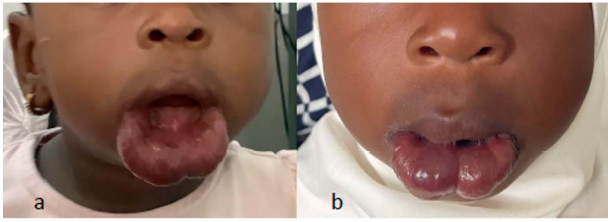


Figure 1. (a and b) Lower lip hemangioma before (a) and after (b) treatment with propranolol.



Figure 2. (a and b) Thermographic medial canthal and hemangioma temperature readings before (a) and after (b) commencement of oral propranolol.

FORMULA FOR CALCULATING MEAN MEDIAL CANTHAL AND DHTS

First, determine the mean medial canthal temperature (MMCT):

$$\text{MMCT} = \text{Right MCT} + \text{Left MCT}.$$

Second, calculate the DHT:

$$\text{DHT} = \text{MMCT} - \text{MHT},$$

where MHT is the maximal hemangioma temperature.

DISCUSSION

This case presentation demonstrates that the use of DHTs provides more information than absolute hemangioma temperatures (Fig. 4) in the assessment of hemangioma activity or the monitoring of treatment. For

facial hemangioma not involving the eyelids, the MMCT can be used as a standard for determination of the DHT.

IR thermography has increased our understanding of the activity of IH, and both static and dynamic IR thermography have been employed in IH activity determination [7–10]. IR thermography is not as expensive as other modalities, such as CT and MRI, in the monitoring of IH. Thermography is a non-contact, non-invasive and useful clinical adjunct for the management of IH. Previous studies have utilized the visual analog scale to determine the effect of propranolol therapy on the activity of IH [6, 8]. Subjective clinical esthetic assessments by either the clinician or patients have also been used [8]. Kalicki *et al.* suggested that comparison of IH temperatures with an adjacent body part would provide more objective measurements [7]. Given that the hemangioma is a vascular tumor, utilization of a normal vascular activity to standardize the temperature readings has some merit. It obviates any form of subjectivity and can be applied readily as seen in this case. Propranolol has replaced corticosteroid as the first line of treatment for IH where conservative watchful waiting is not feasible [5]. Mechanisms of propranolol activity include vasoconstriction, downregulation of vascular endothelial growth factor and basic fibroblast growth factor as well as upregulation of capillary endothelial cell apoptosis [5, 11]. Although its effects are systemic, the side effects, when given at 1–3 mg/kg, are not as significant as those experienced when using corticosteroids in the management of IH [5]. The rebound phenomenon when use of propranolol is discontinued could be as high as 7% [11]. This was seen in our patient when she discontinued the propranolol. This rebound was also more clearly detected by the DHT than the absolute hemangioma temperature.

CONCLUSION

MMCTs can be used as a standard for objectively comparing infantile facial hemangioma activity or for monitoring the effects of treatment. DHT rather than absolute hemangioma temperature is more informative. These measurements can be used to design subsequent studies on facial hemangioma.

ACKNOWLEDGEMENTS

The author thanks Dr Brett Davis and his team for making available the Flir One camera and Ipad.

Table 1. Serial IR thermographic readings

Examinations	Right medial canthal temperature	Left medial canthal temperature	MHT	MMCT	DHT
1	35.90	35.50	36.50	35.7	0.8
2	35.20	35.20	36.20	35.2	1
3	33.00	32.80	33.90	32.9	1
4	35.00	34.60	35.00	34.8	0.2
5	36.90	36.90	36.70	36.9	–0.2
6	37.00	36.80	37.50	36.9	0.6
7	27.60	27.40	27.70	27.5	0.2

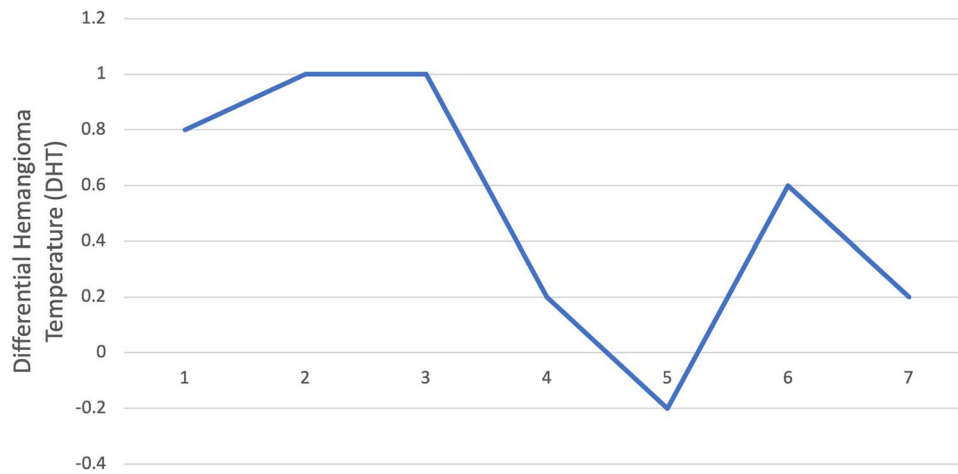


Figure 3. Line graph showing DHTs.

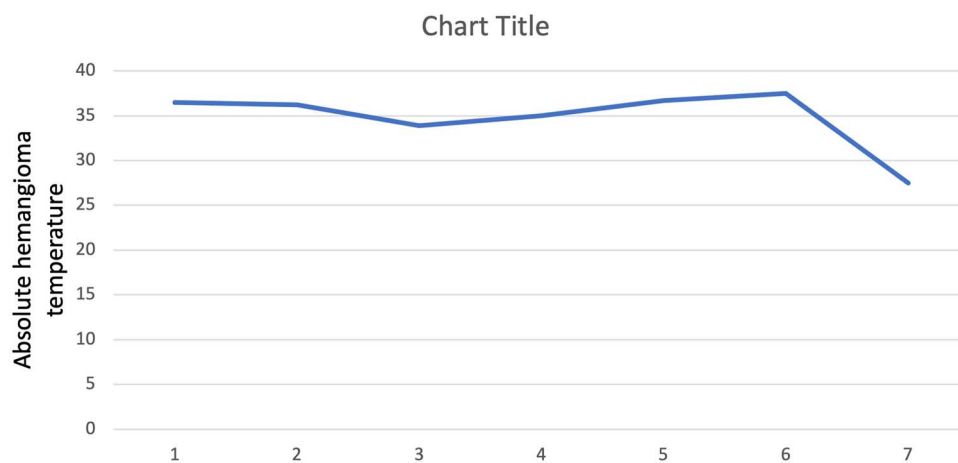


Figure 4. Line graph showing serial absolute hemangioma temperatures.

CONFLICT OF INTEREST STATEMENT

None declared.

FUNDING

None.

REFERENCES

- Burns AJ, Navarro JA, Cooner RD. Classification of vascular anomalies and the comprehensive treatment of hemangiomas. *Plast Reconstr Surg* 2009;**124**:69e–81e.
- Gampper TJ, Morgan RF. Vascular anomalies: hemangiomas. *Plast Reconstr Surg* 2002;**110**:572–85.
- Bauland CG, van Steensel MAM, Steijlen PM, Rieu PNMA, Spauwen PHM. The pathogenesis of hemangiomas: a review. *Plast Reconstr Surg* 2006;**117**:29e–35e.
- Frank RC, Cowan BJ, Harrop AR, Astle WF, McPhalen DF. Visual development in infants: visual complications of periocular haemangiomas. *J Plast Reconstr Aesthet Surg* 2010;**63**:1–8.
- Izadpanah A, Izadpanah A, Kanevsky J, Belzile E, Schwarz K. Propranolol versus corticosteroids in the treatment of infantile hemangioma: a systematic review and meta-analysis. *Plast Reconstr Surg* 2013;**131**:601–13.
- Mohammed JA, Balma-Mena A, Chakkittakandiyil A, Matea F, Pope E. Infrared thermography to assess proliferation and involution of infantile hemangiomas: a prospective cohort study. *JAMA Dermatol* 2014;**150**:964–9.
- Kalicki B, Jung A, Rustecka A, Zylak A, Zuber J, Murawski P, et al. Infantile hemangiomas - the possibility of using infrared thermography in the assessment of propranolol efficacy-preliminary study. *Thermology International* 2012;**22**:66–75.
- Kalicki B, Jung A, Ring F, Rustecka A, Maślany A, Zuber J, et al. Infrared thermography assessment of infantile hemangioma treatment by propranolol. *Thermology International* 2012;**22**:102–3.
- Strumilla A, Kazlauskas V, Pošiūnas G, Verkauskas G, Beiša V. Infantile hemangioma: predicting proliferation by infrared thermography. *Medicina (Lithuania)* 2017;**53**:85–9.
- Burkes SA, Patel M, Adams DM, Hammill AM, Eaton KP, Randall Wickett R, et al. Infantile hemangioma status by dynamic infrared thermography: a preliminary study. *Int J Dermatol* 2016;**55**:e522–32.
- Szychta P, Stewart K, Anderson W. Treatment of infantile hemangiomas with propranolol: clinical guidelines. *Plast Reconstr Surg* 2014;**133**:852–62.