

Intraoperative hybrid left pulmonary artery stenting

Budhaditya Chakraborty, Donald Hagler, Harold M Burkhart, Joseph A Dearani

Division of Cardiac Surgery and Pediatric Cardiology, Mayo Clinic, Rochester, MN, USA

INTRODUCTION

Branch pulmonary artery stenosis can occur with several congenital cardiac anomalies or can be acquired following primary surgical intervention. Most of these isolated stenoses are treated in the catheterization laboratory by percutaneous stent deployment. However, when a concomitant cardiac surgical procedure is required, it is convenient to deploy the stent simultaneously through a pulmonary arteriotomy expeditiously and with great accuracy. The posterior angulation of the left pulmonary artery (LPA) and its position in the chest makes it relatively difficult to be surgically patched and augmented when the stenosis goes beyond its origin and in particular when there is a more distal stenosis. The hybrid stent deployment may be a feasible option in such cases. We have applied hybrid stenting for right pulmonary artery (RPA), LPA, and bilateral pulmonary artery (BPA) stenosis. We present our technique for intraoperative hybrid LPA stent placement at the time of pulmonary valve replacement (PVR).

TECHNIQUE

Supine positioning, standard monitoring line placement, and routine use of transesophageal echo (TEE) is utilized. Interrogation of intracardiac anatomy and determination of the presence of intracardiac shunts is accomplished with agitated saline central venous injection. Chest entry is achieved through redo median sternotomy. Standard cardiopulmonary bypass is instituted at normothermia. In the absence of any intracardiac shunts, single venous cannulation is used; bicaval cannulation is used when intracardiac repair is needed (e.g., patent foramen ovale (PFO) closure, tricuspid repair etc.). Aortic occlusion with cardioplegic

arrest is used for PFO, atrial septal defect (ASD) or ventricular septal defect (VSD) closure. An aortic tack vent is used routinely, even for isolated PVR and the patient's bed is maintained in Trendelenburg position.

After institution of bypass, repair of intracardiac defects is performed. The MPA is then opened longitudinally with the heart beating from its origin and extended up to the bifurcation. It is important not to skeletonize and to avoid unnecessary dissection around the LPA. Scar tissue in this area can be helpful to avoid inadvertent rupture of the LPA during stent placement and dilatation. A pump sucker in the RPA and RV keeps the operative field clear. The LPA stenting is carried out first. The estimated LPA diameter and the extent of the stenosis is predetermined using cardiac catheterization or MRI. An intraoperative confirmatory assessment may be carried out by introducing Hegar dilators. Under direct visualization a balloon expandable, hand mounted stent with a preselected high pressure balloon (ZMED II-8 to 16 atmospheres) is introduced into the LPA across the stenosis by the surgeon [Figure 1]. Dilatation is carried out up to the maximum recommended pressure as determined by the interventional cardiologist. The commonly used stents are the GENESIS XD biliary stent or the eV3 IntraStent LD Max stent. The balloon is reintroduced proximally and distally across the stent and reinflated to ensure complete dilatation. The proximal landing zone of the stent is splayed out so it is flush with the wall of the pulmonary artery. It is then sutured onto the wall of the LPA to prevent distal migration. Accurate placement can be determined by direct inspection [Figure 2]. The length of the stent selected is short enough that there is no compromise of intralobar branches. We do not routinely use intraoperative X-ray to guide stent deployment since we apply this only to patients with stenosis involving the proximal and mid LPA; it is done under direct vision. We do not routinely predilate the stenosis with balloon. Predilatation may be considered if the stenosis is very severe, or for an instent restenosis of a previously implanted stent. Once satisfactory stent positioning is achieved we proceed with PVR [Figure 3]. The MPA is closed primarily when it is dilated or patch augmented with autologous or bovine pericardium as the case demands. Immediate postbypass intraoperative

Access this article online	
Quick Response Code: 	Website: www.annalspc.com
	DOI: 10.4103/0974-2069.107233

Address for correspondence: Dr. Joseph A Dearani, Division of Cardiac Surgery, J0- 5 - 200, First Street, St. Mary's Hospital, Rochester, MN, USA.

E-mail: jdearani@mayo.edu

pulmonary angiography may be helpful to verify stent location and size in selected cases.

DISCUSSION

The hybrid deployment of LPA stent is particularly useful in patients with:

1. Need for concomitant surgery, for example, ASD or VSD closure, tricuspid repair, maze procedure, right ventricular outflow tract (RVOT) augmentation or reconstruction, PVR.
2. Difficult vascular access or increased tortuosity of the pulmonary arteries.
3. Previous pulmonary prosthetic valve.
4. Rescue procedures following percutaneous procedures-in cases of bleeding, stent migration, dissection, etc.

Reoperations are often times complicated by significant scar tissue, adhesions, compressions, and collaterals. At times it becomes imperative to resort to prolonged bypass runs and even low flow or circulatory arrest. The intraoperative use of stents can mitigate these issues to a large extent. The initial reports of intraoperative stenting were published by Mendelsohn, et al.,^[1] in 1993. Ungerleider, et al.,^[2] reported a high hospital mortality (5 out of 27 patients) and 3 late deaths but none attributed to the stents themselves. Progressive improvements in the outcomes were reported in subsequent studies^[3,4] and has spurred on the more frequent use of this modality. The primary concerns have been related to significant restenosis rates (as high as 26% within 15 months median follow-up^[5] and 25% within 2-24 months follow-up^[4]) variously reported.^[6] In our experience, however, the frequency has not been very significant. The other major limitation of this procedure is related to the use of these stents in distal and branch PA stenoses. Since visualization of the distal extent of these stents placed distally are virtually impossible without fluoroscopic guidance, there is a concern that improper positioning or distal stent migration or aggressive ballooning may cause tear, aneurysmal dilation, or jailing of the smaller branched PAs. In our series, the majority of the cases done have been restricted to the proximal and mid portion and hence we have successfully avoided these problems. Performing these procedures in the hybrid laboratory with fluoroscopic availability may be the answer to this issue. Also as mentioned previously, avoiding excess dissection and allowing the scar tissue to act as a scaffolding seems to prevent perforations and transmural ruptures. In our experience^[7] till date, we have not encountered any such event. Lastly there is a valid concern that reoperations on these stented PAs may make them less amenable to Patch plasty at a later date in view of increased tissue friability.

At the Mayo Clinic we have performed the above described procedure in 63 patients, 34 of which are for the LPA only. Rest of the cases involved either right or BPA stentings. We are in the process of formalizing a detailed publication on our experience. There has been no mortality and no complications of

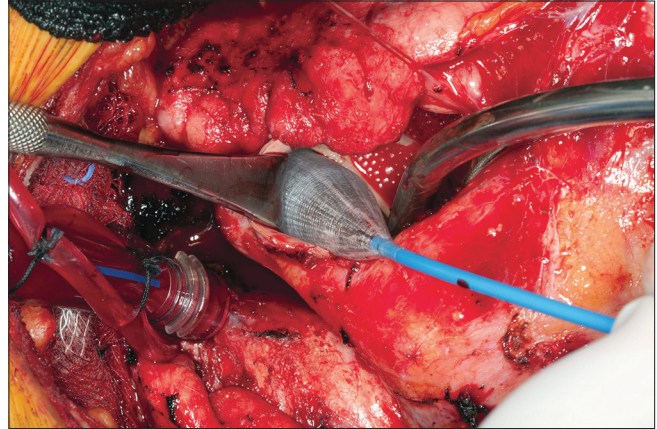


Figure 1: High pressure balloon introduced into the left pulmonary artery under direct visualization across the stenosis

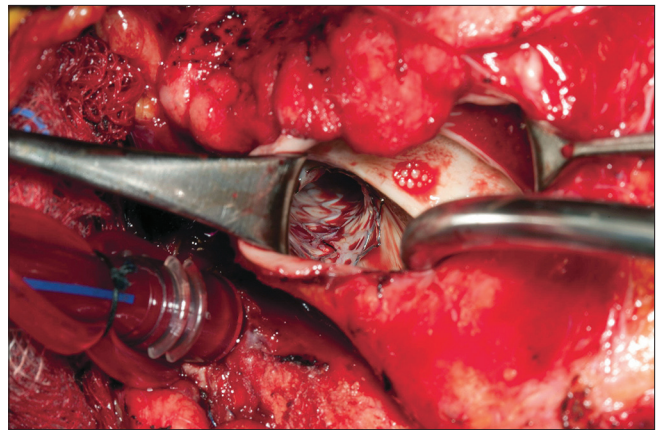


Figure 2: Stent placement in the left pulmonary artery. Position confirmed by direct visualization

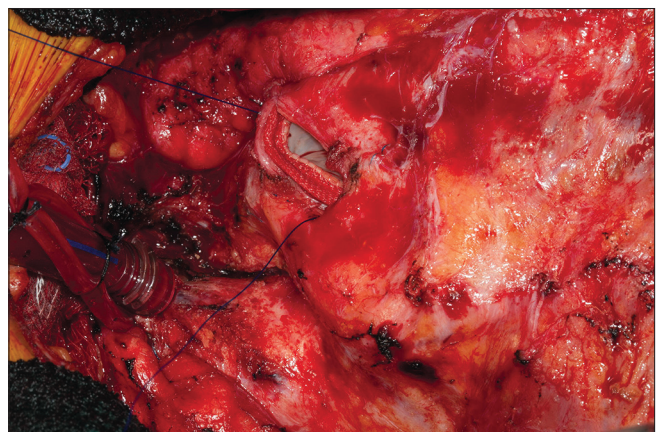


Figure 3: Sewing in the pulmonary valve after completion of left pulmonary artery stenting

pulmonary artery tear, dissection, or stent thrombosis in the perioperative period. Mild distal migration of the stent occurred in two of the early cases that were managed by percutaneous redilatation. Since suturing the proximal stent onto the LPA wall stent migration has not recurred. Typically all patients are discharged on aspirin.

REFERENCES

1. Mendelsohn AM, Bove EL, Lupinetti FM, Crowley DC, Lloyd TR, Fedderly RT, *et al.* Intraoperative and percutaneous stenting of congenital artery and vein stenosis. *Circulation* 1993;88:II210-7.
2. Ungeleider RM, Johnston TA, O'Laughlin MP, Jaggars JJ, Gaskin PR. Intraoperative stents to rehabilitate severely stenotic pulmonary vessels. *Ann Thorac Surg* 2001;71:476-81.
3. Mitropoulos FA, Laks H, Kapadia N, Gurvitz M, Levi D, Williams R, *et al.* Intra operative pulmonary artery stenting: An alternative technique for the management of pulmonary artery stenosis. *Ann Thorac Surg* 2007;84:1338-41.
4. Bokenkamp R, Blom NA, De Wolf D, Francois K, Ottenkamp J, Hazekamp MG. Intraoperative stenting of pulmonary arteries. *Eur J Cardiothorac Surg* 2005;27:544-7.
5. Coles JG, Yemets I, Najm HK, Lukanich JM, Perron J, Wilson GJ, *et al.* Experience with repair of congenital heart defects using adjunctive endovascular devices. *J Thorac Cardiovasc Surg* 1995;110:1513-9.
6. Bergersen L, Lock JE. What is the current option of first choice for treatment of pulmonary arterial stenosis? *Cardiol Young* 2006;16:329-38.
7. Menon SC, Cetta F, Dearani JA, Burkhart HM, Cabalka AK, Hagler DJ. Hybrid intraoperative pulmonary stent placement for congenital heart disease. *Am J Cardiol* 2008;102:1737-41.

How to cite this article: Chakraborty B, Hagler D, Burkhart HM, Dearani JA. Intraoperative hybrid left pulmonary artery stenting. *Ann Pediatr Card* 2013;6:43-5.

Source of Support: Nil, **Conflict of Interest:** None declared