

Effect of computer navigation-assisted minimally invasive direct lateral interbody fusion in the treatment of patients with lumbar tuberculosis

A retrospective study

Jianzhong Jiang, BS^a, Fengping Gan, MS^{a,*}, Haitao Tan, MD^a, Zhaolin Xie, BS^a, Xiang Luo, MS^b, Guoxiu Huang, MS^b, Yin Li, MS^a, Shengbin Huang, MS^a

Abstract

The benefits of navigation-assisted technologies are not entirely understood. Therefore, this study aimed to examine the outcomes of patients with lumbar tuberculosis who received computer navigation-assisted minimally invasive direct lateral interbody fusion (DLIF).

This was a retrospective study of 33 patients with lumbar tuberculosis who underwent minimally invasive DLIF at the Department of Spine and Orthopedics of Guigang People's Hospital (Guangxi, China) between January 2015 and December 2016. The patients were pathologically diagnosed as lumbar tuberculosis and grouped into the navigation-assisted fluoroscopy (NAV; n=18) and non-navigation-assisted fluoroscopy (non-NAV; n=15) groups. X-ray exposure and operation times were assessed in all patients.

All surgical procedures were successfully completed. No case was converted into open surgery. The NAV group had longer surgical preparation time but shorter operation time compared with the non-NAV group (both $P < .01$). Total operation time showed no significant difference between the 2 groups ($P = .1$). The time of radiation exposure in the non-NAV group was longer compared with that of the NAV group (53.2 ± 9.9 vs 13.5 ± 2.6 s; $P < .01$). There were no significant differences regarding intraoperative blood loss, postoperative drainage volume, length of hospital stay, bone fusion and complications between the 2 groups (all $P > .05$).

Computer navigation-assisted minimally invasive DLIF could significantly reduce intraoperative radiation exposure, with no increase in total operation time.

Abbreviations: DLIF = direct lateral interbody fusion, ESR = erythrocyte sedimentation rate, NAV = navigation-assisted fluoroscopy.

Keywords: computer navigation, direct lateral interbody fusion, minimally invasive surgery, operation time, radiation exposure, spinal tuberculosis

1. Introduction

Tuberculosis prevalence in China has gradually increased in recent years,^[1] representing 10% of all cases worldwide,^[2] despite vast national efforts for disease control.^[3–5]

Spinal tuberculosis is among the most common forms of extrapulmonary tuberculosis.^[6,7] Approximately 10% of patients with tuberculosis have bone involvement, with the spine

being the most commonly affected, followed by the hip and the knee.^[6–8] Spinal tuberculosis is particularly common in HIV-infected patients.^[6,7] Its progression is slow and insidious; the most common sign is the Potts's spine, with pain and neurological impairment.^[6–8] Despite its frequency and high morbidity, no standard treatment is available. The primary approach is obviously anti-tuberculous therapy, and available evidence does not support the routine use of surgery.^[6,7,9–12] Surgery is indicated in selected cases to reduce kyphosis, relieve spinal cord compression, relieve severe pain, and achieve faster bone fusion.^[6,7,11–14] Zhang et al^[15] showed that most cases of lumbar and lumbosacral tuberculosis could be treated by minimally invasive surgery.

Direct lateral interbody fusion (DLIF) is commonly used in patients with spinal degenerative diseases, trauma, tumors, and spinal tuberculosis.^[16] Due to the repeated requirement for X-ray fluoroscopy during the process of channel and interbody fusion cage implantation, it is difficult to avoid exposure to large amounts of X-rays and ensure surgical accuracy and safety.

The computer navigation technology significantly improves the accuracy of spinal surgery and reduces the intraoperative X-ray dose.^[17] In pre-psoas oblique lateral interbody fusion (OLIF), a navigation system showed that radiation exposure is eliminated for surgeons and greatly reduced to the patient, compared with conventional fluoroscopy.^[18]

However, navigation-assisted technologies are fairly novel, and additional data are necessary to comprehensively determine

Editor: Leonardo Roever.

JJ and FG contributed equally to this work.

This study was funded by the Guangxi Science and Technology Project (AD17129017).

The authors declare that they have no conflicts of interest.

^aDepartment of Spine and Joint Surgery, ^bGuangxi Clinical Research Center for Digital Medicine and 3D Printing, Guigang People Hospital, Guangxi, China.

*Correspondence: Fengping Gan, Department of Spine and Joint Surgery, Guigang People Hospital, Guangxi 537100, China (e-mail: ganfengping@163.com).

Copyright © 2018 the Author(s). Published by Wolters Kluwer Health, Inc. This is an open access article distributed under the terms of the Creative Commons Attribution-Non Commercial-No Derivatives License 4.0 (CCBY-NC-ND), where it is permissible to download and share the work provided it is properly cited. The work cannot be changed in any way or used commercially without permission from the journal.

Medicine (2018) 97:48(e13484)

Received: 4 April 2018 / Accepted: 7 November 2018

<http://dx.doi.org/10.1097/MD.0000000000013484>

their benefits. Therefore, the aim of the present retrospective study was to examine the outcomes of 18 patients with lumbar tuberculosis who underwent computer navigation-assisted minimally invasive DLIF aiming to complete debridement, interbody fusion, and internal fixation.

2. Subjects and methods

2.1. Study design and patients

This was a retrospective study assessing patients with lumbar tuberculosis who underwent minimally invasive DLIF at the Department of Spine and Orthopedics of Guigang People's Hospital (Guangxi, China) between January 2015 and December 2016. It was approved by the Ethics Committee of Guigang People's Hospital. The need for individual informed consent was waived by the committee because of the retrospective nature of the study.

All patients were pathologically diagnosed with lumbar tuberculosis. The inclusion criteria were:

- (1) lumbar tuberculosis lesion located in a single segment of L1-L5;
 - (2) presence of necrotic bone and paravertebral abscess with segmental instability; and
 - (3) lesion located in the anterior or middle spinal column.
- The exclusion criteria were:
- (4) lesion in the region of the L5/S1 gap or above L1;
 - (5) multiple segments involved;
 - (6) lesion in the posterior spinal column (spine attachment involvement);
 - (7) overt pulmonary tuberculosis;
 - (8) patients with severe comorbidity (such as hepatic or renal failure, abnormal coagulation function, or pulmonary or cardiac insufficiency); or
 - (9) incomplete follow-up data.

2.2. Grouping

According to whether intraoperative navigation technology was used, the patients were grouped into the navigation-assisted fluoroscopy (NAV) and non-navigation-assisted fluoroscopy (non-NAV) groups. The patients chose a treatment approach voluntarily after discussion with the surgeons.

2.3. Preoperative preparation

All the patients received anti-tuberculous therapy for >2 weeks before surgery, including isoniazid (300 mg/d), rifampicin (450 mg/d), ethambutol (750 mg/d), and streptomycin (750 mg/d) or pyrazinamide (15–30 mg/kg/d). Erythrocyte sedimentation rate (ESR) and liver and kidney functions were monitored weekly. The patients underwent surgery after general condition improvement. Patients with poor general condition underwent blood transfusion, human serum albumin injection, and other supportive treatments.^{16,71}

2.4. Equipment

A minimally invasive direct lateral approach channel system from Medtronic, Inc. (Fridley, MN) was used. Intraoperative nerve monitoring was performed on a NIM-ECLIPSE system. The spine navigation system from Medtronic, Inc. was used for computer navigation. The hardware included professional image

workstations, reference frames (which allow navigation system trace changes and device position in real-time, including active and passive reference frames), an infrared photoelectric detector (timely monitor of reference frame position changes and instantaneously tracking of active and passive surgical instruments), and various surgical instruments with infrared tracers.

2.5. Surgery in the NAV group (Figs. 1 and 2)

All patients in both groups were operated by the same chief surgeons and underwent tracheal intubation and general anesthesia. The patients were placed in the 90° lateral position. The side with more severe bone destruction and pus was selected for the surgical approach. The lumbar bridge (considered the center) was aligned with the vertebral body of the lesion segment. The head end of the operation table was inclined downwards by about 40°. The patients were maintained in the appropriate posture of hip and knee flexors with straps and cushions. After disinfection and area sterilization, the navigation reference frame was fixed at the posterior superior iliac spine. The O-arm was connected with the navigator and the lesion segment was scanned. Navigation surgical instruments with tracers were registered at the workstation. The navigation probe was used to locate the skin surface projection of the anteroposterior median position of the lateral side of the lesion space, and a 5-cm incision was made. After the skin and subcutaneous tissues were removed, abdominal wall muscular fibers (external and internal oblique) were bluntly separated with the index through the incision. Using computer navigation, the guide needle was entered into the intervertebral space of the lesion through the retroperitoneal space and psoas. The position guide needle had to be in the middle of the lesion intervertebral space. Expansion cannulas were inserted along the position guide needle in turn. The tubular detachment hook was placed, and free arms were connected and fixed. The incision was opened, revealing the intervertebral space. The paravertebral abscess and cheese-like exudate were removed. Intervertebral disc and necrotic bone lesions were removed until the healthy bone was obtained. Navigation probes were used to identify the range of lesion debridement and decompression. Using computer navigation, screws and a steel plate were implanted, and the optimal entrance points and angles were selected. The screws were inserted into the 1/3 posterior vertebral body under real-time guidance in order to avoid damage to spinal canal nerves. The height of the bone graft slot was measured, and an autologous iliac bone mass with a suitable length was implanted, or a titanium mesh of suitable length and diameter (Beijing Weigao Yahua Manual Work Joint Development Co., Ltd., Beijing, China) was selected. Autologous iliac or allograft freeze-dried bone strips (Shanxi OsteoRad Biomaterial Co., Ltd., Taiyuan, China) were minced, placed into the titanium mesh, implanted into the bone graft slot, and tamped. The anterior approach steel plate (Beijing Fule Science & Technology Development Co., Ltd., Beijing, China) with suitable length was implanted. The nuts of the main screws were tightened, and assistant screws were twisted under the guidance of navigation. C-arm fluoroscopy was performed to confirm the positions of screws and steel plates. The incision was washed, and 1 g of streptomycin and 0.5 g of isoniazid were added to the incision. A drainage tube was placed.

2.6. Surgery in the non-NAV group

In the non-NAV group, establishment of the working channel as well as screw and steel plate placement were performed under

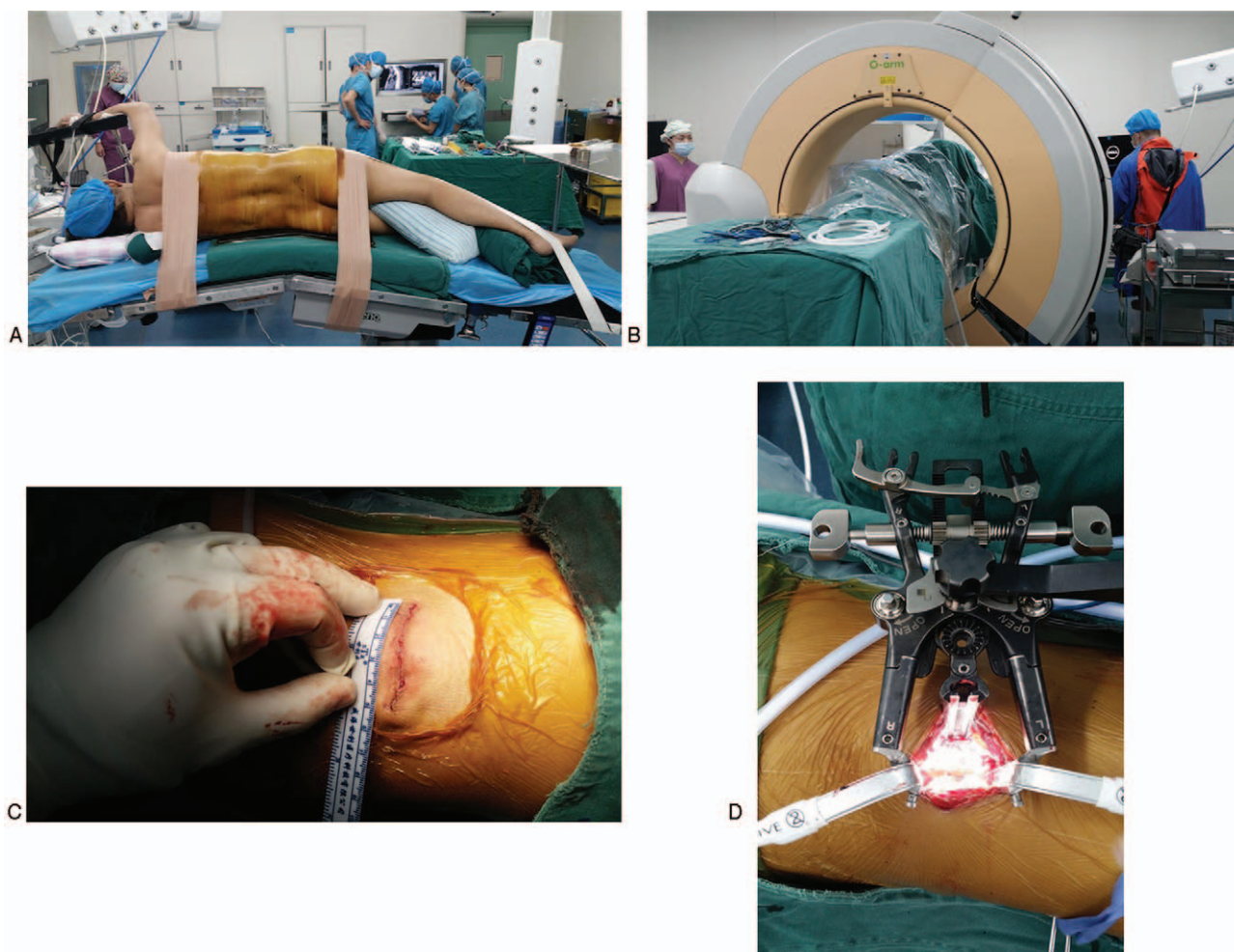


Figure 1. Surgical procedure in the NAV group. (A) 90° lateral position. (B) O-arm three-dimensional scan of the lesion segment after installation of navigation tracers. (C) Surgical incision. (D) After establishing the channel for direct lateral interbody fusion. NAV=navigation.

real-time C-arm fluoroscopy. The methods for lesion debridement and bone grafting were the same as in the NAV group.

2.7. Postoperative management

Cefazolin sodium was routinely administered for 48 hours after surgery. The incision or closed thoracic drainage tube was removed 24 to 48 hours after surgery. The patients attempted to get out of bed and perform walking exercises 3 to 4 days after surgery. A brace was worn routinely for 3 months. The anti-tuberculous treatment was continued for 12 to 18 months.

2.8. Definitions

Surgical preparation time was the period from position fixing to the start of skin incision. Operation time was the period from the start of skin incision to the end of skin suture. Total operation time was the sum of both durations.

2.9. Follow-up

The ESR and liver and kidney functions were reviewed monthly. The patients underwent X-ray and CT examinations at postoperative 1, 3, 6, and 12 months, respectively, as well

at the last follow up to assess bone graft fusion, according to Suk's criteria.^[19] Postoperative complications were observed.

2.10. Statistical analysis

Statistical analyses were performed with SPSS 17.0 for Windows (IBM Corporation, Armonk, NY). Continuous variables were expressed as mean ± standard deviation (SD), and analyzed by Student *t* test. Categorical variables were expressed as frequency and percentage, and assessed by the chi-square test. Two-sided *P* < .05 was considered statistically significant.

3. Results

3.1. Baseline characteristics

At enrollment, there were 47 patients, but 14 were excluded (2 with overt pulmonary tuberculosis, 1 gave up navigation because of navigation error, 3 with multiple segments involved, 3 with severe comorbidity, and 2 in the NAV group and 3 in the non-NAV group were lost to follow-up). Finally, 33 patients were assessed. There were 18 cases in the NAV group, including 10 males and 8 females, aged in average 54.1 (range, 26–85) years. They included one case of L1/2, 6 of L2/3, 5 of L3/4, and 6 of L4/5

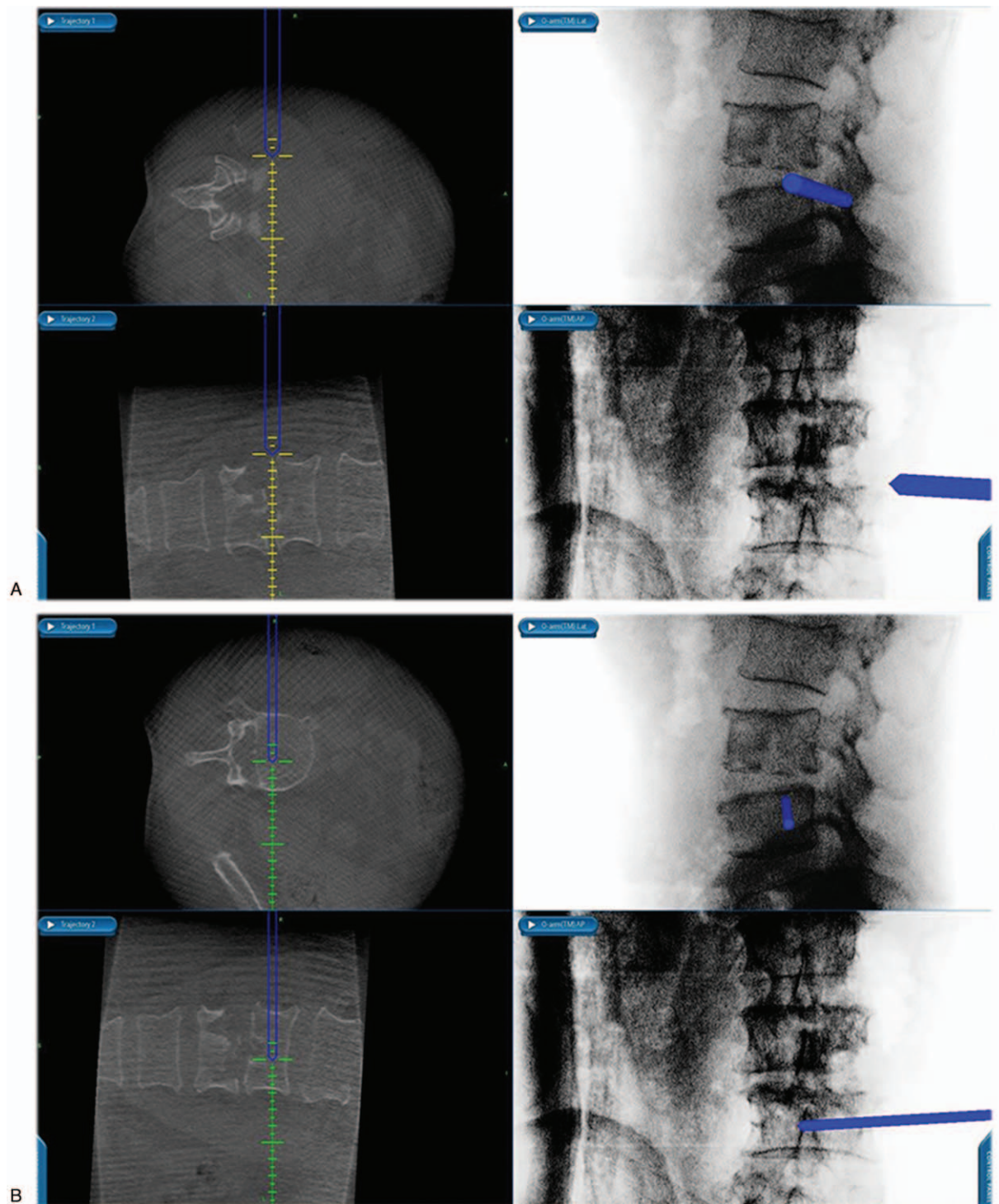


Figure 2. Computer assisted vertebral screw implantation in the NAV group. (A) Puncture for channel installation under the guidance of computer navigation (B) Implantation of vertebral screws under the guidance of computer navigation. NAV=navigation.

involvement. Preoperative ESRs ranged from 35 to 105 mm/h (mean, 82 mm/h). The non-NAV group comprised 15 patients, with seven males and eight females; mean age was 57.6 (range, 30–84) years. There were two cases of L1/2, four of L2/3, 6 of L3/4, and three of L4/5 involvement. Preoperative ESR ranged from 45 to 105 mm/h (mean, 73 mm/h). There were no differences between the 2 groups in baseline characteristics (all $P > 0.05$) (Table 1).

3.2. Operation time and radiation exposure

All surgical procedures were successfully completed (Fig. 3), and no case was converted into open surgery. The NAV group had longer surgical preparation time but shorter operation time, compared with the non-NAV group (both $P < .01$). Total operation time showed no significant difference between the 2 groups ($P = .1$). Radiation exposure time was longer in the non-NAV group compared with the NAV group (53.2 ± 9.9 vs $13.5 \pm$

Table 1
Baseline characteristics in the NAV and non-NAV groups.

Characteristics	NAV (n=18)	Non-NAV (n=15)	P
Age, years	54.1 ± 17.5	57.6 ± 17.9	.6
Gender			.6
Male	10 (56)	7 (39)	
Female	8 (44)	8 (61)	
Location of the lesion			.7
L1/2	1 (6)	2 (13)	
L2/3	6 (33)	4 (27)	
L3/4	5 (28)	6 (40)	
L4/5	6 (33)	3 (20)	
ESR (mm/h)	81.9 ± 17.9	72.7 ± 19.4	.2

Data are expressed as mean ± standard deviation or n (%).
ESR = erythrocyte sedimentation rate, NAV = navigation.

2.6 s, $P < .01$). There were no significant differences in intraoperative blood loss, postoperative drainage volume, and length of hospital stay between the two groups (all $P > .05$) (Table 2).

3.3. Postoperative recovery

All incisions displayed adequate healing in both groups, and no patient suffered from incision-related complications. No patient

Table 2
Surgical conditions in the NAV and non-NAV groups.

Variables	NAV (n=18)	Non-NAV (n=15)	P
Total operation time, min	77.3 ± 1.9	78.9 ± 4.3	.1
Surgical preparation time, min	8.2 ± 1.4	3.7 ± 0.9	<.01
Operation time, min	69.1 ± 1.9	75.5 ± 4.4	<.01
Radioactive exposure time, s	13.5 ± 2.6	53.2 ± 9.9	<.01
Intraoperative bleeding volume, mL	316 ± 65.3	344 ± 48.8	.2
Postoperative drainage volume, mL	222 ± 44.0	224 ± 56.2	.9
Length of hospital stay, days	9.9 ± 1.8	10.1 ± 1.5	.6

Data are expressed as mean ± standard deviation.
NAV = navigation.

suffered from pulmonary infection or respiratory failure. In the NAV group, two patients had anterior numbness of the ipsilateral thigh, and five others felt weak when flexing the hip. In the non-NAV group, two patients had anterior numbness of ipsilateral thigh and 4 patients felt weak when flexing the hip. These patients received physiotherapy, acupuncture, and neurotrophic drugs, and recovered within 1 to 3 months of surgery. At the last follow-up, 12 patients had complete fusion, and 6 showed possible fusion in the NAV group. No patient had loose internal fixation. A total of 10 and 5 patients had complete and possible fusion in

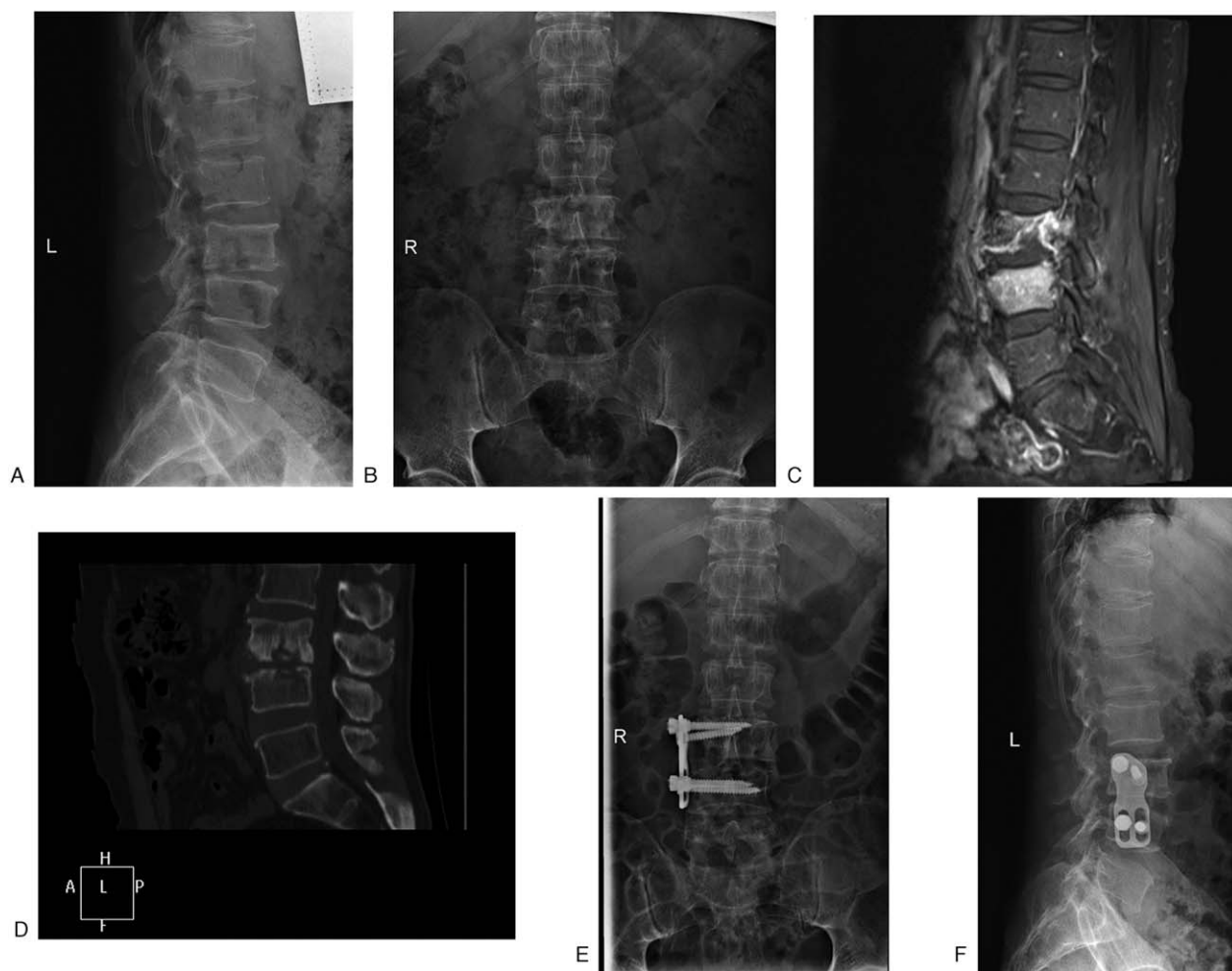


Figure 3. Representative case of a 63-year-old male patient. (A–B) Preoperative X-ray suggested that L3 and L4 had vertebral bone destruction, damaged intervertebral space, and narrowed intervertebral space. (C) Preoperative MR suggested that L3 and L4 had bone marrow edema. (D) Preoperative CT suggested that L3 and L4 had vertebral bone destruction and narrowed intervertebral space. (E–F). Postoperative X-ray suggested adequate position of internal fixation.

the non-NAV group, respectively. No patient had loose internal fixation.

4. Discussion

Surgical treatment of spinal tuberculosis requires complete debridement, interbody fusion, and internal fixation; however, traditional open anterior approach surgery could result in more severe trauma and affect recovery in spine tuberculosis. Minimally invasive surgical treatments of spinal tuberculosis include CT, B-mode ultrasound-guided percutaneous drainage of local abscess, catheter drainage,^[15] thoracoscopy- or laparoscopic-assisted surgery,^[20] channel assisted minimally invasive anterior approach surgery, side approach, and posterior approach surgery.^[21,22]

DLIF is a minimally invasive technique using a channel of the lumbar lateral approach, which passes from the extra-peritoneal psoas to the intervertebral space, in order to complete lesion clearance, intervertebral fusion, and orthopedics. This technique has the advantages of minimal trauma, mild postoperative pain, and fast recovery.^[16] It is mainly applied in lumbar degenerative diseases, intervertebral fusion, and scoliosis.^[23,24] In recent years, this technique has been applied for minimally invasive surgery in lumbar tuberculosis,^[22] with satisfactory results. Nevertheless, as with other minimally invasive techniques for spinal surgery, due to the establishment of small channels, minimal incision, and limited view, the surgical process relies on repeated intraoperative C-arm fluoroscopy in order to ensure channel establishment and the accuracy of screw and cage implantation, avoiding nerve damage and achieving general surgical safety. Thus, this approach greatly increases radiation exposure in both the surgical staff and patients.^[25,26] A previous study confirmed that radiation exposure during spinal surgery is far greater than in limb surgery.^[27] Mainly due to the different fat contents of soft tissues, clear imaging of the spine structure requires larger amounts of radiation than that of limbs.^[27] Similarly, larger amounts of radiation are required for obese patients during intraoperative fluoroscopy.^[28]

The spine structure is complex, and it is adjacent to important nerves and blood vessels. Moreover, spinal variation, deformity, and degeneration are common. Therefore, safety and accuracy in spinal surgery are hardly guaranteed. Since the application of computer navigation in the field of spine surgery, the precision of screw fixation has significantly improved, with reduced intraoperative radiation,^[29–31] which improves the safety of minimally invasive spine surgery. Webb et al^[32] performed a cadaveric study and showed that channel establishment and disc removal times in the fluoroscopy group (19.6 ± 2.5 and 8.4 ± 2.0 min, respectively) are significantly greater than those of the navigation group (15.9 ± 4.1 and 6.0 ± 1.9 min, respectively). Nevertheless, preparation time in the navigation group was longer than that of the fluoroscopy group (5.8 ± 2.7 vs 3.0 ± 0.8 min) and total operation time showed no significant difference between the 2 groups. These findings suggested that computer navigation-assisted DLIF surgery improves accuracy and reduces exposure to radiation. Moreover, operation time was not increased. The present study showed that intraoperative radiation exposure in the NAV group was significantly shorter than that of the non-NAV group, with no significant difference of total operation time between the 2 groups. Nevertheless, some authors claimed that the main disadvantages of computer navigation technology include increased operation time and surgical costs, alongside the long learning curve.^[33] Previous studies demonstrated that if the

computer navigation technique is mastered proficiently, its application in the field of minimally invasive spinal surgery would not increase operation time.^[32,34] In our clinical practice, although it takes some time for the preoperative installation of the reference frame and registration, the surgical preparation time could be significantly reduced if the operator is familiar with the computer navigation technology. Moreover, intraoperative repeated fluoroscopy was not required in the navigation group. Therefore, compared with the conventional fluoroscopy group, who were required to receive repeated anteroposterior and oblique fluoroscopy, time of channel establishment was significantly reduced in the navigation group. The results confirmed that total operation time in the navigation group was not longer than that of the non-navigation group, corroborating previous studies.^[17,18,32,34] Despite the greater accuracy of navigation-assisted minimally invasive surgery, the present and previous studies failed to show improvements in success and outcomes.^[17,18,32,34] Nevertheless, we consider that achieving improved radiological safety is a success in itself. The improved accuracy observed could possibly result in better long-term outcomes; however, since this technology is recent and has been used for a relatively short time, longer follow-up is necessary. The above findings suggested that the NAV approach is superior to the non-NAV method in minimally invasive DLIF for lumbar tuberculosis.

The present study had some limitations. First, the sample size was relatively small, and all patients were from a single center, therefore, larger sample, multicenter trials are required to validate the above findings. Second, computer navigation had the advantages of improving accuracy in spine surgery, but accuracy rates were not compared between the NAV and non-NAV groups. Finally, because of the retrospective nature of this study, we were limited to the data contained in medical charts. In particular, ESR and kidney and liver functions were not consistently available and could not be analyzed.

In conclusion, computer navigation-assisted minimally invasive DLIF could significantly reduce intraoperative radiation exposure, while not increasing total operation time. Additional studies are necessary to examine whether the improved accuracy also results in better long-term outcomes.

Author contributions

Conceptualization: Jianzhong Jiang, Fengping Gan.

Data curation: Jianzhong Jiang, Fengping Gan, Haitao Tan, Zhaolin Xie, Xiang Luo, Guoxiu Huang, Yin Li, Shengbin Huang.

Formal analysis: Jianzhong Jiang, Fengping Gan, Haitao Tan, Zhaolin Xie, Xiang Luo, Guoxiu Huang, Yin Li, Shengbin Huang.

Funding acquisition: Fengping Gan.

Project administration: Fengping Gan.

Writing – original draft: Jianzhong Jiang, Fengping Gan.

Writing – review & editing: Haitao Tan, Zhaolin Xie, Xiang Luo, Guoxiu Huang, Yin Li, Shengbin Huang.

References

- [1] Wu B, Yu Y, Xie W, et al. Epidemiology of tuberculosis in Chongqing, China: a secular trend from 1992 to 2015. *Sci Rep* 2017;7:7832.
- [2] World Health, Organization. Global tuberculosis report 2015. World Health Organization, Geneva:2015.
- [3] Results of directly observed short-course chemotherapy in 112,842 Chinese patients with smear-positive tuberculosis. China Tuberculosis Control Collaboration. *Lancet* 1996;347:358–62.

- [4] Wang L, Zhang H, Ruan Y, et al. Tuberculosis prevalence in China, 1990-2010; a longitudinal analysis of national survey data. *Lancet* 2014;383:2057-64.
- [5] Dye C, Maher D, Weil D, et al. Targets for global tuberculosis control. *Int J Tuberc Lung Dis* 2006;10:460-2.
- [6] Garg RK, Somvanshi DS. Spinal tuberculosis: a review. *J Spinal Cord Med* 2011;34:440-54.
- [7] Rasouli MR, Mirkoohi M, Vaccaro AR, et al. Spinal tuberculosis: diagnosis and management. *Asian Spine J* 2012;6:294-308.
- [8] Gautam MP, Karki P, Rijal S, et al. Pott's spine and paraplegia. *JNMA J Nepal Med Assoc* 2005;44:106-15.
- [9] Jutte PC, van Loenhout-Rooyackers JH. Routine surgery in addition to chemotherapy for treating spinal tuberculosis. *Cochrane Database Syst Rev* 2006;CD004532.
- [10] Five-year assessment of controlled trials of short-course chemotherapy regimens of 6, 9 or 18 months' duration for spinal tuberculosis in patients ambulatory from the start or undergoing radical surgery. Fourteenth report of the Medical Research Council Working Party on Tuberculosis of the Spine. *Int Orthop* 1999;23:73-81.
- [11] Controlled trial of short-course regimens of chemotherapy in the ambulatory treatment of spinal tuberculosis. Results at three years of a study in Korea. Twelfth report of the Medical Research Council Working Party on Tuberculosis of the Spine. *J Bone Joint Surg Br* 1993;75:240-8.
- [12] Pattison PR. Pott's paraplegia: an account of the treatment of 89 consecutive patients. *Paraplegia* 1986;24:77-91.
- [13] Hsu LC, Cheng CL, Leong JC. Pott's paraplegia of late onset. The cause of compression and results after anterior decompression. *J Bone Joint Surg Br* 1988;70:534-8.
- [14] Leong JC. Tuberculosis of the spine. *J Bone Joint Surg Br* 1993;75:173-5.
- [15] Zhang XF, Wang Y, Xiao SH, et al. Treatment of lumbar and lumbosacral spinal tuberculosis with minimally invasive surgery. *Orthop Surg* 2010;2:64-70.
- [16] Ozgur BM, Aryan HE, Pimenta L, et al. Extreme Lateral Interbody Fusion (XLIF): a novel surgical technique for anterior lumbar interbody fusion. *Spine J* 2006;6:435-43.
- [17] Mendelsohn D, Strelzow J, Dea N, et al. Patient and surgeon radiation exposure during spinal instrumentation using intraoperative computed tomography-based navigation. *Spine J* 2016;16:343-54.
- [18] Zhang YH, White I, Potts E, et al. Comparison perioperative factors during minimally invasive pre-psoas lateral interbody fusion of the lumbar spine using either navigation or conventional fluoroscopy. *Global Spine J* 2017;7:657-63.
- [19] Suk SI, Lee CK, Kim WJ, et al. Adding posterior lumbar interbody fusion to pedicle screw fixation and posterolateral fusion after decompression in spondylolytic spondylolisthesis. *Spine (Phila Pa 1976)* 1997;22:210-9.
- [20] Huang TJ, Hsu RW, Chen SH, et al. Video-assisted thoracoscopic surgery in managing tuberculous spondylitis. *Clin Orthop Relat Res* 2000;143-53.
- [21] Karn NK, Rao BS, Prabhakar MM. Minimal invasive anterior decompression in tuberculosis of thoracolumbar junction of the spine-experience with SynFrame. *JNMA J Nepal Med Assoc* 2009;48:262-4.
- [22] Garg N, Vohra R. Minimally invasive surgical approaches in the management of tuberculosis of the thoracic and lumbar spine. *Clin Orthop Relat Res* 2014;472:1855-67.
- [23] Barbagallo GM, Albanese V, Raich AL, et al. Lumbar Lateral Interbody Fusion (LLIF): comparative effectiveness and safety versus PLIF/TLIF and predictive factors affecting LLIF outcome. *Evid Based Spine Care J* 2014;5:28-37.
- [24] Phillips FM, Isaacs RE, Rodgers WB, et al. Adult degenerative scoliosis treated with XLIF: clinical and radiographical results of a prospective multicenter study with 24-month follow-up. *Spine (Phila Pa 1976)* 2013;38:1853-61.
- [25] Abdullah KG, Bishop FS, Lubelski D, et al. Radiation exposure to the spine surgeon in lumbar and thoracolumbar fusions with the use of an intraoperative computed tomographic 3-dimensional imaging system. *Spine (Phila Pa 1976)* 2012;37:E1074-8.
- [26] Uribe JS, Vale FL, Dakwar E. Electromyographic monitoring and its anatomical implications in minimally invasive spine surgery. *Spine (Phila Pa 1976)* 2010;35:S368-74.
- [27] Theocharopoulos N, Damilakis J, Perinakis K, et al. Fluoroscopically assisted surgical treatments of spinal disorders: conceptus radiation doses and risks. *Spine (Phila Pa 1976)* 2006;31:239-44.
- [28] Bindal RK, Glaze S, Ognoskie M, et al. Surgeon and patient radiation exposure in minimally invasive transforaminal lumbar interbody fusion. *J Neurosurg Spine* 2008;9:570-3.
- [29] Nottmeier EW, Bowman C, Nelson KL. Surgeon radiation exposure in cone beam computed tomography-based, image-guided spinal surgery. *Int J Med Robot* 2012;8:196-200.
- [30] Van de Kelft E, Costa F, Van der Planken D, et al. A prospective multicenter registry on the accuracy of pedicle screw placement in the thoracic, lumbar, and sacral levels with the use of the O-arm imaging system and StealthStation Navigation. *Spine (Phila Pa 1976)* 2012;37:E1580-7.
- [31] Gelalis ID, Paschos NK, Pakos EE, et al. Accuracy of pedicle screw placement: a systematic review of prospective in vivo studies comparing free hand, fluoroscopy guidance and navigation techniques. *Eur Spine J* 2012;21:247-55.
- [32] Webb JE, Regev GJ, Garfin SR, et al. Navigation-assisted fluoroscopy in minimally invasive direct lateral interbody fusion: a cadaveric study. *SAS J* 2010;4:115-21.
- [33] Tian NF, Huang QS, Zhou P, et al. Pedicle screw insertion accuracy with different assisted methods: a systematic review and meta-analysis of comparative studies. *Eur Spine J* 2011;20:846-59.
- [34] Sasso RC, Garrido BJ. Computer-assisted spinal navigation versus serial radiography and operative time for posterior spinal fusion at L5-S1. *J Spinal Disord Tech* 2007;20:118-22.