

Inflammation and infection

Scrotal reconstruction on scrotal lymphedema

Gampo Alam Irdam*, Syifa Fadhlly

Department of Urology, Faculty of Medicine Universitas Indonesia, Cipto Mangunkusumo Hospital, Indonesia



ARTICLE INFO

Keywords:

Scrotal
Filariasis
Lymphedema
Reconstruction
Scrotoplasty

Introduction

Filariasis is a tropical disease caused by filarial parasites which is transmitted through mosquito bite. In 2014, this disease infected 1.103 million people in 73 countries at risk of filariasis, accounting for 632 million (57%) of people living in Southeast Asia (9 endemic countries), including the highest endemic location, Indonesia.¹

Case report

We are reporting a case of a 46-year-old man with swelling of the scrotum since 8 years before hospital admission. The enlarged scrotum was as the size of a tennis ball in 2008 and continued to grow and hardened overtime. The presence of pain, pus, history of trauma to the scrotum, difficulty in urination, or loss of body weight were denied. The patient works as a palm plantation inspector, and went out of town frequently and claimed that the swelling first appeared after a trip to Sulawesi. In 2011, the patient was diagnosed with filariasis infection by an internist, treated by taking oral medications for 1 week and was declared healed. Until the hospital admission, the swelling was not reduced. In physical examination, the external genitalia showed a retraction of the penis, enlarged scrotum and was hard on palpation suggesting a scrotal edema and fibrosis, with the size of 15 × 10 × 10 cm. Right and left testicles were difficult to be evaluated (see Fig. 1).

Immunochromatographic Test (ICT) results showed negative findings of filarial parasite. CT-scan and scrotal ultrasonography showed edema of the scrotum with a thickening of a cutaneous-subcutaneous tissue indicating a bilateral scrotal lymphedema. There was also dilatation of the lymphatic ducts, however no sign of filarial dance. The patient was diagnosed with scrotal lymphedema due to filarial infection and was decided to be treated surgically with a scrotoplasty and fibrotic

tissue excision (see Fig. 2).

Incision was made following the marked area, encircling the scrotum, exposing the tunica vaginalis, and continued by tracing it until the funiculus was identified. The urethra was secured by placing a 16 Fr foley catheter followed by scrotal incision. The excised scrotal tissue was sent to histopathology (see Fig. 3).

Postoperative outcome showed the scrotal sac was much reduced. The histopathology examination showed fibrotic tissue with inflammation accompanied with an epidermal cyst. During the 3-month follow up, there was no infection, retraction of the penis or other complication. The patient was satisfied with the surgical results as he claimed to have a better quality of life as well as sexual function.

Discussion

Patient, with a scrotal swelling, suspected to be infected by filarial worms, came to Cipto Mangunkusumo Hospital, to be treated. The huge size of the scrotum was the cause of discomfort for the patient in carrying daily activities, socializing, and impairing his sexual function.

The patient was diagnosed with a scrotal lymphedema due to filarial infection from the information gathered through history taking, where he mentioned that the timing of his growing scrotum occurred just after he went to Sulawesi, which is one of the most endemic region for filariasis.² In the life-cycle, the infective larvae penetrate the human skin and enter the lymphatic system for maturation process to become adult parasites, which takes 3–36 months.^{2–4}

This stage usually can be visualized by detecting the presence of “filarial dance sign” in ultrasonography examination. The adult parasites may live in the lymphatic system for 6–8 years and cause pathologic changes in the lymphatic system.⁵ As they inhibit contractility, and in a course of time, it might develop lymphatic dysfunction that

* Corresponding author.

E-mail address: gampoai@gmail.com (G.A. Irdam).

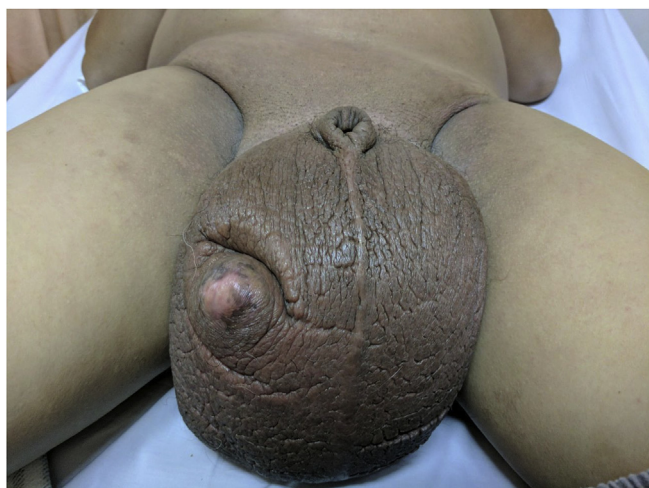

Fig. 1. Pre-operative clinical scrotal appearance.

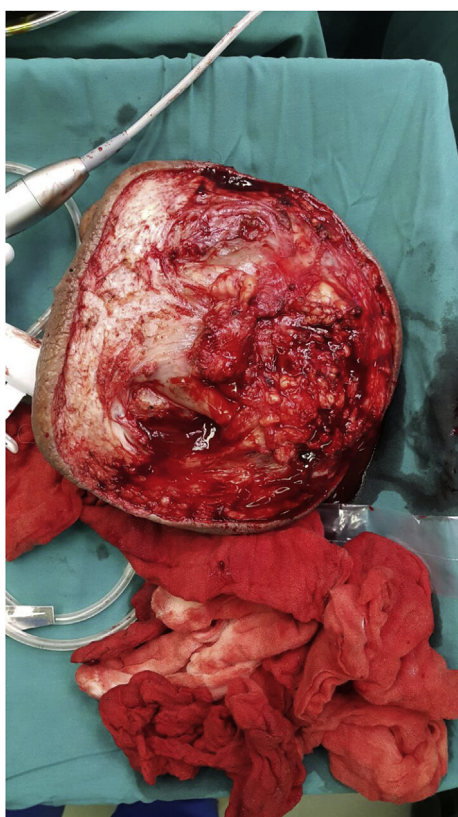


Fig. 2. Excised tissue.

may trigger lymphatic backflow and lymphedema. This is a progressive and irreversible condition even after treatment or death of the filarial parasite. It is also thought that dead parasites activate the host inflammatory response and trigger the progression of lymphatic dysfunction.² This might explain the continuously growing scrotum of the patient as he reported that he had been suffering from scrotal enlargement for 8 years, although he already treated medically.

In the recent ultrasonography examination, no filarial dance sign was found, which most probably an indication that the parasites were already eradicated by the anti-filarial medication given by the internist previously. The ICT test showed similar findings as it showed a negative result. The inflammatory reaction towards the dead parasites was a possible cause of the progressively disabling large size of scrotum.

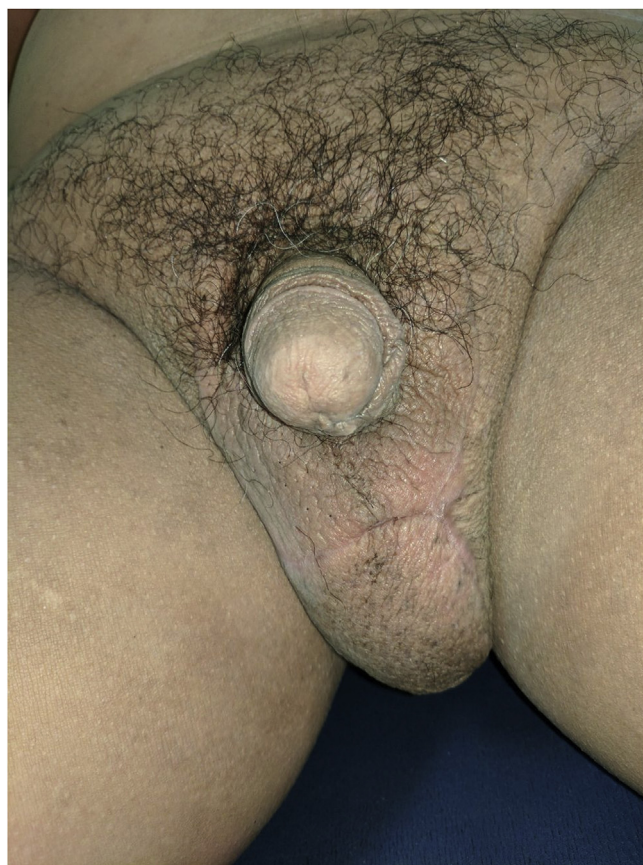

Fig. 3. Post-operative result.

Therefore, as the infection was already treated, the objective of the treatment focused on restoring the patient's quality of life by reducing the size of the scrotum through reconstructive surgery. The basic principle of the surgery is to excise the fibrotic tissue following the shape of the scrotal swelling. It is important to secure the urethra and both sides of the funiculus and testes before doing the tissue excision for an easier execution of the fibrotic remnants. Postoperative outcome showed scrotal sac was much reduced. The patient claimed to be satisfied with the results as he was able to carry daily activities and has better confidence as well quality of life.

In conclusion, although medical treatment is important in eradicating the filarial infection, surgical treatment remains the treatment of choice for scrotal filariasis to reconstruct the disfigurement caused by the lymphedema. Scrotoplasty and fibrotic tissue excision have been reported to be safe and yield good results in the management of scrotal lymphedema due to filariasis and will significantly improve the quality of life of the patient.

Conflicts of interest

The authors declare no conflict of interest.

Acknowledgement

All authors contributed to the creation of and approve the manuscripts.

References

1. Infodatin. Situasi filariasis di Indonesia tahun. *Pusdatin*. 2015;2016.
2. Babu S, Nutman TB. Immunopathogenesis of lymphatic filarial disease. *Semin Immunopathol*. 2012;34(6):847–861.
3. Pfarr KM, Debrah AY, Specht S, Heorauf A. Filariasis and lymphedema. *Parasite*

- Immunol.* 2009;31:664–672.
4. Chakraborty S, Gurusamy M, Zawieja DC, Muthuchami M. Lymphatic filariasis: perspective on lymphatic remodeling and contractile dysfunction in filarial disease pathogenesis. *Microcirculation.* 2013;20(5):349–364. <http://dx.doi.org/10.1111/micc.12031>.
 5. Shenoy RK. Clinical and pathological aspects of filarial lymphedema and its management. *Korean J Parasitol.* 2008;46(3):119–125.