



Contents lists available at ScienceDirect

International Journal of Surgery Case Reports

journal homepage: www.casereports.com

Methods of safe laparoscopic cholecystectomy for left-sided (sinistroposition) gallbladder: A report of two cases and a review of safe techniques[☆]



Constantinos Nastos^{a,*}, Antonios Vezakis^a, Ioannis Papaconstantinou^b,
Theodosios Theodosopoulos^a, Vassilios Koutoulidis^a, George Polymeneas^b

^a Second Department of Surgery, School of Medicine, University of Athens, Aretaieion University Hospital, 76 Vassilisis Sofia's Ave, 11528 Athens, Greece

^b First Department of Radiology, School of Medicine, University of Athens, Aretaieion University Hospital, Athens, Greece

ARTICLE INFO

Article history:

Received 6 July 2014

Received in revised form 15 August 2014

Accepted 19 August 2014

Available online 16 September 2014

Keywords:

Laparoscopic
Cholecystectomy
Left-sided gallbladder
Safe
Technique
Systematic review

ABSTRACT

INTRODUCTION: Left-sided gallbladder is a rare anatomical variation. Usually it is discovered intra-operatively and is accompanied by anatomic variations that can prove quite challenging during laparoscopy.

PRESENTATION OF CASE: From a total of almost 3000 laparoscopic cholecystectomies performed in our institution, two cases of left sided gallbladder were unexpectedly identified intraoperatively. There were no indications for the ectopy preoperatively. In both cases modifications of the standard laparoscopic technique were mandatory. They were performed safely with no post-operative complications. Modifications consisted of transposition of the subxiphoid entry port and alteration in the direction of traction of the rest of the graspers. A review of the literature for methods of safe laparoscopic cholecystectomy was conducted.

DISCUSSION: The surgeon must be aware of the anatomic variances in the rare occasion of a left sided gallbladder, since preoperative diagnosis is very difficult.

CONCLUSION: Knowledge of potential hazards and modifications of laparoscopic technique is mandatory in order to avoid complications.

© 2014 The Authors. Published by Elsevier Ltd. on behalf of Surgical Associates Ltd. This is an open access article under the CC BY-NC-ND license (<http://creativecommons.org/licenses/by-nc-nd/3.0/>).

1. Background

A left-sided gallbladder can either occur as part of situs inversus, or as a true gallbladder malposition. A true malposition of the gallbladder is very rare. Malposition can be either medioposition, or sinistroposition (true left-sided gallbladder). In medioposition, the gallbladder is displaced medially to lie on the undersurface of segment IV but is still on the right side of the round ligament. In sinistroposition, the gallbladder lies under segment III, to the left of the round ligament.¹

Although major issues arise from this anomaly during liver surgery and transplantation, it can cause significant problems, which can lead to complications and morbidity during laparoscopic cholecystectomy, as well, as biliary tract and arterial anomalies are

described in these situations.² It is therefore quite important for the surgeon to be able to recognize this anomaly early, in order to be able to set the laparoscopic ports accordingly and anticipate possible biliary and vascular anatomic variations and prevent complications. We present two cases of patients that were found intra-operatively to have left sided gallbladders during laparoscopic cholecystectomy. After performing a brief review of the literature we propose strategies for intra-operative diagnosis and safe management of this rare entity.

2. Technique presentation

From a total of almost 3000 laparoscopic cholecystectomies performed in our institution during the period 1990–2012, we unexpectedly identified two cases where the gallbladder was situated to the left of the ligamentum teres. Both patients were preoperatively submitted to abdominal ultrasound which revealed gallbladder stones, but no evidence of ectopy, even after post-operative cross-examination of the images (Fig. 1).

After the placement of the trocars the gallbladder was not identified in its usual position, while careful inspection located the gallbladder to the left of the ligamentum teres (Fig. 2a).

[☆] This article is published Open Access at sciencedirect.com. It is distributed under the IJSCR Supplemental terms and conditions, which permits unrestricted non commercial use, distribution, and reproduction in any medium, provided the original authors and source are credited.

* Corresponding author. Tel.: +30 2107286000.

E-mail address: kosnastos@yahoo.gr (C. Nastos).

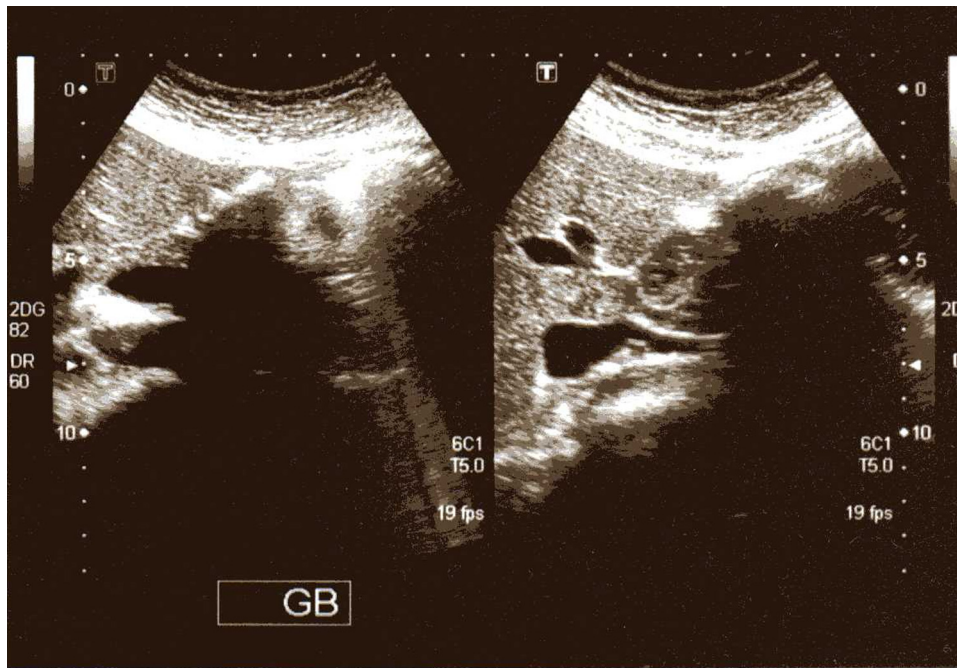


Fig. 1. Case 1: Abdominal ultrasound of the abdomen. Multiple gallbladder stones with extensive acoustic shadowing. Left-sided gallbladder could not be identified.

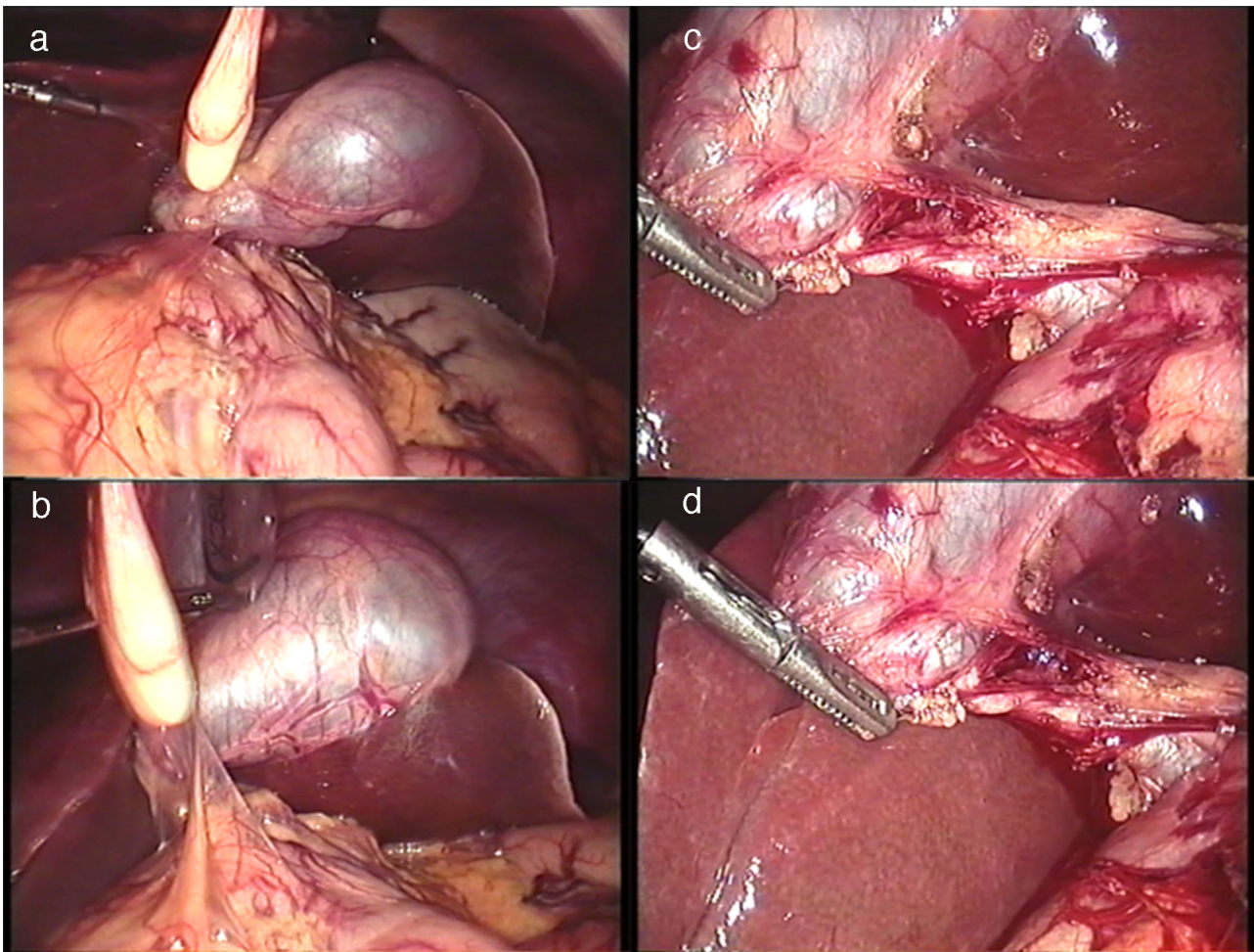


Fig. 2. (a) Case 1: Localization and identification of the gallbladder to the left of the ligamentum teres, under the left hemiliver. (b) Case 1: The subxiphoid port is relocated to the left of the round ligament. The anterior axillary trocar is used to push the fundus of the gallbladder cephalad revealing Calot's triangle. (c) Case 1: Calot's triangle is dissected using the subxiphoid trocar, and the midclavicular trocar is used in order to manipulate Hartmann's pouch. (d) Calot's triangle was dissected revealing a cystic duct entering the common bile duct from the right (white arrow).

The subxiphoid trocar was re-introduced to the left of the round ligament through the same skin incision (Fig. 2b). The right mid-clavicular trocar was passed under the round ligament and was used to retract Hartmann's pouch caudad and medially, while the right anterior axillary trocar was passed under the round ligament and was used to retract the gallbladder fundus cephalad and parallel to the round ligament towards the left clavicle (Fig. 2c). Calot's triangle was dissected revealing a cystic duct entering the common bile duct from the right (Fig. 2d).

Cholecystectomy was carried out with no intra-operative complications.

3. Discussion

3.1. Embryology

Apart from situs inversus, two types of left sided gallbladder exist. In the first place the gallbladder is formed from the hepatic diverticulum normally and after its development it migrates to the left of the ligamentum teres and is attached to the left side of the undersurface of the liver.³ In this case, the cystic duct joins the common bile duct from the right side. The second type of left sided gallbladder is when the hepatic diverticulum does not form a normal gallbladder and an ectopic one is formed originating from the left hepatic duct.²

3.2. Accompanying anatomic anomalies

Left-sided gallbladders have been associated with anomalies of the portal vein, the biliary tract and atrophy of segment IV. Segment IV atrophy has been reported, however there are authors challenging this hypothesis, reporting that segment IV is embedded in the right hemiliver which in turn is relatively hypoplastic. There are no studies addressing possible association with anomalies of the hepatic artery, although in general the artery follows the course of portal vein branches.⁴

However, the cystic artery originating from the right hepatic artery, which lies to the right of the common bile duct, crosses it from right to left to insert on the gallbladder.⁵ An attempt to dissect the cystic artery too close to its origin may lead to common bile duct injury.

Portal vein anomalies have been categorized in three groups. (1) The trifurcation type, (2) the bifurcation type and (3) other variations. Although these variations can be very important in liver surgery and in liver transplantation,⁶ they are of limited interest during laparoscopic cholecystectomy.

However, bile duct anomalies have a major role in the morbidity of cholecystectomy in these patients. There have been reports showing connection of the gallbladder to the right⁷ or left hepatic duct via the cystic duct or accessory bile ducts,^{8,9} or confluence of the common bile duct and the cystic duct from the right or left of the common bile duct.¹⁰ In addition, duplication of the bile duct has been reported in a case report of left sided gallbladder,¹¹ as well as bile duct confluence situated in the umbilical fissure to the left of the umbilical portion of the portal vein.⁵ Moo-Young et al. support that this type of anatomic variation can be quite treacherous in performing laparoscopic cholecystectomy, reporting a very challenging case of common bile duct reconstruction after injury that occurred during laparoscopic cholecystectomy.

3.3. Intra-operative management

A review of the literature was conducted searching PUBMED and SCOPUS electronic databases. A search was made with the keywords "left gallbladder AND cholecystectomy", "left AND cholecystectomy", "left AND gallbladder", "sinistroposition AND

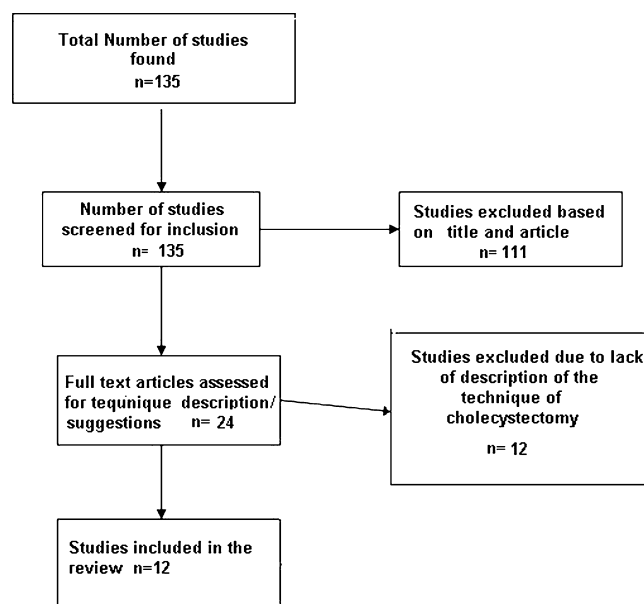


Fig. 3. Flowchart of the literature search according to the PRISMA guidelines.

cholecystectomy", "sinistroposition AND gallbladder" and "sinistroposition AND laparoscopic". Studies reported on patients with true left sided gallbladder (sinistroposition), in the absence of situs inversus, that were operated laparoscopically were included in the review. Studies in languages other than English were excluded. In addition, we excluded studies where there was no full-text available or if there was no description of the technique used. The flowchart according to the PRISMA guidelines is depicted in Fig. 3.

A total of 135 studies were found in our search. Of them 111 were excluded as being irrelevant with our study subject or according to the exclusion criteria. Twenty four studies met the inclusion criteria. Access to full text articles was not available in 6 of these studies. Eighteen studies were finally included and they were fully revised in order to group them according to the laparoscopic technique used. Twelve studies had detailed description of the technique used during the operation.

The feasibility of laparoscopic cholecystectomy has been confirmed in several case reports and small patient series with left sided gallbladder and various laparoscopic techniques have been described in order to facilitate left sided laparoscopic cholecystectomy.^{7,12–23} Wong et al.⁹ suggested that the gallbladder retracting port should be placed more medially and the right-hand operating port should be placed to the left of the midline. He used the falciform ligament as a lift in order to facilitate gallbladder manipulation in accordance to Idu et al. and others.^{10,14,15,17,21,22} This technique can prove to be quite useful, as it does not distort the usual angle used by the instruments to approach the gallbladder and Calot's triangle. However, some of the ports are arranged in different positions than the conventional setup and this can prove to be inconvenient when the trocars have already been placed in the anticipation of a gallbladder in the normal position. Others used a "mirror image" setup compared to classic trocar positioning with the trocars placed to the left of the midline.^{9,18–20,23,24} We believe, that this technique has the disadvantage of performing the operation in a completely different angle than the conventional cholecystectomy technique. This may prove to be dangerous, especially for less experienced surgeons, as this disadvantage is added to the fact that patients with sinistroposition of the gallbladder also have other biliary and vascular anatomic variations. Finally in the mirror image technique the operating room setup should also be re-arranged. Reddy et al.¹ placed the patient in the lithotomy

Table 1
Stratification of studies according to technique used.

Study	Technique used
Matsmura et al. ¹⁸ , Zografos et al. ¹⁹ , Alharthi et al. ²⁰ , Yu et al. ²³ , Wong et al. ⁹	Mirror image port setup—non conventional port entry setup
Reddy et al. ¹⁶ , Kawai et al. ²¹ , Yu et al. ²³ , Donthi et al. ¹³ , Mulvey et al. ¹⁵ , Reddy et al. ¹⁶	Fundus first dissection Placement of additional ports
Hopper et al. ¹⁴ , Mulvey et al. ¹⁵ , Bender et al. ¹⁷ , Kawai et al. ²¹ , Makni et al. ²²	Use of existing port sites with manipulation of falciform ligament
Mulvey et al. ¹⁵ , Reddy et al. ¹⁶ , Zografos et al. ¹⁹ , Yu et al. ²³	Different patient positioning
Bender et al. ¹⁷ , Matsmura et al. ¹⁸ , Alharthi et al. ²⁰ , Kawai et al. ²¹ , Makni et al. ²²	Intra-operative cholangiography

position after the identification of a left sided gallbladder in the supine position, using accessory ports in the left subcostal region in combination with the classic French setup and performing retrograde dissection of the gallbladder. Their technique introduces an additional port and also involves repositioning the patient, which is time consuming.

Matsumura et al.²⁵ used the typical American configuration and performed cholecystectomy normogradely in order to obtain an optimal view of Calot's triangle. In addition he found that a subxiphoid port to the left of the round ligament facilitated manipulation of the gallbladder allowing to relocate the gallbladder to the right of the common bile duct. On the other hand, Reddy et al., as well as others, suggested the use of the antegrade approach in order to well visualize the structures.^{12,16,21,23} The antegrade or normograde approach should alternatively be used according to the operative findings, as is the case in a laparoscopic cholecystectomy for a gallbladder in the normal position. It should really depend on safety considerations and the presence of severe inflammation that does not permit safe identification of structures in Calot's triangle. In any other case, the performance of the "critical view" technique should make the operation safe, without the routine use of a normograde approach.

Finally, Moo-Young et al. suggest that in cases of true left-sided gallbladder identified during cholecystectomy the probability of biliary injury is substantial, especially in the presence of even moderate inflammation. Their recommendation is conversion to open cholecystectomy, or even referral to a tertiary hepatobiliary center after the insertion of cholecystostomy tube.⁵ A stratification of the studies used in this review according to the various techniques proposed are shown in Table 1.

In both our cases the gallbladder was identified as ectopic after all trocars were inserted at the standard sites. According to the experience gained from the above described cases it is our suggestion that elevation of the lower edge of the liver through the subxiphoid port must be performed prior to the insertion of the midclavicular and anterior axillary trocars, in order to verify the usual position of the gallbladder, especially when the fundus is not visible without the above maneuver. If this maneuver fails to identify the gallbladder, the surgeon must attempt to locate it in other usual sites of gallbladder ectopy, including under the left hemiliver. After the localization of the ectopic gallbladder, the midclavicular and anterior axillary trocars should be placed accordingly.

In cases of left sided gallbladder, the subxiphoid trocar should be relocated to the left of the round ligament in order to safely dissect the cystic duct and artery in the hepatoduodenal ligament, avoiding the round ligament, especially when it is enlarged. In both our patients all the trocars had already been placed in the usual positions when we identified the left sided gallbladder. Consequently,

we used the anterior axillary trocar to elevate the fundus of the gallbladder, passing it inferior to the round ligament and pushing the fundus cephalad and parallel to it. Through the midclavicular port the Hartmann's pouch was retracted laterally and caudad in order to pull the cystic duct away from the common bile duct, spreading Calot's triangle. The advantage from this technique is that the surgeon performs the cholecystectomy without major modification to the entry sites of the trocars. Consequently, there is little variation to his usual technique, thus limiting difficulties that can be the result of using a trocar geometry to which he is not accustomed to, as is the case with mirror image trocar placement technique. However, this technique does not overcome the difficulties that might arise from anatomical variation in Calot's triangle. The knowledge and anticipation of these variations are of great importance to the surgeon, in order to identify their existence early and avoid complications.

4. Conclusion

Left sided gallbladder without situs inversus is very rare. Clinical suspicion is of no value, since symptoms and clinical findings are not specific and the radiological exams routinely used fail to depict the anomaly. The ectopy is diagnosed mainly intraoperatively in cases of laparoscopic cholecystectomy. Using specific operative strategies can be the key to a successful and safe management of these patients.

Conflict of interest statement

All authors of this manuscript state that no competing financial interests exist.

Funding

There are no source of funding.

Ethical approval

This is a Case series.

Contributions

NC, VA, PI, and TT contributed to the gathering of the data and information, the preparation of the manuscript, the editing of the laparoscopy images and the review of the literature. KV contributed to the review of the manuscript and the preparation of the radiologic images. PG contributed to the review of the case presentation and the final form of the manuscript.

Key learning points

- Be aware of the gallbladder anatomic variations.
- Think of the rare occasion of a left sided gallbladder.
- Know the potential hazards and modifications of laparoscopic technique.

References

1. Reddy PK, Subramanian RV, Yuvaraja S. Laparoscopic cholecystectomy for left-sided gallbladder (sinistroposition). *JSL: J Soc Laparoendosc Surg/Soc Laparoendosc Surg* 2005;9(3):356–7.
2. Maetani Y, Itoh K, Kojima N, et al. Portal vein anomaly associated with deviation of the ligamentum teres to the right and malposition of the gallbladder. *Radiology* 1998;207(3):723.
3. Gross R. Congenital anomalies of the gallbladder. A review of 148 cases, with report of a double gallbladder. *Arch Surg* 1936;32(1):131.
4. Hsu S, Chen T, Huang T, et al. Left-sided gallbladder: its clinical significance and imaging presentations. *World J Gastroenterol* 2007;13(47):6404.

5. Moo-Young TA, Picus DD, Teeffey S, Strasberg SM. Common bile duct injury following laparoscopic cholecystectomy in the setting of sinistroposition of the galladder and biliary confluence: a case report. *J Gastrointest Surg* 2010;**14**(1):166–70.
6. Hwang S, Lee S, Park K, et al. Hepatectomy of living donors with a left-sided gallbladder and multiple combined anomalies for adult-to-adult living donor liver transplantation. *Liver Transpl* 2004;**10**(1):141–6.
7. Chung CC, Leung KL, Lau WY, Li AK. Ectopic gallbladder revisited, laparoscopically: a case report. *Can J Surg* 1997;**40**(6):464–6.
8. Kanazumi N, Fujiwara M, Sugimoto H, et al. Laparoscopic cholecystectomy for left-sided gallbladder: report of two cases. *Hepatogastroenterology* 2007;**54**(75):674–6.
9. Wong LS, Rusby J, Ismail T. Left-sided gall bladder: a diagnostic and surgical challenge. *ANZ J Surg* 2001;**71**(9):557–8.
10. Idu M, Jakimowicz J, Iuppa A, Cuschieri A. Hepatobiliary anatomy in patients with transposition of the gallbladder: implications for safe laparoscopic cholecystectomy. *Br J Surg* 1996;**83**(10):1442–3.
11. Bender EA, Springhetti S, Shemisa K, Wittenauer J. Left-sided gallbladder (sinistroposition) with duplication of the common bile duct. *JLS: J Soc Laparoendosc Surg/Soc Laparoendosc Surg* 2007;**11**(1):148–50.
12. Schiffino L, Mouro J, Levard H, Dubois F. A case of a left-sided gallbladder treated surgically via laparoscopy. *Ann Ital Chir* 1993;**64**(2):229–31 (discussion 32).
13. Donthi R, Thomas DJ, Sanders D, Schmidt SP. Report of laparoscopic cholecystectomy in two patients with left-sided gallbladders. *JLS: J Soc Laparoendosc Surg/Soc Laparoendosc Surg* 2001;**5**(1):53–6.
14. Hopper N, Ryder JM, Swarnkar K, Stephenson BM. Laparoscopic left hepatic lobe Cholecystectomy. *J Laparoendosc Adv Surg Tech—A* 2003;**13**(6):405–6.
15. Mulvey JM, Laura S, Kelly T. Laparoscopic removal of the left-sided gallbladder. *ANZ J Surg* 2004;**74**(5):390–1.
16. Reddy PK, Subramanian RV, Yuvaraja S. Laparoscopic cholecystectomy for left-sided gallbladder (sinistroposition). *JLS: J Soc Laparoendosc Surg/Soc Laparoendosc Surg* 2005;**9**(3):356–7.
17. Bender EA, Springhetti S, Shemisa K, Wittenauer J. Left-sided gallbladder (sinistroposition) with duplication of the common bile duct. *JLS: J Soc Laparoendosc Surg/Soc Laparoendosc Surg* 2007;**11**(1):148–50.
18. Matsumura N, Tokumura H, Yasumoto A, et al. Laparoscopic cholecystectomy and common bile duct exploration for cholecystocholedocholithiasis with a left-sided gallbladder: report of a case. *Surg Today* 2009;**39**(3):252–5.
19. Zografos GC, Lagoudianakis EE, Grosomanidis D, et al. Management of incidental left-sided gallbladder. *J Soc Laparoendosc Surg* 2009;**13**(2):273–5.
20. Alharthi S, Bernon M, Krige JE. Beware the left-sided gallbladder. *S Afr J Surg* 2012;**50**(3):88–9.
21. Kawai R, Miyata K, Yuasa N, et al. True left-sided gallbladder with a portal anomaly: report of a case. *Surg Today* 2012;**42**(11):1130–4.
22. Makni A, Magherbi H, Ksantini R, Rebai W, Safta ZB. Left-sided gallbladder: an incidental finding on laparoscopic cholecystectomy. *Asian J Surg* 2012;**35**(2):93–5.
23. Yu T, Wu SD, Min L. Incidental left-sided gallbladder during laparoscopic cholecystectomy for cholelithiasis. *Am Surg* 2012;**78**(4):492–3.
24. Donthi R, Thomas DJ, Sanders D, Schmidt SP. Report of laparoscopic cholecystectomy in two patients with left-sided gallbladders. *JLS* 2001;**5**(1):53–6.
25. Matsumura N, Tokumura H, Yasumoto A, et al. Laparoscopic cholecystectomy and common bile duct exploration for cholecystocholedocholithiasis with a left-sided gallbladder: report of a case. *Surg Today* 2009;**39**(3):252–5.

Open Access

This article is published Open Access at sciendoirect.com. It is distributed under the [IJSCR Supplemental terms and conditions](#), which permits unrestricted non commercial use, distribution, and reproduction in any medium, provided the original authors and source are credited.