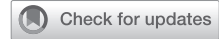

Biatrial drainage of right superior vena cava with left superior vena cava: A diagnostic conundrum



Suneet Bhansali, MD,^a Roi B. Cohen, MD,^b Dan Halpern, MD,^c Sunil Saharan, MD,^a Muhamed Saric, MD, PhD,^c T. K. Susheel Kumar, MD,^d and Ralph S. Mosca, MD,^d New York, NY

From the ^aDepartment of Pediatric Cardiology, ^cLeon H. Charney Division of Cardiology, and ^dDepartment of Cardiothoracic Surgery, NYU Grossman School of Medicine, NYU Langone Health; and ^bDepartment of Internal Medicine, Northwell – Lennox Hill Hospital, New York, NY.

Disclosures: The authors reported no conflicts of interest.

The *Journal* policy requires editors and reviewers to disclose conflicts of interest and to decline handling or reviewing manuscripts for which they may have a conflict of interest. The editors and reviewers of this article have no conflicts of interest.

Drs Bhansali and Cohen contributed equally to this article.

Received for publication Jan 12, 2022; revisions received March 7, 2022; accepted for publication March 30, 2022; available ahead of print April 19, 2022.

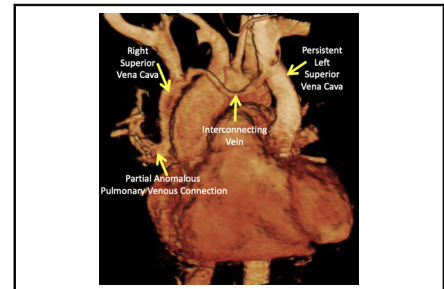
Address for reprints: Suneet Bhansali, MD, Division of Pediatric Cardiology, NYU Grossman School of Medicine, NYU Langone Health, 403 East 34th St, 4th Floor, New York, NY 10016 (E-mail: Suneet.bhansali@nyulangone.org or sabsuneet@gmail.com).

JTCVS Techniques 2022;14:198-200

2666-2507

Copyright © 2022 The Author(s). Published by Elsevier Inc. on behalf of The American Association for Thoracic Surgery. This is an open access article under the CC BY-NC-ND license (<http://creativecommons.org/licenses/by-nc-nd/4.0/>).

<https://doi.org/10.1016/j.jtc.2022.03.020>



Cardiac MRI demonstrating venous anomalies.

CENTRAL MESSAGE

Cardiac MRI plays a crucial role in diagnosing systemic venous anomalies and surgical planning.

▶ Video clip is available online.

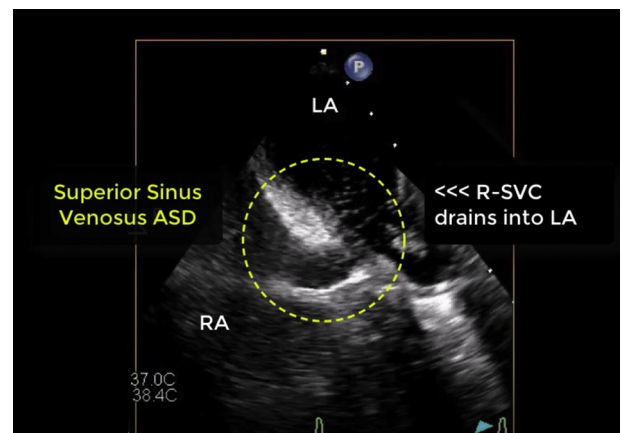
Biatrial drainage of the right superior vena cava (R-SVC) is a rare entity, with fewer than 40 reported cases.^{1,2} There are several anatomical considerations, but only one case with associated persistent left superior vena cava (PLSVC) has previously been reported.¹ When the R-SVC drains into both atria, either due to an abnormal connection, malposition of the atrial septum, or a superior sinus venous atrial septal defect (SV-ASD), it may result in a right-to-left shunt with potentially significant consequences. We herein highlight the challenges associated with diagnosis of biatrial R-SVC drainage in a patient with bilateral superior vena cava (SVC).

CASE REPORT

Consent was obtained to report this case. A 37-year-old man with history of left temporal brain abscess due to *capnocytophaga canis* and *strep intermedius* requiring craniotomy at an outside institution 2 weeks prior presented to our emergency department with aphasia and recurrent brain abscesses prompting further cardiac evaluation. His initial electrocardiogram, radiograph of the chest, and transthoracic echocardiogram were unremarkable except for a dilated coronary sinus, suggestive of a PLSVC. Given

recurrent abscesses and a dilated coronary sinus, a complete congenital heart evaluation was warranted to search for a potential right-to-left shunt.

Transesophageal echocardiogram (TEE) confirmed an enlarged coronary sinus draining into the right atrium (RA) and revealed an SV-ASD shunting predominantly left-to-right (Video 1). Partial anomalous pulmonary



VIDEO 1. Transesophageal echocardiogram demonstrating right arm contrast bubble study with bubbles in the right atrium, coronary sinus and left atrium (Part 1); right superior vena cava connecting to the left atrium (Part 2); and the sinus venous atrial septal defect (Part 3). Video available at: [https://www.jtcvs.org/article/S2666-2507\(22\)00235-8/fulltext](https://www.jtcvs.org/article/S2666-2507(22)00235-8/fulltext).

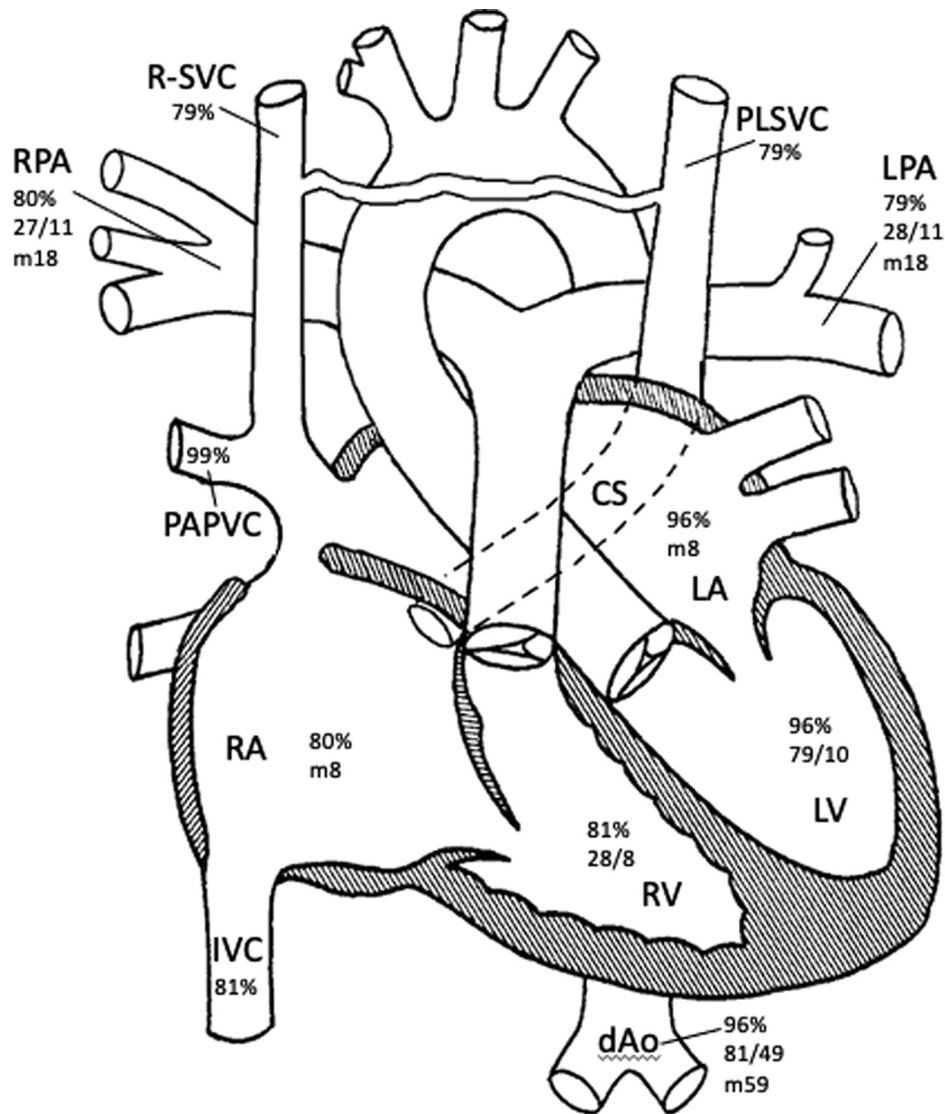


FIGURE 1. Schematic of anatomy with associated oxygen saturations (%), systolic/diastolic, and mean pressures (in mm Hg). *RPA*, Right pulmonary artery; *R-SVC*, right superior vena cava; *PLSVC*, persistent left superior vena cava; *LPA*, left pulmonary artery; *PAPVC*, partial anomalous pulmonary venous connection; *CS*, coronary sinus; *m*, mean pressure; *LA*, left atrium; *RA*, right atrium; *RV*, right ventricle; *LV*, left ventricle; *IVC*, inferior vena cava; *dAo*, descending aorta.

venous connection with right upper pulmonary vein (RUPV) draining into the R-SVC was also noted. A bubble contrast study during the TEE was conducted. Right arm injection showed bubbles in the RA, coronary sinus and left atrium (LA), providing the first clue of anomalous drainage of the R-SVC (Video 1). Left arm injection demonstrated bubbles only in the RA, suggesting an intact coronary sinus (Video 1). Cardiac catheterization demonstrated an R-SVC saturation of 79% without significant step-up in the right heart and LA saturation of 96% (Figure 1). During balloon occlusion of the proximal R-SVC, injection of contrast into the right arm revealed the presence of a 5-mm interconnecting vein allowing for drainage into the RA via PLSVC and

intact coronary sinus. Retrospective review of a previously completed cardiac magnetic resonance study confirmed duplicate SVCs with interconnecting vein (Figure 2). An 11-mm R-SVC inserted into the roof of the LA but drained into the right atrium via the superior SV-ASD. There was also an anomalous RUPV connecting to the base of the R-SVC with flow directed into the LA (Video 2).

The patient was referred for surgery. At surgery, anatomy was confirmed, and the Warden procedure was performed. The R-SVC was transected above the RUPV and reconnected to the RA appendage. The SV-ASD was closed with a patch to allow the RUPV to drain into the LA (Video 2).

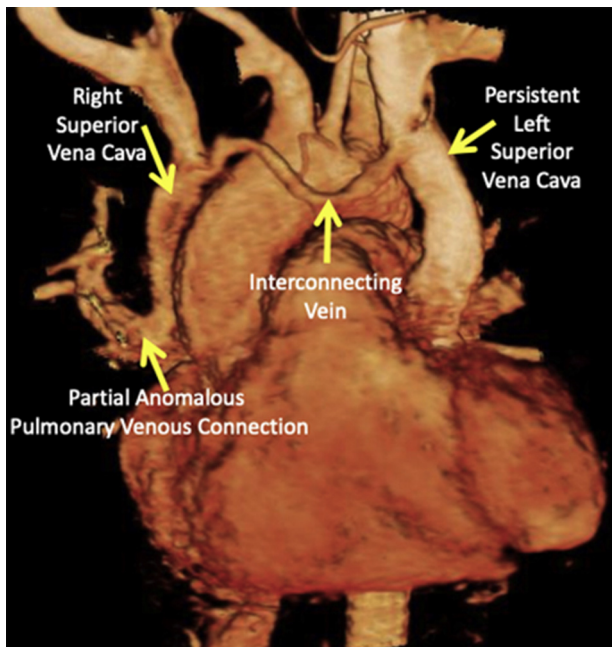


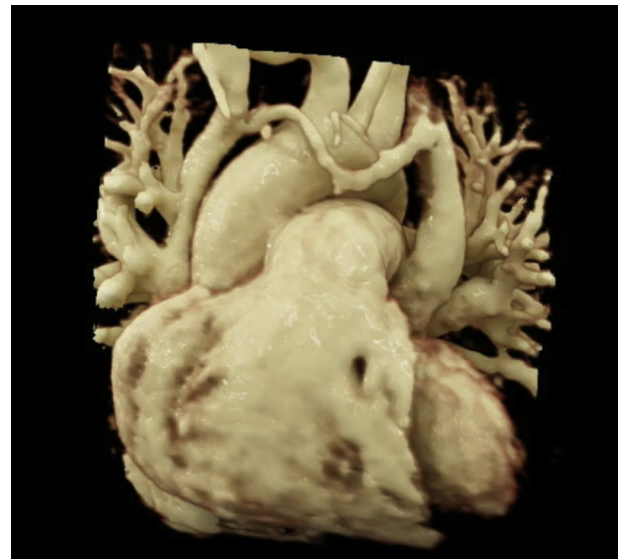
FIGURE 2. Cardiac magnetic resonance imaging demonstrating venous anomalies.

The patient recovered without complications and was discharged home after 5 days. The patient remains well 1-year postsurgery.

DISCUSSION

Bilateral drainage of the R-SVC is a rare condition with potentially significant clinical implications.² Patients may be asymptomatic but cyanosis, mild arterial desaturation, exertional dyspnea, pulmonary emboli, arterial thrombi, stroke, and heart failure have all been attributed to biatrial R-SVC drainage.² Structural variations include anatomically correct R-SVC draining into each atria via separate channels, and an R-SVC connection to both atria in patients with intact atrial septa.²⁻⁴ Biatrial drainage with and without SV-ASDs, and stenosis at the R-SVC and RA junction have also been described.³⁻⁵ Partial anomalous pulmonary venous drainage of the right pulmonary veins is a common association, as seen in our case. An accurate diagnosis before surgery often requires cross-sectional imaging.¹⁻⁴

We describe a unique case of a patient with recurrent brain abscesses and bilateral SVC. Due to unexplained recurrent brain abscesses and dilated coronary sinus, an extensive search for an intracardiac shunt was initiated. In our case, the R-SVC inserted into the LA but biatrial drainage resulted due to shunting across the superior SV-ASD. Correct diagnosis required persistence, familiarity with this entity, and a high degree of suspicion as initial transthoracic echocardiogram only hinted of a PLSVC and the catheterization data demonstrated no significant



VIDEO 2. Cardiac magnetic resonance imaging reconstruction demonstrating presurgical extracardiac anatomy in part 1 and postsurgical anatomy in part 2. *R-SVC*, Right superior vena cava; *PLSVC*, persistent left superior vena cava; *PAPVC*, partial anomalous pulmonary venous connection. Video available at: [https://www.jtcvs.org/article/S2666-2507\(22\)00235-8/fulltext](https://www.jtcvs.org/article/S2666-2507(22)00235-8/fulltext).

intracardiac shunt. The fascinating bubble contrast study, in which subsequent arm injections demonstrated bubbles in contralateral atria, however, suggested the presence of an intracardiac shunt. The final diagnosis was confirmed upon retrospective review of the cardiac magnetic resonance study while keeping in mind the TEE and bubble study findings.

In conclusion, a high degree of clinical suspicion plus optimal imaging is necessary to make the diagnosis of biatrial R-SVC drainage. A thorough evaluation with cross-sectional imaging may allow for accurate diagnosis and precise surgical planning.

References

1. Patel MD, Balasubramanian S, Dorfman AL, Joshi A, Lu JC, Mahani MG, et al. Biatrial drainage of the right superior vena cava: imaging findings. *Radiol Cardiothorac Imaging*. 2020;2:e200414.
2. Van Praagh S, Geva T, Lock JE, Del Nido PJ, Vance MS, Van Praagh R. Biatrial or left atrial drainage of the right superior vena cava: anatomic, morphogenetic, and surgical considerations—report of three new cases and literature review. *Pediatr Cardiol*. 2003;24:350-63.
3. Iwata Y, Kojima A, Nakayama Y, Omoya K, Kuwahara T, Takeuchi T. A case of biatrial drainage of the right superior vena cava. *Asian Cardiovasc Thorac Ann*. 2017;25:292-5.
4. Gazaille RE, Hofelich CS, Zimmerman MJ, Meyers W, Mosali DR. Biatrial drainage of a right-sided superior vena cava. *Radiol Case Rep*. 2015;4:233.
5. Shapiro EP, Al-Sadir J, Campbell NPS, Thilenius OG, Anagnostopoulos CE, Hays P. Drainage of right superior vena cava into both atria. Review of the literature and description of a case presenting with polycythemia and paradoxical embolization. *Circulation*. 1981;63:712-7.