

Vertebral Coplanar Alignment Technique Versus Bilateral Apical Vertebral Derotation Technique in Neuromuscular Scoliosis

Global Spine Journal
2023, Vol. 13(1) 104–112
© The Author(s) 2021
Article reuse guidelines:
sagepub.com/journals-permissions
DOI: 10.1177/2192568221992313
journals.sagepub.com/home/gsj



Karen A. Weissmann, MD^{1,2} , Carlos Barrios, MD, PhD³ ,
Virginie Lafage, PhD⁴, Renaud Lafage, MSc⁴ , Marcelo A. Costa, MD⁵,
Diego Álvarez, MD⁶, Carlos M. Huaiquilaf, MD⁶, Bryan Ang, MD⁷ ,
and Ronald G. Schulz, MD⁵

Abstract

Study Design: Single-center retrospective analysis of prospectively collected data.

Objective: Our aim was to compare the correction capacity in 3 planes of the VCA technique versus the AD technique in neuromuscular scoliosis patients.

Methods: We analyzed patients with neuromuscular scoliosis that underwent posterior spinal fusion from 2013 to 2017 using 2 different techniques for correction: vertebral coplanar alignment (VCA) that takes into consideration the fact that the medial cortex is more resistant than the lateral cortex, with more anchor points for better distribution of forces and ligamentotaxis and the more widely spread apical derotation (AD) technique. Clinical, surgical, and radiographic information of patients operated on with the AD technique were compared to those operated on with the VCA technique in the coronal, sagittal and axial plane at pre-op, immediate post-op, and 2 year follow-up.

Results: 64 patients met inclusion criteria, 34 patients underwent the VCA technique and 30 patients underwent the AD technique. The 2 cohorts did not differ in terms of demographics, clinical presentation or preoperative alignment. There were no significant differences in the correction ability between both techniques regarding curve magnitude, apical vertebral rotation, or pelvic obliquity. There was a significant decrease in thoracic kyphosis in the AD group compared to the VCA group in the immediate postop period ($4.2 \pm 26.6^\circ$ for VCA and $13.2 \pm 21.3^\circ$ for AD ($p = 0.048$)).

Conclusion: Both apical derotation technique and vertebral coplanar alignment allow for correction in the 3 planes for patients with neuromuscular scoliosis. VCA is a less hypokyphosing technique than AD.

Keywords

vertebral coplanar alignment, apical derotation, neuromuscular scoliosis

¹ School of Doctorate, Valencia Catholic University Sant Vincent Martyr, Valencia, Spain

² Department of Orthopedics and Traumatology, University of Chile, San Miguel, Región Metropolitana, Chile

³ Institute for Research on Musculoskeletal Disorders, Valencia Catholic University Sant Vincent Martyr, Valencia, Spain

⁴ Department of Orthopedic Surgery, Hospital for Special Surgery, New York, NY, USA

⁵ Redsalud, Santiago, Chile

⁶ Hospital Exequiel González Cortés, Redsalud, Santiago, Chile

⁷ Weill Cornell School of Medicine, New York, NY, USA

Corresponding Author:

Karen A. Weissmann, MD, School of Doctorate, Valencia Catholic University Sant Vincent Martyr, Valencia, Spain; Department of Orthopedics and Traumatology, University of Chile, Area Sur. Gran Avenida Jose Miguel Carrera, 3100, San Miguel, Región Metropolitana, Chile.

Email: kweissmann@mail.ucv.es; kweissmannm@uchile.cl



Creative Commons Non Commercial No Derivs CC BY-NC-ND: This article is distributed under the terms of the Creative Commons Attribution-Non Commercial-NoDerivs 4.0 License (<https://creativecommons.org/licenses/by-nc-nd/4.0/>) which permits non-commercial use, reproduction and distribution of the work as published without adaptation or alteration, without further permission provided the original work is attributed as specified on the SAGE and Open Access pages (<https://us.sagepub.com/en-us/nam/open-access-at-sage>).

Introduction

Patients with neuromuscular deformity represent a challenging population to treat. As such, determining the correct surgical plan can oftentimes be complex given the multitude of variables to consider, ranging from clinical (i.e. ventilatory function, comorbidities) to biomechanical (i.e. pelvic obliquity, curve magnitude and rigidity, bone quality, sitting balance).^{1,2} Currently, no clear patterns of neuromuscular curvatures have been described in the literature and there remains a lack of consensus on the best technique to achieve a balanced posture.

In the setting of neuromuscular scoliosis, a surgeon has multiple corrective techniques at his or her disposal to select from. The use of traction, either preoperatively or intraoperatively, has been previously reported in patients with high grade curves.³ Combined approaches have a role in correction when treating patients with rigid curves⁴ and permit better control of pelvic obliquity; however, they are also associated with increased OR time and EBL.³ The posterior-only approach on the other hand has been associated with fewer complications and thus remains the preferred technique for a majority of spine surgeons.

Suk et al. first brought attention to 3-dimensional correction for adolescent idiopathic scoliosis in 2011 with his description of the apical derotation technique in achieving vertebral derotation.⁵ This technique takes advantage of long screws and aims at manipulating and translating the vertebrae anteriorly. The derotation torque is applied at the same time to both sides of the vertebra, forcing its position against the convexity. Although not specifically indicated, this technique has successfully been applied in the treatment of neuromuscular scoliosis as well¹

Another strategy for 3D correction is the vertebral coplanar alignment (VCA) technique, which takes into consideration aspects of vertebral anatomy that the apical derotation techniques does not. Because the medial cortex of the vertebral body is wider and more resistant than the lateral cortex,² this allows for more anchor points during derotation for a better distribution of forces. Furthermore, VCA takes advantage of the fact that children have stronger ligaments and more elastic bones by relying on this strong attachment to guide correction.³ By relocating the normal coplanar axis into a single plane, translation and derotation can be achieved in one gesture.⁴

Aim

The objective of this study was to compare the 3D corrective ability of the vertebral coplanar alignment (VCA) technique with that of the apical derotation (AD) technique in the setting of pediatric patients with neuromuscular scoliosis.

Material and Method

Study Design

Following approval by the institutional review board (IRB), a retrospective analysis of prospectively collected data was

performed on patients with neuromuscular scoliosis that underwent posterior spinal fusion at our hospital from 2013 to 2017. Inclusion criteria consisted of neuromuscular scoliosis or collagenopathy patients, age 25 or younger, who underwent a posterior-only approach. Exclusion criteria included patients who underwent revision surgery as well as the presence of any growing rods. All procedures were performed by the same surgeon.

Data Collection

Demographics such as age, gender, diagnosis, and comorbidities were collected from the electronic medical records. Full length radiographs were collected in anteroposterior (AP), lateral, traction, and bending films at preop, in the immediate postoperative period and at 2-year follow-up. Coronal plain films were used to determine each patient's Risser classification, coronal Cobb angle for each curve (proximal thoracic [PT], thoracic/thoracolumbar [T/TL], and lumbar curve⁶), pelvic obliquity (defined as the angle between both iliac crests and the horizontal) and apical vertebral rotation (AVR) as measured by the Raimondi method.⁷ Sagittal parameters included cervical lordosis (CL), thoracic kyphosis (TK), lumbar lordosis (LL), sacral slope (SS), pelvic incidence (PI), pelvic tilt (PT), sagittal vertebral axis (SVA), T9 spino-pelvic inclination (T9Spi) for evaluation of the gravitational center, and T1Spi for assessment of global sagittal alignment. All measurements were performed using Surgimap 2.2.14 (Nemaris Inc, New York, NY). Flexibility of the main curve was assessed on traction and bending x-rays; the coronal surgical correction of the main curve was evaluated by the pre- to post changes in Cobb angles as well as the difference between bending/traction Cobb angles and the corresponding postoperative Cobb angle.

Preoperative Evaluation

Preoperative cardiopulmonary status of these patients were assessed by a cardiologist with a bidimensional echocardiogram and by a pulmonologist with spirometry when possible. The American Society of Anesthesiologist (ASA) Physical Status classification system was used to further characterize each patient's operative risk.⁸ Anesthesia protocol consisted of total intravenous anesthesia (TIVA). No pre-operative traction was used in these patients.

Surgical Technique

Under Neuromonitoring and radioscopy, patients were first positioned prone on the operating table. A total facetectomy was then performed to help in freehand screw placement.⁹ Screws were either in an "all-screws" construct, or in a "zigzag" distribution (i.e. 4 screws at both ends of the construct, then one screw per vertebra on alternate pedicles). Osteotomy types ranged from Schwab type 2 to 5.¹⁰ Patients were assigned to 1 of 2 surgical techniques (apical derotation or vertebral coplanar alignment technique) by osteosynthesis

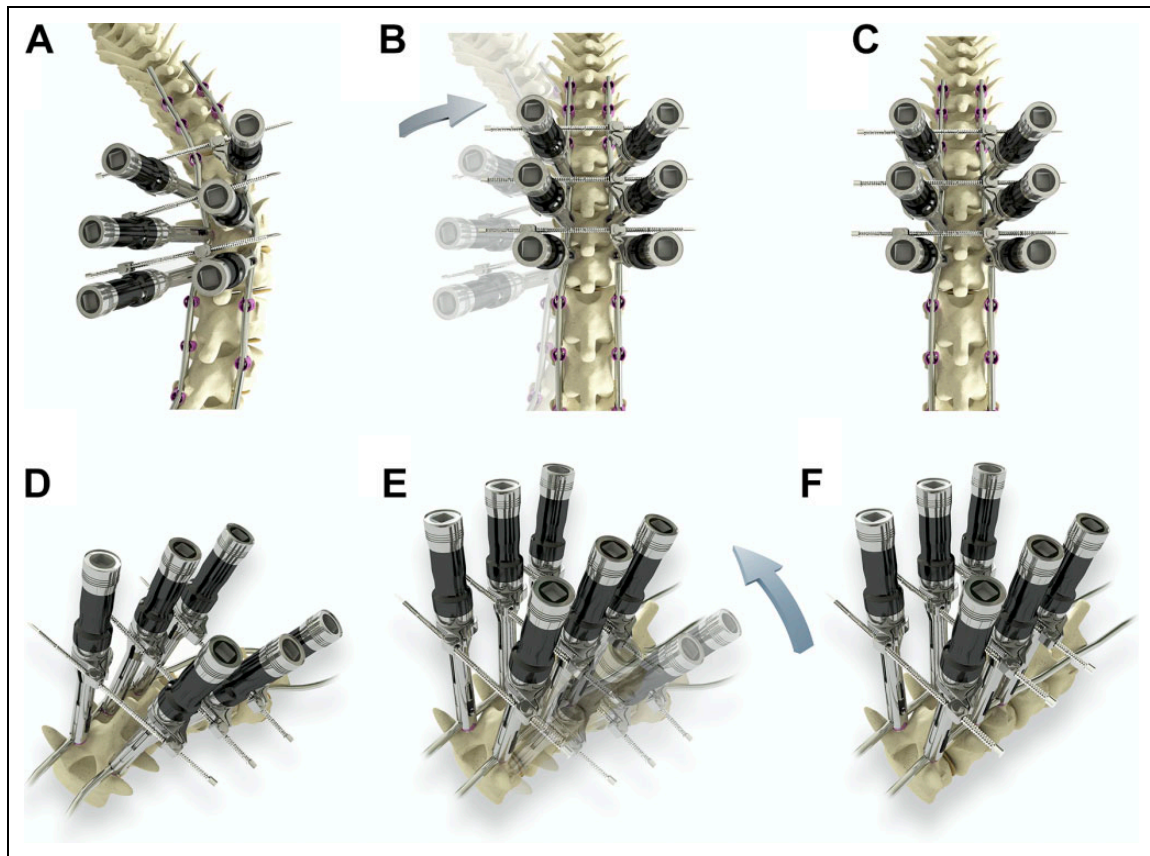


Figure 1. Maneuvers of the Apical Derotation Technique (AD). a: After rod placement, tubes are placed on the apical vertebrae both in the convexity and the concavity; b: bilateral derotation of the apical vertebrae toward the convexity is performed; c: final position of the spine where the inners are tightened; d: Oblique view of the spine with apical tubes; e: derotation maneuver in oblique view. f: final position of the spine in oblique view.

material availability. Both techniques have been described in the literature.^{5,11} The apical derotation technique (AD) consisted of bilateral rotation of the apical vertebrae toward the convexity, after the rods have been already placed, addressing only the apex of the deformity (Figure 1),¹² while the vertebral alignment technique (VCA) aimed at providing a simultaneous 3D correction by inserting a pre-bent rod through pre-aligned slotted tubes (Figures 2 and 3). For grafting, osteoconductors and local bone were used. Wound closure was performed in 4 stages; drains were placed deep and superficial when an osteotomy was performed and only superficial when the spinal canal was left intact.

Post-Operative

All patients remained at least 24 hours in a critical care unit, with patient controlled analgesia (PCA). Those undergoing simultaneous cord de-tethering remained in mechanical ventilation for 24 to 48 hours in order to avoid Valsalva maneuvers. Patients were administered antibiotics for the duration that they had a drain in place. Patients were discharged when no opioids were required for analgesia.

Statistical Analysis

Descriptive statistics were used to describe overall demographic, surgical, and radiographic metrics for both cohorts. The distribution of the parameters was then evaluated with a Kolmogorov-Smirnov test, and the 2 groups were compared using either unpaired t-test or Mann-Whitney U test as appropriate. Operative data such as numbers of levels fused, surgical time, estimated blood loss, hardware material, and neuromonitoring was collected and compared between derotation techniques. Use of a drain, length of stay, and discharge location were also compared using Chi-square and Fisher exact test. Correction potential for each technique was compared using the same process previously described. Loss of correction at 2 year follow-up was also assessed between the 2 techniques by subtraction of the 2 year follow-up value from the immediate postoperative value for coronal, sagittal and axial parameters. Finally, a sub-analysis to determine the ability to maintain kyphosis was done by stratifying the patient's preoperative thoracic kyphosis in 3 groups ($< 20^\circ$, $20\text{-}50^\circ$, $> 50^\circ$) and evaluating the difference between pre and post-operative kyphosis. Statistical analysis was performed using SPSS 20.0 (IBM, Chicago, IL, USA) and $p < 0.05$ was considered statistically significant.

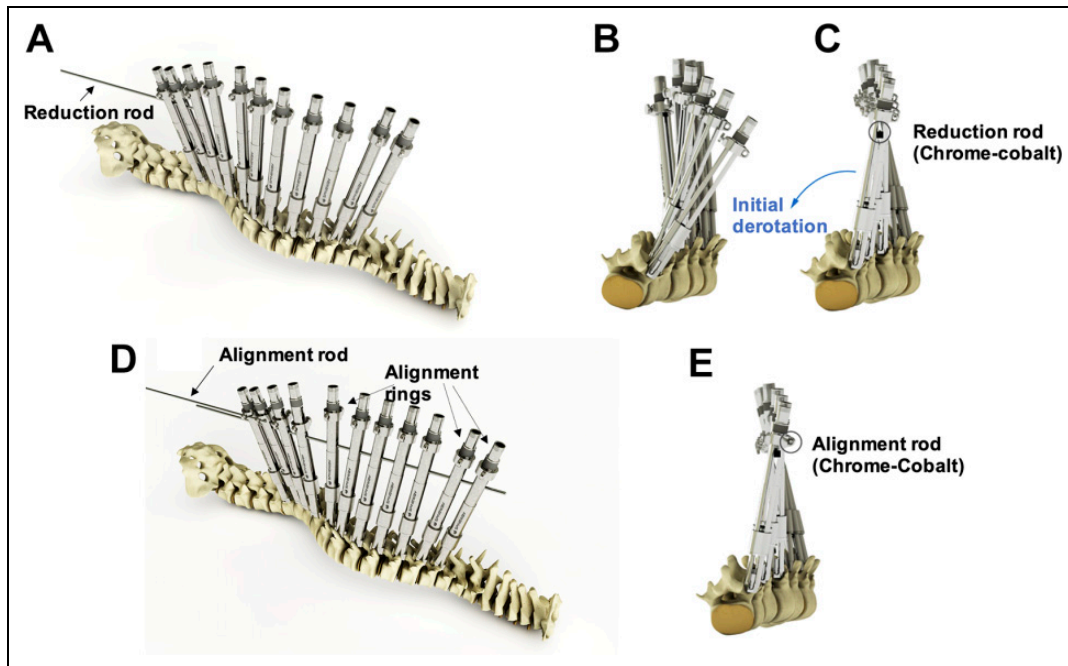


Figure 2. Maneuvers of the Vertebral Coplanar Alignment (VCA). a: Detail of the insertion of the first rod (reduction rod) into the slotted tubes for alignment of the upper end of the tubes; b: axial view before insertion of the reduction rod; c: An initial derotation of the vertebral bodies is obtained once the insertion of the reduction rod is completed; d: insertion of the alignment rod into the lateral alignment rings; e: axial view of the final configuration.

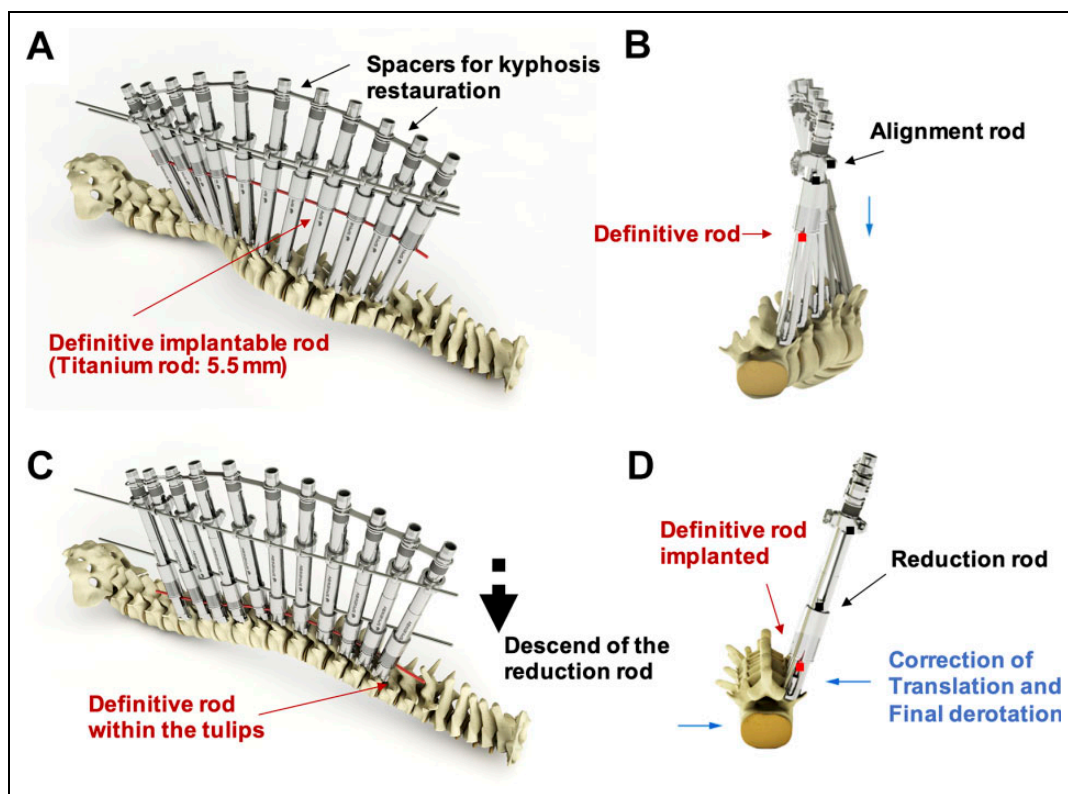


Figure 3. a: restoration of the physiologic kyphosis by spreading the distal ends of the tubes in the thoracic spine using different-sized spacers; the definite implantable rod is inserted below the reduction cylinders; b) axial view of the construct; c) progressive descend of the rods by pushing down the reduction rod; when the definite rod is located within the tulips, all pedicles are aligned in the same plane; d: axial view after the descend of the definite rod that permit correction of spine translation and final derotation.

Results

Preoperative Evaluation

Out of the 64 patients included, 40 were females, with a mean age of 15 years old (8 to 25 years old). The most common diagnosis was Cerebral Palsy (N = 20) (Table 1). Comorbidities were present in 94.1% of patients in the VCA group with a mean of 2.5 comorbidities per patient, and 96.5% for the apical derotation with a mean of 3.8 comorbidities per patient (p = 0.015). On average, patients in the VCA group were 10 kg heavier (p = 0.025) than those in the AD group. There were no other significant differences in demographics or preoperative lab values between cohorts (Table 2).

Table 1. Distribution of Neuromuscular Diseases.

Diagnosis	VCA	AD	
Neuropathics	n (%)	n (%)	total
<i>First Motoneuron</i>			
Cerebral palsy	11	9	20
Chiari type I	2	2	4
Siringomyelia	2	1	3
Intradural tumors	2		2
Spinocerebelar ataxia		1	1
Spinal cord trauma	1	1	2
<i>Second Motoneuron</i>			
Charcot-Marie-Tooth		1	1
Spinal atrophy type II	1	2	3
Congenital hypophonia	2	4	6
Mixed			
Tetherd cord	1	1	2
Myelomeningocele	3	5	8
Myopathic			
Duchenne syndrome		1	1
Central core disease	1		1
Syndromic			
Marfan syndrome	1	2	3
Ehler-Danlos syndrome	4	3	7

VCA indicates vertebral coplanar alignment; AD, apical derotation.

Table 2. Demographics, Anthropometric Prolife, and Preoperative Characteristics of the 2 Groups.

Characteristic	Coplanar n = 34	AD n = 30	p-value
Age (years)	15.65	14.67	0.285
Sex (F/M)	22/12	18/12	0.703
Height (cm)	150 ± 17	145 ± 18	0.398
Weight (kg)	50.5 ± 17	40.7 ± 13	0.020
Menarche (age)	13	12.6	0.361
Perinatal comorbidities (%)	23.5	44.8	0.064
Comorbidities (n°/patient)	2.5	3.8	0.015
Active ambulatory status (%)	73.5	51.7	0.063
Previous use of brace (%)	32.4	33.3	0.935
ASA I, II, III (%)	26.5/55.9/17.6	23.3/53.3/23.3	0.487
Risser (mean)	3.50	3.17	0.801

VCA indicates vertebral coplanar alignment; AD, apical derotation; ASA, American Society of Anesthesiology Physical Classification System.

Preoperative Radiographic Presentation

The highest magnitude curve had a mean Cobb angle of 64.8 ± 24.6° for VCA and 66.9 ± 26.9° for the AD group (p = 0.758). The AVR of this curve was 19.2 ± 13.7° for the VCA group and 18.6 ± 11.2° for the AD group (p = 0.878). The AD group had a significantly larger (p = 0.036, Table 2) but less rigid (Table 3) proximal thoracic curve. The AD group had significantly higher values for PI and SS than the VCA group (Table 2).

Clinical and Surgical Outcomes

The average number of levels instrumented was 12.56 for the coplanar group, and 13.53 for AD group (p = 0.229). Surgical time did not differ between the groups and averaged 198.4 minutes for the VCA, and 203 minutes for the AD (p = 0.384). There was no significant difference in the type of rod material used, type of screw placement, number and type of osteotomy, or additional maneuvers between the 2 groups (Table 4). Two patients in the coplanar group and 6 in the apical derotation group underwent detethering during surgery. There were no dural fistulas in these patients.

The estimated blood loss (EBL) was 938.9 mL with a maximum of 4,000 mL. There was no significant difference between the surgical techniques in terms of EBL (1,041 mL in VCA, and 827 mL in AD group, p = 0.265), postoperative hematocrit/hemoglobin, number of transfusions needed, or use of vasoactive drugs (Table 5).

Analysis of neuromonitoring revealed that 74% of patients in the coplanar and 50% in the Apical derotation group had normal baseline motor and Somatosensitive evoked potentials. VCA had 3 intraoperative neuromonitoring alerts, while AD had 7 alerts (p = 0.106); these alerts resolved before the end of the surgery with a mild decrease in correction maneuvers. One case in the AD group had postoperative unilateral paresis that resolved 3 weeks after the surgery.

Drains remained for 3.5 days in the VCA group and 2.9 days in AD groupe (p = 0.169). Drain output for both groups was not statistically different (p = 0.305) with 452.4 mL for VCA patients and 352.07 mL for AD.

Averaged hospitalization time was 10.5 days; there was no significant difference between both groups regarding length of stay (p = 0.789 for ICU (Intensive care unit), p = 0.928 for ITU (Intermediate care unit), p = 0.518 for MQ (Medico-surgical)) (Table 5).

At 2 year follow-up, the difference in weight was maintained (p = 0.025).

Post-Operative Alignment

The analysis of the pre to post changes (i.e. correction) by group revealed significant differences in coronal alignment except for pelvic obliquity for both groups (p = 0.056 for VCA, and p = 0.109 for AD) and AVR of the proximal and distal curves for the VCA group. At immediate post-op (Table 6), the

Table 3. Preoperative Radiological Parameters for the Coplanar (VCA) and Apical Derotation (AD) Groups.

		Preop		p value*
		VCA mean \pm SD	AD mean \pm SD	
Major Curve	Coronal Cobb**	64.8 \pm 24.6	66.8 \pm 26.9	0.758
	Max Bending	60.7 \pm 27.3	51.3 \pm 29.1	0.346
	Bending Flexibility	6.6 \pm 18.5 (7%)	16.1 \pm 12.7 (29%)	0.076
	Max Traction	54.1 \pm 25.3	47.2 \pm 27.0	0.455
	Traction Flexibility	18.4 \pm 13.6 (26%)	19.4 \pm 11.7 (33%)	0.828
	Max Rotation	19.2 \pm 13.7	18.6 \pm 11.2	0.878
Sagittal profile	Pelvic Obliquity	7.7 \pm 9.4	12.5 \pm 21.1	0.879
	Thoracic Kyphosis	37.3 \pm 28.5	45.6 \pm 28.4	0.290
	Lumbar Lordosis	56.4 \pm 19.7	52.5 \pm 20.2	0.472
	Sacral Slope	33.9 \pm 9.1	39.2 \pm 10.5	0.050
	Pelvic Incidence	46.2 \pm 11.5	57.3 \pm 18.5	0.008
	Pelvic Tilt	13.2 \pm 9.9	16.2 \pm 12.9	0.390
	SVA	29.4 \pm 34.2	23.1 \pm 45.2	0.592
	T9Spi	11.8 \pm 10.3	11.1 \pm 12.1	0.834
	T1Spi	2.7 \pm 6.1	1.3 \pm 7.0	0.444

*unpaired t-test **Cobb: Highest magnitude curve, Max Rotation: Apical vertebral rotation for the curve with the biggest magnitude, Max Bending and MaxTraction: Dynamic measures for the biggest curve magnitude, used to determine curve flexibility. VCA indicates vertebral coplanar alignment; AD, apical derotation.

Table 4. Additional Surgical Tools Used in the 2 Groups.

Technique	VCA	Apical Derotation	p value*
Rod (%)	Ti:62	Ti:47	0.440
	Mixed: 2.9	Mixed: 6.7	
	CrCo:35.1	CrCo:46.3	
Screw Placement (%)	All Screws: 32.4	All Screws: 20	0.512
	ZigZag: 67.7	ZigZag: 80	
Osteotomies (%)	Schwab 2: 32.3	Schwab 2: 33	0.386
	Schwab 3: 8.8	Schwab 3: 3.3	
		Schwab 5: 3.3	
		Schwab 6: 3.3	
Compression and Distraction (%)	Concavity Distraction: 29.4	Concavity Distraction:10	0.323
	Convexity Compression:5.8	Convexity Compression:3.3	
	Both:23.5	Both:36.7	
	End gesture:20.6	End gesture: 20	
	No gesture:20.6	No gesture:30	

*Chi-square test.

VCA indicates vertebral coplanar alignment; AD, apical derotation.

maximum Cobb angles were corrected by $34.6 \pm 13.2^\circ$ for the VCA and $33.2 \pm 15.6^\circ$ for AD patients ($p = 0.721$), AVR correction was $7.8 \pm 14.4^\circ$ in the VCA group and $7.1 \pm 11.8^\circ$ for AD ($p = 0.335$). There were no significant differences in the correction ability between both techniques for each curve regarding curve magnitude, AVR or pelvic obliquity ($p = 0.978$). In the sagittal plane, there was a significant difference in the amount of flattening of the thoracic kyphosis in the immediate post-op period, with the VCA group losing $4.2 \pm 26.6^\circ$ and the AD losing $13.2 \pm 21.3^\circ$ ($p = 0.048$). At 2 year follow-up, the AD group lost significantly more correction than the VCA for this parameter ($p = 0.046$). The rest of the correction in the sagittal parameters was not significant

between the 2 techniques. The stratification by preoperative thoracic kyphosis revealed no significant changes in thoracic kyphosis for the hypokyphotic ($<20^\circ$) and normokyphotic curves ($20-50^\circ$), whereas the hyperkyphotic patients ($>50^\circ$) had a significant flattening of thoracic-kyphosis at immediate postop (50.2%, $p = 0.000$). There was a significant correlation between preoperative kyphosis and correction percentage ($p = 0.000$, RR 0.763) for the whole cohort, as well as for both groups individually (VCA: $p = 0.000$, RR 0.841, AD: $p = 0.000$, RR = 0.665). The analysis of maintenance of correction at 2-years (50% follow-up) demonstrated a small but significantly greater loss of thoracic kyphosis for the AD group (3.7° vs -1.8° , $p = 0.046$).

Table 5. Intra and Postoperative Parameters of the 2 Groups.

Parameter	VCA	Apical Derotation	p value*	p value**
Bleeding (ml)	1040.9 ± 772.9	826.7 ± 519.6	0.265	
Post op Ht (%)	28.5 ± 5.0	28.9 ± 4.7	0.777	
Post op Hb (grs/dl)	10.0 ± 1.6	9.8 ± 1.8	0.585	
RBC transfusions (%patients)	86.4	86.4		0.681
Platelet transfusion (%patients)	50	37.5		0.415
Plasma transfusions (%patients)	76.9	60		0.635
Drain (days)	3.5 ± 1.3	2.9 ± 1.5	0.237	
Discharge Ht (%)	29.5 ± 3.6	30.6 ± 4.5	0.393	
Discharge Hb (grs/dl)	10.4 ± 1.3	13.7 ± 15.8	0.682	
ICU (days)	4.1 ± 7.2	2.7 ± 2.0	0.789	
ITU (days)	2.8 ± 4.8	1.6 ± 1.3	0.928	
MQ (days)	4.9 ± 7.7	5.0 ± 5.0	0.518	
Deep/Superficial (%)	79.4/20.6	70/16.7		0.281/0.470
Neurologic alerts (%)	8.8	23.3		0.106

*Unpaired t test; ** Chi-square test.

VCA indicates vertebral coplanar alignment; AD, apical derotation; Ht, hematocrit; Hb, hemoglobin; RBC, red blood cell; ICU, intensive care unit; ITU, intensive therapy unit; MQ, medico-surgical unit.

Table 6. Comparison of Immediate Postoperative Alignment and Correction (i.e. Change From Pre- to Post-op).

		Immediate postop correction			Change from pre-op to post-op				
		VCA	AD	p**	VCA	p (VCA)*	AD	p (AD)*	p**
Major Curve	Max Cobb	27.7 ± 20.2	33.7 ± 24.3	0.321	-34.6 ± 13.2	0.000	-33.2 ± 15.6	0.000	0.721
	Max AVR	10.6 ± 12.2	10.3 ± 10.1	0.618	-7.8 ± 14.4	0.009	-7.1 ± 11.8	0.007	0.335
	Pelvic Obliquity	4.1 ± 7.5	9.4 ± 12.1	0.065	-2.7 ± 7.2	0.056	-4.4 ± 12.8	0.109	0.978
Sagittal profile	Thoracic Kyphosis	33.9 ± 17.1	30.4 ± 25.1	0.890	4.2 ± 26.6	0.403	13.20 ± 21.3	0.005	0.048
	Lumbar Lordosis	51.7 ± 11.3	52.1 ± 18.9	0.904	-4.6 ± 17.6	0.173	-3.1 ± 12.4	0.219	0.736
	Sacral Slope	31.0 ± 8.6	39.5 ± 11.1	0.002	-2.34 ± 6.8	0.077	-3.6 ± 3.2	0.584	0.192
	Pelvic Incidence	43.3 ± 11.8	55.4 ± 17.8	0.003	-1.9 ± 6.5	0.118	-0.48 ± 3.3	0.480	0.316
	Pelvic Tilt	12.5 ± 7.6	15.5 ± 12.7	0.225	-0.4 ± 6.4	0.731	0.7 ± 4.6	0.474	0.483
	SVA	29.3 ± 41.8	35.0 ± 51.4	0.288	-9.0 ± 44.5	0.282	15.76 ± 75.5	0.857	0.13
	T9Spi	9.7 ± 7.3	6.7 ± 10.1	0.188	-1.9 ± 9.26	0.273	-4.1 ± 17.8	0.431	0.525

*paired t-test within group ** unpaired t-test between the VCA and AD group.
VCA indicates vertebral coplanar alignment; AD, apical derotation.

Complications

38.2% of the patients in the coplanar groups and 50% in the apical derotation group had complications ($p = 0.244$). Late complications were seen in 7.8% of the patients. There were 2 cases of proximal junctional kyphosis within each group. One patient suffered a pedicle fracture secondary to a fall. There were 2 cases of non-union that required revision surgery, both in patients with myelomeningocele who failed at the lumbosacral junction (Table 7).

Discussion

Neuromuscular scoliosis patients have different needs than AIS patients. The goal of surgical treatment in neuromuscular scoliosis is to obtain a solid foundation through a balanced spine, subsequently leading to better ventilation, deglutition and a reduction in pain. In this study, we demonstrated that both the VCA and AD techniques are efficient in correcting the coronal

and axial planes, but the global approach offered by the VCA technique allows for the maintainance of thoracic kyphosis and places less stress on the apex of the curve.

Apical derotation has been for many years the first technique to consider the concept of axial rotation in addition to rod rotation and translation.⁵ However, when describing the concept of apical derotation, Suk et al. never took into account the globality of the spine,⁵ instead applying corrective forces directly to the apex of the vertebra.¹² In this technique, the rod is first forced into the screws before the derotation forces are applied, thus the rod has already been flattened and as only the apex is derotated, the rest of the rod is already fixed into the spine's established pattern. VCA proposes a more indirect approach as it distributes forces across the entirety of the spine, thus including all vertebrae in the process. This translates into less torque being applied at one point of the rod, reducing the degree of rod flattening. Additionally, in osteoporotic patients, this more harmonious distribution of forces could prevent screw pullout and pedicular fractures.

Table 7. Complications for VCA and AD Groups.

Complication	VCA	AD	Total
Intraoperative			
Incidental durotomy	1	1	3.13%
Occipital pressure sore	1	0	1.6%
Intraoperative screw pullout	1	1	3.13%
repositioned during same surgery			
Hypovolemic shock	2	2	6.35%
Tongue biting	1	0	1.6%
Early Postoperative period			
Superficial infection	2	0	3.13%
Deep infection	1	1	3.13%
Bilateral Pneumonia	1	1	3.13%
Minor pneumothorax/Atelectasis	1	3	6.25%
Varicella	1	0	1.6%
Unidentified fever for 2 days	0	3	4.7%
Post op convulsions	0	2	3.13%
Paraparesis	1	1	3.13%
(complete recovery 3 weeks)			
Postoperative paralytic ileum	0	1	1.6%
Late complications			
Proximal screw pullout due to PJK	2	1	4.7%
Pedicle fracture due to traumatic accident	1	0	1.6%
Nonunion	0	2	3.13%
Total	16	19	54.6%

VCA indicates vertebral coplanar alignment; AD, apical derotation.

Studies by Di Silvestre et al. and He et.al demonstrated that VCA had a higher potential to correct main thoracic curves^{13,14} versus AD techniques in AIS patients. However, it is important to note that the curves in AIS patients tend to be more flexible than those with neuromuscular scoliosis; in the study by He et al., the flexibility for the major curve in AIS patients was found to be 43%. In our current study on neuromuscular scoliosis patients with much more rigid curves, we found that both AD and VCA attained a similar degree of correction in the coronal and axial planes. Correction capacity in the coronal plane is achieved by a combination of natural curve correction that occurs when the patient is placed in prone positioning along with the overall efficacy of the surgical technique.

In AIS, apical vertebral rotation correction is important as non instrumented levels usually compensate for this rotation with an increase in curve magnitude. The correcting ability of AD has been reported between 25-60%^{12,15} while the correcting ability of VCA has ranged between 52.9-56.1%.^{11,14} In the current study, both techniques obtained slightly less than 50% of correction in the apical vertebral rotation, with no statistical difference in their derotation capacity. It is possible that baseline spasticity plays an important role in the rigidity seen in neuromuscular scoliosis patients and that once this factor is eliminated during anesthesia, curve correction can be achieved to comparable levels that are seen in AIS patients with more flexible spines. This must be taken into consideration when planning future surgeries for patients with neuromuscular scoliosis as they may not require as aggressive of correction maneuvers that their low preoperative curve flexibility might suggest.

VCA in AIS patients results in increased thoracic kyphosis for hypo-kyphotic patients and no changes for the normo-kyphotic and hyper-kyphotic patients.^{11,14} In the current study, both the patients receiving VCA and those receiving AD achieved a satisfactory thoracic kyphosis by the end of the procedure. Following stratification by preoperative thoracic kyphosis, only the hyper-kyphotic group demonstrated flattening of thoracic kyphosis. This was an expected result of the surgical strategy since the use of posterior osteotomy aims at reducing the degree of thoracic kyphosis for these patients. Interestingly, while both techniques seem adequate in terms of final postoperative thoracic kyphosis, the VCA group had significantly less flattening of the kyphosis with almost 10° of difference when compared to the AD group. This appears to be the main benefit of the VCA technique, as loss of kyphosis remains one of the biggest issues in pediatric deformity patients.¹¹ Limiting hypokyphosis is advantage in neuromuscular patients as most of them already have restrictive ventilatory patterns and diminishing kyphosis might further affect their ventilatory capacity.

Complications were similar in both groups. Although not statistically significant, we reported a larger number of neuromonitoring events for the apical derotation maneuver (7 alerts for AD vs 3 alerts for VCA). Future studies should investigate this concept further as the AD technique places significantly more stress in the most rigid part of the curve and thus may portend a higher potential for major neuromonitoring complications.

The study was limited to a single center with a single surgeon which may affect the generalizability of our results. Additionally, the study's sample size was relatively small and may have implications on the results and overall power of the study. Lastly, the heterogeneity of the rod material may have affected our results, but importantly there was no statistically significant difference in rod composition between the 2 groups. Despite these limitations, this study is unique and informative in regard to comparing the efficacy of the VCA and AD techniques in treating neuromuscular scoliosis. To our knowledge, this is the first study that compares 2 different surgical techniques for apical derotation in neuromuscular scoliosis. It shows the ability of VCA to obtain good coronal and axial correction without significant loss of thoracic kyphosis.

Conclusion

Both apical derotation technique and vertebral coplanar alignment allow for correction in the 3 planes in patients with neuromuscular scoliosis. VCA is a novel approach for surgical correction of neuromuscular scoliosis as it is a less hypokyphosing technique than AD. Both are valid techniques for correcting neuromuscular scoliosis patients.

Consent to Participate

Retrospective study

Consent for Publication

Yes

Declaration of Conflicting Interests

The author(s) declared the following potential conflicts of interest with respect to the research, authorship, and/or publication of this article. Karen Weissmann, M.D.: Consultant fees from Orthopediatrics, Medyssey and Helico. Virginie Lafage, PhD: Royalties: Nuvasive Inc., Consultant Globus Medical, Inc., Speaking and/or Teaching Arrangements: DePuy Synthes, Implanet. Carlos Barrios, M.D. PhD: No conflict of interest. Renaud Lafage MSc: Nemaris: Stock-option. Marcelo A. Costa M.D.: No conflict of interest. Diego Alvarez M.D.: No conflict of interest. Carlos M. Huaiquilaf M.D.: No conflict of interest. Bryan Ang.: No conflict of interest. Ronald G. Schulz M.D.: No conflict of interest.

Ethics Approval

This project was presented to the ethics committee of the southern area of out city (Memo 383/2019, MAT: 66-19082019)

Funding

The author(s) received no financial support for the research, authorship, and/or publication of this article.

ORCID iDs

Karen A. Weissmann, MD  <https://orcid.org/0000-0003-4263-6704>
 Carlos Barrios, MD, PhD  <https://orcid.org/0000-0002-6657-7246>
 Renaud Lafage, MSc  <https://orcid.org/0000-0002-4820-1835>
 Bryan Ang, MD  <https://orcid.org/0000-0002-4174-997X>

References

1. Modi HN, Suh SW, Song HR, Yang JH, Jajodia N. Evaluation of pelvic fixation in neuromuscular scoliosis: a retrospective study in 55 patients. *Int Orthop*. 2010;34(1):89-96. doi:10.1007/s00264-008-0703-z
2. Hong JY, Suh SW, Easwar TR, Hong SJ, Yoon YC, Kang HJ. Clinical anatomy of vertebrae in scoliosis: global analysis in four different diseases by multiplanar reconstructive computed tomography. *Spine J*. 2013;13(11):1510-1520. doi:10.1016/j.spinee.2013.06.047
3. Caine D, Purcell L. The exceptionality of the young athlete. In: Caine D, Purcell L (eds) *Injury in Pediatric and Adolescent Sports. Epidemiology, Treatment and Prevention*, Vol. 1. In: Micheli LJ (ed) *Contemporary Pediatric and adolescent sports Medicine*, Vol. 27, 1st ed. Springer; 2016:248. doi:10.1007/978-3-319-18141-7
4. Vallespir GP, Flores JB, Trigueros IS, et al. Vertebral coplanar alignment: a standardized technique for three dimensional correction in scoliosis surgery: technical description and preliminary results in Lenke type 1 curves. *Spine (Phila Pa 1976)*. 2008; 33(14):1588-1597. doi:10.1097/BRS.0b013e3181788704
5. Suk SI. Pedicle screw instrumentation for adolescent idiopathic scoliosis: the insertion technique, the fusion levels and direct vertebral rotation. *Clin Orthop Surg*. 2011;3(2):89-100. doi:10.4055/cios.2011.3.2.89
6. Expert Panel on Pediatric I. Kadom N, Palasis S, et al. ACR Appropriateness criteria((R)) suspected spine trauma-child. *J Am Coll Radiol*. 2019;16(5 S):S286-S299. doi:10.1016/j.jacr.2019.02.003
7. Mangone M, Raimondi P, Paoloni M, et al. Vertebral rotation in adolescent idiopathic scoliosis calculated by radiograph and back surface analysis-based methods: correlation between the Raimondi method and rasterstereography. *Eur Spine J*. 2013;22(2): 367-371. doi:10.1007/s00586-012-2564-9
8. Hurwitz EE, Simon M, Vinta SR, et al. Adding examples to the ASA-physical status classification improves correct assignment to patients. *Anesthesiology*. 2017;126(4):614-622. doi:10.1097/ALN.0000000000001541
9. Kim YJ, Lenke LG. Thoracic pedicle screw placement: free-hands technique. *Neurology India*. 2005;53(4):512-519.
10. Schwab F, Blondel B, Chay E, et al. The comprehensive anatomical spinal osteotomy classification. *Neurosurgery*. 2014;74(1): 112-120; discussion 120. doi:10.1227/NEU.0000000000001820
11. Barrios C, Lajara JM, Mazeau P, et al. Satisfactory restoration of thoracic kyphosis in Lenke I AIS curves using bilateral vertebral coplanar alignment: an international multicenter experience. *Spine Deform*. 2020;8(3):469-479. doi:10.1007/s43390-020-00067-8
12. Lee SM, Suk SI, Chung ER. Direct vertebral rotation: a new technique of three-dimensional deformity correction with segmental pedicle screw fixation in adolescent idiopathic scoliosis. *Spine (Phila Pa 1976)*. 2004;29(3):343-349. doi:10.1097/01.brs.0000109991.88149.19
13. Di Silvestre M, Lolli F, Bakaloudis G, Maredi E, Vommaro F, Pastorelli F. Apical vertebral derotation in the posterior treatment of adolescent idiopathic scoliosis: myth or reality? *Eur Spine J*. 2013;22(2):313-323. doi:10.1007/s00586-012-2372-2
14. He S, Bao H, Zhu Z, et al. Vertebral coplanar alignment technique: a surgical option for correction of adult thoracic idiopathic scoliosis. *Eur Spine J*. 2016;25(2):417-423. doi:10.1007/s00586-015-4080-1
15. Steib JP, Dumas R, Mitton D, Skalli W. Surgical correction of scoliosis by in situ contouring: a detorsion analysis. *Spine (Phila Pa 1976)*. 2004;29(2):193-199. doi:10.1097/01.BRS.0000107233.99835.A4