

## Use of Optical Coherence Tomography in MI with Non-obstructive Coronary Arteries

Grigoris Karamasis , Iosif Xenogiannis , Charalampos Varlamos , Spyridon Deftereos and Dimitrios Alexopoulos

Second Department of Cardiology, Attikon University Hospital,  
National and Kapodistrian University of Athens Medical School, Athens, Greece

### Abstract

MI with non-obstructive coronary arteries (MINOCA) comprises an important minority of cases of acute MI. Many different causes have been implicated in the pathogenetic mechanism of MINOCA. Optical coherence tomography (OCT) is an indispensable tool for recognising the underlying pathogenetic mechanism when epicardial pathology is suspected. OCT can reliably identify coronary lesions not apparent on conventional coronary angiography and discriminate the various phenotypes. Plaque rupture and plaque erosion are the most frequently found atherosclerotic causes of MINOCA. Furthermore, OCT can contribute to the identification of ischaemic non-atherosclerotic causes of MINOCA, such as spontaneous coronary artery dissection, coronary spasm and lone thrombus. Recognition of the exact cause will enable therapeutic management to be tailored accordingly. The combination of OCT with cardiac magnetic resonance can set a definite diagnosis in the vast majority of MINOCA patients.

### Keywords

MI with non-obstructive coronary arteries, optical coherence tomography, plaque rupture, plaque erosion, calcified nodule, coronary spasm, spontaneous coronary artery dissection

**Disclosure:** GK has received honoraria from Abbott Vascular. DA has received lecturing honoraria/advisory board fees from AstraZeneca, Bayer, Boehringer Ingelheim, Pfizer, Medtronic, Biotronik and Chiesi Hellas. All other authors have no conflicts of interest to declare.

**Received:** 11 October 2021 **Accepted:** 20 January 2022 **Citation:** *Interventional Cardiology* 2022;17:e06. **DOI:** <https://doi.org/10.15420/icr.2021.31>

**Correspondence:** Grigoris Karamasis, Attikon University Hospital, National and Kapodistrian University of Athens Medical School, Rimini 1, Chaidari 124 62, Athens, Greece. E: [grigoris.karamasis@gmail.com](mailto:grigoris.karamasis@gmail.com)

**Open Access:** This work is open access under the CC-BY-NC 4.0 License which allows users to copy, redistribute and make derivative works for non-commercial purposes, provided the original work is cited correctly.

MI with non-obstructive coronary arteries (MINOCA) is a common clinical entity, with a prevalence estimated at between 5% and 7% of MI cases, although it has been reported to be as high as 15%.<sup>1,2</sup> Compared with patients who have MI with obstructive coronary artery disease (CAD), patients with MINOCA are more likely to be younger, female and non-diabetic, to have lower admission and peak troponin concentrations and to present with non-ST segment elevation MI (NSTEMI).<sup>1,3</sup>

Patients with MINOCA have a better prognosis than patients with MI and obstructive CAD. However, MINOCA is not a benign condition and MINOCA patients have worse clinical outcomes than matched patients without CAD.<sup>1,3,4</sup> Thus, current guidelines recommend that the treating physician should follow a diagnostic work-up seeking the underlying cause of MINOCA.<sup>5</sup> Identification of the responsible pathophysiological mechanism is imperative because the various clinical disorders that are potentially the cause of MINOCA have different prognoses and therapies.

Optical coherence tomography (OCT) is an intravascular imaging modality that, because of its high spatial resolution (10–20  $\mu\text{m}$ ), can visualise intraluminal and coronary vessel wall microstructures in detail.<sup>6</sup> OCT has been shown to be superior to other imaging modalities in identifying, at a coronary level, MI pathologies such as plaque rupture, erosion and intracoronary thrombus.<sup>7,8</sup> Therefore, OCT has been proposed as an

important tool for the detection of culprit lesions and the assessment of ambiguous or inconclusive angiographic lesions.<sup>9</sup>

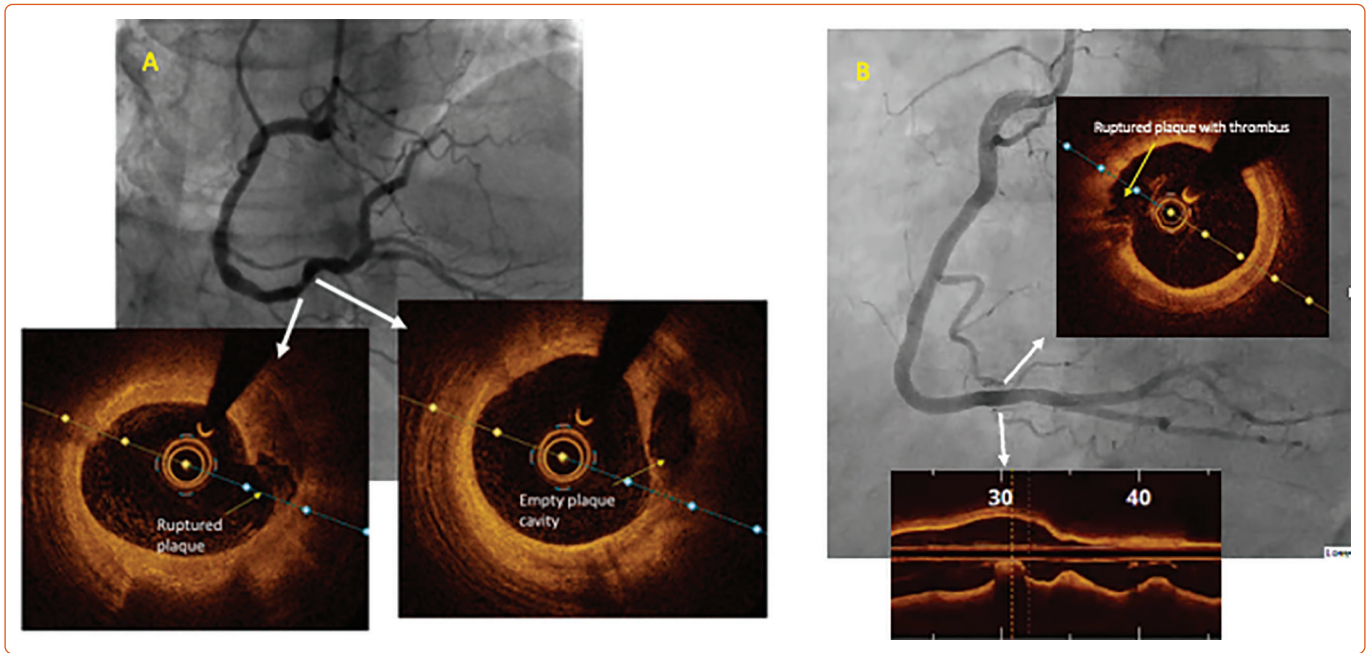
In this review, we describe the use of OCT in delineating causes of MINOCA, review the relevant literature and discuss the therapeutic implications of OCT.

### Contemporary Definition and Causes of MINOCA

In the past, the term 'MINOCA' has been broadly used, occasionally leading to the misclassification of cases; however, recent European and American scientific documents provide a formal and updated definition of MINOCA.<sup>5,10</sup> Accordingly, MINOCA is defined as the fulfilment of the following criteria: acute MI (AMI) as defined by the Fourth Universal Definition of Myocardial Infarction; non-obstructive coronary arteries on coronary angiography, defined as no lesions  $\geq 50\%$  in a major epicardial vessel; and no specific alternative diagnosis for the clinical presentation, such as non-cardiac conditions (i.e. sepsis, pulmonary embolism) or non-ischaemic causes (i.e. myocarditis, takotsubo syndrome and other cardiomyopathies).<sup>5,10,11</sup>

The above definition is clinically relevant because it differentiates true MINOCA from numerous conditions where a coronary angiogram was performed showing non-obstructive disease. However, MINOCA is still an

Figure 1: Examples of MINOCA Caused by Plaque Rupture



A: A 58-year-old man with arterial hypertension and dyslipidaemia presented with acute onset chest pain. Initial ECG showed ST-segment elevation in leads II, III and aVF. Echocardiography showed inferior left ventricle wall hypokinesia. On arrival in the catheterisation laboratory, ST-segment elevation had been resolved. Coronary angiography revealed multiple <50% stenoses in the right coronary artery (RCA). Optical coherence tomography (OCT) was performed, illustrating a ruptured plaque. B: A 66-year-old man with dyslipidaemia and diabetes presented with chest pain lasting for 1 h. ECG showed transient ST-segment elevation in leads II, III and aVF. Emergency coronary angiography showed unobstructed coronaries. OCT revealed a ruptured plaque in the distal RCA.

umbrella term, rather than a definite diagnosis, under which multiple clinical disorders with diverse pathophysiological mechanisms fall. The most recent scientific statement by the American Heart Association discriminates specific aetiologies of MINOCA into ‘atherosclerotic’ and ‘non-atherosclerotic’ causes of myocardial necrosis.<sup>10</sup> Plaque disruption is the ‘atherosclerotic’ cause, encompassing its pathoanatomical substrates of plaque rupture, plaque erosion and calcific nodule.<sup>12</sup> Non-atherosclerotic causes include epicardial coronary vasospasm, spontaneous coronary artery dissection (SCAD), coronary embolism/thrombosis, microvascular dysfunction and supply–demand mismatch (type 2 MI).<sup>10</sup>

### OCT Delineation of Specific Causes of MINOCA Atherosclerotic Causes

Plaque rupture is defined as a discontinuity of the fibrous cap of thin cap fibroatheroma with underlying lipid and a necrotic core, with or without core ‘washout’ or associated thrombus.<sup>6</sup> Examples of plaque rupture in patients with MINOCA are shown in *Figure 1*.

Plaque erosion is characterised by the presence of thrombi and an irregular luminal surface with no evidence of plaque rupture.<sup>6</sup> Examples of plaque erosion in patients with MINOCA are shown in *Figure 2*.

Calcified nodule is defined as one or more protruding, signal-poor and well-delineated regions (characteristics that imply the presence of calcium) frequently forming sharp, jutting angles.<sup>6</sup> In contrast to plaque erosion, which is more prevalent in young, premenopausal women, calcified nodules are found in older, diabetic patients.<sup>10</sup>

### Non-atherosclerotic Causes of MINOCA

Coronary artery spasm is a recognised cause of MINOCA.<sup>10</sup> Angiographic resolution of coronary spasm by nitrates could provide the diagnosis, but often MINOCA patients undergo angiography remote from the acute phase. Provocative testing for coronary artery spasm is the test of choice

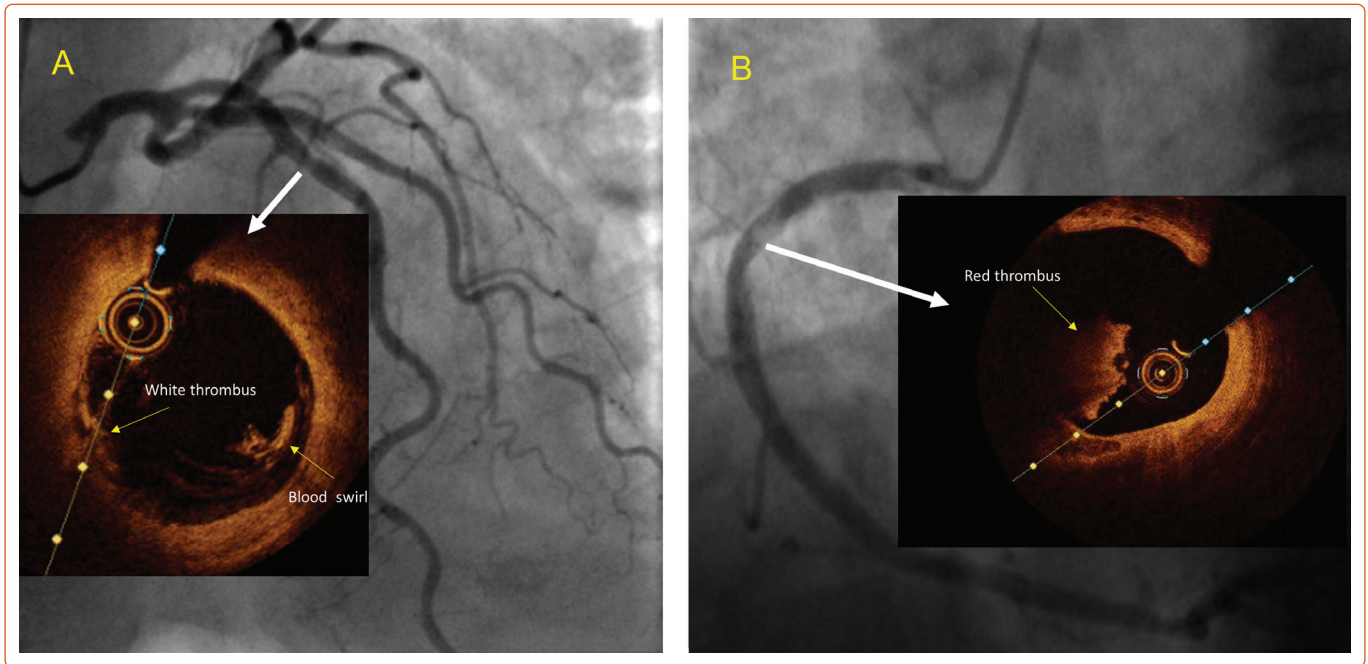
when vasomotor abnormalities are suspected.<sup>13</sup> OCT can identify areas of intimal bumping (intimal projections into the lumen with thickening of the media), which have been found to correspond to areas of spasm.<sup>14</sup> An example of a coronary spasm as a cause of MINOCA is shown in *Figure 3*.

SCAD is a spontaneous separation of the coronary artery wall that is not iatrogenic, and not related to trauma or atherosclerosis.<sup>15</sup> SCAD angiographic characteristics vary, and a standardised classification has been proposed.<sup>9</sup> Type 1 SCAD represents the classical linear coronary defect with potential arterial wall stain. Type 2 SCAD is characterised by an abrupt reduction in vessel size and subsequent normalisation or with persistent size reduction to the distal vessel and is the most observed type. SCAD can also mimic atherosclerosis (Type 3) or simply present with abrupt vessel closure (Type 4). OCT can delineate the diagnosis when there is angiographic uncertainty (typically Types 3 and 4) because it produces characteristic images of SCAD.<sup>9</sup> Nevertheless, it should only be used when deemed safe and necessary for diagnostic purposes because vessel manipulation and contrast injection could propagate the dissection plane.<sup>16</sup> An example of SCAD as a cause of MINOCA is shown in *Figure 4*.

### Existing Evidence of OCT Use in MINOCA

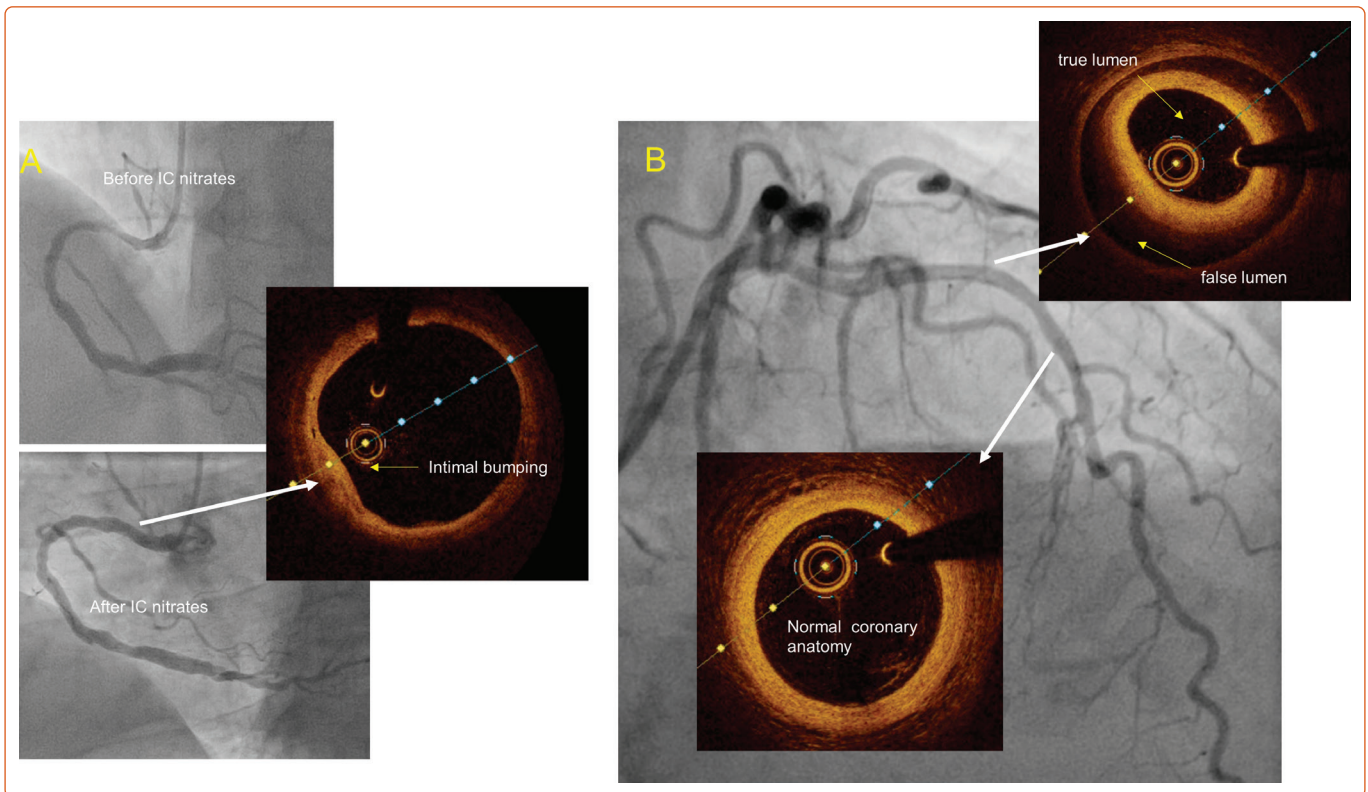
A small number of studies examined the usefulness of OCT in MINOCA patients (*Table 1*). The design of these studies varied widely with regard to the studied population, the description and classification of OCT findings and the diagnostic work-up followed. For example, the provocation test was used to exclude epicardial spasm as the cause of MINOCA before performing OCT in one study.<sup>17</sup> In another study, OCT was encouraged in all three vessels regardless of the ECG, echocardiography and coronary angiography findings.<sup>18</sup> Some studies used OCT with cardiac magnetic resonance (CMR) to evaluate the diagnostic yield of this combination, as well as the agreement of these two imaging modalities regarding the final diagnosis.<sup>17–19</sup> Some of these studies are heavily limited by the small number of patients and their single-centre design.

Figure 2: Examples of MINOCA Caused by Plaque Erosion



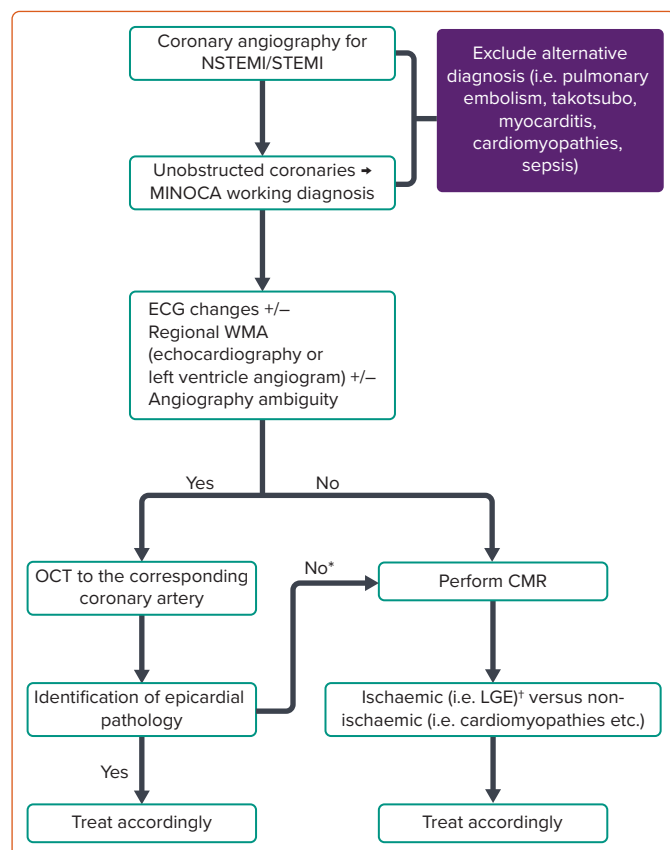
A: 71-year-old woman presented with non-ST segment elevation myocardial infarction (biphasic T-wave inversion in anterior leads). An echocardiogram showed anterior hypokinesia. Coronary angiography showed <50% stenosis at the left anterior descending artery, but optical coherence tomography (OCT) revealed a mid-vessel plaque erosion (intimal irregularities with superimposed white thrombus). B: A 50-year-old man presented with chest pain and transient ST-segment elevation in inferior leads. Coronary angiography showed an atheromatic right coronary artery with no significant stenosis and an area of haziness in the proximal segment. OCT revealed plaque erosion: a red thrombus (a high-backscattering mass protruding into the artery lumen, with signal-free shadowing) and no evidence of fibrous cap rupture at the underlying atheromatic plaque.

Figure 3: Examples of MINOCA Caused by Coronary Spasm and Spontaneous Coronary Artery Dissection



A: A 48-year-old man presented with chest pain and transient ST-segment elevation in the inferior leads. The patient had a similar presentation a few years ago, when a coronary angiogram showed unobstructed coronaries and subsequent cardiac magnetic resonance showed late gadolinium enhancement in an area of the inferior wall. At that time, the patient was discharged with a diagnosis of MINOCA without further specification of the underlying cause. This time the patient developed chest pain and ST changes while on the catheterisation laboratory table. Coronary angiography showed a severe proximal right coronary artery lesion that was resolved with the administration of IC nitrates. A subsequent optical coherence tomography (OCT) image in the corresponding area is shown. Although, there is pathological intimal thickening, the image is not a typical example of OCT findings in coronary spasm because there is no obvious corresponding medial thickening. B: A 78-year-old hypertensive woman presented with recurrent episodes of chest pain at rest. ECG showed anterior T wave inversion, high-sensitivity troponin was increased and echocardiography showed anterior wall hypokinesia. Coronary angiography showed an unobstructed left anterior descending artery, but OCT revealed a SCAD with false lumen and intramural haematoma extending from the mid to proximal vessel.

**Figure 4: Clinical Algorithm for the Use of Optical Coherence Tomography in MINOCA**



\*Consider ACh provocation test if available. \*In cases of regional ischaemic pattern detection, repeated invasive assessment with OCT of the 'suspected' culprit vessel could be considered. CMR = cardiac magnetic resonance; LAD = left anterior descending artery; LGE = late gadolinium enhancement; LV = left ventricle; NSTEMI = non-ST-segment elevation MI; RCA = right coronary artery; SCAD = spontaneous coronary artery dissection; STEMI = ST-segment elevation myocardial infarction; WMA = wall motion abnormalities.

In a retrospective single-centre study, Yamamoto et al. sought to evaluate the morphological characteristics of non-obstructive coronary lesions as assessed by OCT in a mixed population of acute coronary syndrome (ACS) and stable CAD patients.<sup>20</sup> In this small ACS cohort (n=31), the incidence of any 'high-risk OCT finding' (i.e. plaque rupture, calcified nodule, intimal laceration or thrombus) was 25.8%, with thrombus being recognised in 12.9% of cases.<sup>20</sup> Interestingly, the rate of 'high-risk findings' was similar in the stable CAD group (22.5%; p=0.70).<sup>20</sup>

Another small, single-centre study reported OCT findings in patients with ACS and non-significant coronary lesions on coronary angiography.<sup>21</sup> In that study, an 'unstable plaque' was found in 78% of patients. Specifically, plaque erosion (41%) was the most common finding, followed by plaque rupture (30%) and calcified nodule with thrombus/plaque disruption (7%).<sup>21</sup> Although all patients had angiographic coronary stenoses of <50%, percutaneous coronary intervention (PCI) was performed in 95% of those with an unstable plaque identified by OCT.<sup>21</sup> The value of that study is questionable due to the very high rate of revascularisation in lesions causing mild stenosis, a practice that, as discussed below in the Therapeutic Implications section, is not generally recommended.<sup>9,10</sup>

Opolski et al. were the first investigators to follow a robust prospective methodology including the combination of OCT with CMR in the work-up of MINOCA patients. In their study, they included 38 patients with MI and coronary stenosis of ≤50%.<sup>19</sup> Plaque rupture, plaque erosion and calcified

nodule were identified in 8 (21%), 4 (11%) and 2 (5%) patients respectively, with the total percentage of patients with an underlying atherosclerotic mechanism of MINOCA being 36% (one patient had both plaque rupture and calcified nodule).<sup>19</sup> Interestingly, immediate interpretation of OCT led to a change in therapeutic plan in 16% of cases, including referral for PCI in five patients and/or modification of antithrombotic therapy for two patients.<sup>19</sup> In a subgroup of 31 patients who underwent CMR, ischaemic-type late gadolinium enhancement (LGE) was present in 7 (23%) and was more common in patients with than without plaque disruption (50% versus 13%, respectively; p=0.053) and coronary thrombus (67% versus 12%, respectively; p=0.014).<sup>19</sup>

In their study, Taruya et al. included 82 consecutive patients with ACS and non-obstructive CAD who underwent OCT and had clinical follow up for up to 2 years.<sup>22</sup> High-risk lesions in the culprit artery were identified in approximately half the patients (51.2%), including ruptured plaque (15.9%), calcified nodule (11.0%), SCAD (8.5%), lone thrombus (8.5%) and plaque erosion (1.2%).<sup>22</sup> Although none of the patients without high-risk lesions experienced major adverse cardiovascular events (MACE), four (10%) of the patients in the high-risk-lesion group had a recurrent ACS event with obstructive coronary artery stenosis. All the recurrent ACS events occurred at the segment where the high-risk lesion had been originally identified.<sup>22</sup>

Gerbaud et al. evaluated the diagnostic yield of OCT accompanied by CMR in a highly selected group of 40 MINOCA patients.<sup>17</sup> The authors followed the contemporary MINOCA definition, and their cohort was carefully selected because they only included patients with a suspected diagnosis of epicardial cause based on the correlation between ECG changes and regional wall motion abnormalities (WMA) observed either on admission echocardiography or left ventricle angiogram. Furthermore, before final inclusion, the authors used provocation testing for coronary artery spasm in patients presenting with suspected vasospastic angina according to COVADIS (Coronary Vasomotion Disorders International Study) group recommendations.<sup>23</sup> In the final study cohort, OCT identified a pathological substrate in 80% of cases.<sup>17</sup> Plaque rupture (35%) and plaque erosion (30%) were the most commonly recognised potential MINOCA mechanisms, followed by lone thrombus (7.5%), SCAD (5%) and eruptive calcific nodule (2.5%). OCT findings changed medical management in 11 patients (27.5%). AMI was evident at CMR in 31 of 40 patients (77.5%). Twenty-three patients (57.5%) had a substrate and/or diagnosis supported by both techniques, with an evident relationship between the findings obtained by the two techniques. By coupling OCT with CMR, a substrate and/or diagnosis was found in 100% of cases.<sup>17</sup>

Reynolds et al. conducted the largest study to date in the field, including 145 women with MINOCA who per protocol would undergo multivessel (ideally three-vessel) OCT followed by CMR within 1 week.<sup>18</sup> Eventually, OCT in all three major coronary arteries was performed in 59.3% of cases. A definite or possible culprit lesion was identified on OCT in 67 (46.2%) of patients, with the most common culprit lesions being intraplaque cavity (21.4%), layered plaque (13.1%), plaque rupture (5.5%) and thrombus without plaque rupture (3.1%; i.e. thrombus overlying an intact fibrous cap, or lone thrombus). Furthermore, three patients (2.1%) had intimal bumping suggesting coronary artery spasm and one (0.7%) had SCAD.<sup>18</sup> Not surprisingly, there was no calcified nodule identified, a phenotype that is more common among older, male, diabetic patients. CMR, which was available in 116 of the 145 participants, was abnormal in 74.1% of cases with an ischaemic pattern of LGE, regional injury or non-ischaemic findings (i.e. myocarditis, takotsubo and other cardiomyopathies) in 32.8%, 20.7% and 20.7% of cases, respectively.<sup>18</sup> After the combination of OCT and CMR,

**Table 1: Studies Evaluating the Findings of Optical Coherence Tomography in MI with Non-obstructive Coronary Arteries**

Author	No. Patients	Study Population	Recognition of Unstable Coronary Lesions	Plaque Rupture	Plaque Erosion	Calcified Nodule	Lone Thrombus	Spasm	SCAD	Ischaemia/MI in CMR	Non-ischaemic Pathological Pattern
Yamamoto et al. <sup>20</sup>	31 patients with ACS*	ACS and stable CAD with stenosis <50%	8 (25.8)	2 (6.5)	NA	2 (6.5)	4 (12.9)	NA	NA	NA	NA
Mas-Lladó et al. <sup>21</sup>	27	MINOCA	21 (78)	8 (30)	11 (41)	2 (7)	NA	NA	NA	NA	NA
Opolski et al. <sup>19</sup>	38	MINOCA	15 (39)	8 (21)	4 (11)	2 (5)	2 (5)	NA	NA	7 (23)	8 (26)*
Taruya et al. <sup>22</sup>	82	ACS patients with stenosis <50%	42 (51.2)	13 (15.9)	1 (1.2)	9 (11)	7 (8.5)	NA	7 (8.5)	NA	NA
Gerbaud et al. <sup>17</sup>	40	MINOCA	32 (80)	14 (35)	12 (30)	1 (2.5)	3 (7.5)	NA <sup>‡</sup>	2 (5)	31 (77.5)	NA <sup>  </sup>
Reynolds et al. <sup>18</sup>	145	MINOCA	67 (46.2)	8 (6)	NA	0 (0)	5 (4)	3 (2.1)	1 (0.7)	62 (53.5)	24 (20.7)

Unless indicated otherwise, data are presented as n (%). \*Only findings for the 31 patients with ACS are described in the table. †One patient (3%) had both transmural and mid-wall late gadolinium enhancement (mixed pattern). ‡Provocation testing with methylergonovine (0.4 mg) was performed in patients with suspected coronary spasm before study enrolment. Epicardial coronary artery spasm with provocation testing was confirmed in 35 of 114 patients (31%). ||CMR was used for the diagnosis of non-ischaemic causes, such as myocarditis, before patient enrolment in the study. ACS = acute coronary syndrome; CAD = coronary artery disease; CMR = cardiac magnetic resonance; MINOCA = MI with non-obstructive coronary artery disease; NA = not applicable; SCAD = spontaneous coronary artery dissection.

a cause was identified in 84.5% of women, with an ischaemic cause/MI being confirmed in 63.8% of cases.<sup>18</sup>

Although Gerbaud et al. identified abnormal findings on OCT in 80% of patients, Reynolds et al. identified a culprit lesion by OCT in less than half of the patients (46%).<sup>17,18</sup> This discrepancy is not surprising if the screening/recruiting process of the two studies is considered. Gerbaud et al. followed the contemporary MINOCA definition and mandated ECG changes and correlated WMA for all included cases.<sup>10,17</sup> In contrast, in the study of Reynolds et al., 35% of patients had a normal ECG and only 44.1% had WMA on echocardiography.<sup>18</sup> The latter study was conducted exclusively in women; hence, the results cannot be extrapolated to men. In addition, the study was criticised because it included layered plaque among the unstable plaque phenotypes. The formation of such a plaque may take weeks to months and likely represents a sequela rather than a pathophysiological mechanism of ACS.<sup>24</sup>

### Therapeutic Implications

Robust scientific data with respect to MINOCA therapeutic strategies are missing. In any case, the diverse population with multiple discrete underlying pathologies that is described under the umbrella term of MINOCA would make a one-size-fits-all strategy faulty and meaningless. This is probably the disadvantage of a large observational study derived by the SWEDEHART registry, which reported that dual antiplatelet therapy (DAPT) showed no benefit.<sup>25</sup> Because multiple distinct pathologies could be involved in the clinical presentation of MINOCA, it seems intuitive that subsequent management should be based on the final established underlying cause. This is supported by the current European guidelines, which recommend the management of patients with an initial diagnosis of MINOCA and a final established underlying cause according to disease-specific guidelines.<sup>5</sup> In cases in which a final diagnosis is not reached, the guidelines state that secondary prevention for atherosclerotic disease may be applied.<sup>5</sup>

When OCT has demonstrated plaque disruption (rupture, erosion or calcific nodule) as the underlying cause, the administration of a P2Y<sub>12</sub> receptor inhibitor in addition to aspirin seems logical based on studies of patients with MI that did not discriminate between obstructive and non-

obstructive CAD.<sup>26</sup> The duration of DAPT should be individualised after taking into consideration the bleeding risk as well as the therapeutic management (medical versus invasive) of the patient with the by-default strategy being DAPT administration for 12 months followed by lifetime single antiplatelet therapy.<sup>27</sup>

Regarding the need for routine stent implantation, more research is needed because currently there is no consensus and management remains controversial. An expert consensus document of the European Association of Percutaneous Cardiovascular Interventions is in favour of PCI when intravascular imaging identifies a ruptured plaque in MINOCA patients.<sup>9</sup> According to the same statement, stenting can be deferred in cases of plaque erosion when the lesion is non-obstructive and flow has been restored.<sup>9</sup> In contrast, a scientific statement from the American Heart Association recommends against routine stenting in cases of plaque rupture and erosion with no residual significant stenosis without discriminating between the two mechanisms.<sup>10</sup>

A small randomised trial (EROSION study) on patients with ACS caused by plaque erosion that leads to  $\leq 70\%$  stenosis demonstrated that DAPT with aspirin and ticagrelor without stenting was associated with favourable outcomes at 1 year, with approximately 93% of patients remaining without MACE, supporting the concept of medical-only management in this group of patients.<sup>28</sup> There are no studies or expert recommendations when the underlying lesion is an eruptive calcific nodule. What should be considered though is the fact that calcified nodules are related to stent underexpansion and higher rates of future target vessel revascularisation.<sup>29</sup> Therefore, when PCI is deemed necessary, it should be accompanied by calcium modification techniques.

When the cause of MINOCA is one of the non-atherosclerotic causes, management should be according to the underlying condition. For example, when vasospasm is identified as the underlying pathophysiological mechanism,  $\beta$ -blockers should be halted/avoided and the patient should be started on calcium channel blockers, which are the agents of choice with short-acting nitrates being the second option.<sup>10,27</sup> Regarding SCAD, there are no randomised controlled trials to guide management, and the use and duration of aspirin alone or DAPT in medically managed cases

remains controversial. A recent document by a panel of experts suggested DAPT for 2–4 months followed by low-dose aspirin as monotherapy for up to 12 months; aspirin alone or not antiplatelet therapy at all was proposed as a reasonable alternative for patients at high bleeding risk.<sup>15</sup> The same document emphasised that patient counselling and shared decision making should be employed, especially among the younger, female population, which carries an advanced risk of bleeding (e.g. due to menorrhagia).<sup>15</sup> Importantly, a recently published multicentre SCAD registry that investigated single and dual antiplatelet regimens on conservatively treated patients challenged the paradigm of DAPT in SCAD.<sup>30</sup> That study showed that prolonged DAPT (97% of patients received DAPT for 12 months) was independently associated with a higher rate of adverse cardiovascular events at the 1-year follow-up.<sup>30</sup>

Regarding further intervention, spontaneous angiographic healing is the natural history of the disease in 95% of patients, highlighting that conservative therapy is preferred in stable patients without ongoing ischaemia, as in cases with MINOCA where, by definition, there is no significant angiographic coronary stenosis.<sup>31</sup> In any case, it should be highlighted that intervention in SCAD cases carries elevated risks.<sup>32</sup>

### Clinical Perspectives

Current scientific documents underline the significance of CMR in MINOCA. European guidelines for the management of ACS without persistent ST-segment elevation recommend the performance of CMR in all MINOCA patients without an obvious underlying cause (class I, level of evidence B).<sup>5</sup> The guidelines do not give any specific recommendation for the utilisation of OCT, although the recent studies that support the use of CMR (e.g. Reynolds et al.) have shown the value of OCT too.<sup>17–19</sup> CMR is an excellent modality to discriminate between ischaemic and non-ischaemic causes of MINOCA, as discussed previously. However, CMR cannot inform us regarding the underlying pathology of the ischaemic insult: for example, it cannot tell us whether the ischaemia was due to a ruptured plaque or coronary spasm. As shown previously, OCT can discriminate the various phenotypes of epicardial pathologies.<sup>9,14,16–22</sup> Importantly, it can take place at the time of coronary angiography, guiding immediate management. Conversely, ‘blind’ three-vessel OCT is not practical and the diagnostic yield of such a strategy is low.

It is characteristic that in the study of Reynolds et al., although three-vessel OCT was recommended, it took place in 59.3% of cases, highlighting the practical limitations of such a strategy.<sup>18</sup> In addition, it is

likely that ‘blind’ three-vessel OCT, not guided by electrocardiographic and imaging findings, could lead to the erroneous recognition of a bystander lesion as the culprit because ‘unstable’ plaques have been also found in patients with stable CAD.<sup>20</sup> Furthermore, as discussed previously, the rate of pathological findings is much lower when compared with OCT guided by ECG and echocardiography/left ventricle angiogram findings. Considering the above aspects, we propose a practical algorithm for OCT use in cases of MINOCA (Figure 4). In our algorithm, OCT vessel interrogation is guided by ECG changes and regional WMA, and is suggested in the corresponding coronary artery. A hazy non-obstructive coronary lesion in a MINOCA case is highly suspicious of a coronary pathology and should prompt further investigation by OCT. However, even when the vessel appears smooth in angiography, there still may be an underlying pathology (i.e. Figure 1B) and OCT should be considered in the artery corresponding to ECG changes and/or WMA.

Finally, it needs to be acknowledged that even in coronary causes of MINOCA, OCT cannot always give a definite diagnosis. OCT could generate the suspicion for the presence of epicardial coronary spasm, but it is not the test of choice. Furthermore, OCT does not provide any information regarding coronary microvascular spasm, which plays a role in several MINOCA cases.<sup>13</sup> In patients with suspected coronary vasomotor abnormalities, a provocation test with acetylcholine should be considered to assess the presence of epicardial or microvascular spasm<sup>33</sup> (Figure 4). Provocation testing in MINOCA patients has been shown to be safe and able to identify high-risk patients.<sup>13</sup> However, its use in clinical practice is currently limited and mainly restricted to specialised centers.<sup>34</sup> Thrombus embolism not related to plaque disruption is another coronary cause of MINOCA where OCT is not diagnostic. A patient’s clinical history and characteristics could set the suspicion of embolism (e.g. prosthetic heart valves, apical thrombus, infective endocarditis or myxoma) and echocardiography could be useful in delineating the cause of MINOCA in such cases.<sup>33</sup>

### Conclusion

OCT is an indispensable tool for the recognition of the underlying pathogenetic mechanism of MINOCA when epicardial pathology is suspected because it can reliably identify pathologies not apparent on coronary angiography. OCT should be part of the diagnostic work-up for a patient with MINOCA when ECG changes and WMA on an echocardiogram or left ventricle angiogram indicate a localised epicardial coronary cause. □

- Barr PR, Harrison W, Smyth D et al. Myocardial infarction without obstructive coronary artery disease is not a benign condition (ANZACS-QI 10). *Heart Lung Circ* 2018;27:165–74. <https://doi.org/10.1016/j.hlc.2017.02.023>; PMID: 28408093.
- Pasupathy S, Air T, Dreyer RP et al. Systematic review of patients presenting with suspected myocardial infarction and nonobstructive coronary arteries. *Circulation* 2015;131:861–70. <https://doi.org/10.1161/CIRCULATIONAHA.114.011201>; PMID: 25587100.
- Safdar B, Spatz ES, Dreyer RP et al. Presentation, clinical profile, and prognosis of young patients with myocardial infarction with nonobstructive coronary arteries (MINOCA): results from the VIRGO Study. *J Am Heart Assoc* 2018;7:e009174. <https://doi.org/10.1161/JAHA.118.009174>; PMID: 29954744.
- Pizzi C, Xhyheri B, Costa GM et al. Nonobstructive versus obstructive coronary artery disease in acute coronary syndrome: a meta-analysis. *J Am Heart Assoc* 2016;5:e004185. <https://doi.org/10.1161/JAHA.116.004185>; PMID: 27986756.
- Collet J-P, Thiele H, Barbato et al. 2020 ESC Guidelines for the management of acute coronary syndromes in patients presenting without persistent ST-segment elevation. *Eur Heart J* 2021;42:1289–367. <https://doi.org/10.1093/eurheartj/ehaa575>; PMID: 32860058.
- Tearney GJ, Regar E, Akasaka T et al. Consensus standards for acquisition, measurement, and reporting of intravascular optical coherence tomography studies: a report from the International Working Group for Intravascular Optical Coherence Tomography Standardization and Validation. *J Am Coll Cardiol* 2012;59:1058–72. <https://doi.org/10.1016/j.jacc.2011.09.079>; PMID: 22421299.
- Kubo T, Imanishi T, Takarada S et al. Assessment of culprit lesion morphology in acute myocardial infarction: ability of optical coherence tomography compared with intravascular ultrasound and coronary angiography. *J Am Coll Cardiol* 2007;50:933–9. <https://doi.org/10.1016/j.jacc.2007.04.082>; PMID: 17765119.
- Jia H, Abtahian F, Aguirre AD et al. In vivo diagnosis of plaque erosion and calcified nodule in patients with acute coronary syndrome by intravascular optical coherence tomography. *J Am Coll Cardiol* 2013;62:1748–58. <https://doi.org/10.1016/j.jacc.2013.05.071>; PMID: 23810884.
- Johnson TW, Räber L, di Mario C et al. Clinical use of intracoronary imaging. Part 2: acute coronary syndromes, ambiguous coronary angiography findings, and guiding interventional decision-making: an expert consensus document of the European Association of Percutaneous Cardiovascular Interventions. *Eur Heart J* 2019;40:2566–84. <https://doi.org/10.1093/eurheartj/ehz332>; PMID: 31112213.
- Tamis-Holland JE, Jneid H, Reynolds HR et al. Contemporary diagnosis and management of patients with myocardial infarction in the absence of obstructive coronary artery disease: a scientific statement from the American Heart Association. *Circulation* 2019;139:e891–908. <https://doi.org/10.1161/CIR.0000000000000670>; PMID: 30913893.
- Thygesen K, Alpert JS, Jaffe AS et al. Fourth universal definition of myocardial infarction (2018). *J Am Coll Cardiol* 2018;72:2231–64. <https://doi.org/10.1016/j.jacc.2018.08.1038>; PMID: 30153967.
- Falk E, Nakano M, Bentzon JF et al. Update on acute coronary syndromes: the pathologists’ view. *Eur Heart J* 2013;34:719–28. <https://doi.org/10.1093/eurheartj/ehs411>; PMID: 23242196.
- Montone RA, Niccoli G, Fracassi F, et al. Patients with acute myocardial infarction and nonobstructive coronary arteries: safety and prognostic relevance of invasive coronary provocative tests. *Eur Heart J* 2018;39:91–8. <https://doi.org/10.1093/eurheartj/ehx667>; PMID: 29228159.
- Tanaka A, Shimada K, Tearney GJ et al. Conformational change in coronary artery structure assessed by optical coherence tomography in patients with vasospastic angina.

- J Am Coll Cardiol* 2011;58:1608–13. <https://doi.org/10.1016/j.jacc.2011.06.046>; PMID: 21958888.
15. Hayes SN, Tweet MS, Adlam et al. Spontaneous coronary artery dissection: JACC state-of-the-art review. *J Am Coll Cardiol* 2020;76:961–84. <https://doi.org/10.1016/j.jacc.2020.05.084>; PMID: 32819471.
  16. Adlam D, Tweet MS, Gulati R et al. Spontaneous coronary artery dissection: pitfalls of angiographic diagnosis and an approach to ambiguous cases. *JACC Cardiovasc Interv* 2021;14:1743–56. <https://doi.org/10.1016/j.jcin.2021.06.027>; PMID: 34412792.
  17. Gerbaud E, Arabucki F, Nivet H et al. OCT and CMR for the diagnosis of patients presenting with MINOCA and suspected epicardial causes. *JACC Cardiovasc Imaging* 2020;13:2619–31. <https://doi.org/10.1016/j.jcmg.2020.05.045>; PMID: 32828786.
  18. Reynolds HR, Maehara A, Kwong RY et al. Coronary optical coherence tomography and cardiac magnetic resonance imaging to determine underlying causes of myocardial infarction with nonobstructive coronary arteries in women. *Circulation* 2021;143:624–40. <https://doi.org/10.1161/CIRCULATIONAHA.120.052008>; PMID: 33191769.
  19. Opolski MP, Spiewak M, Marczak M et al. Mechanisms of myocardial infarction in patients with nonobstructive coronary artery disease: results from the Optical Coherence Tomography Study. *JACC Cardiovasc Imaging* 2019;12:2210–21. <https://doi.org/10.1016/j.jcmg.2018.08.022>; PMID: 30343070.
  20. Yamamoto MH, Maehara A, Song L et al. Optical coherence tomography assessment of morphological characteristics in suspected coronary artery disease, but angiographically nonobstructive lesions. *Cardiovasc Revasc Med* 2019;20:475–9. <https://doi.org/10.1016/j.carrev.2018.07.011>; PMID: 30054255.
  21. Mas-Lladó C, Maristany J, Gómez-Larab J et al. Value of the optical coherence tomography in the diagnosis of unstable patients with non-significant coronary stenosis. *REC Interv Cardiol* 2020;2:272–9. <https://doi.org/10.24875/RECICE.M20000117>.
  22. Taruya A, Tanaka A, Nishiguchi T et al. Lesion characteristics and prognosis of acute coronary syndrome without angiographically significant coronary artery stenosis. *Eur Heart J Cardiovasc Imaging* 2020;21:202–9. <https://doi.org/10.1093/ehjci/jez079>; PMID: 31056642.
  23. Beltrame JF, Crea F, Kaski JC, et al. International standardization of diagnostic criteria for vasospastic angina. Coronary Vasomotion Disorders International Study Group (COVADIS). *Eur Heart J* 2017;38:2565–8. <https://doi.org/10.1093/eurheartj/ehv351> PMID: 26245334.
  24. Bryniarski K, Gasior P, Legutko J et al. OCT findings in MINOCA. *J Clin Med* 2021;10:2759. <https://doi.org/10.3390/jcm10132759>; PMID: 34201727.
  25. Lindahl B, Baron T, Erlinge D et al. Medical therapy for secondary prevention and long-term outcome in patients with myocardial infarction with nonobstructive coronary artery disease. *Circulation* 2017;135:1481–9. <https://doi.org/10.1161/CIRCULATIONAHA.116.026336>; PMID: 28179398.
  26. Chen ZM, Jiang LX, Chen YP et al. Addition of clopidogrel to aspirin in 45,852 patients with acute myocardial infarction: randomised placebo-controlled trial. *Lancet* 2005;366:1607–21. [https://doi.org/10.1016/S0140-6736\(05\)67660-X](https://doi.org/10.1016/S0140-6736(05)67660-X) PMID: 16271642.
  27. Scalone G, Niccoli G, Crea F. Editor's choice – pathophysiology, diagnosis and management of MINOCA: an update. *Eur Heart J Acute Cardiovasc Care* 2019;8:54–62. <https://doi.org/10.1177/2048872618782414>; PMID: 29952633.
  28. Jia H, Dai J, Hou J et al. Effective anti-thrombotic therapy without stenting: intravascular optical coherence tomography-based management in plaque erosion (the EROSION study). *Eur Heart J* 2017;38:792–800. <https://doi.org/10.1093/eurheartj/ehw381>; PMID: 27578806.
  29. Kobayashi N, Takano M, Tsurumi M et al. Features and outcomes of patients with calcified nodules at culprit lesions of acute coronary syndrome: an optical coherence tomography study. *Cardiology* 2018;139:90–100. <https://doi.org/10.1159/000481931>; PMID: 29301128.
  30. Cerrato E, Giacobbe F, Quadri G, et al. Antiplatelet therapy in patients with conservatively managed spontaneous coronary artery dissection from the multicentre DISCO registry. *Eur Heart J* 2021;42:3161–71. <https://doi.org/10.1093/eurheartj/ehab372>; PMID: 34338759.
  31. Hassan S, Prakash R, Starovoytov A, Saw J. Natural history of spontaneous coronary artery dissection with spontaneous angiographic healing. *JACC Cardiovasc Interv* 2019;12:518–27. <https://doi.org/10.1016/j.jcin.2018.12.011>; PMID: 30826233.
  32. Kotecha D, Garcia-Guimaraes M, Premawardhana D, et al. Risks and benefits of percutaneous coronary intervention in spontaneous coronary artery dissection. *Heart* 2021;107:1398–406. <https://doi.org/10.1136/heartjnl-2020-318914>; PMID: 34006503.
  33. Montone RA, Jang IK, Beltrame JF, et al. The evolving role of cardiac imaging in patients with myocardial infarction and non-obstructive coronary arteries. *Prog Cardiovasc Dis* 2021;68:78–87. <https://doi.org/10.1016/j.pcad.2021.08.004>; PMID: 34600948.
  34. Montone RA, Meucci MC, De Vita A, et al. Coronary provocative tests in the catheterization laboratory: pathophysiological bases, methodological considerations and clinical implications. *Atherosclerosis* 2021;318:14–21. <https://doi.org/10.1016/j.atherosclerosis.2020.12.008>; PMID: 33360263.