

# Eyelid Reconstruction Using Oral Mucosa and Ear Cartilage Strips as Sandwich Grafting

Naoto Yamamoto, MD, PhD\*  
 Hiroyuki Ogi, MD†  
 Satoshi Yanagibayashi, MD\*  
 Ryuichi Yoshida, MD\*  
 Megumi Takikawa, MD, PhD\*  
 Akio Nishijima, MD\*  
 Tomoharu Kiyosawa, MD, PhD‡

**Background:** The eyelid structure can be divided into an inner layer and an outer layer. Reconstruction of a full-thickness eyelid defect is accomplished by full-thickness composite tissue transfer or combined layered reconstruction. We present a new technique for inner layer reconstruction using ear cartilage and oral mucosa.

**Methods:** The oral mucosa graft is harvested from the inner side of the lower lip to fit the defect size and shape. The ear cartilage graft is harvested as a rectangular strip. The harvested mucosa is sutured to the defect margin and the cartilage strip graft is interposed to the defect. Finally, the outer layer of the defect is covered with skin flaps. Consequently, the ear cartilage graft is sandwiched between the mucosa graft and the skin flap.

**Results:** We used this technique for the reconstruction of 13 full-thickness eyelid defects of various locations, sizes, and shapes. Ten cases involved the lower eyelid, 2 cases involved the lower eyelid including the medial canthus, and 1 case involved the upper eyelid. The oral mucosa graft survived in all patients. The reconstructions were successful and there were no postoperative reports of conjunctival or corneal irritation.

**Conclusions:** The present technique using a combination of an ear cartilage strip graft and oral mucosa graft is an easy and versatile technique for reconstruction of inner layer eyelid defects. We believe that the beneficial effects of tears, which are richly oxygenated, improved survival of the grafted mucosa. (*Plast Reconstr Surg Glob Open* 2017;5:e1301; doi: 10.1097/GOX.0000000000001301; Published online April 19 2017.)

Full-thickness eyelid defects involving one-third or less of the horizontal width can usually be repaired by direct suturing or closure with lateral canthotomy and a lateral canthus tendon cut.<sup>1</sup> In addition, the use of a semicircular flap (Tenzel flap) allows direct closure of half of an eyelid.<sup>1,2</sup> When direct closure is impossible, reconstructive surgery is needed.<sup>1</sup>

The eyelid structure can be divided into 2 layers: an inner layer (posterior lamella) and an outer layer (anterior lamella). The inner layer is composed of the tarsal plate

and mucosa; the outer layer is composed of the orbicularis oculi muscles, subcutaneous tissue, and skin. Reconstruction of a full-thickness eyelid defect is accomplished by full-thickness composite tissue transfer or combined layered reconstruction.

We believe that an ideal method of eyelid reconstruction should have the following characteristics: good contact without irritation to the bulbar conjunctiva and cornea; supportable, particularly in the lower eyelids; applicable to various types of defects; easy to perform; and reduced damage of the donor site. To achieve this, we created a new technique for inner layer reconstruction using ear cartilage and oral mucosa, which have good versatility for various defects.

## OPERATIVE TECHNIQUE

The oral mucosa graft, which is created with the same size and shape as the defect in the palpebral conjunctiva, is harvested from the inner side of the lower lip. The donor site is left as an open wound and heals conservatively. Next, the ear cartilage graft is harvested mainly from the conchal lateral wall through a postauricular incision as a rectangu-

From the \*Department of Plastic and Reconstructive Surgery, New Tokyo Hospital, Chiba, Japan; †Department of Plastic and Reconstructive Surgery, Asakadai Central General Hospital, Saitama, Japan; and ‡Department of Plastic and Reconstructive Surgery, National Defense Medical College, Saitama, Japan.

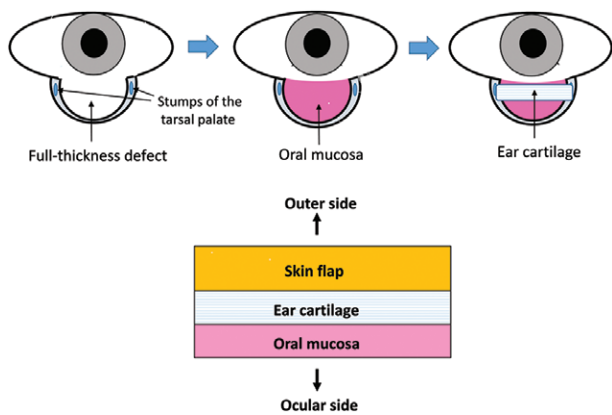
Received for publication October 12, 2016; accepted February 24, 2017.

Presented in part in the 56th annual meeting of Japanese Association of Plastic and Reconstructive Surgery, 2013, Tokyo.

Copyright © 2017 The Authors. Published by Wolters Kluwer Health, Inc. on behalf of The American Society of Plastic Surgeons. This is an open-access article distributed under the terms of the Creative Commons Attribution-Non Commercial-No Derivatives License 4.0 (CCBY-NC-ND), where it is permissible to download and share the work provided it is properly cited. The work cannot be changed in any way or used commercially without permission from the journal.

DOI: 10.1097/GOX.0000000000001301

**Disclosure:** The authors have no financial interest to declare in relation to the content of this article. The Article Processing Charge was paid for by the authors.



**Fig. 1.** Diagram of the sandwich technique. Upper: Oral mucosa and ear cartilage grafting procedure for inner layer reconstruction. Lower: Sectional drawing of the reconstructed full-thickness defect.

lar strip approximately 5–6 mm in width. If the length is not enough, then the harvest is extended cranially and caudally.

The suture line and the outer and posterior sides of the ear harvest site are widely coated with 2-octyl-cyanoacrylate skin adhesive to splint the shape and prevent subcutaneous hematoma.<sup>3</sup> The length of the cartilage graft is fit to the defect width. The ear cartilage graft does not need to entirely cover the defect; it is sufficient to only interpose the defect. Then, the harvested mucosa is sutured to the defect margin using an absorbable suture. Next, the cartilage graft is sutured to the stumps of the tarsal palate. If there is no residual tarsal palate due to resection, then the cartilage graft is fixed to the canthal tendon or the periosteum (Fig. 1). Finally, the outer layer of the defect is covered by skin flaps from the adjacent region.

We usually use the cheek rotation flap<sup>4</sup> for the lower eyelid. If the defect is located on the lateral side and is transversally long, then the lateral orbital flap<sup>5</sup> is chosen. The medial forehead flap is an option for a large defect of the upper eyelid. When the medial canthus is involved, transposition flaps from the dorsum of nose are used. When the defect includes an eyelid margin, the suture line of the skin flap and the mucosal graft form an eyelid margin. Consequently,

the grafted mucosa is circumferentially in contact with tissue that has a blood supply. The ear cartilage graft is sandwiched between the mucosa graft and the skin flap (Fig. 1).

**RESULTS**

We used this technique for 13 patients with full-thickness eyelid defects after cancer resection. The mean patient age was 70 years (range, 43–83). The length of the follow-up period ranged from 1 to 6 years after surgery (Table 1).

Ten cases involved the lower eyelid, 2 cases involved the lower eyelid including the medial canthus, and 1 case involved the upper eyelid. Skin flaps used for outer layer reconstruction were the lateral orbital flap,<sup>5</sup> cheek rotation flap,<sup>4</sup> medial frontal flap, nasolabial flap, rhomboid flap, and V-Y advancement flap.

There was excessive tear production and the tissue demonstrated swelling soon after surgery. However, this was generally observed with other eyelid reconstruction methods. No patient reported conjunctival or corneal irritation after surgery. During the early postoperative period, the portion of the grafted mucosa in contact with living tissue developed a red color. In contrast, the portion overlying the middle of the grafted cartilage appeared slightly pale. Complete healing of this portion took 1–2 weeks for all patients. We did not observe any contracture of the grafted mucosa.

One patient developed minimal necrosis of the grafted mucosa at the margin in contact with the area of marginal necrosis of the skin flap. However, it healed naturally over the course of 3 weeks without exposure of the grafted cartilage.

One patient who underwent lower eyelid reconstruction developed a minor marginal ectropion of the reconstructed site soon after surgery; this patient did not require revision surgery because of minimal subjective symptoms. In other patients, no postoperative problems such as irritation of the conjunctiva and cornea or turning out of the eyelid margin were observed. No scar contractures occurred in any patient.

The lower lip donor site healed within approximately 2–3 weeks with little or no noticeable scar formation. Deformity of the auricle donor site was almost completely absent.

**Table 1. Patient Demographics**

No.	Age/ Gender	Original Disease	Defect Location	Size of Mucosal Defect (W × H)	Flaps for Outer Layer	Follow-up Period (y)
1	65/M	Sebaceous carcinoma	Lower, outer	22×8 mm	Lateral orbital flap	2.5
2	87/F	Sebaceous carcinoma	Lower, outer	18×8 mm	Lateral orbital flap	2
3	73/M	Sebaceous carcinoma	Lower, outer	12×8 mm	Cheek rotation flap	6
4	70/M	Basal cell carcinoma	Lower, inner (switch flap donor)	15×10 mm	Nasolabial flap	1
5	60/F	Basal cell carcinoma	Lower, medial	12×7 mm	Cheek rotation flap	2
6	43/M	Basal cell carcinoma	Lower, medial	12×8 mm	V-Y flap	3
7	83/M	Basal cell carcinoma	Lower, lateral	17×7 mm	Cheek rotation flap	2
8	65/M	Basal cell carcinoma	Lower, medial	10×8 mm	Cheek rotation flap	2
9	55/F	Basal cell carcinoma	Lower, lateral	20×8 mm	Lateral orbital flap	1
10	79/F	Basal cell carcinoma	Lower, lateral	23×10 mm	Cheek rotation flap	1
11	67/M	Basal cell carcinoma	Upper, subtotal	28×12 mm	Medial forehead flap	2.5
12	83/M	Basal cell carcinoma	Lower, medial and inner canthus	20×18 mm	Cheek rotation flap, rhomboid flap	3
13	78/M	Basal cell carcinoma	Lower, medial and inner canthus	13×12 mm	Cheek rotation flap, rhomboid flap	2

## CASE REPORTS

### Case 1

The patient was a 55-year-old woman with basal cell carcinoma on the lateral side of the lower eyelid margin (Fig. 2). After resection of the lesion, oral mucosa harvested from the inner side of the lower lip was sutured to the mucosal surgical margin. Next, strip-shaped ear cartilage was harvested, interposed and fixed using 4-0 nylon sutures between the stumps of the tarsal plate and the outer canthus ligament (Figs. 3–6). The outer layer was reconstructed with a lateral orbital flap (Figs. 7, 8). Post-operative functional and cosmetic results were acceptable (Figs. 9, 10). Deformity and scar formation of the donor sites were minimal (Figs. 11, 12).

### Case 2

The patient was a 67-year-old man with advanced basal cell carcinoma involving three-quarters of the upper eyelid (Fig. 13). Curative excision required subtotal excision of the upper eyelid. The tissue resection margin was 5 mm from the gross tumor margin and the inner margin was along the conjunctival fornices. The tarsal plate and upper limb of the inner canthus tendon were excised en bloc. The skin defect measured 4×2 cm and the mucosal defect measured 2.5×1.2 cm (Fig. 14).

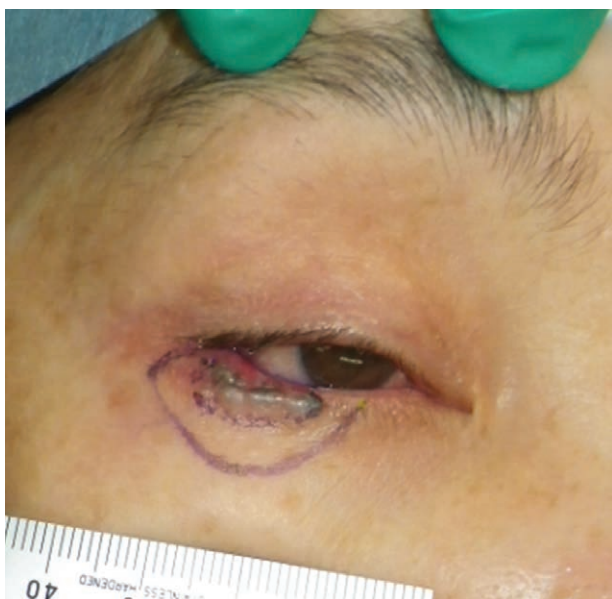
After resection of the lesion, inner layer reconstruction was performed in the same manner as for case 1. Oral mucosa was sutured to the mucosal surgical margin (Fig. 15). The ear cartilage strip was interposed between the stumps of the tarsal plate and the inner canthus ligament. The stump of the levator aponeurosis was sutured to the upper edge of the grafted cartilage, thus completing the inner layer reconstruction (Fig. 16). Finally, a median forehead flap was elevated and sutured to the defect margin (Fig. 17).

The postsurgical course was uneventful. The patient did not report irritation of the bulbar conjunctiva or cornea. The reconstructed eyelid could be fully opened and lagophthalmos was not observed. The cosmetic result was acceptable (Fig. 18).

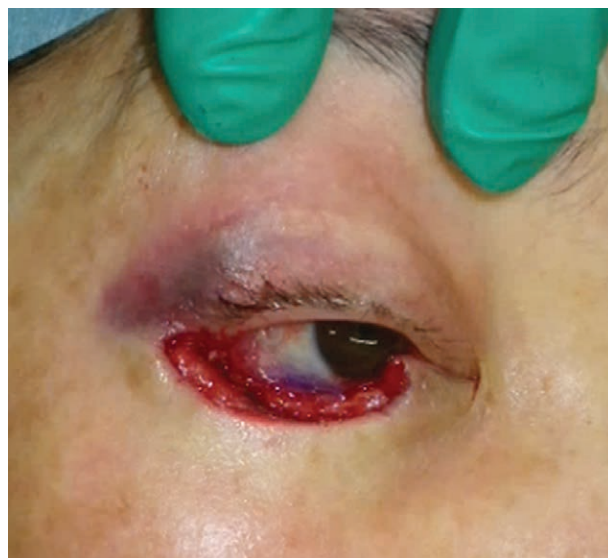## DISCUSSION

Chondromucosal grafts from the nasal septum,<sup>6,7</sup> palatal mucosa grafts,<sup>8</sup> pedicled transfer of composite tissue from the palpebral<sup>4,9–11</sup> or from the dorsum of nose,<sup>12</sup> and conchal cartilage grafts<sup>13</sup> have been reported for reconstruction of the inner layer of the eyelid. However, the applications of these methods are sometimes limited.

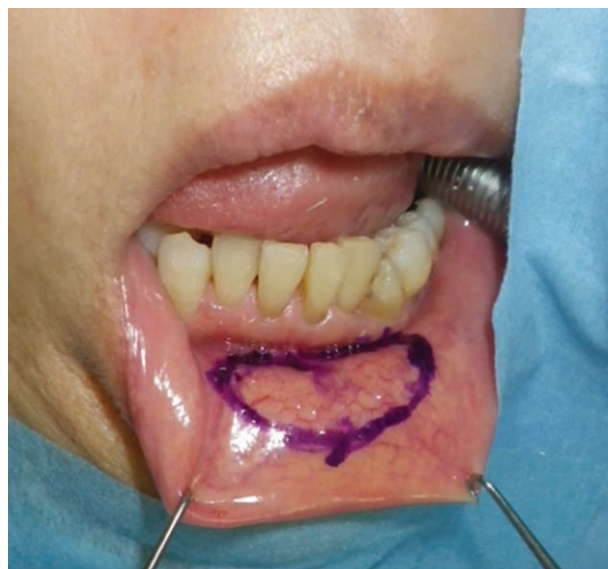Chondromucosal grafts from the nasal septum consist of highly supportable tissue. However, because it is com-



**Fig. 2.** Case 1. Basal cell carcinoma arising in the lower eyelid margin and marking of the incision line.

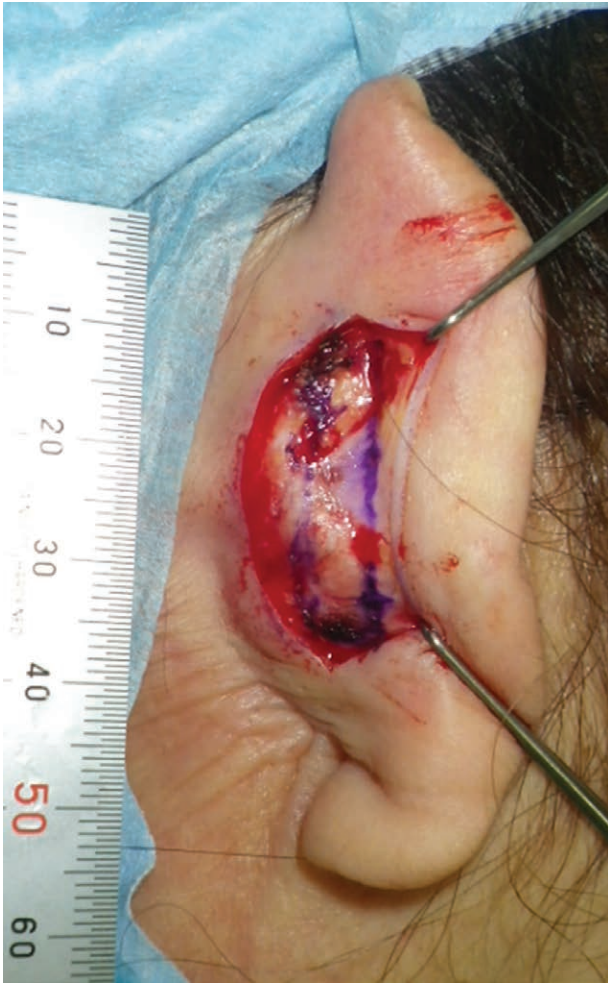

**Fig. 3.** Case 1. Defect after tumor excision.

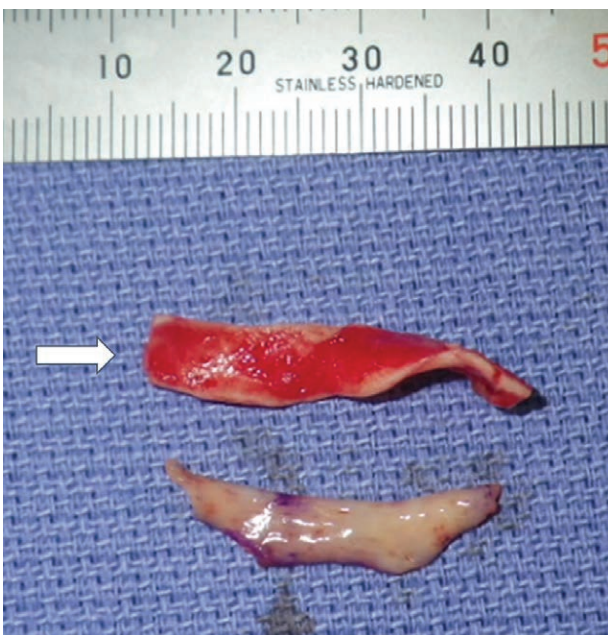

**Fig. 4.** Case 1. Harvesting of the oral mucosa from the lower lip.

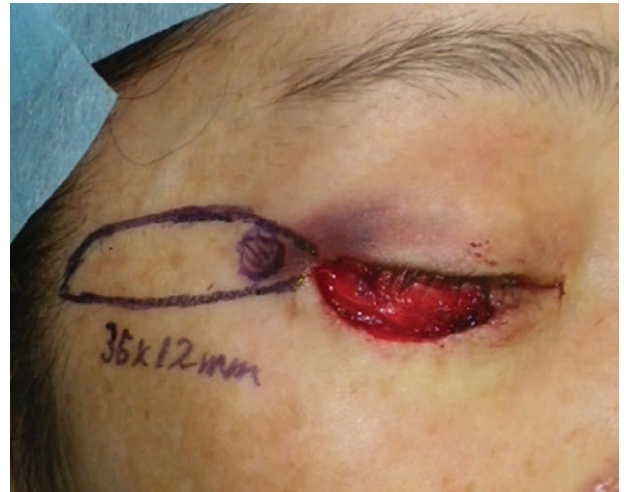



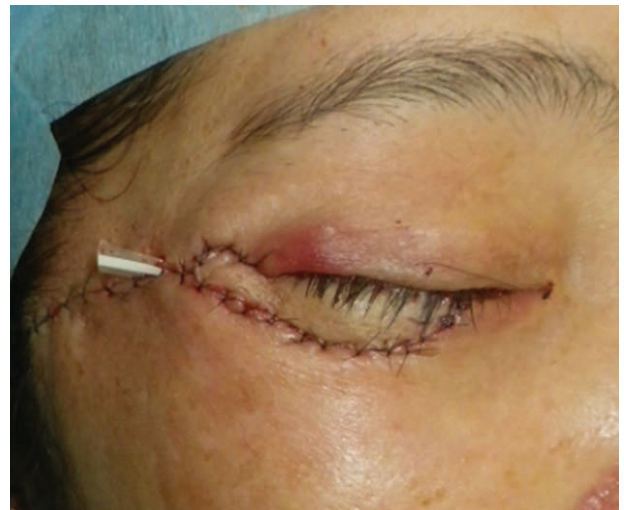**Fig. 5.** Case 1. Harvesting of the ear cartilage strip through the post-auricular incision.



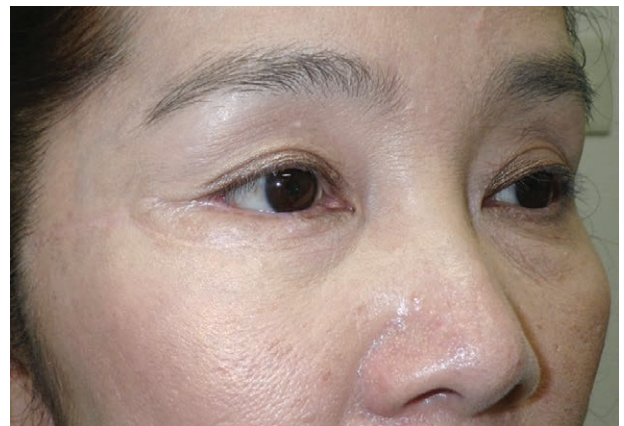
**Fig. 6.** Case 1. Ear cartilage strip graft (arrow) and mucosal graft.



**Fig. 7.** Case 1. Inner layer reconstruction was completed and the lateral orbital flap was marked.

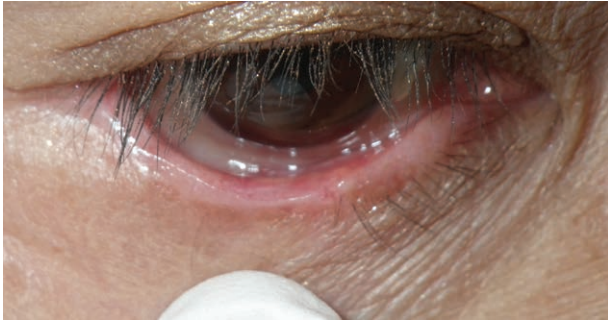


**Fig. 8.** Case 1. Completion of the flap transfer.

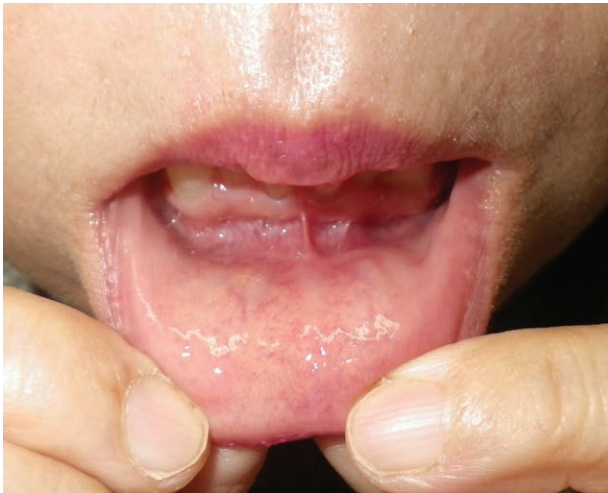

**Fig. 9.** Case 1. One year after surgery.

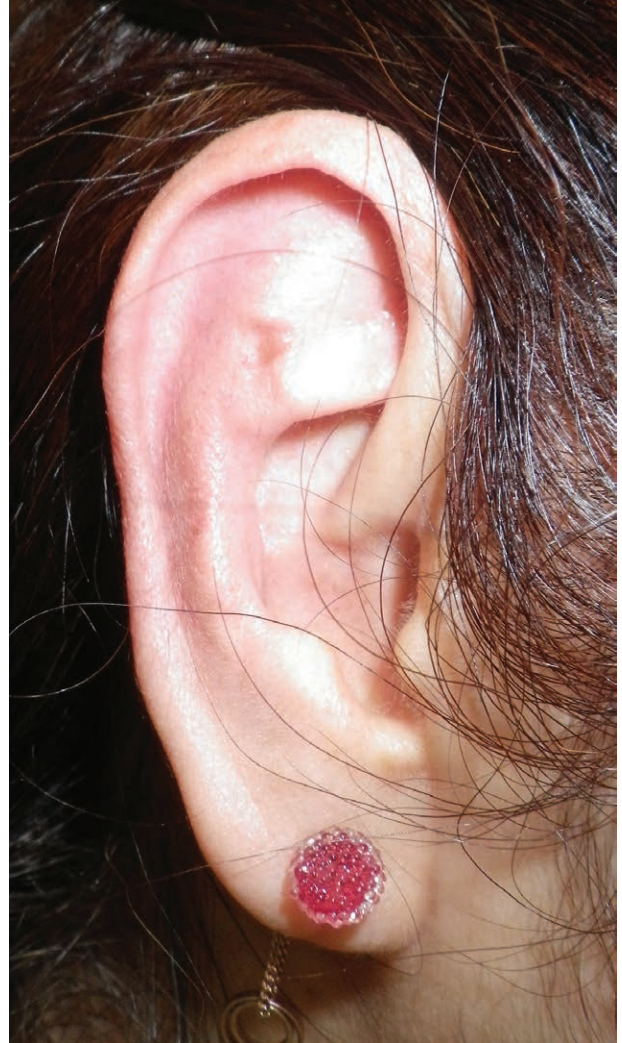



**Fig. 10.** Case 1. Reconstructed eyelid margin 1 year after surgery.



**Fig. 11.** Case 1. View of the donor site of the oral mucosa 6 months after surgery.



**Fig. 12.** Case 1. View of the donor site of the ear cartilage 6 months after surgery.

posed of hyaline cartilage, it lacks softness and flexibility. This may result in difficulty with fabrication and unsuitable contact with the bulbar conjunctiva. In addition, the harvestable size is limited.

Pedicled flaps can transfer composite tissue with adequate blood flow.<sup>4,9-12</sup> However, the surgical procedure is complicated and secondary separation of the pedicle is sometimes necessary.

An ear cartilage graft for lower eyelid reconstruction has been reported as a conchal fossa cartilage graft without an inner lining.<sup>13</sup> Ear cartilage is useful because it is easy to harvest and fabricate, has suitable flexibility, and provides adequate support. However, with the previously reported approach, the defect was covered entirely by conchal cartilage. The graft is in direct contact with the bulbar conjunctiva until the raw surface is epithelialized from the marginal conjunctiva, which takes 3–6 weeks. When it is used for upper eyelid reconstruction, irritation is a concern until total epithelialization occurs.<sup>13</sup> Depending on the defect size and shape, it is difficult to cover defects entirely with this technique.

We successfully used ear cartilage as a strip-shaped graft coupled with oral mucosa for inner layer reconstruction. The characteristics of the present technique are as follows: the procedure is very easy to perform, the harvested grafts are easily fabricated to fit defects with various sizes and

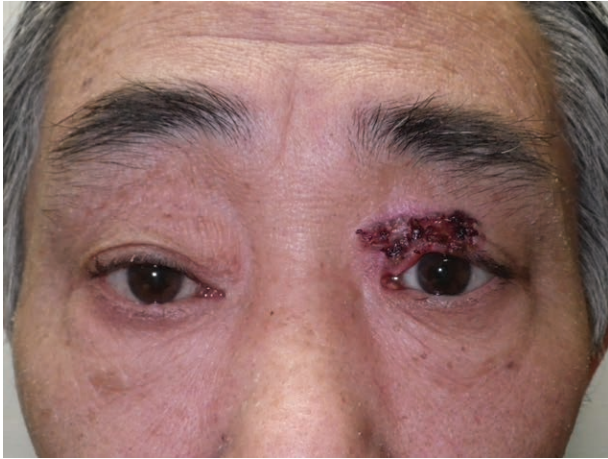shapes, and sacrifice of the donor site is minimal. Although the grafts should be harvested from the 2 sites involved in our technique, we did not encounter any problems.

The success of the mucosal graft overlying the grafted cartilage is probably due to angiogenesis caused by contact with living tissue at the surgical margin. In addition, we believe tears have positive effects. Tears are richly oxygenated and thus contribute to oxygen delivery to the superficial corneal layer. This mechanism is one potential factor allowing for survival of the grafted mucosa.

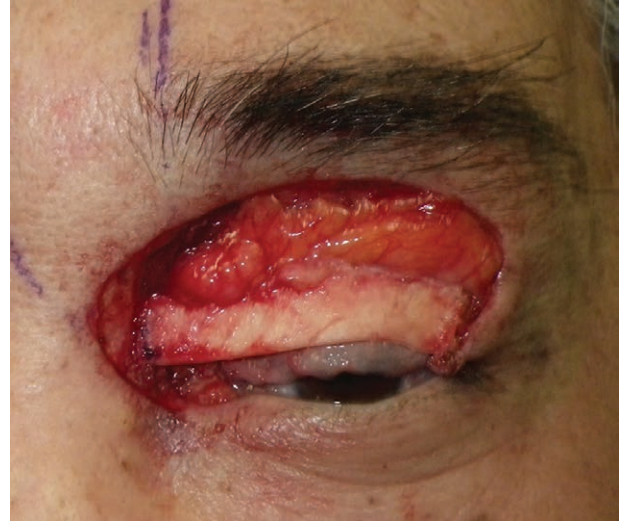A minor marginal ectropion seen in one patient was due to the cartilage strip graft being slightly longer than the defect width. The length of the cartilage strip should be equal to or slightly smaller than the defect width.

Regarding reconstruction of full-thickness defects of the upper eyelid, we are of the opinion that pedicled full-thickness composite tissue transfer, such as the Cutler-Bread method<sup>11</sup> or Mustrade method (switch flap),<sup>4</sup> is the best option in terms of cosmetic and functional results. Eyelash reconstruction is particularly important for the upper eyelid. Therefore, we usually choose to

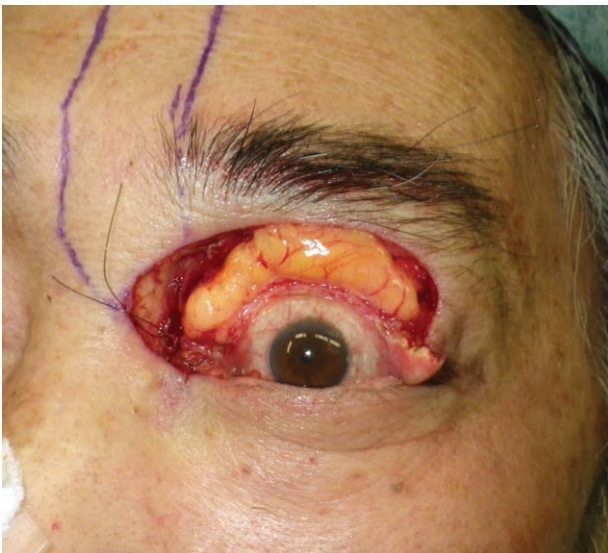



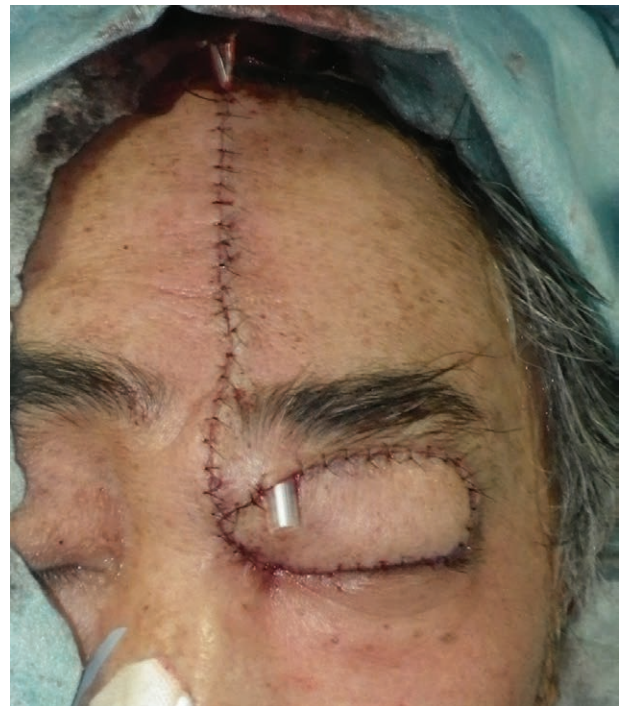**Fig. 13.** Case 2. Preoperative view.



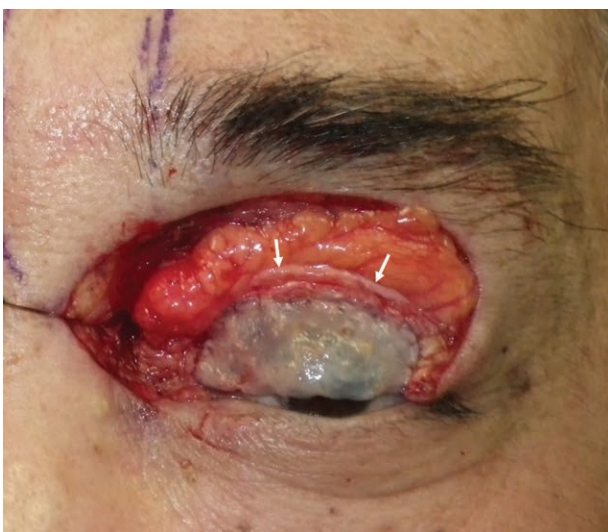**Fig. 16.** Case 2. Completion of inner layer reconstruction. The ear cartilage strip graft was fixed to the stumps of the inner canthus tendon and the tarsal palpe. The levator stump was sutured to the upper edge of the cartilage graft.



**Fig. 14.** Case 2. Defect after tumor resection.



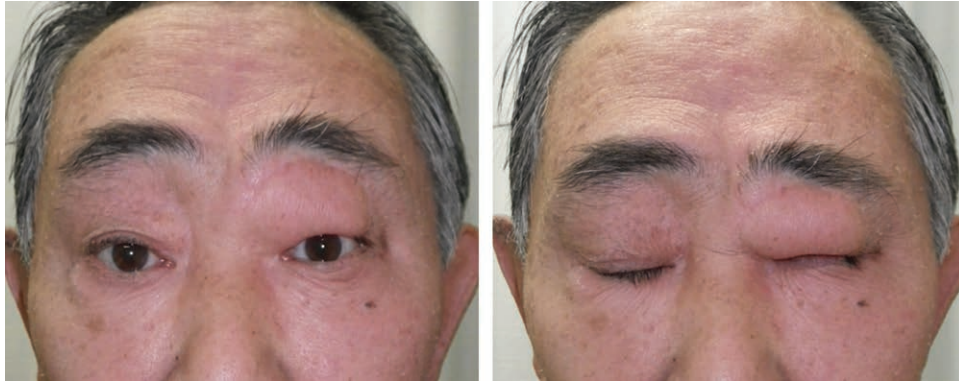
**Fig. 17.** Case 2. The outer layer was reconstructed with a medial forehead flap.



**Fig. 15.** Case 2. The mucosal graft was sutured at the tissue margin. Arrows indicate the stump of the levator aponeurosis.

create a switch flap from the lower eyelid and use the present method to reconstruct the donor of the switch flap.

We believe that the present method is applicable for defects of the inner layer only, full-thickness lower eyelid defects, full-thickness upper eyelid defects for which the pedicled full-thickness flaps cannot be applied (as in case 1), and defects of both the upper and lower eyelids.



**Fig. 18.** Case 2. Two years after surgery.

### CONCLUSION

The present technique using a combination of an ear cartilage strip graft and oral mucosa graft is an easy and versatile technique for reconstruction of inner layer eyelid defects.

**Naoto Yamamoto, MD, PhD**

Department of Plastic and Reconstructive Surgery  
New Tokyo Hospital  
1271, Wanagaya, Matsudo  
Chiba 270-2232, Japan  
E-mail: fwii6869@nifty.com

### PATIENT CONSENT

*Patients provided consent for the use of their image.*

### REFERENCES

1. Tyers AG, Collin JRO. Eyelid reconstruction: Eyelid margin closure. In: Tyers AG, Collin JRO, eds. *Color Atlas of Ophthalmic Plastic Surgery*. 3rd ed. Butterworth-Heinemann: Oxford, UK; 2007:349–362.
2. Tenzel RR. Reconstruction of the central one half of an eyelid. *Arch Ophthalmol*. 1975;93:125–126.
3. Yamamoto N, Yanagibayashi S, Yoshida R, et al. 2-Octylcyanoacrylate skin adhesive used as a splinting material in auricular surgery. *Modern Plastic Surg*. 2016;6:21–26.
4. Mustradé JC. *Repair and Reconstruction in the Orbital Region*. 3rd ed. Edinburgh: Churchill Livingstone; 1991.
5. Takikawa M, Nambu M, Kato M, et al. Two cases of lower eyelid repair with lateral orbital flap after sebaceous carcinoma resections. *Skin Surg*. 2007;16:13–17 (written in Japanese).
6. Millard DR Jr. Eyelid repairs with a chondromucosal graft. *Plast Reconstr Surg Transplant Bull*. 1962;30:267–272.
7. Mehorta ON. Repairing defects of the lower eyelid with a free chondromucosal graft. *Plast Reconstr Surg*. 1977;59:689–693.
8. Siegel RJ. Palatal grafts for eyelid reconstruction. *Plast Reconstr Surg*. 1985;76:411–414.
9. Hughes WL. New method for rebuilding lower eyelid. Report of a case. *Arch Ophthalmol*. 1937;17:1008–1017.
10. Hewes EH, Sullivan JH, Beard C. Lower eyelid reconstruction by tarsal transposition. *Am J Ophthalmol*. 1976;81:512–514.
11. Cutler NL, Beard C. A method for partial and total upper lid reconstruction. *Am J Ophthalmol*. 1955;39:1–7.
12. Scuderi N, Ribuffo D, Chiummariello S. Total and subtotal upper eyelid reconstruction with the nasal chondromucosal flap: a 10-year experience. *Plast Reconstr Surg*. 2005;115:1259–1265.
13. Matsuo K, Hirose T, Takahashi N, et al. Lower eyelid reconstruction with a conchal cartilage graft. *Plast Reconstr Surg*. 1987;80:547–552.