

Dietary Creatine as a Possible Novel Treatment for Crohn's Ileitis

Abhik Roy, MD, and David Lee, MD

Division of Digestive and Liver Diseases, Columbia University, New York, NY

ABSTRACT

Creatine, a commonly used dietary supplement, plays an important role in maintaining gut barrier function. Given that dysregulation of the intestinal epithelial barrier is a hallmark of inflammatory bowel disease, it is plausible that creatine supplementation may attenuate disease severity. We present a patient with Crohn's ileitis who responded to creatine supplementation with both symptomatic and endoscopic improvement in disease activity.

INTRODUCTION

In the United States, the use of dietary supplements is a multibillion-dollar industry, and creatine (*N*-[aminoimino-methyl]-*N*-methyl-glycine) accounts for \$200 million in sales annually.¹ Although the use of dietary supplements by patients with inflammatory bowel disease (IBD) is common and there is extensive literature about the use of vitamin D, probiotics, curcumin, etc., for the treatment of IBD,^{2,3} the role of creatine has not been extensively studied or reported.

CASE REPORT

A 33-year-old male was referred for evaluation of a 2-year history of hematochezia and anal pain thought secondary to non-healing anal fissures. In addition to rectal bleeding, the patient reported a long history of cramping abdominal pain and loose stools. He denied prior surgeries or endoscopies and had no family history of gastrointestinal (GI) disease. In addition to topical therapy for the presumed anal fissures, the patient was taking creatine hydrochloride 1,034 g/d as a dietary supplement. Proctoscopy did not show anal fissures, but internal hemorrhoids were noted in the left lateral and right anterior/posterior locations, and an anal tag was found left of the midline posteriorly. Initial labs showed normal hemoglobin (15.6 g/dL), C-reactive protein (0.6 mg/L), and fecal calprotectin (37 μ /g).

Given the patient's long-standing GI symptoms, anal tag, and hemorrhoids, a colonoscopy was performed to evaluate for IBD. The colon was normal, and mild inflammation and serpentine ulcerations were found in the terminal ileum (TI) (Figure 1). The Simple Endoscopic Score for Crohn's Disease (SES-CD) in the TI was 4 (aphthous ulcers <0.5 cm in diameter, 10–30% ulcerated surface, <50% affected surface, no narrowing). Biopsies of the TI showed mildly active chronic ileitis, and a computed tomography enterography showed two distinct areas of mucosal hyper-enhancement and thickening in the TI concerning for IBD.

With a new diagnosis of mild Crohn's ileitis, the patient was started on mesalamine (Salix Pharmaceuticals, Raleigh, NC) 1.5 g/d. The patient also stopped his creatine. Over the following 4 months, the patient reported progressively more frequent and severe abdominal pain. A repeat colonoscopy at that time revealed worsening ileitis with

ACG Case Rep J 2016;3(4):e173. doi:10.14309/crj.2016.146. Published online: December 7, 2016.

Correspondence: Abhik Roy, Division of Digestive and Liver Diseases, Columbia University, 622 W 168th St, PH7W Suite 318, New York, NY 10032 (Abhikroy86@gmail.com).



Copyright: © 2016 Roy et al. This work is licensed under a Creative Commons Attribution-NonCommercial-NoDerivatives 4.0 International License. To view a copy of this license, visit <http://creativecommons.org/licenses/by-nc-nd/4.0>.

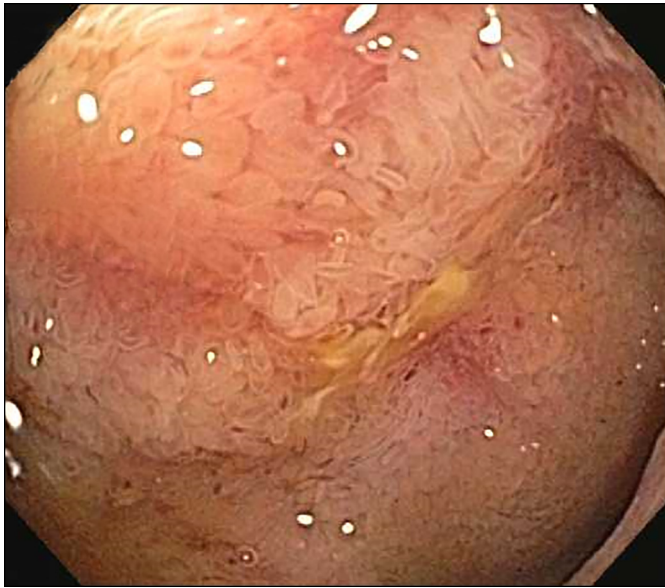

Figure 1. Colonoscopy in March 2015 showing aphthous ulcers <0.5 cm in diameter, 10–30% ulcerated surface, <50% affected surface, and no narrowing (SES-CD: 4).

more extensive ulceration (Figure 2). The SES-CD in the TI was 7 (ulcers 0.5–2.0 cm in diameter, >30% ulcerated surface, 50–75% affected surface, no narrowing).

Given this progressive ileitis, more intensive therapy was planned. Prior to initiating new agents, however, the patient requested a trial of his previous creatine hydrochloride supplement, as he felt his symptoms were better on the creatine supplement and worsened once it was stopped. Upon stopping mesalamine and reinitiating creatine hydrochloride at

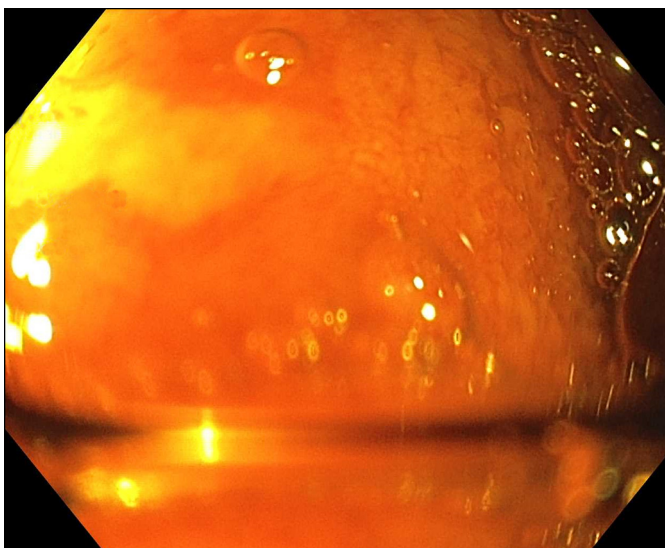


Figure 2. Colonoscopy in July 2015 showing large ulcers 0.5–2.0 cm in diameter, >30% ulcerated surface, 50–75% affected surface, and no narrowing (SES-CD: 7).

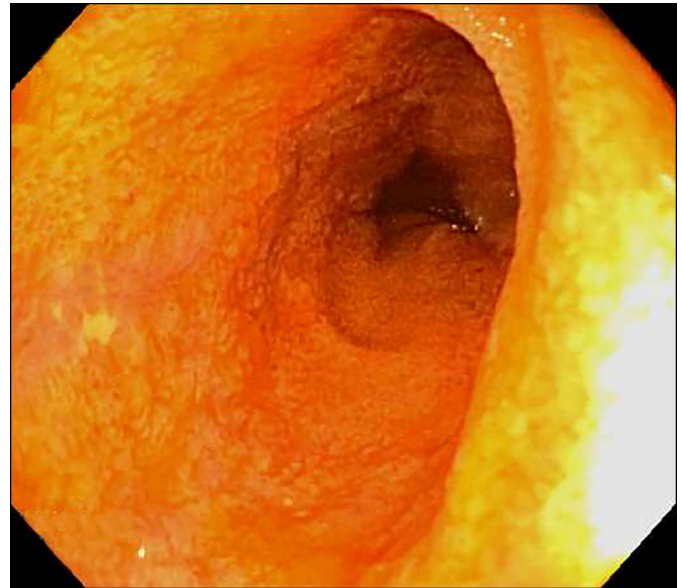


Figure 3. Colonoscopy in December 2015 showing aphthous ulcers <0.5 cm in diameter, <10% ulcerated surface, <50% affected surface, and no narrowing (SES-CD: 3).

1,034 g/day, the patient reported a significant improvement in his symptoms. A repeat colonoscopy was performed 6 months later to assess endoscopic Crohn's activity on “creatine monotherapy.” The prior extensive ulceration and inflammation in the TI appeared significantly improved, and only one, small aphthous ulcer was seen (Figure 3). The SES-CD in the TI was 3 (aphthous ulcers <0.5 cm in diameter, <10% ulcerated surface, <50% affected surface, no narrowing). On the basis of these findings and patient preference, therapy with creatine was continued. To distinguish the therapeutic effects of creatine from the naturally relapsing/remitting course of IBD, we plan regular surveillance of the patient's disease activity using biomarkers and endoscopy.

DISCUSSION

Creatine is an endogenous molecule synthesized in the kidney, liver, and pancreas, and it is found in all cells of the body.⁴ The most well-understood role of creatine is in energy production, as the reciprocal conversion of creatine to phosphocreatine allows for the regeneration of intracellular adenosine triphosphate using the creatine kinase (CK) reaction. Creatine is often used as a dietary supplement to increase muscle mass and enhance anaerobic exercise performance.^{5,6}

To date, the GI benefits of creatine have not been well studied. Two reports in 1999 and 2000 suggested that creatine might inhibit colon cancer growth.^{7,8} More recently, a murine study showed that the enzymes involved in creatine metabolism, the CKs, are coupled to the apical junctional complex of intestinal epithelium and maintain gut barrier function.⁹ When the CK pathway was disrupted in colitis models, junctional

assembly and barrier integrity were compromised. Dietary creatine supplementation, however, significantly attenuated the severity of colitis. Most interestingly, special staining of colon biopsy sections from human IBD patients showed altered expression of mitochondrial and cytosolic CK enzymes and an overall decrease in transcript levels of CK. These findings highlight the important role played by creatine metabolism in intestinal mucosal function and colitis resolution.

While clinical trials are now underway to study the effects of dietary creatine on mucosal inflammation in IBD, ours is the first reported case of a patient with IBD who experienced significant clinical improvement with creatine supplementation.¹⁰ Importantly, we have documented worsening symptoms and mucosal ulceration/inflammation when creatine was stopped, followed by improvement in both parameters with the reinstitution of creatine monotherapy. Despite our observations, we point out that creatine supplementation is neither regulated by the United States Food and Drug Administration nor approved for the treatment of IBD. Further, there is no standard dosing of creatine, and its use can be expensive and associated with side effects including weight gain and muscle cramps.¹

In addition to the potential therapeutic role of creatine, our case demonstrates two important concepts in the management of IBD. First, the new paradigm of “treat-to-target” in IBD involves serial objective evaluations of inflammatory burden through endoscopic, radiologic, and biochemical parameters. Following the algorithm proposed by Bouguen et al in 2015, we pursued regular endoscopic assessments in our patient with newly diagnosed Crohn's ileitis.¹¹ This allowed us to adjust treatment on the basis of our target of achieving mucosal healing. Second, our case demonstrates the importance of utilizing a standardized scoring tool for assessing endoscopic disease activity. Our rigorous photographic documentation and use of the SES-CD allowed us to compare the findings from serial endoscopies to determine how our patient's mucosal ulceration and inflammation responded to therapy.¹² In an era when mucosal healing is proposed as the ideal target for IBD therapy, employing a simple and reproducible endoscopic scoring system is invaluable.

DISCLOSURES

Author contributions: A. Roy acquired the data, wrote and revised the manuscript, and is the article guarantor. D. Lee acquired the data and revised the manuscript.

Financial disclosure: None to report.

Informed consent was obtained for this case report.

Received April 17, 2016; Accepted July 7, 2016

REFERENCES

1. Schnirring L. Creatine supplements face scrutiny: Will users pay later? *Phys Sports Med*. 1998;26:15–23.
2. Gerasimidis K, McGrogan P, Hassan K, Edwards CA. Dietary modifications, nutritional supplements and alternative medicine in paediatric patients with inflammatory bowel disease. *Aliment Pharmacol Ther*. 2008;22(2):155–65.
3. Parian A, Limketkai BN. Dietary supplement therapies for inflammatory bowel disease: Crohn's disease and ulcerative colitis. *Curr Pharm Des*. 2016;22(2):180–8.
4. Bloch K, Schoenheimer R. The biological precursors of creatine. *J Biol Chem*. 1941;138(1):167–94.
5. Walker JB. Creatine: Biosynthesis, regulation, and function. *Adv Enzymol Relat Areas Mol Biol*. 1979;50:177–242.
6. Riesberg LA, Weed SA, McDonald TL, et al. Beyond muscles: The untapped potential of creatine. *Int Immunopharmacol*. 2016;S1567–5769.
7. Kirstensen CA, Askenasy N, Jain RK, Koretsky AP. Creatine and cyclo-creatine treatment of human colon adenocarcinoma xenografts: 31P and 1H magnetic resonance spectroscopic studies. *Br J Cancer*. 1999;79(2):278–85.
8. Wyss M, Kaddurah-Daouk R. Creatine and creatinine metabolism. *Physiol Rev*. 2000;80(3):1107–213.
9. Glover LE, Bowers BE, Saeedi B, et al. Control of creatine metabolism by HIF is an endogenous mechanism of barrier regulation in colitis. *Proc Natl Acad Sci U S A*. 2013;110(49):19820–5.
10. University of Colorado, Denver. Therapeutic Modulation of the Intestinal Creatine Kinase System in Inflammatory Bowel Disease (IBD). 2016. Available: <https://clinicaltrials.gov/ct2/show/NCT02463305> NLM Identifier: NCT02463305.
11. Bouguen G, Levesque BG, Feagan BG, et al. Treat to target: A proposed new paradigm for the management of Crohn's disease. *Gastroenterol Hepatol*. 2015;13(6):1042–50.
12. Daperno M, D'Haens G, Van Assche G, et al. Development and validation of a new, simplified endoscopic activity score for Crohn's disease: The SES-CD. *Gastrointest Endosc*. 2004;60:505–12.