



# Difference and ratio of the cross-sectional area of median nerve at the carpal tunnel and the pronator quadratus muscle in diagnosing carpal tunnel syndrome: a cross-sectional study

Cheng Xu<sup>1,2#</sup>, Yang Zhou<sup>3#</sup>, Zhou He<sup>4#</sup>, Wei Liu<sup>3#</sup>, Meilin Zou<sup>5</sup>, Yanjun Sun<sup>3</sup>, Jinxin Qiu<sup>3</sup>, Yuting Ren<sup>6</sup>, Guomin Mao<sup>6</sup>, Yue Wang<sup>6</sup>, Qinghua Xi<sup>3</sup>, Yuehua Chen<sup>7</sup>, Bin Zhang<sup>1,2</sup>

<sup>1</sup>Department of Imaging, Affiliated Hospital of Nantong University, Nantong, China; <sup>2</sup>Department of Infectious Diseases, Affiliated Hospital of Nantong University, Nantong, China; <sup>3</sup>Department of Obstetrics and Gynecology, Affiliated Hospital of Nantong University, Nantong, China; <sup>4</sup>Department of Orthopaedics, Dongtai People's Hospital, Yancheng, China; <sup>5</sup>Department of Obstetrics and Gynecology, Rugao People's Hospital, Nantong, China; <sup>6</sup>Department of Emergency Medicine, Affiliated Hospital of Nantong University, Nantong, China; <sup>7</sup>Department of Imaging, Nantong Third People's Hospital, Nantong, China

**Contributions:** (I) Conception and design: C Xu, Y Chen; (II) Administrative support: Q Xi, B Zhang; (III) Provision of study materials or patients: Y Sun, J Qiu; (IV) Collection and assembly of data: Y Zhou, M Zou, Z He; (V) Data analysis and interpretation: Y Ren, W Liu; (VI) Manuscript writing: All authors; (VII) Final approval of manuscript: All authors.

<sup>#</sup>These authors contributed equally to this work and should be considered as co-first authors.

**Correspondence to:** Bin Zhang. Department of Infectious Diseases, Affiliated Hospital of Nantong University, Nantong 226001, China. Email: tdfy Zhangb@163.com; Yuehua Chen. Department of Imaging, Nantong Third People's Hospital, Nantong 226006, China. Email: cyh810917@163.com; Qinghua Xi. Department of Obstetrics and Gynecology, Affiliated Hospital of Nantong University, 20 West Temple Road, Nantong 226001, China. Email: ntdxfsyxqh@163.com.

**Background:** At present, the most commonly used diagnostic method of carpal tunnel syndrome (CTS) is based on clinical manifestations and electrophysiology, but the electrophysiology is not cheap, invasive, and lacks the presentation of peripheral nerve conditions, which is exactly the advantage of ultrasound (US). The purpose of this study was to evaluate the accuracy and effectiveness of US in the diagnosis of CTS by calculating the cross-sectional area (CSA) at the carpal tunnel and proximally at the level of the pronator quadratus muscle., and to find an appropriate index that can be used to achieve the diagnosis in a more cost-effective manner.

**Methods:** Forty-three wrists from 35 symptomatic CTS patients and 23 wrists from 18 asymptomatic volunteers were evaluated. Diagnosis in the CTS group was based on the American Academy of Neurology clinical diagnostic criteria. The ultrasonic probe was placed at the carpal tunnel and the distal 1/3 of the pronator muscle respectively, and the carpal tunnel cross-sectional area (CSAC) and the proximal cross-sectional area (CSAP) was calculated, with a further calculation of their difference ( $\Delta$ CSA) and ratio (R-CSA).

**Results:** There was a significant difference between the 2 groups regarding mean  $\pm$  standard deviation (SD) of CSAC, CSAP,  $\Delta$ CSA, and R-CSA ( $P < 0.01$ ). The cutoff value of 12.14 mm<sup>2</sup> for CSAC had a sensitivity and specificity of 90.7% and 100%, respectively; the cutoff value of 1.235 mm<sup>2</sup> for R-CSA had a sensitivity and specificity of 97.67% and 95.65%, respectively; and the cutoff value of 2.035 mm<sup>2</sup> for  $\Delta$ CSA had a sensitivity and specificity of 100% and 100%, respectively. Therefore, US was found to be an effective method for the diagnosis of CTS. Receiver operating characteristic curve (ROC) analysis of all patients showed area under the curve (AUC) was 0.9778 for CSAC, 0.9949 for R-CSA and 1.000 for  $\Delta$ CSA.

**Conclusions:** US can provide reference values for the diagnosis of CTS. CSAC,  $\Delta$ CSA, and R-CSA can be used for CTS diagnosis and evaluation. The ROC curve analysis showed that among the 3 values,  $\Delta$ CSA was the most useful in the diagnosis of patients with CTS.  $\Delta$ CSA is considered a valid diagnostic value for CTS, as its threshold of 2.04 mm<sup>2</sup> showed the highest sensitivity and specificity.

**Keywords:** Carpal tunnel syndrome (CTS); ultrasound (US); median nerve (MN); cross-sectional area (CSA)

Submitted Dec 31, 2021. Accepted for publication Mar 21, 2022.

doi: 10.21037/atm-22-1128

View this article at: <https://dx.doi.org/10.21037/atm-22-1128>

## Introduction

Carpal tunnel syndrome (CTS) is the most common peripheral nerve compression neuropathy in the upper limb (1-3), affecting about 3% to 6% of the general population and up to 14.5% among specific occupational groups (4,5). CTS results from compression of the median nerve (MN) at the wrist as it passes through a narrow, osteofibrous canal (6). CTS can be primary or secondary to other conditions such as flexor tenosynovitis, ganglion cyst, gouty tophi, bone deformity, arthritis, or tumor (7). Age has a significant impact on incidence, with incidence in women increasing with age and reaching a peak between 50 and 59 years. For men, CTS peaks at ages 50 to 59 and 70 to 79 (8). CTS is associated with certain occupations, particularly those involving hand motions with high intensity and frequency of repetition. A systematic literature review (9) reported that regular and prolonged use of hand-held vibratory tools increases the risk of CTS >2-fold. In addition to work-related risks, suspected risk factors for CTS include but are not limited to diabetes, menopause, hypothyroidism, obesity, arthritis, and pregnancy (6,10). The classic presentation of CTS is radiating pain, numbness, and tingling sensations. Paresthesias is not limited to the MN innervation region, but can involve the whole hand in a glove-shaped distribution (11). Symptoms are worse at night, and nocturnal awakening is common. In advanced cases, patients can experience muscle atrophy or paralysis (12-14). Therefore, early diagnosis is essential to reduce permanent neurological injury and functional disability.

Currently, the typical CTS diagnostic process involves making a preliminary diagnosis based on clinical manifestations, which is then confirmed by other examinations. Electrodiagnostic testing (EDT), which assesses physiologic malfunctions of the MN, is the most important auxiliary examination for the diagnosis of CTS. EDT can indicate the severity of the MN injury, but cannot reveal histomorphological changes of the MN and its peripheral tissue. EDT has a false negative rate of 5–10% (6,15), and these false-negative cases may be due to the onset of symptoms preceding impaired nerve conduction of myelinated sensory fibers.

Ultrasound (US) is a diagnostic imaging modality that can

depict structural abnormalities caused by nerve swelling (16). Compared with EDT, US can be used not only to confirm the diagnosis and evaluation of CTS but also to distinguish between primary and secondary CTS (17). US provides insight into the causes of lesions and can inform subsequent surgical methods. A meta-analysis comparing the sensitivity and specificity of US with clinical diagnosis or EDT concluded that although US may not replace EDT, it may be a feasible alternative to EDT as a first-line confirmatory test (18). This finding has been validated by other studies (19-22).

Ultrasonic diagnostic indexes for CTS include the following parameters (23,24): transverse carpal ligament (TCL), MN cross-sectional area (CSA), MN blood flow exploration, and flattening ratio (FR), as well as palmar retinacular bowing (BR), and carpal tunnel volume. Among these parameters, measurement of the MN CSA is the most discriminatory and frequently used criteria of CTS (7). However, the MN CSA is greatly affected by individual factors such as race, gender, occupation, and body mass index (BMI) (25), making it difficult to establish a universal cutoff threshold to distinguish between control subjects and patients with CTS. We need to find a way through the noninvasive US examination, and the result is not influenced by individual factors. To solve this problem, more US parameters have been introduced to compensate for individual differences, such as the difference and ratio between the MN CSA at the carpal tunnel and the forearm, the ratio between the MN CSA and the carpal tunnel cross-sectional area (CSAC), and the difference and ratio between the MN CSA at the entrance and outlet of the carpal tunnel bone marker. One study (26) suggested that the MN CSA should be measured at the proximal 1/3 of the anterior pronator muscle, as this measurement value had the best repeatability. The difference ( $\Delta$ CSA) and ratio (R-CSA) between the proximal cross-sectional area (CSAP) and the CSAC can better make up for individual differences and thus offer more advantages than either CSAC or CSAP alone in diagnosis accuracy.

The purpose of our study was to assess the accuracy of US in CTS diagnosis by analyzing differences in CSAC, CSAP,  $\Delta$ CSA, and R-CSA between patients with CTS and healthy control subjects. The results of the CSA cutoff

analysis using receiver operating characteristic (ROC) curves may be helpful in the diagnosis of CTS. We present the following article in accordance with the STARD reporting checklist (available at <https://atm.amegroups.com/article/view/10.21037/atm-22-1128/rc>).

## Methods

### *Study design*

This study is a cross-sectional study, which collects the distribution of factors related to CTS in a specific population at a specific time point and within a specific range, so as to provide clues for further research on the etiology.

### *Participants*

Thirty-five patients (43 wrists) with CTS who were presented to the Affiliated Hospital of Nantong University between 2020 and 2021 underwent US evaluation, and 18 healthy subjects without CTS underwent an identical US evaluation as a control group. The project was approved by the Ethics Committee of Affiliated Hospital of Nantong University (No. 2019-L002) and was conducted in accordance with the Declaration of Helsinki (as revised in 2013). All patients signed informed consent prior to participation.

### **Inclusion criteria**

The inclusion criteria which was based on the clinical diagnostic criteria of the American Academy of Neurology were as follows: (I) numbness or pain on the radial side of the thumb, index finger, middle finger, or ring finger of the affected limb, which was aggravated by certain activities and relieved after resting or swinging the hands; (II) sensory disturbance or weakness in three-and-a-half fingers on the radial side; (III) atrophy of the thenar muscle to varying degrees; (IV) Tinel test and/or Phalen test is positive; and (V) the MN sensory conduction velocity (SCV) slows down or the latency is prolonged. CTS can be diagnosed in patients who meet 2 or more of diagnostic criteria 1–4 and criteria 5.

### **Elimination criteria**

Patients with MN diseases outside the wrist such as cervical spondylosis, brachial plexus injury, Struthers' ligament compression, pronator teres syndrome, neuritis, MN injury, or neuroma were excluded.

### *General clinical parameters*

#### **Electrophysiological diagnosis of abnormal criteria**

A difference of >0.4 ms between the median and ulnar sensory peak latencies or a prolonged median distal motor latency of >4 ms was taken as confirmatory electrophysiological evidence of CTS (27).

#### **MN normal sonographic findings**

In the two-dimensional US image, the nerve fibers were hypoechoic, the endoneurium and epineurium were linear hyperechoic, and the cross section of the MN was sieve-like with short-streak blood stream signals detected by the color Doppler. Nine medium hyperechoic tendons could be seen around and behind the nerve, and the hyperechoic TCL covered the surface of the carpal tunnel.

### *US technique*

Patients with CTS received cross-section examinations of the affected wrist, while healthy controls were randomly assigned a unilateral or bilateral wrist examination. Patients in both groups were examined by the same examiner, who had over 15 years of US experience and was blinded to the patients' clinical information or reference standard results. A GE Logiq E9 color Doppler US instrument (GE Healthcare, Chicago, IL, USA) was used in the study, and the frequency of the superficial line array probe was set at 12–15 MHz to examine the patient's musculoskeletal tissue.

### **Examination method**

The patient sat by the examination bed with the arm in a neutral position (the palm flat on the bed, the forearm relaxed, and the wrist slightly extended). During the examination, the scanning area was coated with a thick coupling agent, and the probe was lightly attached to the skin surface to avoid the deformation and displacement of the MN caused by the probe pressure. The technician first performed longitudinal scanning along the long axis of the MN with a US probe to observe the position, route, and anteroposterior diameter of the patient's carpal tunnel MN and to further determine the compressed and swollen areas. The probe then transected across the MN and remained perpendicular to it so that the MN was in the middle of the probe. The image was then observed and the MN CSA is measured by trajectory method. The examiner next

**Table 1** Comparison of demographic data in the 2 groups

Age (years)	CTS group, n (%)			Control group, n (%)		
	Male	Female	Total	Male	Female	Total
20–29	0	0	0 (0.0)	1	4	5 (27.8)
30–39	3	1	4 (11.4)	0	1	1 (5.6)
40–49	1	10	11 (31.4)	1	2	3 (16.7)
50–59	1	11	12 (34.3)	2	4	6 (33.3)
60–69	2	4	6 (17.1)	0	2	2 (11.1)
70–79	0	1	1 (2.9)	1	0	1 (5.6)
80–89	0	1	1 (2.9)	0	0	0 (0.0)
Total	7 (20.0)	28 (80.0)	35 (100.0)	5 (27.8)	13 (72.2)	18 (100.0)

CTS, carpal tunnel syndrome.

**Table 2** Comparison of chronic diseases in the 2 groups

Group	Chronic disease		Total	Positive incidence	$\chi^2$	P value
	With	Without				
CTS group	3	32	35	8.6%	0.42	0.51
Control group	0	18	18	0.0%		
Total	3	50	53	5.7%		

CTS, carpal tunnel syndrome.

moved the probe along the forearm to the distal third of the pronator quadratus muscle and measured the MN CSA with the same method. All measurements were taken three times for a median value (28,29). At last, the difference ( $\Delta$ CSA) and ratio (R-CSA) between CSAC and CSAP was calculated in both patients and controls.

### Statistical analysis

Prism 6 (GraphPad Software Inc., San Diego, CA, USA) and SPSS version 26 (IBM Corp., Armonk, NY, USA) statistical software were used for data analysis. The quantitative data were expressed as mean  $\pm$  standard deviation (SD), while enumeration data were expressed as constituent ratio or rate (%). The CTS group and the healthy control group were compared using a *t*-test for the CSAC, CSAP,  $\Delta$ CSA, and R-CSA measurements, and a chi-squared test was used to assess the occurrence of chronic disease and prior surgery among the study groups. A ROC curve was plotted for the CSAC,  $\Delta$ CSA, and R-CSA measurements and used to calculate the cutoff values which

provided the highest sensitivity, specificity, and accuracy for predicting CTS. In all analyses,  $P < 0.05$  indicated a statistically significant difference.

## Results

### Baseline characteristics of the subjects

#### CTS group

This group comprised 43 wrists of 35 patients, including 7 men (mean age, 52.8 years; range, 34–61 years) and 28 women (mean age, 53.3 years; range, 34–82 years), with an overall mean age of 53.3 years and an overall range of 34–82 years. There were 27 right wrists and 16 left wrists in the group. Eight patients had bilateral CTS, and 15 patients had received surgical treatment.

#### Control group

This group comprised 23 wrists of 18 healthy volunteers with no clinical signs or symptoms of CTS, including 5 males (mean age, 42.0 years; range, 26–63 years) and 13 females (mean age, 50.0 years; range, 28–78 years), with an overall mean age of 42.0 years and an overall range of 26–78 years. The demographic data of the CTS and control groups are outlined in *Table 1*.

### Clinicopathological parameter correlation

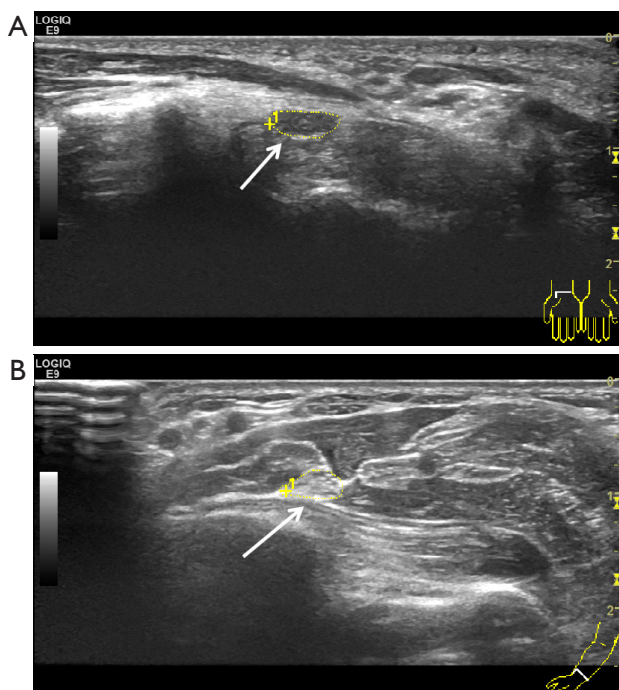
Three patients in the CTS group had chronic diseases (complicated diabetes mellitus, hypertension, and chronic pneumonia), while no participants in the control group had



**Table 3** Comparison of surgical history in the 2 groups

Group	Surgical history		Total	Positive incidence	$\chi^2$	P value
	With	Without				
CTS group	7	28	35	20.0%	2.59	0.12
Control group	0	18	18	0%		
Total	7	36	43	16.3%		

CTS, carpal tunnel syndrome.



**Figure 1** Control group. The arrow indicates the cross-sectional area to be measured. (A) CSAC was 11.02 mm<sup>2</sup>; (B) a more CSAP obtained in the distal forearm at the level of the proximal third of the pronator quadratus muscle was 9.62 mm<sup>2</sup>;  $\Delta$ CSA and R-CSA were 1.40 and 1.14 mm<sup>2</sup>, respectively.  $\Delta$ CSA, the difference of CSAC and CSAP; R-CSA, the ratio of CSAC and CSAP; CTS, carpal tunnel syndrome; CSAC, carpal tunnel cross-sectional area; CSAP, proximal cross-sectional area.

chronic diseases. These data were statistically processed with a chi-squared test using SPSS version 26 (Table 2). There was no statistical significance ( $P > 0.05$ ). However, a previous meta-analysis (30) found that both type 1 and type 2 diabetes are associated with the occurrence of CTS. In our CTS group, 1 case was a diabetic, and the chi-squared test showed no statistical significance. Considering the small sample size of this study, the effect was small.

Seven patients in the CTS group had an operative history (complicated rib fractures, caesarean section, appendix resection, lumbar spine surgery, contralateral CTS incision decompression, gynecological operation, and radical mastectomy), while no participants in the control group had a history of surgery or trauma. These data were statistically processed with a chi-squared test using SPSS version 26 (Table 3). There was no significant difference ( $P > 0.05$ ).

### Comparison of US results

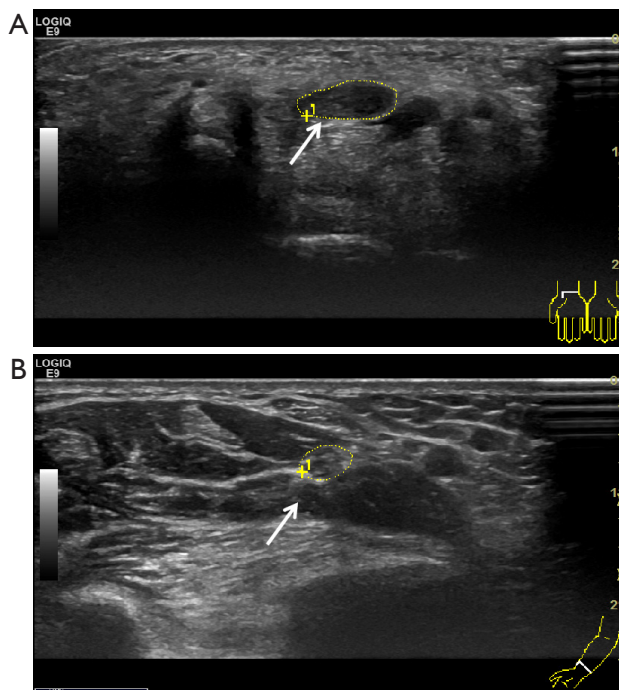
In the control group, there was little change in the CSA and anteroposterior diameter of the MN, as shown in Figure 1. In the CTS group, obvious compression of the MN at the carpal tunnel was observed at the hook of the hamate bone, the MN was significantly thickened at the carpal tunnel inlet, and the transverse area was enlarged. On the longitudinal section, the MN was uneven in thickness and had a notch at the lamping position, the echo of the internal nerve bundle membrane was decreased, and the nerve was grid-form blurred (Figure 2).

### Electrophysiological analysis

In the control group (Figure 3A), SCV, motor nerve conduction velocity (MCV), and F waves were within the normal range. In the CTS group (Figure 3B), there was no spontaneous potential in resting state, and the motor unit potential (MUP) time and potential of light contraction were normal. MCV was slowed down in the palmar carpal segment of the MN on the affected side, and compound muscle action potential (CMAP) wave amplitude was normal. Latency of wrist of the affected side was prolonged. The MCV of all segments of the ulnar nerve was normal, and CMAP wave amplitude was normal. MN sensory nerve action potential (SNAP) was not elicited, ulnar nerve SCV was normal, and SNAP amplitude was normal. MN and ulnar nerve F wave latency and occurrence rate were normal.

### Data analysis results

As shown in Table 4 and Figures 4-7, there was a highly significant difference between the 2 groups regarding mean  $\pm$  SD of CSAC,  $\Delta$ CSA, and R-CSA ( $P < 0.001$ ). In comparison, the diagnostic value of CSAP was not obvious ( $P > 0.001$ ). To determine the accurate cutoff value and the most sensitive and specific threshold values, a ROC curve



**Figure 2** CTS group. The arrow indicates the cross-sectional area to be measured. (A) CSAC was 22.58 mm<sup>2</sup>; (B) CSAP was 10.39 mm<sup>2</sup>; ΔCSA and R-CSA were 12.19 and 2.17 mm<sup>2</sup>, respectively. ΔCSA, the difference of CSAC and CSAP; R-CSA, the ratio of CSAC and CSAP; CTS, carpal tunnel syndrome; CSAC, carpal tunnel cross-sectional area; CSAP, proximal cross-sectional area.

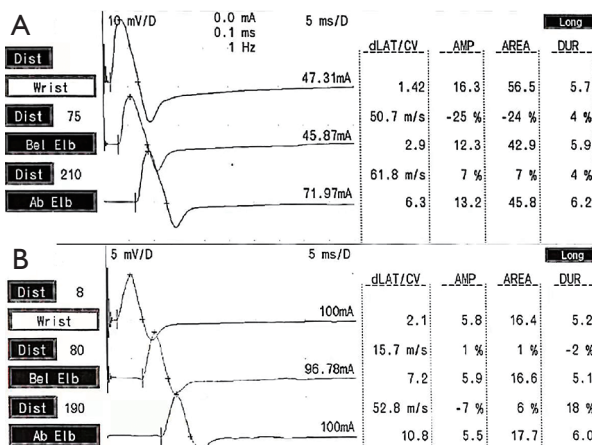
was produced and the area under the curve (AUC) was calculated. The AUC of CSAC was 0.9778, with a threshold value of 12.14 mm<sup>2</sup>; the AUC of R-CSA was 0.9949, with a threshold value of 1.235 mm<sup>2</sup>; and the AUC of ΔCSA was 1.000, with a threshold value of 2.035 mm<sup>2</sup> (Figure 8). The best diagnostic values were achieved by using a ΔCSA threshold of 2.04 mm<sup>2</sup>.

### Discussion

CTS is a MN compression neuropathy that affects the wrist. It is the most frequent entrapment neuropathy (31,32), with high prevalence in females (33). Different criteria have been proposed for the diagnosis of CTS, depending on the individual doctor's expertise and clinical experience. Apart from clinical evaluation, EDT is the most commonly used method for CTS diagnosis worldwide. Jablecki *et al.* (34) and Werner and Andary (4) summarized the advantages of the electrophysiological diagnostic method, including its high sensitivity and specificity. However, they also found that this method had a certain rate of missed diagnosis and could not provide information about MN peripheral conditions. Therefore, it is not sufficient to rely solely on EDT results for the diagnosis of CTS.

With improvements in US resolution, observations and measurements of the peripheral nerves have increased in accuracy, and there is now a broad consensus about the value of US in providing complementary information regarding nerve anatomy and neighboring structures within the carpal tunnel (18,35). Buchberger *et al.* (36) first made use of US to measure changes in the carpal tunnel MN of patients with CTS to assist in diagnosis (35). The most reliable ultrasonographic indicator of peripheral nerve entrapment neuropathy is enlargement of the nerve CSA. Previous studies have attempted to ascertain a universal cutoff value of the CSA for the diagnosis of CTS (26,37-41). The carpal tunnel inlet has been used as the MN CSA measurement point with a range of 8.5–15.0 mm<sup>2</sup>, and the sensitivity (62.0–97.9%) and specificity (63–100%) of CTS diagnosis were also significantly different. To date, there is no standard universal cutoff range for the CSA, as the MN CSA may be affected by demographic factors such as body height, body weight, age, sex, and ethnicity.

In this study, we used a comparison between 2 levels of the MN to avoid potential bias caused by the aforementioned individual variations. We investigated the use of MN CSA measurements by US in patients with CTS and in control subjects without CTS to determine the best

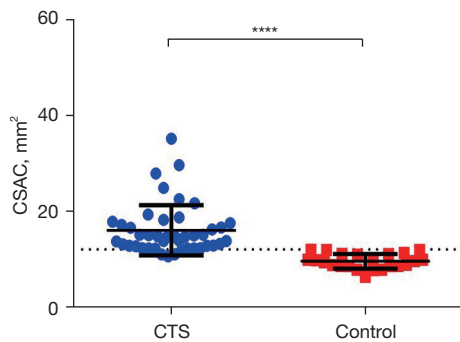


**Figure 3** Electrophysiological manifestation in the 2 groups. (A) Control group; (B) CTS group. Ab Elb, above elbow; AMP, amplitude; Bel Elb, below elbow; CTS, carpal tunnel syndrome; CV, conduction velocity; dist, distance; dLAT, latent period; DUR, duration.

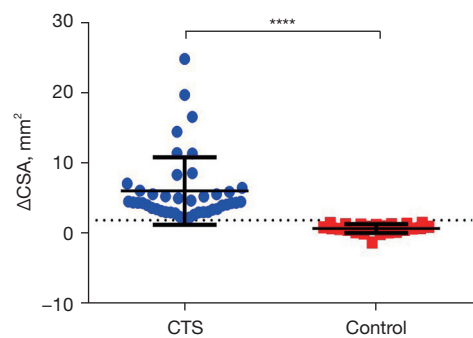
**Table 4** Comparison of CSAC, CSAP,  $\Delta$ CSA, and R-CSA in the 2 groups

Variables	Mean $\pm$ SD		T value	P value
	CTS group	Control group		
CSAC (mm <sup>2</sup> )	16.0900 $\pm$ 0.7948	9.6600 $\pm$ 0.3182	5.768	<0.0001***
CSAP (mm <sup>2</sup> )	9.9190 $\pm$ 0.2415	8.7710 $\pm$ 0.3484	2.753	0.0077**
$\Delta$ CSA	6.1710 $\pm$ 0.7263	0.8883 $\pm$ 0.1342	5.275	<0.0001***
R-CSA	1.6270 $\pm$ 0.0731	1.1110 $\pm$ 0.0173	5.110	<0.0001***

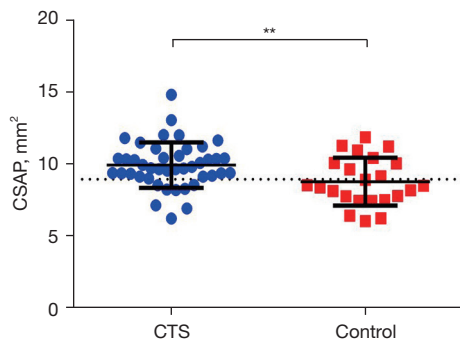
\*\**P* < 0.01; \*\*\**P* < 0.001, using an analysis of variance (ANOVA). SD, standard deviation; CSAC, carpal tunnel cross-sectional area; CSAP, proximal cross-sectional area;  $\Delta$ CSA, the difference of CSAC and CSAP; R-CSA, the ratio of CSAC and CSAP.



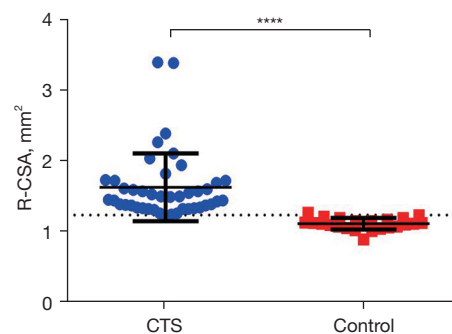
**Figure 4** Analysis of CSAC data in the 2 groups. The dotted line denotes the optimal cutoff value. GraphPad was used to calculate P values. \*\*\*\*, *P* < 0.0001. CSAC, carpal tunnel cross-sectional area; CTS, carpal tunnel syndrome.



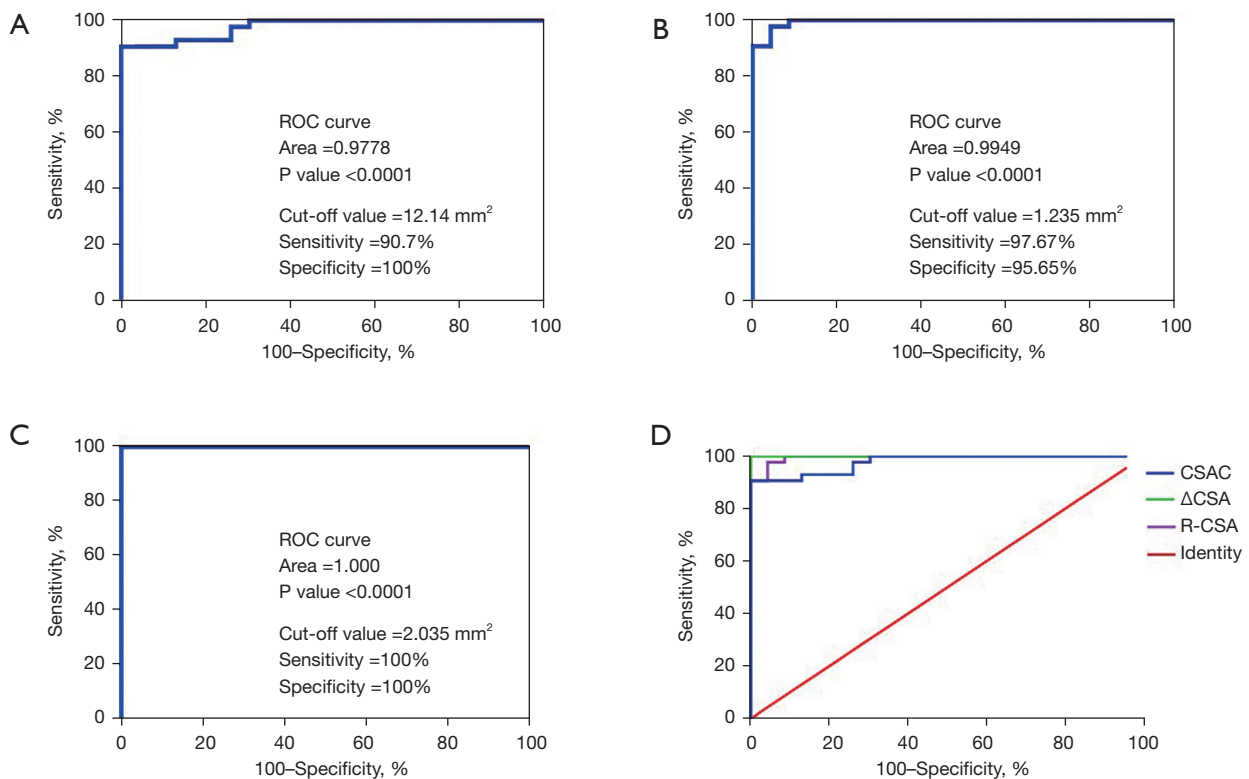
**Figure 6** Analysis of  $\Delta$ CSA data in the 2 groups. The dotted line denotes the optimal cutoff value. GraphPad was used to calculate P values. \*\*\*\*, *P* < 0.0001.  $\Delta$ CSA, the difference of CSAC and CSAP; CTS, carpal tunnel syndrome; CSAC, carpal tunnel cross-sectional area; CSAP, proximal cross-sectional area.



**Figure 5** Analysis of CSAP data in the 2 groups. The dotted line denotes the optimal cutoff value. GraphPad was used to calculate P values. \*\*, *P* < 0.001. CTS, carpal tunnel syndrome; CSAP, proximal cross-sectional area.



**Figure 7** Analysis of R-CSA data in the 2 groups. The dotted line denotes the optimal cutoff value. GraphPad was used to calculate P values. \*\*\*\*, *P* < 0.0001. R-CSA, the ratio of CSAC and CSAP; CTS, carpal tunnel syndrome; CSAC, carpal tunnel cross-sectional area; CSAP, proximal cross-sectional area.



**Figure 8** Analysis and comparison of ROC curve data of three values. (A) ROC analysis of all patients showed that the AUC of CSAC was 0.9778, and the optimal cutoff point was  $12.14 \text{ mm}^2$  (sensitivity 90.7%, specificity 100%). (B) The AUC of R-CSA was 0.9949, and the optimal cutoff point was  $1.235 \text{ mm}^2$  (sensitivity 97.67%, specificity 95.65%). (C) The AUC of  $\Delta\text{CSA}$  was 1.000, and the optimal cutoff point was  $2.035 \text{ mm}^2$  (sensitivity 100%, specificity 100%). D-value:  $\Delta\text{CSA}$ . (D) A combination of the above 3 pictures for comparison, showing that the AUC of  $\Delta\text{CSA}$  is obviously greater. ROC, receiver operating characteristic; CSAC, carpal tunnel cross-sectional area; CSAP, proximal cross-sectional area; R-CSA, the ratio of CSAC and CSAP;  $\Delta\text{CSA}$ , the difference of CSAC and CSAP.

method of diagnosing CTS with US. We evaluated the CSAC and CSAP at the level of the pronator quadratus muscle. Furthermore, we calculated the difference ( $\Delta\text{CSA}$ ) and the ratio (R-CSA) between CSAC and CSAP to omit individual variability rather than depending on the CSA at the level of the carpal tunnel only. We found a statistically significant difference in the US values of CSAC, CSAP,  $\Delta\text{CSA}$ , and R-CSA between CTS patients and healthy controls, and the best diagnostic values were achieved by using a  $\Delta\text{CSA}$  threshold of  $2.04 \text{ mm}^2$ . These findings are in agreement with Klauser *et al.* (29). Our results suggest that  $\Delta\text{CSA}$  measurements can compensate for interindividual variability in the MN CSA and yield a more accurate diagnosis of CTS.

Increased MN CSA is an important diagnostic indicator of compressive neuropathy. Long-term nerve compression causes changes in nerve microcirculation,

making nerves prone to ischemia and leading to abnormal vascular endothelial permeability, which ultimately manifests as intra-nerve edema and an increased CSA measurement. As compression increases, symptoms worsen, and this may manifest as a CSA increase on US. This suggests a certain relationship between the severity of CTS and the measurement of the CSA, which has been confirmed (42). With respect to CTS US classification criteria, an increasing number of studies have provided data on the relationship between the MN CSA and the grading of CTS severity. However, these standards are not uniform, for the following reasons. First, the studies use different standards for classification. Second, different US technologies, methods of measurement, and machine resolutions create bias in the results. Third, CSAC is closely linked to individual factors such as age, gender, body weight, and ethnicity.



Padua *et al.* (43) and Karadağ *et al.* (44) have shown that electrophysiological diagnosis and US are consistent when classifying CTS severity. Phongamwong *et al.* (45) conducted a characteristic analysis of 106 patients with moderate and severe CTS; their results showed that a CSA cutoff value measured at the carpal tunnel inlet of 14 mm<sup>2</sup> had a specificity of 91.4% and a sensitivity of 42.3% in diagnosing moderate to severe CTS. In 2019, Roomizadeh *et al.* (46) conducted a meta-analysis of 16 studies with a sample size of 2,292 wrists. Lesion severity was graded in accordance with the electrophysiological results, and the carpal tunnel inlet was selected as the measurement location to obtain the CSA thresholds of different levels. The pooled results showed a MN CSA of 11.64 mm<sup>2</sup> for mild CTS, 13.74 mm<sup>2</sup> (adjusted: 13.43 mm<sup>2</sup>) for moderate CTS, and 16.80 mm<sup>2</sup> (adjusted: 16.36 mm<sup>2</sup>) for severe CTS.

With respect to the  $\Delta$ CSA index used for classification, Klauser *et al.* (47) conducted a US examination of 427 patients (643 wrists), and the results showed that the optimal critical values of  $\Delta$ CSA for mild to moderate CTS and moderate to severe CTS were 6 and 9 mm<sup>2</sup>, respectively. In a 2021 cross-sectional study, Ji (48) showed that the best cutoff values of CSA for mild to moderate CTS and moderate to severe CTS were 6.32 and 8.82 mm<sup>2</sup>, respectively.

Despite the high value of US in the classification of CTS, Martikkala (49) and Mohammadi (24) have suggested that MN transsectional US has value in the diagnosis or exclusion of CTS but cannot be used to grade the severity. However, these studies only focused on CSAC and did not further compare  $\Delta$ CSA with electrophysiology. Therefore, the authors of the present study maintain a neutral attitude towards this point of view, as more data are needed to compare the value of  $\Delta$ CSA and electrophysiological diagnostic classification of CTS.

In conclusion, there is a correlation between ultrasonography and EDT in providing an objective basis for the clinical diagnosis and classification of CTS. These 2 diagnostic methods can complement each other and reduce missed diagnoses. Kamolz *et al.* (50) has suggested that patients suspected of CTS should be first diagnosed by experienced clinicians, and then the MN and its surrounding structures should be assessed by US to rule out anatomic variation or other etiology. Finally, patients who are negative on US but have some or all symptoms and do not respond to treatment may be referred for EDT. For patients with atypical symptoms or more extensive neuropathy, EDT should be the first choice, with US used as a supplementary test.

## Conclusions

US examination is a noninvasive and simple method for CTS diagnosis. This method has good clinical application value, as it can be used to identify morphological abnormalities of the MN and its surrounding tissues and can thus inform the preparation of a surgical plan. MN activity combined with CSA measurements are valuable in US diagnosis of CTS, while CSAC,  $\Delta$ CSA, and R-CSA measurements can help determine the severity of CTS. The ROC curve analysis showed that among these 3 measurements,  $\Delta$ CSA was the most useful for the diagnosis, evaluation, and treatment of patients with CTS. As a correction index that excluded individual influencing factors,  $\Delta$ CSA was more accurate and had a higher diagnostic value. Our results suggest that US examination, which is safe and noninvasive, can be used to guide clinical diagnosis and treatment of CTS.

## Acknowledgments

*Funding:* This research received funding from the National Natural Science Foundation of China Youth Fund (81801893), the Nantong Clinical Medicine Research Center (HS2019005, HS2020001), Natural Science Research Project of Nantong Science and Technology Bureau (MS12021021, MS12020006, MS12020017, MS12021035), Jiangsu Planned Projects for Postdoctoral Research Fund (2021K031A), Deputy General Manager Project of Science and Technology of Jiangsu Province (FZ20210652), Jiangsu geriatric clinical technology application research project (LR2021047).

## Footnote

*Reporting Checklist:* The authors have completed the STARD reporting checklist. Available at <https://atm.amegroups.com/article/view/10.21037/atm-22-1128/rc>

*Data Sharing Statement:* Available at <https://atm.amegroups.com/article/view/10.21037/atm-22-1128/dss>

*Conflicts of Interest:* All authors have completed the ICMJE uniform disclosure form (available at <https://atm.amegroups.com/article/view/10.21037/atm-22-1128/coif>). The authors have no conflicts of interest to declare.

*Ethical Statement:* The authors are accountable for all aspects of the work in ensuring that questions related to the accuracy or

integrity of any part of the work are appropriately investigated and resolved. The project was approved by the Ethics Committee of Affiliated Hospital of Nantong University (No. 2019-L002) and was conducted in accordance with the Declaration of Helsinki (as revised in 2013). All patients signed informed consent prior to participation.

*Open Access Statement:* This is an Open Access article distributed in accordance with the Creative Commons Attribution-NonCommercial-NoDerivs 4.0 International License (CC BY-NC-ND 4.0), which permits the non-commercial replication and distribution of the article with the strict proviso that no changes or edits are made and the original work is properly cited (including links to both the formal publication through the relevant DOI and the license). See: <https://creativecommons.org/licenses/by-nc-nd/4.0/>.

## References

- Graham B. The diagnosis and treatment of carpal tunnel syndrome. *BMJ* 2006;332:1463-4.
- Harris I, Mulford J, Solomon M, et al. Association between compensation status and outcome after surgery: a meta-analysis. *JAMA* 2005;293:1644-52.
- Werner RA. Evaluation of work-related carpal tunnel syndrome. *J Occup Rehabil* 2006;16:207-22.
- Werner RA, Andary M. Electrodiagnostic evaluation of carpal tunnel syndrome. *Muscle Nerve* 2011;44:597-607.
- Roquelaure Y, Ha C, Pelier-Cady MC, et al. Work increases the incidence of carpal tunnel syndrome in the general population. *Muscle Nerve* 2008;37:477-82.
- Padua L, Coraci D, Erra C, et al. Carpal tunnel syndrome: clinical features, diagnosis, and management. *Lancet Neurol* 2016;15:1273-84.
- Ng AWH, Griffith JF, Lee RKL, et al. Ultrasound carpal tunnel syndrome: additional criteria for diagnosis. *Clin Radiol* 2018;73:214.e11-8.
- Mondelli M, Giannini F, Giacchi M. Carpal tunnel syndrome incidence in a general population. *Neurology* 2002;58:289-94.
- Palmer KT, Harris EC, Coggon D. Carpal tunnel syndrome and its relation to occupation: a systematic literature review. *Occup Med (Lond)* 2007;57:57-66.
- Pardal-Fernandez JM. Carpal tunnel syndrome. The contribution of ultrasonography. *Rev Neurol* 2014;59:459-69.
- Stevens JC, Smith BE, Weaver AL, et al. Symptoms of 100 patients with electromyographically verified carpal tunnel syndrome. *Muscle Nerve* 1999;22:1448-56.
- Roquelaure Y, Chazelle E, Gautier L, et al. Time trends in incidence and prevalence of carpal tunnel syndrome over eight years according to multiple data sources: Pays de la Loire study. *Scand J Work Environ Health* 2017;43:75-85.
- Kim WL, Kim JS, Lee JB, et al. Survey of Preferences in Patients Scheduled for Carpal Tunnel Release Using Conjoint Analysis. *Clin Orthop Surg* 2017;9:96-100.
- Jegal M, Woo SJ, Lee HI, et al. Anatomical Relationships between Muscles Overlying Distal Transverse Carpal Ligament and Thenar Motor Branch of the Median Nerve. *Clin Orthop Surg* 2018;10:89-93.
- Rempel D, Evanoff B, Amadio PC, et al. Consensus criteria for the classification of carpal tunnel syndrome in epidemiologic studies. *Am J Public Health* 1998;88:1447-51.
- Grundberg AB. Carpal tunnel decompression in spite of normal electromyography. *J Hand Surg Am* 1983;8:348-9.
- Deniz FE, Oksüz E, Sarikaya B, et al. Comparison of the diagnostic utility of electromyography, ultrasonography, computed tomography, and magnetic resonance imaging in idiopathic carpal tunnel syndrome determined by clinical findings. *Neurosurgery* 2012;70:610-6.
- Fowler JR, Gaughan JP, Ilyas AM. The sensitivity and specificity of ultrasound for the diagnosis of carpal tunnel syndrome: a meta-analysis. *Clin Orthop Relat Res* 2011;469:1089-94.
- Roll SC, Case-Smith J, Evans KD. Diagnostic accuracy of ultrasonography vs. electromyography in carpal tunnel syndrome: a systematic review of literature. *Ultrasound Med Biol* 2011;37:1539-53.
- Chen YT, Williams L, Zak MJ, et al. Review of Ultrasonography in the Diagnosis of Carpal Tunnel Syndrome and a Proposed Scanning Protocol. *J Ultrasound Med* 2016;35:2311-24.
- Fu T, Cao M, Liu F, et al. Carpal tunnel syndrome assessment with ultrasonography: value of inlet-to-outlet median nerve area ratio in patients versus healthy volunteers. *PLoS One* 2015;10:e0116777.
- Impink BG, Gagnon D, Collinger JL, et al. Repeatability of ultrasonographic median nerve measures. *Muscle Nerve* 2010;41:767-73.
- Atan T, Günendi Z. Diagnostic utility of the sonographic median to ulnar nerve cross-sectional area ratio in carpal tunnel syndrome. *Turk J Med Sci* 2018;48:110-6.
- Mohammadi A, Afshar A, Etemadi A, et al. Diagnostic value of cross-sectional area of median nerve in grading severity of carpal tunnel syndrome. *Arch Iran Med* 2010;13:516-21.
- Ulaşlı AM, Duymuş M, Nacir B, et al. Reasons for using swelling ratio in sonographic diagnosis of carpal tunnel syndrome and a reliable method for its calculation. *Muscle Nerve* 2013;47:396-402.

26. Elnady B, Rageh EM, Ekhouly T, et al. Diagnostic potential of ultrasound in carpal tunnel syndrome with different etiologies: correlation of sonographic median nerve measures with electrodiagnostic severity. *BMC Musculoskelet Disord* 2019;20:634.
27. Basiri K, Katirji B. Practical approach to electrodiagnosis of the carpal tunnel syndrome: A review. *Adv Biomed Res* 2015;4:50.
28. Seror P. Sonography and electrodiagnosis in carpal tunnel syndrome diagnosis, an analysis of the literature. *Eur J Radiol* 2008;67:146-52.
29. Klauser AS, Halpern EJ, De Zordo T, et al. Carpal tunnel syndrome assessment with US: value of additional cross-sectional area measurements of the median nerve in patients versus healthy volunteers. *Radiology* 2009;250:171-7.
30. Pourmemari MH, Shiri R. Diabetes as a risk factor for carpal tunnel syndrome: a systematic review and meta-analysis. *Diabet Med* 2016;33:10-6.
31. Gelberman RH, Eaton RG, Urbaniak JR. Peripheral nerve compression. *Instr Course Lect* 1994;43:31-53.
32. Möller I, Miguel M, Bong DA, et al. The peripheral nerves: update on ultrasound and magnetic resonance imaging. *Clin Exp Rheumatol* 2018;36 Suppl 114:145-58.
33. Ibrahim I, Khan WS, Goddard N, et al. Carpal tunnel syndrome: a review of the recent literature. *Open Orthop J* 2012;6:69-76.
34. Jablecki CK, Andary MT, So YT, et al. Literature review of the usefulness of nerve conduction studies and electromyography for the evaluation of patients with carpal tunnel syndrome. *AAEM Quality Assurance Committee. Muscle Nerve* 1993;16:1392-414.
35. Descatha A, Huard L, Aubert F, et al. Meta-analysis on the performance of sonography for the diagnosis of carpal tunnel syndrome. *Semin Arthritis Rheum* 2012;41:914-22.
36. Buchberger W, Schön G, Strasser K, et al. High-resolution ultrasonography of the carpal tunnel. *J Ultrasound Med* 1991;10:531-7.
37. Lee D, van Holsbeeck MT, Janevski PK, et al. Diagnosis of carpal tunnel syndrome. *Ultrasound versus electromyography. Radiol Clin North Am* 1999;37:859-72, x.
38. Koyuncuoglu HR, Kutluhan S, Yesildag A, et al. The value of ultrasonographic measurement in carpal tunnel syndrome in patients with negative electrodiagnostic tests. *Eur J Radiol* 2005;56:365-9.
39. Wong SM, Griffith JF, Hui AC, et al. Carpal tunnel syndrome: diagnostic usefulness of sonography. *Radiology* 2004;232:93-9.
40. Ziswiler HR, Reichenbach S, Vögelin E, et al. Diagnostic value of sonography in patients with suspected carpal tunnel syndrome: a prospective study. *Arthritis Rheum* 2005;52:304-11.
41. Yesildag A, Kutluhan S, Sengul N, et al. The role of ultrasonographic measurements of the median nerve in the diagnosis of carpal tunnel syndrome. *Clin Radiol* 2004;59:910-5.
42. Beekman R, Visser LH. Sonography in the diagnosis of carpal tunnel syndrome: a critical review of the literature. *Muscle Nerve* 2003;27:26-33.
43. Padua L, Pazzaglia C, Caliandro P, et al. Carpal tunnel syndrome: ultrasound, neurophysiology, clinical and patient-oriented assessment. *Clin Neurophysiol* 2008;119:2064-9.
44. Karadağ YS, Karadağ O, Çiçekli E, et al. Severity of Carpal tunnel syndrome assessed with high frequency ultrasonography. *Rheumatol Int* 2010;30:761-5.
45. Phongamwong C, Soponprapakorn N, Kumnerdee W. Determination of Electrophysiologically Moderate and Severe Carpal Tunnel Syndrome: Ultrasonographic Measurement of Median Nerve at the Wrist. *Ann Rehabil Med* 2017;41:604-9.
46. Roomizadeh P, Eftekharsadat B, Abedini A, et al. Ultrasonographic Assessment of Carpal Tunnel Syndrome Severity: A Systematic Review and Meta-Analysis. *Am J Phys Med Rehabil* 2019;98:373-81.
47. Klauser AS, Abd Ellah MM, Halpern EJ, et al. Sonographic cross-sectional area measurement in carpal tunnel syndrome patients: can delta and ratio calculations predict severity compared to nerve conduction studies? *Eur Radiol* 2015;25:2419-27.
48. Ji L. Correlation analysis of ultrasound parameters of median nerve cross-sectional area and flat rate with severity of carpal tunnel syndrome. *Journal of Xinjiang Medical University* 2021;44:922-6.
49. Martikkala L, Himanen SL, Virtanen K, et al. The Neurophysiological Severity of Carpal Tunnel Syndrome Cannot Be Predicted by Median Nerve Cross-Sectional Area and Wrist-to-Forearm Ratio. *J Clin Neurophysiol* 2021;38:312-6.
50. Kamolz LP, Schrögenderfer KF, Rab M, et al. The precision of ultrasound imaging and its relevance for carpal tunnel syndrome. *Surg Radiol Anat* 2001;23:117-21.

(English Language Editor: C. Gourlay)

**Cite this article as:** Xu C, Zhou Y, He Z, Liu W, Zou M, Sun Y, Qiu J, Ren Y, Mao G, Wang Y, Xi Q, Chen Y, Zhang B. Difference and ratio of the cross-sectional area of median nerve at the carpal tunnel and the pronator quadratus muscle in diagnosing carpal tunnel syndrome: a cross-sectional study. *Ann Transl Med* 2022;10(6):340. doi: 10.21037/atm-22-1128