

Intraoperative Parathyroid Hormone Monitoring in Guiding Adequate Parathyroidectomy

Aabid Hassan Naik, Munir Ahmad Wani¹, Khursheed Alam Wani, Bashir Ahmad Laway², Ajaz Ahmad Malik¹, Zafar Amin Shah³

General and Minimal Access Surgery, Skims, Soura, Departments of ¹General and Minimal Access Surgery, ²Endocrinology and ³Immunology, SKIMS, Srinagar, Jammu and Kashmir, India

Abstract

Background: Parathyroidectomy has been traditionally performed through bilateral neck exploration (BNE). However, with the use of intraoperative parathyroid hormone (IOPTH) assay along with preoperative localization studies, focused parathyroidectomy can be performed with good surgical success rate, multiglandular disease can be predicted, and hence recurrence and surgical failure can be prevented. Furthermore, it predicts eucalcemia in the postoperative period. The aim of this study was to evaluate the usefulness of IOPTH assay in guiding adequate parathyroidectomy in patients of primary hyperparathyroidism. **Materials and Methods:** Between year 2015 and 2017, 45 patients of primary hyperparathyroidism underwent parathyroidectomy with IOPTH assay employed as an intraoperative tool to guide the surgical procedure. Blood samples were collected: (1) at preincision time, (2) preexcision of gland, (3) 5-min postexcision of gland, and (4) 10-min postexcision of gland. On the basis of the Irvin criterion, an intraoperative PTH drop >50% from the highest either preincision or preexcision level after parathyroid excision was considered a surgical success. Otherwise, BNE was performed and search for other parathyroid glands done. **Results:** Ten-min postexcision PTH levels dropped >50% in 34 (75.6%) patients. True positive among them were 31 (68.8%), true negative 8 (17.7%), false positive 3 (6.6%), and false negative 3 (6.6%). We performed focused exploration at the outset in 40 (88.9%) patients and bilateral exploration for five patients as guided by preoperative localizing studies. Hence, IOPTH was helpful in guiding further exploration in 8 (17.7%) patients and prevented further exploration in 32 (71.1%) patients and also was able to predict eucalcemia in 97.7% patients at 6 months. Thus, IOPTH was able to obviate or to ask for additional procedure in 88.8% of patients. However, in three (6.6%) patients, IOPTH would guide unnecessary exploration and in equally, that is, three (6.6%) patients may require reoperation for unidentified parathyroids. **Conclusion:** IOPTH in adjunct with other localizing studies is very helpful for carrying out successful parathyroidectomy in uniglandular disease and predicting postoperative eucalcemia. However, more importantly, its role is valuable in equivocal imaging, in such cases, it prevents unnecessary exploration or helps in adequate parathyroidectomy.

Keywords: Intraoperative parathyroid hormone, parathyroid hormone, parathyroidectomy, primary hyperparathyroidism

INTRODUCTION

Intraoperative parathyroid hormone (IOPTH) monitoring has changed the surgical approach to primary hyperparathyroidism (PHPT). The traditional approach for the treatment of PHPT is a bilateral neck exploration (BNE), which entails the identification of all parathyroid glands and resection of abnormal glands. However, with the advent of improved surgical adjuncts, including preoperative ultrasonography (USG) and sestamibi scintigraphy and IOPTH monitoring, the pendulum has swung from bilateral exploration to minimally invasive parathyroidectomy (MIP). Recently, it has been shown that limited exploration has its advantages, including

shorter hospital stay, less postoperative pain, and fewer complications.^[1] Some problems currently affect patients with negative 2-methoxyisobutylisonitrile (MIBI) or in which imaging studies are discordant. In these cases, BNE is generally recommended, although limited exploration with the aid of IOPTH monitoring has been suggested to be an alternative approach.^[2,3]

Address for correspondence: Dr. Aabid Hassan Naik, IRM Lane Sector A, House No. 21 Budshshnagar, Natipora, Srinagar - 190 015, Jammu and Kashmir, India.
E-mail: aabidnaik53@gmail.com

This is an open access journal, and articles are distributed under the terms of the Creative Commons Attribution-NonCommercial-ShareAlike 4.0 License, which allows others to remix, tweak, and build upon the work non-commercially, as long as appropriate credit is given and the new creations are licensed under the identical terms.

For reprints contact: reprints@medknow.com

How to cite this article: Naik AH, Wani MA, Wani KA, Laway BA, Malik AA, Shah ZA. Intraoperative parathyroid hormone monitoring in guiding adequate parathyroidectomy. Indian J Endocr Metab 2018;22:410-6.

Access this article online

Quick Response Code:



Website:
www.ijem.in

DOI:
10.4103/ijem.IJEM_678_17

The most common and widely accepted adjuncts used with MIP are USG scanning, MIBI scanning, and IOPTH. The reported accuracy for identifying a single adenoma is 71%–80% for USG and 74%–88% for MIBI, and 64%–95% when both are combined.^[4] On the other hand, the accuracy of identifying multigland disease is lower with either single (69% for USG and 49% for MIBI) or combined (62%) imaging modalities.^[5] IOPTH is reported to have an overall accuracy of 80%.^[4] Similar to preoperative localizing studies, the best results of IOPTH occur in patients with single-gland disease (87%–99%),^[6] but IOPTH assay is less accurate in patients with multigland disease (58%).^[4]

Padma *et al.*^[6] conducted a study about the feasibility of rapid parathormone assay for enabling MIP excision. Seven patients with unifocal disease underwent MIP through 2–3 cm lateral incision. They found solitary adenoma in all seven patients and IOPTH levels fell in six out of seven patients. However, the sample size is small and the patients with multiglandular disease were not included in the study.

Trehan *et al.*^[7] performed a study about the utility of intraoperative parathyroid hormone levels in the management of PHPT from 2010 to 2014 and compared its sensitivity with preoperative radiological investigations. A total of 50 parathyroidectomies were performed. The findings of USG neck and sestamibi scan were concordant in 88% cases. In the rest 12% of patients, USG and sestamibi scans were discordant and IOPTH monitoring was helpful in performing MIP. IOPTH monitoring was done in 52% of cases, only one patient had to undergo BNE, following minimally invasive procedures.

Tampi *et al.*^[8] in 2014 conducted a study on seven patients undergoing surgery for PHPT with the evaluation of their IOPTH levels along with the routine frozen and paraffin sections. All seven patients showed more than a 50% intraoperative fall in serum PTH after excision of the abnormal gland. This was indicative of an adenoma and was confirmed by histopathological examination and normalization of serum calcium postoperatively. They concluded that IOPTH is a sensitive and specific guide to a complete removal of the abnormal parathyroid tissue and is superior to frozen section diagnosis in parathyroid surgery. Again, the sample size is very small with no differentiation of patients into uniglandular and multiglandular disease.

Dobrinja *et al.*^[9] conducted a study in 2017 about the effectiveness of IOPTH monitoring in predicting a multiglandular or malignant parathyroid disease and the main goal of the study was to confirm the usefulness of IOPTH monitoring when using minimally invasive techniques for treatment of sporadic PHPT. A retrospective review of 125 patients of PHPT who underwent parathyroidectomy between 2001 and 2006 was done. They concluded that IOPTH determinations ensure operative success of surgical resection in almost all hyperfunctioning tissue and in particular is very important in avoiding BNE. The use of IOPTH monitoring offer increased sensitivity in detecting multiglandular

disease and can minimize the need and risk associated with recurrent operations. Moreover, IOPTH monitoring could be a reliable marker to predict a malignant disease during parathyroidectomy, showing higher baseline value and superior drop compared to benign disease.

Similar to preoperative localizing studies, the best results of IOPTH occur in patients with single-gland disease (87%–99%),^[4,10] but IOPTH is less accurate in patients with multigland disease. Others, content that IOPTH is accurate and allows for the successful operative treatment of patients with both single-gland and multigland disease and rely on parathyroid gland function rather than morphology or histology.^[11] We conducted a study using IOPTH in both groups of patients (uniglandular and multiglandular disease).

MATERIALS AND METHODS

We conducted a prospective study from year 2015 in the Department of General and Minimal Access surgery in collaboration with the Department of Immunology and Molecular medicine at Sher-i-Kashmir Institute of Medical Sciences, Jammu and Kashmir, 45 patients diagnosed as cases of PHPT and planned for surgical intervention (parathyroidectomy) were included in the study. Patients with features of hyperparathyroidism were thoroughly worked up with biochemical as well as imaging modalities. Asymptomatic patients with incidental detection of hypercalcemia and raised PTH levels were also subjected to these investigations. Baseline investigations such as complete blood count and liver function tests were obtained. Other biochemical investigations included serum calcium and PTH levels. Further investigations such as serum urea and creatinine and 24-h urinary calcium levels were obtained. Imaging studies for localization such as ^{99m}Tc-labeled sestamibi scanning and US neck were routinely performed in all of the study patients. ^{99m}Tc-labeled MIBI scan was performed by injecting 10–15 mCi of ^{99m}Tc-labelled MIBI and anterior cervical views were taken at 15 min and 90 min and if needed at 3 h using Gamma camera. USG neck was obtained using high-frequency probe (12–14 MHz) GE Healthcare LOGIQ P5 imaging systems. In cases of discordant or negative imaging studies, 4D computed tomography (CT) [Figure 1] was obtained using 64-slice Siemens imaging unit with the protocol of three imaging phases with the field of view from angle of the mandible to carina. First phase was NCCT followed by two contrast-enhanced phases performed after IV administration of 90 ml of Iopamidol at 4 ml/s followed by 25 ml of saline chase. Arterial phase images were acquired at 25 s followed by venous phase at 80 s from the start of injecting. The characteristic enhancement pattern of a parathyroid adenoma is avid contrast enhancement in the arterial phase with rapid washout of contrast material in the delayed phase and lower attenuation compared with thyroid gland in the nonenhanced phase. Miami criterion (>50% drop from highest baseline IOPTH level at 10 min after excision) was used as end-point of surgery. Informed consent was obtained from patients for surgery, the expected complications,

a total of four IO blood samples each equal to 3 ml was taken from patients. Focused exploration through a 2–3 cm incision as per preoperative imaging studies was performed. IO four blood samples each equal to 3 ml were obtained at (1) preincision, (2) preexcision of gland, (3) 5-min post excision, and (4) 10 min after excision from peripheral vein and transported immediately to the immunology laboratory for serum separation and PTH estimation by chemiluminescence method on Beckman Coulter DXI-800 analyzer, following their protocol.

The results obtained were compared and decision regarding completion of parathyroidectomy or further exploration taken in each case. Excised glands were sent for histopathological examination. Patients were followed in immediate postoperative period for signs of hypocalcemia and then up to 6 months for any hypercalcemia or recurrence of hyperparathyroidism. The recorded data were compiled and entered in a spreadsheet (Microsoft Excel) and then exported to data editor of SPSS Version 20.0 (SPSS Inc., Chicago, Illinois, USA). Continuous variables were summarized as mean \pm SD and categorical variables were expressed as frequencies and percentages.

RESULTS

A total of 45 patients of PHPT underwent parathyroidectomy. The majority of the patients were of the age group 30–44 years old (53.3%) followed by 45–59 years old (24.4%). The youngest of the patient we had a 9-year-old boy, while the oldest one was a 70-year-old male, majority of the patients were female (68.9%) with female: male ratio of 2.2:1, majority of the patients had nephrolithiasis or nephrocalcinosis which was evaluated and found to have PHPT (51.1%). Others presented with generalized body aches and easy fatiguability, while one of the cases presented with jaw tumor [Figure 2] and another one with hoarseness of voice, this patient when explored by parathyroidectomy, parathyroid adenoma was pressing over the RLN. Only two patients (4.4%) had palpable gland on examination. Most of the patients had normal kidney function tests. Most of the patients had 24-h urinary calcium in the range of 200–400 mg/24 h (46.7%) and 400–800 mg/24 h (48.9%). Parathormone levels of majority of the patients were in the range of 100–300 pg/ml (53.3%) and 300–600 pg/ml (31.1%), while only 3 patients (6.7%) had levels >900 pg/ml. Similarly, 20 (44.4%) of the patients had serum calcium 10.5–11.5 mg/dl, while 11 patients (24.4%) had very high serum calcium levels more than 13 mg/dl. Phosphorus in most of the patients 31 (68.9%) was between 1.5 and 2.5 mg/dl. We also encountered two patients (4.4%) who had raised serum amylase secondary to hypercalcemia-induced pancreatitis.

USG neck was negative in five of the patients (11.1%), while it detected 20 of each of left inferior and right inferior glands, that is 44.4% of each. MIBI scan though was negative in double the cases of USG, that is, 10 patients (22.2%) while left inferior parathyroid was shown in 18 (40%) of cases and right inferior in 16 (35.6%) of cases. We also performed 4D

CT in 13 (28.9%) patients which was negative in one of them and only USG was positive for that patient.

Cholelithiasis was present in 5 (11.1%) patients. Others had renal stones while one patient had associated thyroid nodule which turned out to be papillary Ca thyroid on HPE and patient was later taken for total thyroidectomy. In 40 (88.9%) patients, we performed focused exploration at the outset, while in 5 (11.1%) patients extended exploration was done before IOPTH as guided by preoperative localization studies.

IOPTH was monitored in all of the patients. The values of IOPTH are shown in Table 1 and depicted in Figure 3. There was a slight increase in the preexcision values of PTH from 33.3% to 35.6% in the range of 300–600 pg/ml. 5-min postexcision PTH levels dropped >50% in 18 (40%) patients; however, 10-min postexcision PTH levels dropped >50% in 34 (75.6%) patients. True positive among them with respect

Table 1: Intraoperative parathyroid hormone levels in study patients

IOPTH levels	Frequency (%)
Preincision PTH (pg/ml)	
100-300	24 (53.3)
300-600	15 (33.3)
600-900	3 (6.7)
>900	3 (6.7)
Preexcision PTH (pg/ml)	
100-300	23 (51.1)
300-600	16 (35.6)
600-900	3 (6.7)
>900	3 (6.7)
5 min postexcision	
<50% drop	27 (60.0)
\geq 50% drop	18 (40.0)
10 min postexcision	
<50% drop	11 (24.4)
\geq 50% drop	34 (75.6)

IOPTH: Intraoperative parathyroid hormone, PTH: Parathyroid hormone

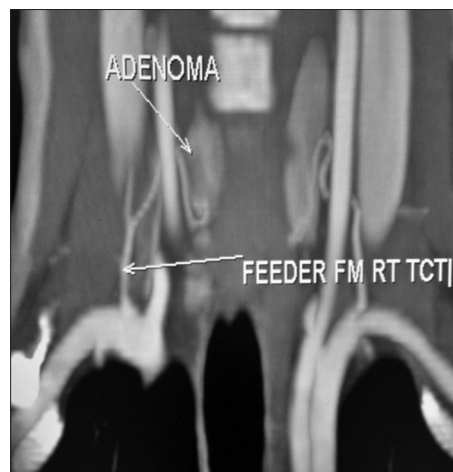


Figure 1: Arterial supply on the right side from thyrocervical trunk of parathyroid hormone adenoma on 4D computed tomography

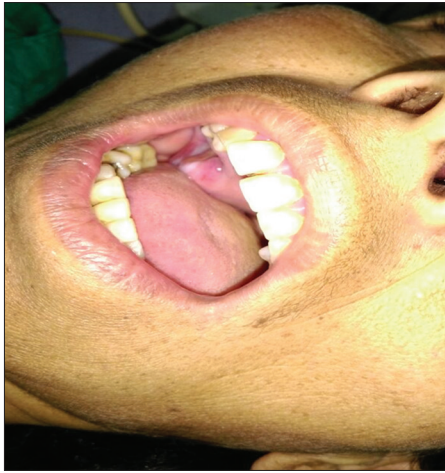


Figure 2: Patient with jaw tumor syndrome

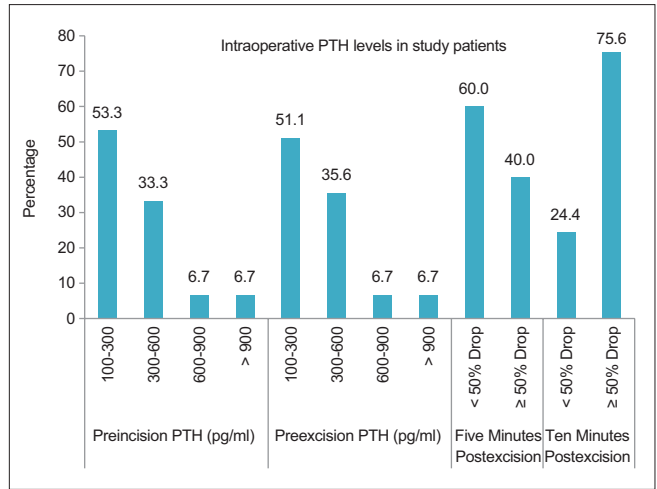


Figure 3: Intraoperative PTH levels in study patients

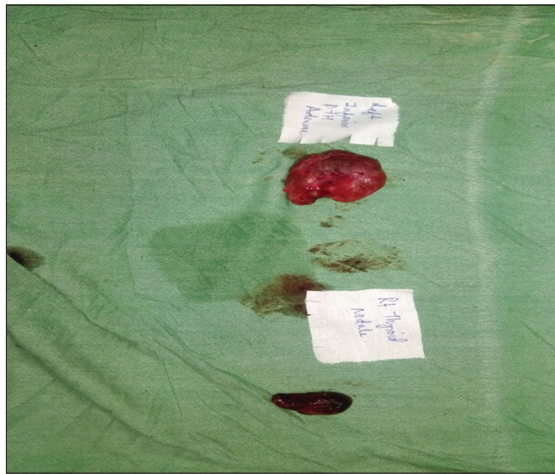

Figure 4: Double adenoma excised

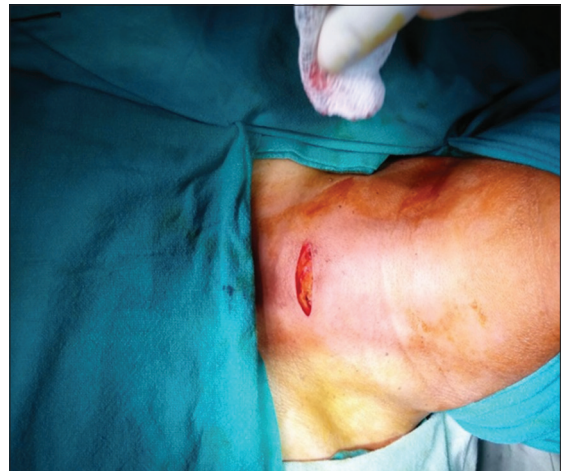

Figure 5: Small incision used for unilateral parathyroidectomy

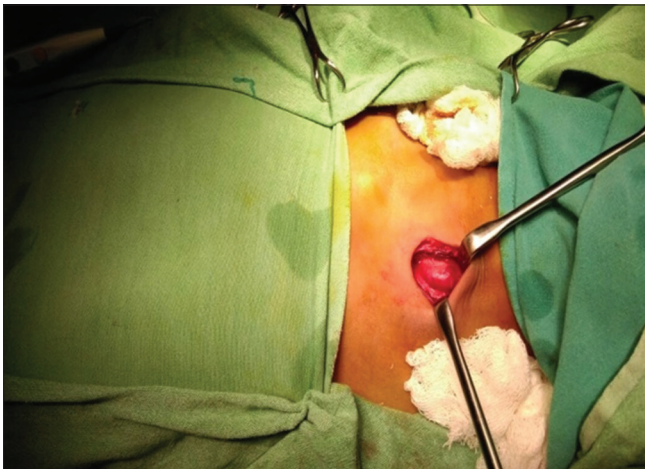

Figure 6: Unilateral exploration through a small incision

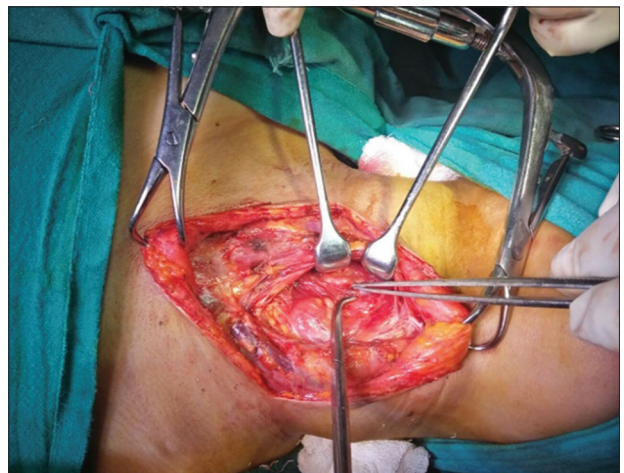

Figure 7: Exploration of all parathyroid glands

to IOF and histopathology were 31 (68.8%), true negative 8 (17.7%), false positive 3 (6.6%), and false negative 3 (6.6%)
 A total of 40 (88.9%) patients were found to have adenoma either single or double adenomas [Figure 4] while 5 (11.1%)

were found to have hyperplasia. No patient of parathyroid carcinoma was encountered. Thirteen (28.9%) of our patients had postoperative serum calcium levels <8 mg/dl, among which 4 (14.45%) patients were symptomatic for hypocalcemia

and required calcium supplements. These were the patients with either high PTH values or patients who were subjected to multigland excision. Only 10 (22.2%) of our patients had hypercalcemia at 48-h postoperatively, while it declined to 2 (4.4%) at 1 month and after 6 months one of our patient continued with hypercalcemia. Only 1 (2.2%) of our study patients had recurrence of hyperparathyroidism, who was later on follow-up found to have an ectopic parathyroid which was not picked up by localization studies and IOPTH also failed to predict for it as this was suppressed and started to secrete PTH after 1 month of surgery.

When compared with IOF and histopathology, sensitivity of the IOPTH assay was found to be 91.2%, specificity 72.7%, positive predictive value 91.2%, negative predictive value 72.7%, and accuracy as 86.7% as shown in Table 2.

DISCUSSION

Failure to surgically cure hyperparathyroidism is usually related to multiglandular disease, ectopic adenomas, misinterpretation of frozen section pathologic findings, and incorrect diagnosis of PHPT.^[12,13] Experienced surgeons have reported large series with excellent results using different surgical approaches to parathyroidectomy.^[14] During the past two decades, new surgical procedures have evolved for the treatment of PHPT. From a principle point of view, the main difference is still being bilateral and unilateral neck exploration. The latter could be performed using a variety of forms of general and local anesthesia. The main claim of the proponents of unilateral neck exploration is that compared with bilateral exploration, the unilateral approach carries a decreased risk for temporary and permanent hypocalcemia,^[15-18] without an increased risk for persistent or recurrent PHPT.^[19]

Improving imaging and appreciation that the majority of patients have single-gland disease has led to the development of unilateral and focused or minimally invasive procedures.

Correct identification and complete excision of the abnormal parathyroid glands with minimal complications are the main goals of surgery. The use of IOPTH monitoring in combination with preoperative imaging has been useful to surgeons in performing MIP. Previous studies report MIP to be linked with better cosmetic results from a smaller incision, quicker

operative time, uneventful recovery and a reduced risk of developing hypocalcemia, and recurrent laryngeal nerve injury.^[20]

It has been proved that the parathyroid glands are the only endocrine glands in the body to secrete parathormone and this 84-residue parathormone molecule has a half-life of <5 min and usually its secretion is suppressed by properly functioning parathyroids. Therefore, blood concentrations of intact PTH should decrease immediately within a short period of time subsequent to the removal of all hypersecreting parathyroid glands.^[21] In the setting of PHPT, numerous studies have shown that a rapid IOPTH assay was accurate in predicting surgical success and reported cure rates of 96%–98%.^[22,23] Meanwhile, studies also revealed the recurrence rate after limited parathyroidectomy to be 1.5%. This is comparable to the rates reported after conventional BNE.^[24] The parathyroid imaging studies reported 96% sensitivity and 88% accuracy.^[25,26] The limited accuracy of parathyroid imaging precludes the surgeon from completely depending on the preoperative localization studies. Hence, adjuncts such as intraoperative isotope scanning and IOPTH measurement have been utilized. In addition in secondary and tertiary hyperparathyroidism cases, the rapid PTH assay has been shown to be useful, and the success rate in preoperative cases for failed surgery or recurrent disease improved from 76% to 94%.^[27,28]

As our main criterion, we used a >50% drop in PTH measured at 5 and 10 min after resection. When a patient's PTH level has decreased and been maintained at a level 50% below the baseline value (determined at the commencement of surgery), the surgeon can be confident that production of PTH has ceased as a result of complete excision of all hypersecreting tissue.^[29] We routinely drew four samples for PTH assay: the preincision baseline sample, the preexcision (second) baseline sample, the sample drawn 5 min after excision, and the sample drawn 10 min after excision. The second baseline sample was drawn to determine the stability of the original baseline. The higher of the two baseline values was used as our working PTH baseline, from which we calculated the required >50% decrease in PTH level.^[29]

Previous data from India report that 12%–13% patients with PHPT have pancreatitis.^[30] We also encountered two patients (4.4%) who had raised serum amylase secondary to hypercalcemia-induced pancreatitis. Our study showed hypophosphatemia (<2.5 mg/dl) present in 68.9% of patients which is remarkably similar to study by Misgar *et al.*^[31] who reported hypophosphatemia in 69.3% of patients and also to Western data^[32] and another Indian study has reported hypophosphatemia in 65% of patients while another study has reported normal serum phosphorus levels^[33,34]

We performed focused exploration [Figures 5 and 6] at the outset in 40 (88.9%) patients and bilateral exploration [Figure 7] for five patients as guided by preoperative localizing studies. Hence, IOPTH was helpful in guiding further exploration in 8 (17.7%) patients and prevented further exploration in

Table 2: Diagnostic accuracy of intraoperative parathyroid hormone assay

Variable	Value (%)	95% CI
Sensitivity	91.2	76.3-98.1
Specificity	72.7	39.1-93.9
PPV	91.2	76.3-98.1
NPV	72.7	39.1-93.9
Accuracy	86.7	

NPV: Negative predictive value, PPV: Positive predictive value, CI: Confidence interval

32 (71.1%) patients and also was able to predict eucalcemia or hypocalcemia in 97.7% of patients at 6 months. Thus, IOPTH was able to obviate or to ask for the additional procedure in 88.8% of patients. However, in 3 (6.6%) patients, IOPTH would guide unnecessary exploration, and in equally, that is, 3 (6.6%) patients may require reoperation for unidentified parathyroids. Again our results are remarkably comparable with the study done by Neves *et al.*^[35] Many other studies show results which are consistent with our study.^[36-42]

A total of 12 (26.6%) of our study patients had equivocal imaging studies and IOPTH acted as a very useful adjunct in these patients. Eight out of 12 (66.6%) had to undergo further exploration. At the same time, 4/12 (33.3%) of such patients were treated by unilateral exploration thus preventing them from unnecessary BNE and its associated morbidity. Hence, IOPTH is very useful in patients with equivocal imaging and allows a surgeon to perform adequate parathyroidectomy by either extended exploration or unilateral exploration. Similar results have been found by Khan *et al.*^[40] While as preoperative localization studies have been found to have age-related variability and have less accuracy and sensitivity with increased age. Within all age groups, IOPTH has been found more accurate and sensitive than USG neck or MIBI scan.^[43]

Out of 45 patients, 33 (73.3%) patients had concordant preoperative imaging studies and IOPTH did not change the course of parathyroidectomy in 31/33 (93.9%) patients, however, it enabled the surgeon to be confident to terminate the procedure and restricted the surgeon to perform unilateral exploration with its known benefits to the patient. A study by Padma *et al.*^[6] on seven patients of PHPT concluded that through imaging studies and rapid PTH assay, it is feasible to successfully localize the uniglandular disease of hyperparathyroidism and parathyroidectomy can be performed through a more limited dissection. The whole procedure is cost-effective than traditional surgery and results in earlier discharge of patients, improved cosmetic appearance, and reduced postoperative pain. Similarly, a study by Tampi *et al.*^[8] in their study on seven patients of hyperparathyroidism concluded that IOPTH is a sensitive and specific guide to a complete removal of abnormal parathyroid tissue and as an intraoperative guide is superior to frozen section diagnosis in parathyroid surgery. However, 12 (26.6%) patients with equivocal imaging studies IOPTH changed the course of surgery in 8/12 (66.6%) patients who were found to have either double adenomas or hyperplasia. Hence, IOPTH is more useful in patients of multiglandular disease and patients with discordant imaging studies. Remarkably, similar results were found in a study conducted by Alexandra Thielmann and Paul Kerr.^[44]

Thus, we conclude that IOPTH in adjunct with other localizing studies proves very helpful in successfully localizing the uniglandular disease of hyperparathyroidism and parathyroidectomy can be performed through a more limited dissection and allows the surgeon to confidently terminate

the procedure once feasible levels of IOPTH are achieved. Its role is particularly most useful as an adjunct to preoperative imaging when imaging results are equivocal allowing for more focused/unilateral operations to be performed.

CONCLUSION

Furthermore, it predicts eucalcemia in postoperative period in patients with either concordant imaging studies or equivocal imaging studies and is able to reduce remarkably the recurrence of hyperparathyroidism. It is very much helpful in reducing the rate of BNE and the complications and morbidity associated with such exploration.

Financial support and sponsorship

Nil.

Conflicts of interest

There are no conflicts of interest.

REFERENCES

1. Thier M, Nordenström E, Bergenfelz A, Westerdahl J. Surgery for patients with primary hyperparathyroidism and negative sestamibi scintigraphy – A feasibility study. *Langenbecks Arch Surg* 2009;394:881-4.
2. Bergenfelz AO, Wallin G, Jansson S, Eriksson H, Mårtensson H, Christiansen P, *et al.* Results of surgery for sporadic primary hyperparathyroidism in patients with preoperatively negative sestamibi scintigraphy and ultrasound. *Langenbecks Arch Surg* 2011;396:83-90.
3. Lal A, Chen H. The negative sestamibi scan: Is a minimally invasive parathyroidectomy still possible? *Ann Surg Oncol* 2007;14:2363-6.
4. Miura D, Wada N, Arici C, Morita E, Duh QY, Clark OH, *et al.* Does intraoperative quick parathyroid hormone assay improve the results of parathyroidectomy? *World J Surg* 2002;26:926-30.
5. Siperstein A, Berber E, Barbosa GF, Tsinberg M, Greene AB, Mitchell J, *et al.* Predicting the success of limited exploration for primary hyperparathyroidism using ultrasound, sestamibi, and intraoperative parathyroid hormone: Analysis of 1158 cases. *Ann Surg* 2008;248:420-8.
6. Padma KS, Lakshman K, Srikanta SS. Feasibility of rapid parathormone assay for enabling minimally invasive parathyroid excision. *Indian J Surg* 2013;75:210-5.
7. Trehan M, Trehan M, Garg N, Mahajan A, Singh P, Singh J, *et al.* Minimally invasive parathyroidectomy with or without intraoperative parathyroid hormone monitoring. *Int J Anat Radiol Surg* 2015;4:23-6.
8. Tampi C, Chavan N, Parikh D. Intraoperative parathyroid hormone assay-cutting the Gordian Knot. *Indian J Endocrinol Metab* 2014;18:210-2.
9. Dobrinja C, Santandrea G, Giacca M, Stenner E, Ruscio M, de Manzini N, *et al.* Effectiveness of intraoperative parathyroid monitoring (ioPTH) in predicting a multiglandular or malignant parathyroid disease. *Int J Surg* 2017;41 Suppl 1:S26-S33.
10. Gawande AA, Monchik JM, Abbruzzese TA, Iannuccilli JD, Ibrahim SI, Moore FD Jr, *et al.* Reassessment of parathyroid hormone monitoring during parathyroidectomy for primary hyperparathyroidism after 2 preoperative localization studies. *Arch Surg* 2006;141:381-4.
11. Carneiro DM, Solorzano CC, Nader MC, Ramirez M, Irvin GL 3rd. Comparison of intraoperative iPTH assay (QPTH) criteria in guiding parathyroidectomy: Which criterion is the most accurate? *Surgery* 2003;134:973-9.
12. Levin KE, Clark OH. The reasons for failure in parathyroid operations. *Arch Surg* 1989;124:911-4.
13. Järhult J, Nordenström J, Perbeck L. Reoperation for suspected primary hyperparathyroidism. *Br J Surg* 1993;80:453-6.
14. Boggs JE, Irvin GL 3rd, Carneiro DM, Molinari AS. The evolution of

- parathyroidectomy failures. *Surgery* 1999;126:998-1002.
15. Tibblin S, Bondeson AG, Ljungberg O. Unilateral parathyroidectomy in hyperparathyroidism due to single adenoma. *Ann Surg* 1982;195:245-52.
 16. Worsey MJ, Carty SE, Watson CG. Success of unilateral neck exploration for sporadic primary hyperparathyroidism. *Surgery* 1993;114:1024-9.
 17. Tibblin S, Bondeson AG, Bondeson L, Ljungberg O. Surgical strategy in hyperparathyroidism due to solitary adenoma. *Ann Surg* 1984;200:776-84.
 18. Tibblin S, Bizard JP, Bondeson AG, Bonjer J, Bruining HA, Meier F, *et al.* Primary hyperparathyroidism due to solitary adenoma. A comparative multicentre study of early and long-term results of different surgical regimens. *Eur J Surg* 1991;157:511-5.
 19. Petti GH Jr., Chonkich GD, Morgan JW. Unilateral parathyroidectomy: The value of the localizing scan. *J Otolaryngol* 1993;22:307-10.
 20. Brasier AR, Wang CA, Nussbaum SR. Recovery of parathyroid hormone secretion after parathyroid adenectomy. *J Clin Endocrinol Metab* 1988;66:495-500.
 21. Irvin GL 3rd, Deriso GT 3rd. A new, practical intraoperative parathyroid hormone assay. *Am J Surg* 1994;168:466-8.
 22. Boggs JE, Irvin GL 3rd, Molinari AS, Deriso GT. Intraoperative parathyroid hormone monitoring as an adjunct to parathyroidectomy. *Surgery* 1996;120:954-8.
 23. Garner SC, Leight GS Jr. Initial experience with intraoperative PTH determinations in the surgical management of 130 consecutive cases of primary hyperparathyroidism. *Surgery* 1999;126:1132-7.
 24. Carneiro DM, Solorzano CC, Irvin GL 3rd. Recurrent disease after limited parathyroidectomy for sporadic primary hyperparathyroidism. *J Am Coll Surg* 2004;199:849-53.
 25. Arici C, Cheah WK, Ituarte PH, Morita E, Lynch TC, Siperstein AE, *et al.* Can localization studies be used to direct focused parathyroid operations? *Surgery* 2001;129:720-9.
 26. Burkey SH, Synder WH 3rd, Nwaraiku F, Watumull L, Mathews D. Direct parathyroidectomy: Feasibility and performance in 100 consecutive patients with primary hyperparathyroidism. *Arch Surg* 2003;138:604-9.
 27. Sokoll LJ, Drew H, Udelsman R. Intraoperative parathyroid hormone analysis: A study of 200 consecutive cases. *Clin Chem* 2000;46:1662-8.
 28. Irvin GL 3rd, Molinari AS, Figueroa C, Carneiro DM. Improved success rate in reoperative parathyroidectomy with intraoperative PTH assay. *Ann Surg* 1999;229:874-8.
 29. Sokoll LJ, Wians FH Jr., Remaley AT. Rapid intraoperative immunoassay of parathyroid hormone and other hormones: A new paradigm for point-of-care testing. *Clin Chem* 2004;50:1126-35.
 30. Jacob JJ, John M, Thomas N, Chacko A, Cherian R, Selvan B, *et al.* Does hyperparathyroidism cause pancreatitis? A South Indian experience and a review of published work. *ANZ J Surg* 2006;76:740-4.
 31. Misgar RA, Dar PM, Masoodi SR, Ahmad M, Wani KA, Wani AI, *et al.* Clinical and laboratory profile of primary hyperparathyroidism in Kashmir valley: A single-center experience. *Indian J Endocrinol Metab* 2016;20:696-701.
 32. Bilezikian JP, Silverberg SJ, Shane E, Parisien M, Dempster DW. Characterization and evaluation of asymptomatic primary hyperparathyroidism. *J Bone Miner Res* 1991;6 Suppl 2:S85-9.
 33. Bhansali A, Masoodi SR, Reddy KS, Behera A, das Radotra B, Mittal BR, *et al.* Primary hyperparathyroidism in North India: A description of 52 cases. *Ann Saudi Med* 2005;25:29-35.
 34. Udelsman R. Six hundred fifty-six consecutive explorations for primary hyperparathyroidism. *Ann Surg* 2002;235:665-70.
 35. Neves MC, Ohe MN, Rosano M, Abrahão M, Cervantes O, Lazaretti-Castro M, *et al.* A 10-year experience in intraoperative parathyroid hormone measurements for primary hyperparathyroidism: A prospective study of 91 previous unexplored patients. *J Osteoporos* 2012;2012:914214.
 36. Calò PG, Pisano G, Loi G, Medas F, Tatti A, Piras S, *et al.* Surgery for primary hyperparathyroidism in patients with preoperatively negative sestamibi scan and discordant imaging studies: The usefulness of intraoperative parathyroid hormone monitoring. *Clin Med Insights Endocrinol Diabetes* 2013;6:63-7.
 37. Romani AM, Panarese A, La Torre V, Pironi D, Sardella D, Mancini E, *et al.* The role of intraoperative parathyroid hormone assay in the surgical management of hyperparathyroidism. *Ann Ital Chir* 2007;78:91-6.
 38. Calò PG, Pisano G, Loi G, Medas F, Barca L, Atzeni M, *et al.* Intraoperative parathyroid hormone assay during focused parathyroidectomy: The importance of 20 minutes measurement. *BMC Surg* 2013;13:36.
 39. Çelik A, Divarçı E, Dökümcü Z, Ergün O, Özen S, Gökşen D, *et al.* Intraoperative parathyroid hormone monitoring corroborates the success of parathyroidectomy in children. *J Clin Res Pediatr Endocrinol* 2014;6:158-62.
 40. Khan AA, Khatun Y, Walker A, Jimeno J, Hubbard JG. Role of intraoperative PTH monitoring and surgical approach in primary hyperparathyroidism. *Ann Med Surg (Lond)* 2015;4:301-5.
 41. Barczyński M, Gołkowski F, Nawrot I. The current status of intraoperative iPTH assay in surgery for primary hyperparathyroidism. *Gland Surg* 2015;4:36-43.
 42. Pellitteri PK. The role of intraoperative measurement of parathyroid hormone in parathyroid surgery. *ORL J Otorhinolaryngol Relat Spec* 2008;70:319-30.
 43. Bishop B, Wang B, Parikh PP, Lew JJ. Intraoperative parathormone monitoring mitigates age-related variability in targeted parathyroidectomy for patients with primary hyperparathyroidism. *Ann Surg Oncol* 2015;22 Suppl 3:S655-61.
 44. Thielmann A, Kerr P. Validation of selective use of intraoperative PTH monitoring in parathyroidectomy. *J Otolaryngol Head Neck Surg* 2017;46:10.