

LETTER TO THE EDITOR

New onset pemphigus foliaceus following AstraZeneca COVID-19 vaccination

Dear Editor,

Pemphigus vulgaris (PV) and pemphigus foliaceus (PF) are a rare group of immunobullous disorders that can lead to high morbidity and mortality.¹ Analogous to the other autoimmune diseases, pemphigus is closely related to the immune response, which is impacted by several factors including: polymorphism of the genes, family history of other autoimmune disorders including pemphigus, gender, ethnicity, geographical area and environmental factors.^{2,3} Several triggers including different drugs and treatments, diseases, vaccines, nutrients, micronutrients, pregnancy and stress have all been implicated in the aetiology of the disease.⁴ Here, we present a case with PF whose disease developed after administration of the first dose of ChAdOx1 nCoV-19 (AstraZeneca) vaccination and was exacerbated following the second dose of this vaccine.

A 62-year-old woman in good health with no significant past medical history and no previous skin disease developed a generalized erythematous itchy rash 1 week after the first

dose of AstraZeneca COVID-19 vaccination. Administration of the second dose of the same vaccine 12 weeks later resulted in significant skin worsening within 2 days, with extensive scaling and erythema. The patient was not taking any regular or new medications and did not have any family history of autoimmune conditions or skin problems. Physical examination demonstrated large erosive annular erythematous plaques on her face, trunk and limbs (Figure 1a). No mucosal involvement was present.

Histology demonstrated subcorneal acantholysis and a blister filled with neutrophils (Figure 1b). Direct immunofluorescence (DIF) revealed intercellular IgG in the epidermis in a chicken wire-like pattern (Figure 1c). A tissue biopsy for histology and DIF in combination with clinical findings remains the best diagnostic tool for pemphigus. Histology reveals acantholysis with suprabasal blistering in PV and subcorneal blistering in PF. DIF reveals intercellular IgG and C3 epidermal depositions in a chicken wire-like pattern. Although PV has the same DIF pattern and

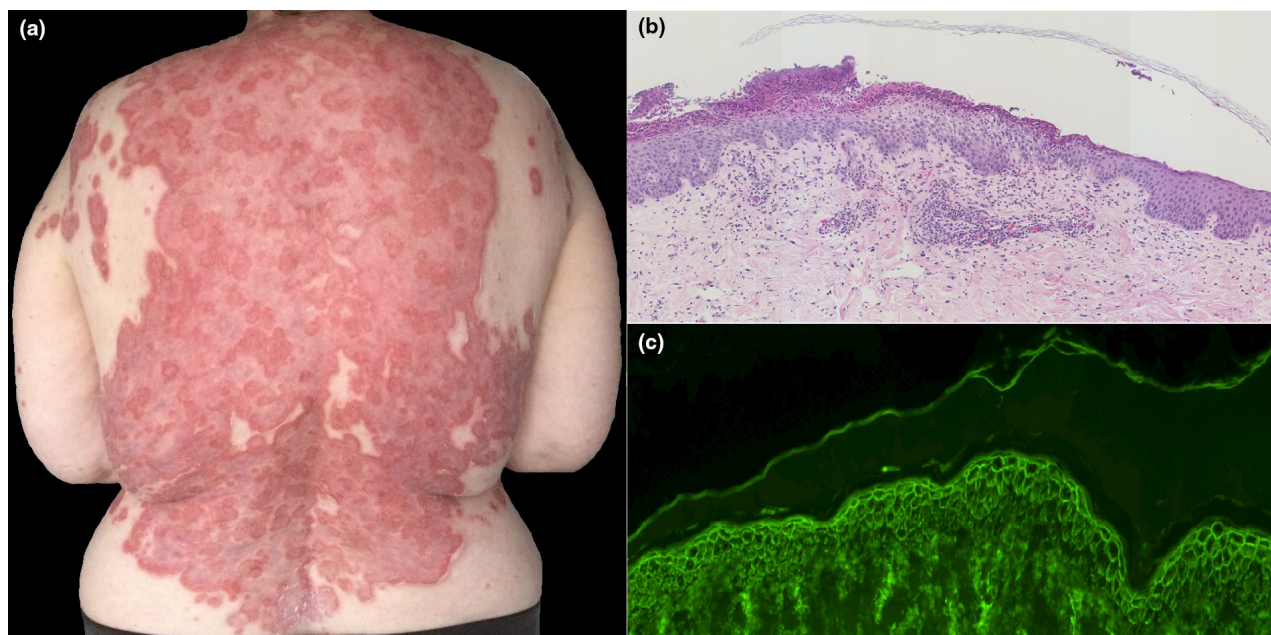


FIGURE 1 (a) Large erosive annular erythematous plaques on the back. (b) Histology of the skin shows subcorneal acantholysis and blister filled with neutrophils. The epidermis is infiltrated by a large number of neutrophils. H and E stain $\times 100$ magnification. (c) Direct immunofluorescent staining shows intercellular IgG in the epidermis in a chicken wire-like pattern. IMF stain $\times 200$ magnification.

TABLE 1 Summary table of reported cases of pemphigus triggered following COVID-19 vaccination

Age/sex	Type of pemphigus	Type of vaccine	Time to onset	Reference
38 F	PV	ChAdOx1 nCoV-19 (Astra Zeneca)	1 week after the first dose, No data on the second dose	Thongprasom K, Oral Dis, Sep 2021 ⁹
40 F	PV	BNT162b2 (Pfizer-BioNTech)	5 days after the first dose, worsening 3 days after the second dose	Solimani et al. ⁸
60 M	PV	mRNA-1273 (Moderna)	1 week after the second dose	Koutlas IG, Oral Dis, Nov 2021 ¹⁰
34 M	PV	ChAdOx1 nCoV-19 (Astra Zeneca)	Few days after the first dose, No data on the second dose	Hatami P, Dermatol Ther, Jan 2022 ¹¹
83 M	PF	BNT162b2 (Pfizer-BioNTech)	2 days after the second dose	Lua A, Australas J Dermatol, Feb 2022 ¹²
69 F	PV	Inactivated vaccine (CoronaVac)	1 week after the second dose	Akoglu G, Dermatol Ther, Feb 2022 ¹³
44 M	PV	ChAdOx1 nCoV-19 (Astra Zeneca)	1 week after the second dose	Singh A, J Cosmet Dermatol, March 2022 ¹⁴
76 F	PV	BBIBP-CorV (Sinopharm)	1 month after the second dose	Saffarian Z, Dermatol Ther, March 2022 ¹⁵
50 F	PF	BNT162b2 (Pfizer-BioNTech)	15 days after the second dose	Hali F, Cureus, March 2022 ¹⁶
58 F	PV	BNT162b2 (Pfizer-BioNTech)	1 month after the first dose, no data on the second dose	Hali F, Cureus, March 2022 ¹⁶
60 F	PV	BNT162b2 (Pfizer-BioNTech)	1 week after the second dose	Calabria E, Pathol Res Pract, April 2022 ¹⁷
89 M	PV	BNT162b2 (Pfizer-BioNTech)	1 month after the second dose	Knechtl GV, J Eur Acad Dermatol Venereol, April 2022 ¹⁸

type of deposition, in PF the fluorescence signal is stronger in the upper epidermis.¹ Based on the characteristic clinical and histological findings in this case, the diagnosis was confirmed as new onset Pemphigus Foliaceus following COVID-19 AstraZeneca vaccination. She was started on Prednisolone 0.75 mg/kg/day and mycophenolate mofetil as a steroid-sparing agent. This approach resulted in significant improvement of skin changes.

ChAdOx1 nCoV-19 (AstraZeneca) is an adenovirus-vector vaccine, which has been proven to generate robust neutralising antibody and cellular immune responses against the SARS-CoV-2 spike glycoprotein.⁵ The main proposed mechanism for AstraZeneca vaccine-induced pemphigus could be a hyper-immune reaction in genetically predisposed individuals, with eventual formation of anti-desmoglein antibodies. An alternative hypothesis is that vaccine components could act as foreign antigens resulting in a cross-reaction with pemphigus antigens, as previously postulated with other immunizations.⁶

There have been numerous reports of relapse or exacerbation of patients with a confirmed diagnosis of pemphigus following COVID-19 vaccination. Twelve cases of new emergence of pemphigus that are believed to be associated with the administration of various COVID-19 vaccines have also been reported in the literature (Table 1). The reported time interval between the vaccination and the occurrence of pemphigus is between 2 days to 1 month. Previous reports refer to only one dose of the vaccine, which includes either the first dose with

no information on the second dose or the second dose only. This pattern of reaction with a low probability score might suggest that vaccination coincidentally occurs shortly before the pemphigus appears. This may, therefore, raise the question as to whether a true relationship between COVID-19 vaccines and the new occurrence of pemphigus actually exists.⁷ However, the case we present here, as well as the case reported by Solimani et al.⁸ help shed some light on this concern. We believe that the close association of COVID-19 vaccination with the acute onset of pemphigus in our patient, as well as the exacerbation following subsequent administration of the vaccine, is more than a coincidence. This is supported by a probability score of 8 (possible causal reaction) on the Naranjo Adverse Drug Reaction Probability Scale.

Although a direct pathological link between the COVID-19 vaccines and the onset of pemphigus is not yet identified, continued observation and documentation of true adverse events of the vaccination is essential.

ACKNOWLEDGEMENT

The patients in this manuscript have given written informed consent to the publication of their case details.

FUNDING SOURCES

None.

CONFLICT OF INTEREST

None.

DATA AVAILABILITY STATEMENT

Data sharing not applicable – no new data generated, or the article describes entirely theoretical research.

Mina Almasi-Nasrabadi¹ 

Radha S. Ayyalaraju¹

Ashish Sharma¹

Somaia Elsheikh²

Shanti Ayob¹

¹*Department of Dermatology, Nottingham University Hospitals NHS Trust, Treatment Centre, Nottingham, UK*

²*Department of Histopathology, Nottingham University Hospitals NHS Trust, QMC Campus, Nottingham, UK*

Correspondence

Shanti Ayob, Department of Dermatology, Nottingham University Hospitals NHS Trust, Treatment Centre, Lister Road, Nottingham, NG7 2FT, UK.

Email: shanti.ayob@nuh.nhs.uk

ORCID

Mina Almasi-Nasrabadi  <https://orcid.org/0000-0002-9918-7260>

REFERENCES

- Melchionda V, Harman KE. Pemphigus vulgaris and pemphigus foliaceus: an overview of the clinical presentation, investigations and management. *Clin Exp Dermatol.* 2019;44:740–6.
- Timóteo RP, Silva MV, da Silva DAA, Catarino JDS, Alves FHC, Rodrigues Júnior V, et al. Cytokine and chemokines alterations in the endemic form of pemphigus foliaceus (fogo selvagem). *Front Immunol.* 2017;8:978.
- Timoteo RP, da Silva MV, Miguel CB, Silva DA, Catarino JD, Rodrigues Junior V, et al. Th1/Th17-related cytokines and chemokines and their implications in the pathogenesis of pemphigus vulgaris. *Mediators Inflamm.* 2017;2017:7151285.
- Tavakolpour S. Pemphigus trigger factors: special focus on pemphigus vulgaris and pemphigus foliaceus. *Arch Dermatol Res.* 2018;310:95–106.
- Ramasamy MN, Minassian AM, Ewer KJ, Flaxman AL, Folegatti PM, Owens DR, et al. Safety and immunogenicity of ChAdOx1 nCoV-19 vaccine administered in a prime-boost regimen in young and old adults (COV002): a single-blind, randomised, controlled, phase 2/3 trial. *Lancet.* 2021;19:1979–93.
- Simone CD, Caldarola G, D'agostino M, Zampetti A, Amerio P, Feliciani C. Exacerbation of pemphigus after influenza vaccination. *Clin Exp Dermatol.* 2008;33:718–20.
- Russo R, Gasparini G, Cozzani E, D'Agostino F, Parodi A. Absolving COVID-19 vaccination of autoimmune bullous disease onset. *Front Immunol.* 2022;13:834316.
- Solimani F, Mansour Y, Didona D, Dilling A, Ghoreschi K, Meier K. Development of severe pemphigus vulgaris following SARS-CoV-2 vaccination with BNT162b2. *J Eur Acad Dermatol Venereol.* 2021;35:e649–51.
- Thongprasom K, Pengpis N, Phattarataratip E, Samaranayake L. Oral pemphigus after COVID-19 vaccination. *Oral Dis.* 2021. <https://doi.org/10.1111/odi.14034>
- Koutlas IG, Camara R, Argyris PP, Davis MD, Miller DD. Development of pemphigus vulgaris after the second dose of the mRNA-1273 SARS-Cov-2 vaccine. *Oral Dis.* 2021. <https://doi.org/10.1111/odi.14089>
- Hatami P, Balighi K, Nicknam Asl H, Aryanian Z. COVID vaccination in patients under treatment with rituximab: A presentation of two cases from Iran and a review of the current knowledge with a specific focus on pemphigus. *Dermatol Ther.* 2022;35:e15216.
- Yin Lua AC, Ling Ong FL, Lin Choo KJ, Yeo YW, Oh CC. An unusual presentation of pemphigus foliaceus following COVID-19 vaccination. *Australas J Dermatol.* 2022;63:128–30.
- Akoglu G. Pemphigus vulgaris after SARS-CoV-2 vaccination: A case with new-onset and two cases with severe aggravation. *Dermatol Ther.* 2022;35:e15396.
- Singh A, Bharadwaj SJ, Chirayath AG, Ganguly S. Development of severe pemphigus vulgaris following ChAdOx1 nCoV-19 vaccination and review of literature. *J Cosmet Dermatol.* 2022;21:2311–4.
- Saffarian Z, Samii R, Ghanadan A, Vahidnezhad H. De novo severe pemphigus vulgaris following SARS-CoV-2 vaccination with BBIBP-CorV. *Dermatol Ther.* 2022;35:e15448.
- Hali F Sr, Araqi L Jr, Marnissi F, Meftah A, Chiheb S. Autoimmune bullous dermatosis following COVID-19 vaccination: a series of five cases. *Cureus.* 2022;14:e23127.
- Calabria E, Canfora F, Mascolo M, Varricchio S, Mignogna MD, Adamo D. Autoimmune mucocutaneous blistering diseases after SARS-Cov-2 vaccination: A Case report of Pemphigus Vulgaris and a literature review. *Pathol Res Pract.* 2022;232:153834.
- Knechtel GV, Seyed Jafari SM, Berger T, Rammlmair A, Feldmeyer L, Borradori L. Development of pemphigus vulgaris following mRNA SARS-CoV-19 BNT162b2 vaccination in an 89-year-old patient. *J Eur Acad Dermatol Venereol.* 2022;36:e251–3.