

Case Report

A First Report of Infestation by *Pseudolynchia canariensis* in a Herd of Pigeons in Shahrekord (Southwest of Iran)

Khodadad Pirali-Kheirabadi ¹, *Amir Dehghani-Samani ², Nader Ahmadi-Baberi ³, Vida Najafzadeh ⁴

¹Department of Pathobiology, Faculty of Veterinary Medicine, Shahrekord University, Shahrekord, Iran

²Department of Clinical Sciences, Faculty of Veterinary Medicine, Shahrekord University, Shahrekord, Iran

³Expert of the Faculty of Veterinary Medicine, Shahrekord University, Shahrekord, Iran

⁴Under Graduated Student of Faculty of Veterinary Medicine, Shahrekord University, Shahrekord, Iran

(Received 3 Aug 2013; accepted 1 Aug 2015)

Abstract

Background: Pigeons (*Columba livia*) have been kept as pet and reared for food in several countries including Iran. Ectoparasites are regarded as the basic causes of retardation in growth, lowered vitality and poor conditions of the birds. *Pseudolynchia canariensis* a hippoboscidae fly is one of the important ectoparasites of pigeons and is responsible for the transmission of pathogens to birds and humans same as pathogenic protozoan *Haemoproteus columbae*.

Methods: A herd of domestic pigeons contained 50 pigeons in Shahrekord, southwest Iran was evaluated clinically infested by ectoparasites. Ectoparasites were removed. The samples were collected and then referred to the Laboratory of Parasitology of Shahrekord University, Shahrekord, Iran.

Results: Usin diagnostic key for diptera fly, these flies were find *P. canariensis*. This is a rare report of infestation of pigeons herd by *P. canariensis* in Iran. The infestation rate was 40% that rate of infestation in pipers was more than females and in females was more than males.

Conclusion: The rate of infested pipers was more than adults that maybe the less potential of pipers in removing of ectoparasites is reason of this higher rate.

Keywords: Domestic pigeons, *Pseudolynchia canariensis*, Iran

Introduction

Pigeons and doves have colonized suburban and urban areas of Iran. Their interaction with humans and other domestic and wild animals portends them as a potential carrier of zoonotic pathogens and parasites same as *Haemoproteus columbae* (Dehghani-Samani et al. 2013). Pigeons constitute a major source of infection and transmission of diseases to human, same as yersiniosis (Hubbert 1972), salmonellosis (Muller 1965), western equine encephalomyelitis (Fothergill et al. 1938), cryptococcosis (Newberry et al. 1967), chlamydiosis or ornithosis (Terskikh et al. 1961) and Q fever (Syrucek and Raska 1956).

Several health problems can affect pigeons, but parasite infections play a major role. Ectoparasites are regarded as the basic causes of retardation in growth, lowered vitality and poor conditions of the birds. They can affect bird health directly by causing irritation, discomfort, tissue damage, blood loss, toxicosis, allergies and dermatitis which in turn reduce the quality and quantity of meat, initiate excessive preening which interrupts feeding, as the birds spend much time preening rather than being involved in other essential life activities and egg production (Wall and Shearer 2001, Mullen and Durden 2002).

Pseudolynchia Bequaert, 1926 a hippoboscid fly is responsible for the transmission of a pathogenic protozoan in pigeons (Dehghani Samani et al. 2013), hippoboscid flies are also considered potential carriers of parasites, mainly of chewing lice and mites that infest birds (Harbison et al. 2009).

Pseudolynchia is a genus containing five species. Of these, only *Pseudolynchia brunnea* Latreille, 1812 is endemic to the American continent (Bequaert 1955). *Pseudolynchia canariensis* Macquart, 1840 presents a large dorsoventrally flattened body, with a small head located immediately adjacent to the prothorax (Yamauchi et al. 2011).

Hippoboscidae flies are ubiquitous and a vector for *Haemoproteus* sp among pigeons and doves of the order *Columbiformes*, whereas *P. canariensis* is the vector of *H. columbae* among *Columba livia* pigeons, both in the case of natural and experimental infections (Gracioli and Carvalho 2003). They can be found in all biogeographical regions in the world and usually infect birds and some mammalian orders (Freitas et al. 2002).

Pseudolynchia canariensis feeds for 20 to 80 minute about twice a day (Arcoverde et al. 2009). The life history of *P. canariensis* has features that make it amenable to study in the lab. Eggs are hatched in uterus in the female and then three stages of larvae feed from milk glands (Harwood and James 1979). The larvae pupate and female flies deposit puparia in the substrate in or around pigeon nests (Arcoverde et al. 2009). The flies will reproduce on captive birds, depositing puparia under layers of newspaper lining pigeon cages. Female *P. canariensis* produce their first puparium six days after their first blood meal; they produce one puparium about every two days thereafter (Herath 1966, Klei 1971).

The present investigation was concentrated on the occurrence of *P. canariensis* infestation in the herd of domestic pigeons.

The aim of this report was to presentation of infestation with adult stage of a rare ectoparasite named *P. canariensis*, reported in southwest of Iran. We focused on some of keys that help us for identification of this fly's species.

Materials and Methods

Study area is located in Shahrekord, southwest Iran at 2000 meters above sea level with very cold climate. It is beside the southwest mountains, far from the sea, (31°59'59" N 50°39'42" E), the temprature in winter is less than 0 °C usually. At first we received information about a sever infestation of a domestic pigeons herd with diptera on July 2012, in visit of the herd of domestic pigeons with 50 pigeons (17 pigeons were male, 18 female and 15 pipers), all of the pigeons were infested. Clinical examination revealed several flies on the surface of the skin of all of the pigeons. Twenty samples were collected carefully from different parts of the body of birds, from down and contour feathers of skin, trunk, rump and nape feathers, quill feathers of wing and tail, and samples referred to the Laboratory of Parasitology for diagnosis. The identification was carried out under a microscope, according to identification keys of Hutson (1984).

Results

Our macroscopic and microscopic graphs show that wings of collected flies had only one cross-vein. Palpi distinctly more than twice as long as broad (Fig.1), median length of scutellum is about the distance between bases of scutellar setae; posterior margin of scutellum is more or less straight (Fig. 2), male mid metatarsus had ventral peg-like setae near base. Samples were identified and confirmed as *P. canariensis* (Fig. 3).



Fig. 1. Head, mouth appendix and palpi of *Pseudolynchia canariensis*

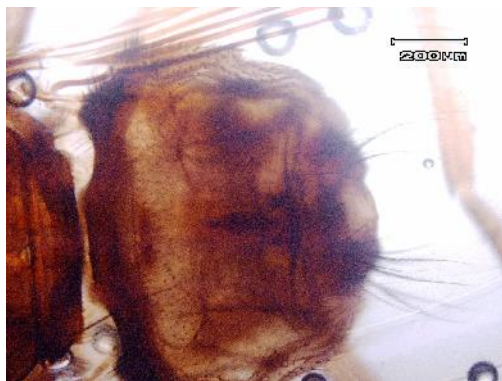


Fig. 2. Ventral view of abdomen of *Pseudolynchia canariensis*



Fig. 3. *Pseudolynchia canariensis* removed from *Columba livia*

Discussion

For the first time we report the infestation by *P. canariensis* of domestic pigeons in Shahrekord with very cold climate in south-west of Iran. Infestation by *P. canariensis* is reported from many locations in world but there is a few reports of this fly from different climates of Iran.

Same as our study, Radfar et al. (2012) observed a higher prevalence of *P. canariensis* on adult individuals of *C. livia* captured in the municipality of Khorasan, in the Iranian semiarid region. A low intensity of infestation of *P. canariensis* on adult individuals of *C. livia* is expected, as they acquire a higher level of immunity against parasites (Merila et al. 1995).

The prevalence of *C. livia* parasites was studied on the Canary Islands, where *P. canariensis* was observed in 36% of studied pigeons (Adlard et al. 2004). In the state of Minas Gerais, in southeastern Brazil, a research study with free-living pigeons (*C. livia domestica*) showed that all pigeons were infested with *P. canariensis* (Oliveira et al. 2000).

In this report, we showed the infestation by *P. canariensis* in pigeons only. We did not study on the seasonal distribution of this fly but the prevalence and intensity of infestation by *P. canariensis* were positively correlated to temperature, both being followed by autumn and least in winter. The increased prevalence of ectoparasites during summer months can be attributed to the requirement of optimum temperatures for the development of parasites and decreased resistance of birds to the parasites in high temperatures resulting in heavy infestations (Nadeem et al. 2007). In this report high infestation by *P. canariensis* occurred in summer in Iran same as Nadeem et al. (2007) report.

Conclusion

This report shows that pigeons can have high prevalence of ectoparasite infestation even if they kept in metal cages and near the humans. Parasitic infestations are harmful to their host; also, infested pigeons may transfer ectoparasites and other organisms to other hosts and humans. Therefore, we should care about this risk and find new effective ways to ward of these ectoparasites from our pets.

Acknowledgment

The authors are grateful to the Deputy of Research, University of Shahrekord for financial support of this project. The authors declare that there is no conflict of interests.

References

- Adlard RD, Peirce MA, Lederer R (2004) Blood parasites of birds from southeast Queensland. *Ornithology*. 104: 191–196.
- Arcoverde AR, Rodrigues AF, Daemon A (2009) Feeding and breeding aspects of *Pseudolynchia canariensis* (Macquart, 1839) (Diptera: Hippoboscidae) under laboratory conditions. *Parasitology Research*. 104: 277–280.
- Bequaert JC (1955) The hippoboscids or louse flies (Diptera) of mammals and birds. Part II. Taxonomy, evolution and revision of American genera and species. *Entomol Am, New Series*. 35: 233–416.
- Dehghani-Samani A, Pirali-Kheirabadi Kh, Dehghani-Samani A (2013) Prevalence and Rate of Parasitemia of *Haemoproteus columbae* in *Columba livia domestica* in Southwest of Iran. *Iran J Parasitol*. 8(4): 641–644.
- Fothergill L, John D, Dingle H, Farber S, Connerley ML (1938) Human encephalitis caused by the virus of the Eastern variety of equine encephalomyelitis. *New England J Med*. 219: 411.
- Frittas FL de, Oliveira MB de, Oliveira AB (2002) Gastrointestinal parasites of captive wild birds in Pernambuco state, Brazil. *Parasitol Latinoam*. 57: 50–54.
- Gracioli G, Carvalho CJB (2003) Hippoboscidae (Diptera: Hippoboscoidea) in the State of Paraná, Brazil: keys, hosts and geographic distribution. *Rev Bras Zool*. 20: 667–74.
- Harwood RF, James MT (1979) *Entomology in Human and Animal Health*. Seventh edition. Macmillan, New York, New York, USA, pp. 319–341.
- Harbison CW, Jacobsen MV, Clayton DH (2009) A hitchhiker's guide to parasite transmission: the phoretic behaviour of feather chewing lice. *Int J Parasitol*. 39: 569–575.
- Herath PRJ (1966) Colonizing *Pseudolynchia canariensis* on hosts other than the pigeon, *Columba livia*. Dissertation. Wayne State University, Detroit, Michigan, USA.
- Hubbert WT (1972) Yersiniosis in mammals and birds in the United States. *Am J Trop Med and Hyg*. 21: 458–463.
- Hutson AM (1984) Keds, flat-flies and bat-flies. Diptera, Hippoboscidae and Nycteribiidae- Handbooks for the Identification of British Insects. 10(7): 1–40.
- Klei TR (1971) Studies on *Haemoproteus columbae* of the pigeon, *Columba livia*, and the intermediate host *Pseudolynchia canariensis*. [Dissertation]. Wayne State University, Detroit, Michigan, USA.
- Merila J, Bjorklund M, Bennett GF (1995) Geographic and individual variation in haematozoan infections in the greenfinch, *Carduelis chloris*. *Can J Zool*. 73: 1798–1804.
- Mullen GR, Durden LA (2002) *Medical and Veterinary Entomology*. Academic Press, London.

- Muller G (1965) Salmonella in bird faeces. *Nature*. 207(5003): 1315.
- Nadeem M, Khan MN, Iqbal Z (2007) Determinants influencing prevalence of louse infestations on layers of district Faisalabad (Pakistan). *Br Poult Sci*. 48(5): 546–550.
- Newberry MW, Jinks J, Walter E, John W, Chandler J, Fred ET (1967) Epidemiological study of *Cryptococcus neoformans*. *Ann Int Med*. 67: 724–732.
- Oliveira PR, Mundim MJS, Cabral DD (2000) A survey of parasitic fauna in domestic pigeons (*Columba livia domestica*) in Uberlândia, MG, Brazil. *Vet Not*. 6: 53–56.
- Radfar MH, Asl EM, Seghinsara HR, Dehaghi MM, Fathi S (2012) Diversity and prevalence of parasites of domestic pigeons (*Columba livia domestica*) in a selected semiarid zone of South Khorasan, Iran. *Trop Anim Health Prod*. 44(2): 225–229.
- Syruczek L, Raska K (1956) Q fever in domestic and wild birds. *Bull World Health Organ*. 15(1–2): 329–337.
- Terskikh II, Chel'tsov-Bebutov AM, Kuborina LN, Keleinikov AA (1961) Study on ornithosis in birds and its natural focal occurrence. *Probl Virol*. 6: 141–146.
- Wall R, Sherarer D (2001) *Veterinary Ectoparasites: Biology, Pathology and Control*. 2nd edn. Wiley Blackwell, London, p. 304.
- Yamauchi T, Tsuda Y, Sato Y, Murata K (2011) Pigeon louse fly, *Pseudolynchia canariensis* (Diptera: Hippoboscidae), collected by dry-ice trap. *J Am Mosq Control Assoc*. 27(4): 441–443.