

Reduced-Force Closed Trocar Entry Technique: Analysis of Trocar Insertion Force Using a Mechanical Force Gauge

James Fanning, DO, Manish Shah, MD, Bradford Fenton, MD, PhD

ABSTRACT

Background and Objectives: Trocar insertion injury has a high morbidity, mortality, and cost. The purpose of this study was to compare standard trocar entry with our reduced-force closed trocar entry technique by measuring trocar insertion force using a mechanical force gauge.

Methods: In the operating room, the force gauge was inserted into a sterile glove and connected to the proximal portion of the trocar to measure insertion force. Through one incision, we used a standard closed trocar entry, while through the other incision, we used our reduced-force closed trocar entry technique. After making the skin incision and before trocar entry, we spread and dilated the skin, subcutaneous tissue, fascia, and muscle with a hemostat.

Results: Twenty-five patients entered the trial and none were excluded. Median trocar insertion force was 3.3lb (range, 1.6 to 5.4) with our reduced-force trocar entry technique versus 6.5lb (range, 2.0 to 14.0) with the standard trocar entry ($P=.001$). No complications occurred with the reduced-force trocar entry technique.

Conclusion: Our reduced-force trocar entry technique decreases trocar insertion force by 50%, requires no additional instruments or cost and is fast and safe. Reduced-entry force pressure may decrease the risk of trocar insertion injury.

Key Words: Laparoscopy, Reduced force, Trocar entry.

INTRODUCTION

Advanced laparoscopic procedures are increasingly being used as an alternative for laparotomy in gynecological surgery. A metaanalysis of 27 prospective randomized trials has proven the benefits of laparoscopic compared with abdominal gynecologic surgery: decreased pain, decreased surgical-site infections (decreased relative risk 80%), decreased hospital stay (2 days less), quicker return to activity (2 weeks sooner), and decreased postoperative adhesions (decreased by 60%).¹

Initial access into the abdomen is a major challenge of laparoscopy, because it can result in injury to the gastrointestinal tract, urinary tract, and blood vessels. Trocar insertion injury occurs in <1% of cases with 50% of these complications occurring during initial trocar insertion.² Because of the rarity of trocar insertion injury (1%), there are no prospective randomized studies to prove the safest method of trocar insertion.²

Veress needle-pneumoperitoneum-closed trocar entry is the most common laparoscopic entry technique.² Following a skin incision, the Veress needle is inserted and gas is insufflated into the abdomen. A trocar is then introduced into the abdominal cavity. We have developed a reduced-force closed trocar entry technique by spreading and dilating the skin, subcutaneous tissue, fascia, and muscle with a hemostat after making the skin incision and before Veress needle and trocar entry (**Figures 1 and 2**). This technique requires no additional instruments or cost, and takes only a few seconds to perform. We believe that this technique reduces the force of entry into the abdomen, which possibly could decrease injury associated with trocar insertion.

The purpose of this study was to compare standard trocar entry with our reduced-force trocar entry technique by measuring trocar insertion force with a mechanical force gauge.

MATERIALS AND METHODS

Female patients undergoing advanced gynecologic laparoscopic procedures through our standard four 5-mm tro-

Department of Obstetrics and Gynecology, Pennsylvania State University, Milton S. Hershey Medical Centre, Hershey, Pennsylvania USA (all authors).

Address correspondence to: James Fanning, DO, Professor, Chief, Division of Gynecologic Oncology, Department of Obstetrics and Gynecology, Pennsylvania State University, Milton S. Hershey Medical Center, 500 University Drive – Room C-3620, Hershey, PA 17033. USA. Telephone: (717) 531-8144, Fax: (717) 531-0007, E-mail: jfanning1@hmc.psu.edu

DOI: 10.4293/108680811X13022985131219

© 2011 by JSLS, *Journal of the Society of Laparoendoscopic Surgeons*. Published by the Society of Laparoendoscopic Surgeons, Inc.

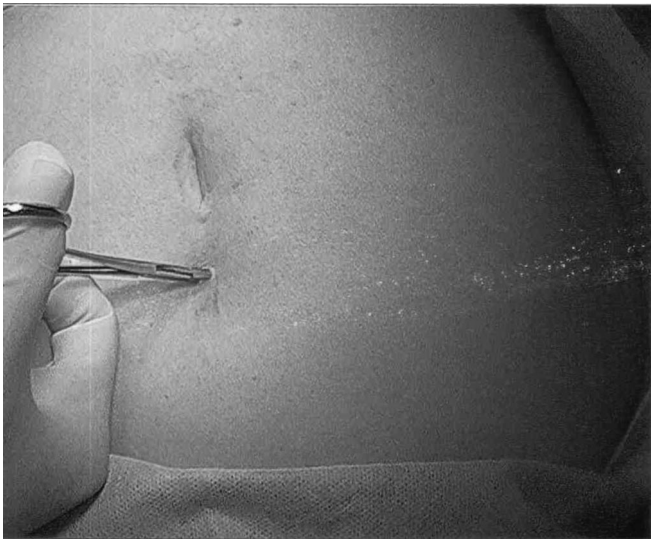


Figure 1. Reduced-force trocar entry technique.

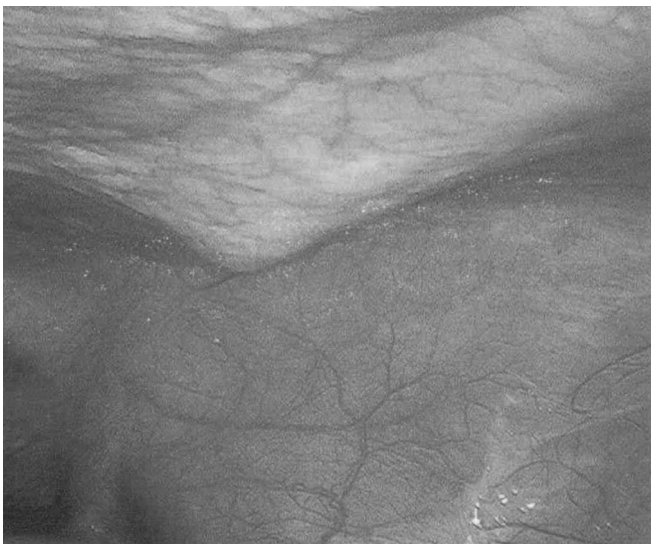


Figure 2. Reduced-force trocar entry technique—laparoscopic view—tips of hemostat visible above the peritoneum.

car approach³⁻⁶ were eligible. IRB approval and informed consent were obtained.

All patients received a preoperative bowel prep with 45cc of magnesium citrate orally, a single dose of preoperative prophylactic antibiotics if indicated, and external pneumatic cuffs. All procedures were performed with the patient under general endotracheal anesthesia with muscle relaxation. An orogastric tube was inserted and removed at the end of surgery. The patient was positioned in the dorsolithotomy position with legs in Allen stirrups.

Pressure was recorded by using a Wagner Force Dial, model FDK 10 (Wagner Instruments, Greenwich, CT), which is accurate to 0.1lb. In the operating room, the force gauge was inserted into a sterile glove. The force gauge was connected to the proximal portion of the trocar to measure the pressure of trocar insertion force. The same type of trocar was used in all cases: a 5-mm disposable, shielded, bladed design (Applied Medical, Rancho Santa, CA). We routinely perform our laparoscopic surgery through four 5-mm trocars.³⁻⁵ Two of 4 trocars are parallel to each other in the right and left lower quadrants. Using a pen, we marked the 2 incision locations having the same size (7mm) and same location (1 in the right and 1 in the left lower quadrant). The exact location depended on the individual surgery. As per our standard, no trocar insertions are through a prior surgical scar. Through one of the incisions, we used a standard trocar entry while through the other incision we used our reduced-force trocar entry technique. After making the skin incision and prior to trocar entry, we spread and dilated the skin, subcutaneous tissue, fascia and muscle with a hemostat (**Figures 1 and 2**). Successful dilation can be felt manually and was verified laparoscopically by an assistant. The trocar was then inserted. Because of the dilation, the trocar routinely follows the same insertion path. We alternated the side (right vs. left) of the reduced-force trocar entry technique every other patient. All trocar insertions were performed by the same surgeon, using the right (dominant) hand and standing on the trocar side of the patient. Pressure readings during insertion were blinded, because the Wagner Force Dial was inside a surgical glove. Standard trocar entry and reduced-force trocar entry technique were not observed laparoscopically (the surgeon performing the trocar insertion did not look at the monitor during insertion) in an effort to mimic initial trocar insertion.

Insertion force was compared using a 2-tailed *t* test. Sample size calculation using a P value of 0.05 and a power of 0.8 required a sample size of 12 patients used as their own controls to detect a 30% difference in force.

RESULTS

Twenty-five patients entered the trial and none were excluded. Median age was 56 years (range 41 to 80), and median BMI was 33kg/m² (range, 24 to 51). Of the patients, 80% had medical comorbidities, 48% had prior abdominal surgery, and 80% were Caucasian.

Median operative time was 2.0 hours (range, 1.1 to 3.5), and median blood loss was 150cc (range, 50 to 500).

Median trocar insertion force was 3.3lb (range, 1.6 to 5.4) with our reduced-force trocar entry technique versus 6.5lb (range, 2.0 to 14.1) with standard trocar entry (P=.001).

There were no port-site hematomas or other complications with the reduced-force trocar entry technique, and there was no problem with inadvertent port withdrawal. Although not prospectively evaluated, no patient reported increased pain at the dilated port site.

DISCUSSION

Advanced laparoscopic procedures are increasingly being utilized with multiple proven benefits. Although rare (1%), trocar insertion injury can be a serious complication. In a review of 629 FDA reported cases, mortality was 5%, including a 21% mortality following bowel injury not recognized during surgery.⁷ Trocar insertion injury frequently results in malpractice litigation that is expensive to settle.⁸ Because of the rarity of trocar insertion injury, there are no prospective randomized studies to prove the safest method of trocar insertion²: Veress needle, closed trocar entry, open trocar entry (Hasson), or visual entry. Although not proven, it is logical that greater entry force pressure may increase the risk of injury to the gastrointestinal tract, urinary tract, and blood vessels. In fact, the major drawback of radially expanding trocars is the excessive force required for entry.² In a PubMed search, we located several studies measuring trocar insertion force,^{9,10} but none evaluating a reduced-force trocar entry technique.

Our reduced-force trocar entry technique decreases insertion force pressure ~50%. We consider our force pressures are accurate, because the Wagner Force Dial is accurate to 0.1lb, incision locations were precisely marked, the same surgeon performed all trocar insertions, and pressure readings were blinded. Since 50% of trocar insertion injuries occur during initial trocar insertion, we attempted to mimic initial trocar insertion by not observing standard trocar entry and reduced-force trocar entry techniques laparoscopically. Although time was not measured in this study, reduced-force trocar entry technique takes ~5 seconds to perform. Because it requires no additional instruments and takes minimal time to perform, there is no additional cost. There were

no complications with the reduced-force trocar entry technique, which is predictable since the hemostat remains above the peritoneum.

CONCLUSION

We have developed a reduced-force trocar entry technique that decreases insertion force pressure ~50%, requires no additional instruments or cost and is fast and safe. Because reduced-entry force pressure may decrease the risk of trocar insertion injury, we recommend the use of our reduced-force trocar entry technique.

References:

1. Johnson N, Barlow D, Lethaby A, Tavender E, Curr E, Garry R. Surgical approach to hysterectomy for benign gynaecological disease. *Cochrane Database Syst Rev.* 2005;1:DC003677.
2. Vilos GA, Ternamian A, Dempster J, Laberge PY. The Society of Obstetrics and Gynecology of Canada. Laparoscopy entry: a review of techniques, technologies and complications. *J Obstet Gynaecol Can.* 2007;29(5):433–465.
3. Fanning J, Fenton B, Purohit M. Robotic radical hysterectomy. *Am J Obstet Gynecol.* 2008;198:649–650.
4. Fanning J, Fenton B, Switzer M, Johnson J, Clemons J. Laparoscopically assisted vaginal hysterectomy for uteri weighing 1,000 g or more. *JLS.* 2008;12:376–379.
5. Fanning J, Trinh H. Feasibility of laparoscopic ovarian debulking at recurrence in patients with prior laparotomy debulking. *Am J Obstet Gynecol.* 2004;190:1394–1397.
6. Fanning J, Hojat R, Johnson J, Fenton B. Laparoscopic cytoreduction for primary advanced ovarian cancer. *JLS.* 2009;13:S3.
7. Bhojru S, Vierra MA, Nezhat CR, Krummel TM, Way LW. Trocar injuries in laparoscopic surgery. *J Am Coll Surg.* 2001;192(6):677–683.
8. Kren KA. Malpractice litigation involving laparoscopic cholecystectomy. Cost, cause, and consequences. *Arch Surg.* 1997 Apr;132(4):392–397; discussion 397–398.
9. Shafer DM, Khajanchee Y, Wong J, Swanstrom LL. Comparison of five different trocar systems: analysis of insertion force, removal force and defect size. *Surg Innov.* 2006 Sept;13(3):183–189.
10. Ng PS, Sahota DS, Yuen PM. Measurement of trocar insertion force using a piezoelectric transducer. *J Am Assoc Gynecol Laparosc.* 2003;10(4):534–538.