

CASE REPORT

Open Access



# Superior vena cava syndrome after pacemaker implantation treated with direct oral anticoagulation

Nicola Mumoli<sup>\*</sup> , Antonino Mazzone, Isabella Evangelista, Marco Cei and Alessandra Colombo

## Abstract

**Background:** Superior Vena Cava (SVC) syndrome, is a quite rare but serious complication after pacemaker lead implantation; most patients are asymptomatic due to the development of adequate venous collateral circulation.

**Case presentation:** We report a case of a 75-year-old woman who developed SVC syndrome after transvenous pacemaker implantation with complete resolution of the thrombosis after 3 months of oral anticoagulation.

**Conclusions:** Generally other causes as malignancy are considered to be the most common etiology of SVC syndrome, but benign iatrogenic causes, mainly intravascular devices (central vein catheters, cardiac defibrillators and pacemaker wires), are becoming increasingly common. Procedures performed on venous vasculature, causing a possible intimal injury or vein stenosis, provoked by transvenous leads, seem to be the most reasonable explanation for the observed complication.

**Keywords:** Superior vena cava, Pacemaker, Thrombosis

## Background

The Superior Vena Cava (SVC) represents the main drainage vessel for the venous blood of the head, neck, upper extremities, and upper chest. SVC syndrome is a very rare but debilitating complication after pacemaker lead implantation. Symptoms depend on how quickly the obstruction establishes. They include headache, upper limb edema, jugular vein distention, cyanosis, and facial swelling.

## Case presentation

A 75-year-old woman was admitted to our Emergency Department because of headache and progressive cyanosis and swelling of the face, neck, thorax, and both upper extremities. She denied any pain, but reported heaviness of both arms. These symptoms worsened

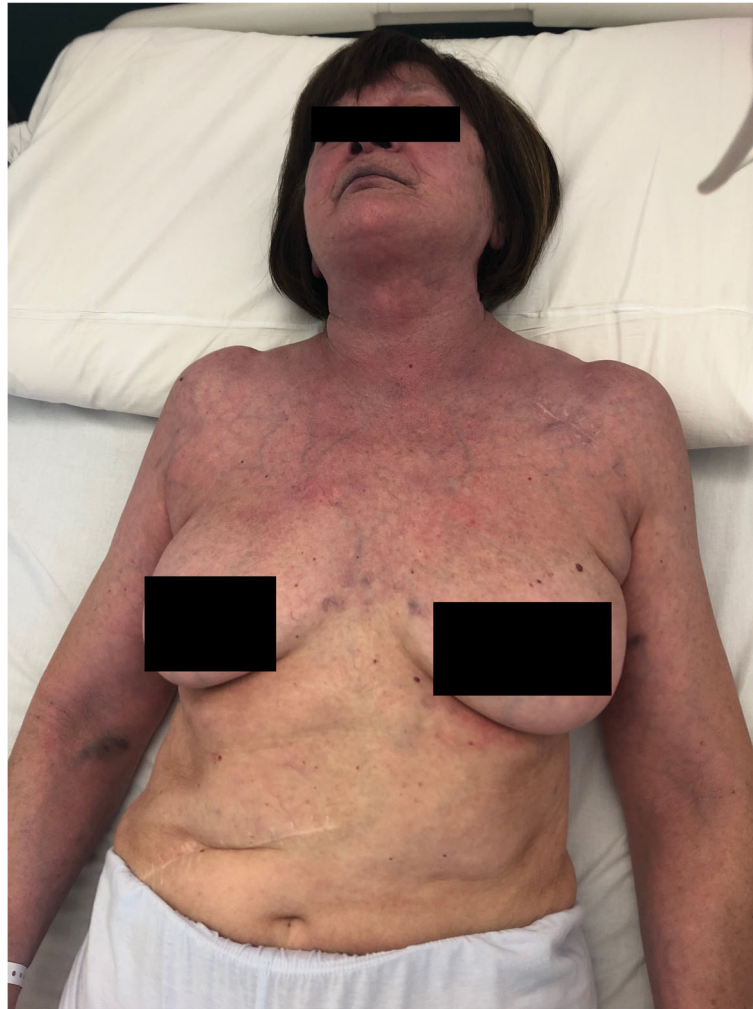gradually over the past 4 months. Her medical history included pacemaker implantation 2 years before for sick sinus syndrome; physical examination revealed cyanosis, edema, and prominent engorged vasculature on the face, neck, bilateral upper limbs and anterior chest wall (Fig. 1). Complete blood count, coagulation, renal and hepatic function were within normal limits, except for an increase in D-dimer value (925 ng/mL; upper reference limit, < 270 ng/mL). Computed tomography (CT) angiography of the chest (Fig. 2, arrow) and superior cavography (Fig. 3, arrow) revealed a thrombus obstructing the superior vena cava around indwelling pacemaker leads, with increased flow through the collateral circulation. Balloon angioplasty was considered [1] but the patient refused. Due to the long period of onset of symptoms, treatment with fibrinolytics was not considered appropriate. After a week of full dose subcutaneous enoxaparin, anticoagulation with Edoxaban 60 mg once daily was started and gradually a complete resolution of

\* Correspondence: [nicola.mumoli@asst-ovestmi.it](mailto:nicola.mumoli@asst-ovestmi.it)

Department of Internal Medicine, Ospedale Fornaroli, via Donatori Sangue, 50, 20013 Magenta, MI, Italy



© The Author(s). 2021 **Open Access** This article is licensed under a Creative Commons Attribution 4.0 International License, which permits use, sharing, adaptation, distribution and reproduction in any medium or format, as long as you give appropriate credit to the original author(s) and the source, provide a link to the Creative Commons licence, and indicate if changes were made. The images or other third party material in this article are included in the article's Creative Commons licence, unless indicated otherwise in a credit line to the material. If material is not included in the article's Creative Commons licence and your intended use is not permitted by statutory regulation or exceeds the permitted use, you will need to obtain permission directly from the copyright holder. To view a copy of this licence, visit <http://creativecommons.org/licenses/by/4.0/>. The Creative Commons Public Domain Dedication waiver (<http://creativecommons.org/publicdomain/zero/1.0/>) applies to the data made available in this article, unless otherwise stated in a credit line to the data.



**Fig. 1** The image show cyanosis, edema and prominent engorged vasculature in the face, neck, bilateral upper limbs and anterior chest wall

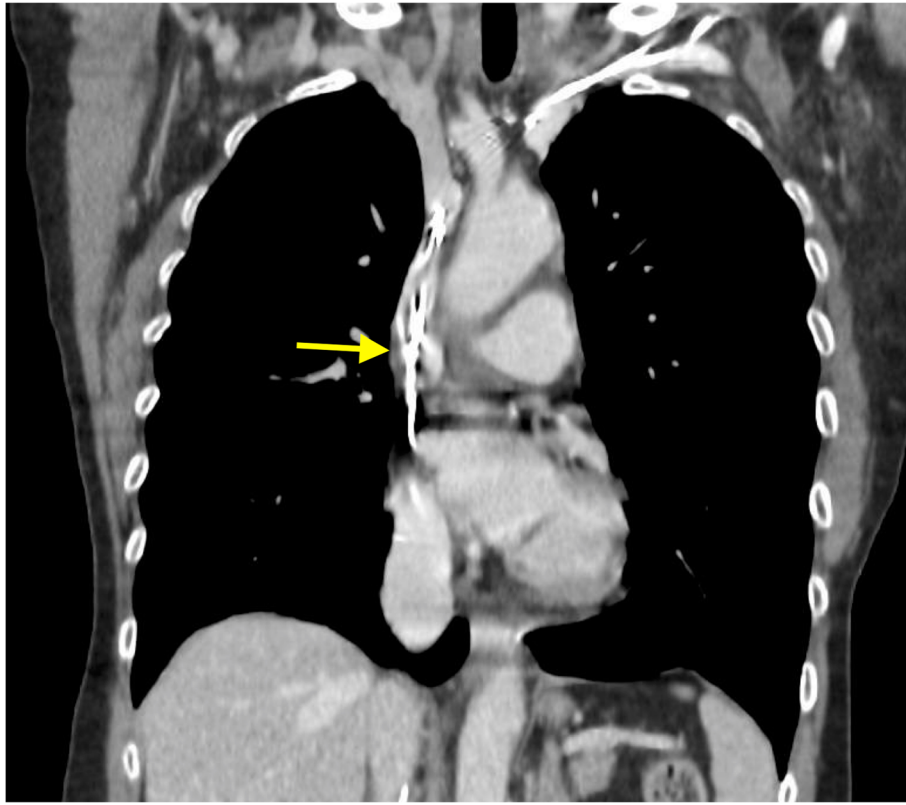
the symptoms was obtained. The patient was discharged in a stable condition 10 days later.

Three months later, the patient was free of symptoms and a chest CT angiography revealed complete resolution of the thrombosis and the anticoagulant was interrupted without evidence of recurrence 3 months afterward.

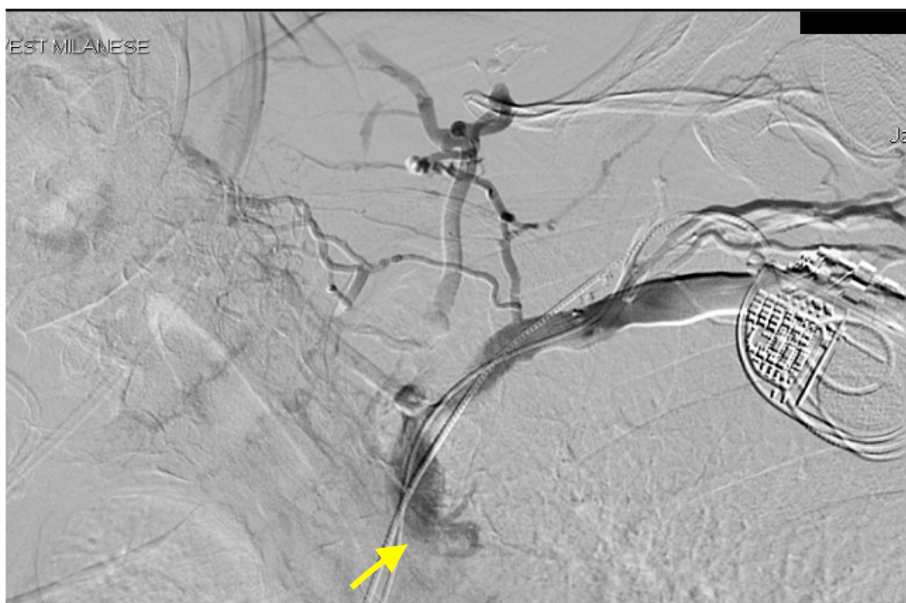### Discussion and conclusions

Superior Vena Cava (SVC) syndrome [2, 3] is a very rare but debilitating complication after pacemaker lead implantation. Symptoms depend on how quickly the obstruction establishes; however, the insurgence of thrombosis caused by pacemaker leads seems to be unrelated to the time elapsed from the procedure [4]. Most patients are often less symptomatic due to the development of collateral circulation. Several causes lead to this syndrome. The most common is malignancy (85%): lung cancer, lymphomas; metastasis to the mediastinum from

breast cancer or gastrointestinal tumors, primary mediastinal tumors. The mechanisms most involved are extrinsic compression and neoplastic infiltration of SVC. Less commonly, non-oncologic causes may occur: infections, spontaneous thrombosis, and iatrogenic causes. Among the latter, radiotherapy on the mediastinum and thrombosis or infections of intravascular devices (central vein catheters, cardiac defibrillators, and pacemaker wires) are becoming increasingly common. However, in a large series from Rice [5], a pacemaker was considered to be the cause of SVC syndrome in only 1 out of 78 cases (1.28%). Procedures performed on venous vasculature, causing a possible intimal injury or vein stenosis, provoked by transvenous leads, seem to be the most reasonable explanation for the observed complication. The treatment of SVC syndrome involves the use of medical, interventional, or surgical therapy. Medical management includes anticoagulants or thrombolytics; interventional procedures commonly performed include balloon



**Fig. 2** Thoracic CT angiography in coronal view, showing a superior vena cava obstruction determined by thrombus (arrow) around indwelling leads



**Fig. 3** superior cavography showing a minus image in superior vena cava (arrow) around indwelling leads, with increased flow through the collateral circulation (indirect thrombus demonstration)

angioplasty and stenting. The duration of symptoms before the onset of thrombolytic therapy, can often guide the most appropriate approach. The success rate of thrombolytic therapy is greater if treatment is begun less than or equal to 5 days after the symptoms started. Endovascular repair is less invasive but equally effective compared to the surgical approach. The open repair treatment is mostly used in SVC syndrome due to mediastinal fibrosis [2]. When the cause is pacemaker implantation two treatments are possible. The first one is the lead removal, stent implantation, and reimplantation of new leads, but the long-term efficacy of this approach is unknown. The other one is balloon dilatation of the vein with stent placement [1]. Adjuvant anticoagulation is usually used after angioplasty. In our case, the patient refused the endovascular treatment so the medical approach was adopted. Furthermore, due to the long persistence of symptoms, we speculated that the thrombosis was not acute, and hypothesized that anticoagulation should restore a favorable balance between thrombosis persistence and physiologic fibrinolysis, leading to thrombus resolution. The anticoagulation treatment of upper extremity deep vein thrombosis (UE-DVT) has not been standardized yet; however, the current practice is to start warfarin after 5 to 7 days of low-molecular-weight heparin. Currently, there are no completed randomized trials of direct oral anticoagulants (DOACs) in UE-DVT; nevertheless, DOACs are increasingly used in real-world experiences with an adequate profile of efficacy and safety [6]. Thus, treatment of iatrogenic superior vena cava thrombosis with a DOAC represents an interesting new approach, to be validated in prospective trials against the current standard (heparin followed by warfarin).

#### Abbreviations

SVC: Superior Vena Cava; CT: computed tomography; UE-DVT: upper extremity deep vein thrombosis; DOACs: direct oral anticoagulants

#### Authors' contributions

Nicola Mumoli treated the patient and wrote the manuscript. Isabella Evangelista, Marco Cei, Antonino Mazzone and Alessandra Colombo revised and edited the manuscript. All authors have read and approved the final manuscript.

#### Funding

The authors received no financial support for the research, authorship, and/or publication of this article.

#### Availability of data and materials

Not applicable.

#### Declarations

##### Ethics approval and consent to participate

Our study adhered to the Ethical Guidelines for Medical and Health Research Involving Human Subjects established by the Declaration of Helsinki.

#### Consent for publication

Written informed consent was obtained from the patient for publication of this case report and any accompanying images.

#### Competing interests

The authors declared no potential conflicts of interest.

Received: 30 June 2021 Accepted: 8 September 2021

Published online: 08 November 2021

#### References

1. Teo N, Sabharwal T, Rowland E, Curry P, Adam A. Treatment of superior vena cava obstruction secondary to pacemaker wires with balloon venoplasty and insertion of metallic stents. *Eur Heart J*. 2002;23:1465–70.
2. Sfyroeras GS, Antonopoulos CN, Mantas G, Moulakakis KG, Kakisis JD, Brontzos E, Lattimer CR, Geroulakos G. A review of open and endovascular treatment of superior vena cava syndrome of benign Aetiology. *Eur J Vasc Endovasc Surg* 2017;53(2):238–254. doi: <https://doi.org/10.1016/j.ejvs.2016.11.013>. Epub 2016 Dec 19. PMID: 28007450.
3. Picascia O, Fiorini V, Vitale G, Quassone P, Scognamiglio M, Ferrandino G, Pelella I, Rosano N, De Simone F, Sarti G, Camocardi A, Tamburrini S, Marano I. Iatrogenic superior vena cava syndrome with concomitant deep vein thrombosis of azygos and hemiazygos veins. *Radiol Case Rep*. 2021; 16(7):1895–1898. doi: <https://doi.org/10.1016/j.radcr.2021.04.061>. PMID: 34113414; PMCID: PMC8170043.
4. Mazzetti H, Dussaut A, Tentori C, Dussaut E, Lazzari JO. Superior vena cava occlusion and/or syndrome related to pacemaker leads. *Am Heart J* 1993; 125(3):831–837. doi: [https://doi.org/10.1016/0002-8703\(93\)90178-c](https://doi.org/10.1016/0002-8703(93)90178-c). PMID: 8438712.
5. Rice TW, Rodriguez RM, Light RW. The superior vena cava syndrome: clinical characteristics and evolving etiology. *Medicine (Baltimore)* 2006;85(1):37–42. doi: <https://doi.org/10.1097/01.md.0000198474.99876.f0>. PMID: 16523051.
6. Montiel FS, Ghazvinian R, Gottsäter A, Elf J. Treatment with direct oral anticoagulants in patients with upper extremity deep vein thrombosis. *Thromb J*. 2017;15:26.

#### Publisher's Note

Springer Nature remains neutral with regard to jurisdictional claims in published maps and institutional affiliations.

Ready to submit your research? Choose BMC and benefit from:

- fast, convenient online submission
- thorough peer review by experienced researchers in your field
- rapid publication on acceptance
- support for research data, including large and complex data types
- gold Open Access which fosters wider collaboration and increased citations
- maximum visibility for your research: over 100M website views per year

At BMC, research is always in progress.

Learn more [biomedcentral.com/submissions](https://biomedcentral.com/submissions)

