

# VEGFR-1 Expression Relates to Fuhrman Nuclear Grade of Clear Cell Renal Cell Carcinoma

Sayamaa Lkhagvadorj<sup>1</sup>, Sung Soo Oh<sup>2</sup>, Mi-Ra Lee<sup>1</sup>, Jae Hung Jung<sup>3</sup>, Hyun Chul Chung<sup>3</sup>, Seung-Kuy Cha<sup>4,5</sup>, Minseob Eom<sup>1,\*</sup>

Departments of <sup>1</sup>Pathology, <sup>2</sup>Occupational & Environmental Medicine, <sup>3</sup>Urology, and <sup>4</sup>Physiology, and <sup>5</sup>Institute of Lifestyle Medicine, Yonsei University Wonju College of Medicine, Wonju, Korea

**Background:** Increasing evidence suggests that vascular endothelial growth factor (VEGF) and VEGF receptor (VEGFR) 1 signaling may play an important role in the progression of pathological angiogenesis that occurs in many tumors, including renal cell carcinoma (RCC). Therapeutic targeting directed against VEGF and VEGFR-2 has been proven to be successful for metastatic clear cell RCC (CCRCC). However, the expression of VEGFR-1 and its association with prognostic parameters of CCRCC in the tumorigenesis of renal cancer remains unclear. Therefore, we examined the expression of VEGFR-1 and its prognostic significance in CCRCC.

**Methods:** Immunohistochemical staining for VEGFR-1 was performed on 126 formalin-fixed paraffin-embedded CCRCC tissue samples. Six of these cases were available for Western blot analyses. The results were compared with various clinicopathologic parameters of CCRCC and patients' survival.

**Results:** VEGFR-1 expression was detected in 59 cases (46.8%) of CCRCC. Higher VEGFR-1 expression was significantly correlated with a lower Fuhrman nuclear grade and the absence of renal pelvis invasion, although it was not related to patients' survival. Western blot analyses showed higher VEGFR-1 expression in low grade tumors.

**Conclusion:** VEGFR-1 expression may be associated with favorable prognostic factors, particularly a lower Fuhrman nuclear grade in CCRCC.

**Key Words:** VEGFR-1, Clear Cell Renal Carcinoma, Prognosis, Immunohistochemistry, Western blotting

## INTRODUCTION

Renal cell carcinoma (RCC) is the most common renal tumor and accounts for 3% of all malignancies in adults [1]. The incidence and mortality of renal cancer has increased worldwide, which is probably due to both an increased prevalence of risk factors and an improvement of diagnosis [2]. According to the cancer statistics in Korea, the incidence of

RCC in Korea has shown a steady increase, a trend that has also been seen worldwide [3]. Surgery is an effective treatment for the majority of patients who present with clinically localized RCC. However, metastatic RCC is still difficult to treat and the outcome of patients with metastatic RCC is very poor [4].

Clear cell RCC (CCRCC), which is the most common subtype of RCC, is mainly associated with mutational inactivation of von Hippel-Lindau (*VHL*), which plays an important role in tumor growth [5]. The VHL protein negatively regulates hypoxia-inducible factor-1  $\alpha$  (HIF-1  $\alpha$ ) [6] and the activated HIF-1  $\alpha$  translocates into the nucleus and induces the transcription of hypoxia-inducible genes,

Received: February 23, 2014, Accepted: March 7, 2014

\*Corresponding author: Minseob Eom

Department of Pathology, Yonsei University Wonju College of Medicine, 20 Ilsan-ro, Wonju, Gangwondo 220-701, Republic of Korea  
Tel: 82-33-741-1554, Fax: 82-33-731-6590  
E-mail: eomm@yonsei.ac.kr

including vascular endothelial growth factor (VEGF), platelet-derived growth factor (PDGF), basic fibroblast growth factor (bFGF), and transforming growth factor  $\alpha$  (TGF- $\alpha$ ) [7-11]. As a growth factor, VEGF exerts its biological effect mainly through interaction with its two different receptors, VEGF receptor (VEGFR)-1 (Flt-1) and VEGFR-2 (Flk-1), which are selectively expressed on vascular endothelial cells [12]. Therapeutic targeting directed against VEGF and VEGFR-2 has been successful for metastatic RCC treatment [13]. Increasing evidence suggests that VEGF/VEGFR-1 signaling is crucial for angiogenesis of CCRCC, which consists of highly vascularized malignant tumors [14]. Therefore, further characterization of VEGFR-1 expression in CCRCC is needed.

The expression of VEGF and VEGFR-1 has been studied in CCRCC [15,16]. However, the expression level of VEGFR-1 and its potential prognostic significance in comparison to clinicopathological parameters of CCRCC has not been analyzed. Therefore, we asked whether VEGFR-1 expression is correlated with the clinicopathological parameters of CCRCC. In this study, we examined the expression of VEGFR-1 in CCRCC and compared its expression with well-known prognostic factors of CCRCC and with patient survival to validate its prognostic value.

## MATERIALS AND METHODS

### 1. Patients and tissue samples

Formalin-fixed paraffin-embedded (FFPE) tissue samples from 126 patients of CCRCC were collected. All patients underwent radical nephrectomy at the Yonsei University Wonju Severance Christian Hospital from 2001 to 2011. Two expert pathologists reviewed all pathology slides with the pathologic reports and clinical records. Tumor staging was reclassified according to the seventh edition of the AJCC cancer staging manual [17]. Nuclear grade was classified according to the Fuhrman nuclear grading system and grouped into low grade (grade 1+2) and high grade (grade 3+4) [18]. Six fresh tissue samples of CCRCC were available for Western blot analysis. The institutional ethics committee of Yonsei University Wonju College of Medicine approved this study.

### 2. Immunohistochemistry (IHC)

Representative tumor site without necrosis and hemorrhage was marked in the paraffin block. The selected tumor area was harvested using a 5-mm Quick-ray tip-punch (Unitma, Seoul, Korea), placed on a 20-pore TMA mold (Unitma), and re-embedded with paraffin. 4- $\mu$ m sections of TMA blocks were cut and attached onto coated slides.

Immunohistochemical staining was performed using the Ventana Benchmark XT (Roche Diagnostics, Basel, Switzerland) automatic immunostaining machine. The sections were deparaffinized in xylene, rehydrated in graded alcohols, and subjected to pretreatment with CC1 (Roche Diagnostics). The sections were washed with reaction buffer followed by incubation with primary VEGFR-1 antibody (Abcam, Cambridge, MA, USA) at a 1:50 dilution for 60 min at 42°C. Bound antibody was detected with the Ultra View Universal DAB kit (Roche Diagnostics) and sections were counterstained with hematoxylin (Roche Diagnostics) according to the manufacturer's instructions. Positive and negative control stains were also performed.

We used a modified Allred scoring system to evaluate positivity, with staining intensity and distribution being scored separately [19]. The staining intensity was scored as 0 points (negative), 1 point (weak), 2 points (intermediate), or 3 points (strong) and the distribution of positive-stained cells was assessed as 0 point (negative), 1 point (<1%), 2 points (1-10%), 3 points (11-33%), 4 points (34-67%), or 5 points (>67%). The total staining score was calculated as the sum of two parameters. Total staining scores from 0 to 2 points were considered negative, while scores from 3 to 8 points were considered positive. The mean staining scores were also compared as continuous variables in each group.

### 3. Western blot analysis

The six cases of CCRCC with adjacent normal kidney parenchyma were lysed using 2 mL of PRO-PREP lysis buffer (iNtRon Biotechnology, Daejeon, Korea), and then ground for 15-20 sec on ice using a homogenizer (ProScience, Woburn, MA, USA). The lysates were centrifuged at 13,000 rpm for 15 min. The protein concentration was measured using the Bradford protein assay. An amount of 10  $\mu$ g of protein from each sample was used for sodium dodecyl sul-

fate-polyacrylamide gel electrophoresis (SDS-PAGE). Proteins were transferred to immobilon-P membranes (Millipore, Billerica, MA, USA), using an electrophoretic transfer system (Bio-Rad, Hercules, CA, USA) at 100V for one and a half hours. The membranes were blocked with 5% skim milk in TBS-T buffer for an hour. The blocked membranes were washed with TBS-T buffer and incubated overnight at 4°C in primary VEGF Receptor 1 (Abcam) and  $\beta$ -actin (Santa Cruz Biotechnology, Dallas, TX, USA) antibodies, with dilutions of 1:2000 and 1:5000, respectively. The membranes were then incubated with secondary Anti-Mouse IgG-HRP (Santa Cruz Biotechnology) antibody using a dilution of 1:5000 for one hour at room temperature. Immunoreactive proteins were detected using the Luminata TM Forte Western HRP Substrate (Millipore) and the Biospectrum Imaging System (UVP, Upland, CA, USA). Band densities on immunoblots were measured with the ImageJ software (available at <http://rsb.info.nih.gov/ij/index.html>).

#### 4. Statistical analysis

Statistical analysis was performed using PASW, version

20.0 (SPSS Inc., Chicago, IL, USA).  $\chi^2$  test, student's *t*-test, and ANOVA were used to compare the categorical and continuous variables. The period of overall survival was measured from the date of surgery to the date of death due to the tumor. Tumor recurrence was defined as the presence of clinically diagnosed or pathologically confirmed metastases after surgery. Survival rates were analyzed using the Kaplan-Meier method and compared using the log-rank test. A value of  $p < 0.05$  was considered statistically significant.

## RESULTS

### 1. General clinicopathological characteristics

Most patients in this study were men with a mean age of  $57.4 \pm 10.5$  years. The mean tumor size was  $5.3 \pm 2.7$  cm. Fifteen cases (11.9%) were Fuhrman nuclear grade 1, 57 cases (45.2%) were grade 2, 42 cases (33.4%) were grade 3, and 12 cases (9.5%) were grade 4. Eighty-seven cases (69.0%) were TNM stage I, 13 cases (10.3%) were stage II, 22 cases (17.5%) were stage III, and four cases (3.2%) were stage IV. There was follow-up information on 123 out of 126 patients. The median follow-up time was 45 months. Nine patients (7.1%) had tumor recurrence. Twelve patients (9.5%) died due to the tumor at the time of the last follow-up. These data are summarized in Table 1.

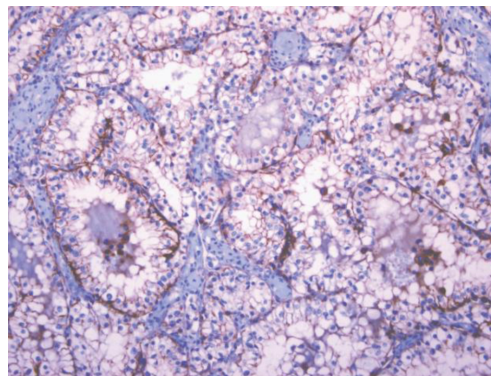
### 2. Expression pattern of VEGFR-1 and its correlation with CCRCC prognostic factors

The IHC staining showed that VEGFR-1 was observed in the membrane and/or cytoplasm of the tumor cells (Fig. 1).

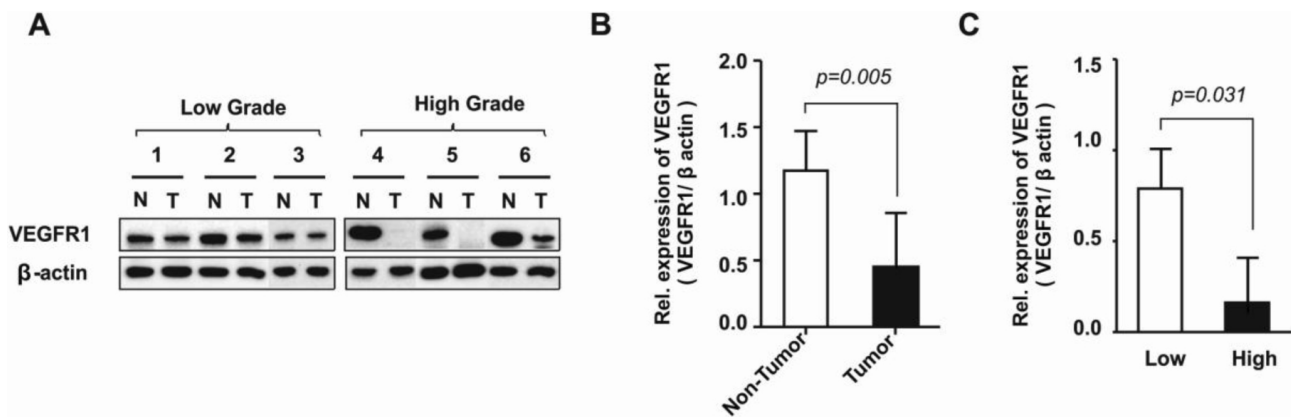
**Table 1.** Summary of clinical and pathological findings

Characteristics	Number of cases (%)
Gender	
Male	94 (74.6)
Female	32 (25.4)
Age (yrs)	
Mean $\pm$ SD*	57.4 $\pm$ 10.5
Tumor size (cm)	
Mean $\pm$ SD*	5.3 $\pm$ 2.7
Fuhrman nuclear grade	
1	15 (11.9)
2	57 (45.2)
3	42 (33.4)
4	12 (9.5)
TNM stage	
I	87 (69.0)
II	13 (10.3)
III	22 (17.5)
IV	4 (3.2)
Recurrence	
Present	9 (7.1)
Absent	103 (81.7)
Health status	
Alive	111 (88.1)
Died	12 (9.5)

\*SD: standard deviation.



**Fig. 1.** Immunohistochemistry of VEGFR1 in clear cell renal cell carcinoma.



**Fig. 2.** Expression level of VEGFR-1 in CCRCC associated with tumor grade. (A) Representative immunoblotting of VEGFR-1. Expression level of VEGFR-1 in paired tissues of normal tissue (N) and tumor tissue (T), including low and high grades, were analyzed with immunoblotting.  $\beta$ -actin served as a protein loading control. (B) Relative expression of VEGFR-1 in non-tumor and tumor tissues. (mean  $\pm$  SEM, n = 6). (C) Relative expression of VEGFR-1 in low and high grade tumor tissues. (mean  $\pm$  SEM, n = 6).

In paired fresh tissues, VEGFR-1 was expressed in both CCRCC and normal renal parenchymal tissue (Fig. 2A). We found a significant reduction of VEGFR-1 in tumor tissue compared to non-tumor tissue (Fig. 2B). In addition, the expression level of VEGFR-1 was significantly elevated in low grade tumors compared to high grade tumors (Fig. 2C).

By immunohistochemistry, VEGFR-1 was positive in 56.9% of cases with a low (1+2) Fuhrman nuclear grade and in 33.3% of cases with a high (3+4) Fuhrman nuclear grade, which was statistically significant ( $p = 0.009$ ). Furthermore, VEGFR-1 was positive in 49.6% of cases without renal pelvis invasion and in 11.1% of cases with renal pelvis invasion. This difference in VEGFR-1 expression was statistically significant ( $p = 0.036$ ). With respect to the rhabdoid component, VEGFR-1 positivity was seen in 49.1% of cases without the rhabdoid feature and in 20% of cases with the rhabdoid feature, but the difference was not significant. Although VEGFR-1 expression seems to be higher in cases without the sarcomatoid feature, tumor necrosis, perirenal fat, renal sinus fat, and vascular invasion, and is lower in cases with cystic change, these differences were not statistically significant. Moreover, 50% of cases with pathologic T stage 1 were VEGFR-1 positive, as were 38.9% of cases with pathologic T stage 2-4 cases, which was not significant. VEGFR-1 was expressed in 50.6% of cases with TNM stage I and in 38.5% of cases with TNM stages II-IV. VEGFR-1 expression seemed to be higher in low TNM stage tumors compared to high TNM stage tumors, although this was not

a statistically significant finding (Table 2).

The mean staining score of each group was also compared in IHC assays. A statistically significant difference was observed between the mean staining scores of low and high Fuhrman nuclear grades ( $2.63 \pm 2.18$  vs.  $1.56 \pm 2.04$ ) ( $p=0.006$ ). For renal pelvis invasion, the mean staining score was  $2.26 \pm 2.20$  in cases without renal pelvis invasion and  $0.89 \pm 1.45$  in cases with renal pelvis invasion, but the difference was not significant. Although the mean staining score of VEGFR-1 seems to be higher in cases without the sarcomatoid or rhabdoid features, tumor necrosis, perirenal fat, renal sinus fat, and vascular invasion, and lower in cases with cystic change, the differences were not statistically significant. With respect to pathologic T stage, the mean staining score was  $2.36 \pm 2.18$  in cases of stage 1 and  $1.69 \pm 2.12$  in cases of stages 2-4. Although higher VEGFR-1 expression was correlated with a lower pathologic T stage, this was not significant. Furthermore, the mean staining score of VEGFR-1 was  $2.38 \pm 2.21$  and  $1.69 \pm 2.07$  in cases of TNM stage I and TNM stages II-IV, respectively. The difference was not statistically significant (Table 3). However, there was no significant difference of survival and recurrence rate between VEGFR-1 positive and negative groups ( $p=0.180$  and  $p=0.372$ , respectively).

## DISCUSSION

There are several well-known prognostic factors, which

**Table 2.** Correlation of VEGFR-1 expression and clinicopathological parameters of clear cell renal cell carcinoma (CCRCC)

Parameters	VEGFR-1 expression		p-value
	No. of positive cases (%)	No. of negative cases (%)	
Sarcomatoid feature			
Absent	57 (47.5)	63 (52.5)	0.402
Present	2 (33.3)	4 (66.7)	
Tumor necrosis			
Absent	49 (49.0)	51 (51.0)	0.337
Present	10 (38.5)	16 (61.5)	
Rhabdoid feature			
Absent	57 (49.1)	59 (50.9)	0.072
Present	2 (20.0)	8 (80.0)	
Fuhrman nuclear grade			
Low (1+2)	41 (56.9)	31 (43.1)	0.009
High (3+4)	18 (33.3)	36 (66.7)	
Perirenal fat invasion			
Absent	53 (48.2)	57 (51.8)	0.424
Present	6 (37.5)	10 (62.5)	
Renal pelvis invasion			
Absent	58 (49.6)	59 (50.4)	0.036
Present	1 (11.1)	8 (88.9)	
Vascular invasion			
Absent	53 (47.3)	59 (52.7)	0.752
Present	6 (42.9)	8 (57.1)	
Renal sinus fat invasion			
Absent	57 (47.1)	64 (52.9)	0.560
Present	2 (40.0)	3 (60.0)	
Cystic change			
Present	18 (52.9)	16 (47.1)	0.403
Absent	41 (44.6)	51 (55.4)	
Pathologic T stage			
1	45 (50.0)	45 (50.0)	0.176
2-4	14 (38.9)	22 (61.1)	
TNM stage			
I	44 (50.6)	43 (49.4)	0.143
II-IV	15 (38.5)	24 (61.5)	

$\chi^2$  test.

can be used to predict the prognosis of RCC. The Fuhrman nuclear grading system is an example of an important prognostic factor and is divided into grades 1 to 4 [18]. Another reliable prognostic factor is the TNM staging system, which takes into account tumor size and the extent of the tumor [17]. Other pathologic factors that give poor prognosis include the presence of tumor necrosis, sarcomatoid and rhabdoid features, vascular, perirenal fat, renal pelvis, and renal sinus fat invasions [20]. In contrast, the presence of cystic change in CCRCC is known to be a favorable prognostic factor [21].

**Table 3.** Correlation of mean staining score of VEGFR-1 expression and the clinicopathological parameters of clear cell renal cell carcinoma (CCRCC)

Parameters	VEGFR-1 expression	
	Mean $\pm$ SD*	p-value
Sarcomatoid feature		
Absent	2.21 $\pm$ 2.20	0.339
Present	1.33 $\pm$ 1.51	
Tumor necrosis		
Absent	2.30 $\pm$ 2.20	0.179
Present	1.65 $\pm$ 2.08	
Rhabdoid feature		
Absent	2.26 $\pm$ 2.21	0.107
Present	1.10 $\pm$ 1.52	
Fuhrman nuclear grade		
Low (1+2)	2.63 $\pm$ 2.18	0.006
High (3+4)	1.56 $\pm$ 2.04	
Perirenal fat invasion		
Absent	2.27 $\pm$ 2.19	0.153
Present	1.44 $\pm$ 2.03	
Renal pelvis invasion		
Absent	2.26 $\pm$ 2.20	0.068
Present	0.89 $\pm$ 1.45	
Vascular invasion		
Absent	2.28 $\pm$ 2.23	0.109
Present	1.29 $\pm$ 1.54	
Renal sinus fat invasion		
Absent	2.21 $\pm$ 2.19	0.313
Present	1.20 $\pm$ 1.64	
Cystic change		
Present	2.59 $\pm$ 2.41	0.188
Absent	2.01 $\pm$ 2.08	
Pathologic T stage		
1	2.36 $\pm$ 2.18	0.124
2-4	1.69 $\pm$ 2.12	
TNM stage		
I	2.38 $\pm$ 2.21	0.102
II-IV	1.69 $\pm$ 2.07	

Student's *t*-test. \*SD: standard deviation.

We found that VEGFR-1 expression was identified in the membrane and/or cytoplasm in 46.8% cases of CCRCC. Higher VEGFR-1 expression was significantly related to a lower Fuhrman nuclear grade and the absence of renal pelvis invasion. In addition, the results of Western blot analyses showed that expression of VEGFR-1 was significantly higher in adjacent normal tissue than in CCRCC tissue. Moreover, there was a significant difference in VEGFR-1 expression between low and high grade tumors. Therefore, we suggest that high VEGFR-1 expression may be asso-

ciated with favorable prognostic factors of CCRCC, although the results of survival analysis were not statistically significant. In particular, higher expression of VEGFR-1 is significantly correlated to lower Fuhrman nuclear grade tumors.

RCC is a malignant tumor that is characterized by high tumor vascularity and VEGF is the most important angiogenic factor. *VEGF* (also referred to as VEGFA) belongs to a gene family that consists of placental growth factor (*PLGF*), *VEGFB*, *VEGFC*, and *VEGFD* [22]. The *VEGF* gene is composed of eight exons and is differentially spliced to encode four major isoforms, including *VEGF<sub>121</sub>*, *VEGF<sub>165</sub>*, *VEGF<sub>189</sub>*, and *VEGF<sub>206</sub>* [23]. The importance of VEGF and VEGFR-1 in regulating tumor angiogenesis in CCRCC has been reported previously [15,16]. One study suggests that knockdown of VEGFR-1 impairs growth of CCRCC [14]. Ljungberg et al.[16] found that the *VEGF*, *VEGFR-1*, and *VEGFR-2 mRNA* levels were higher in tumors compared to the normal kidney cortex, which is contrary to our results. However, it has been suggested that VEGFR-1 may not be the primary receptor transmitting a mitogenic signal, but rather it is a ‘decoy’ receptor, able to negatively regulate the activity of VEGF on the vascular endothelium, preventing VEGF from binding to VEGFR-2 [24]. The functions and signaling properties of VEGFR-1 can be different depending on the developmental stage of the animal and the cell type [22].

HIF-1  $\alpha$  induces transcription of several factors such as VEGF/VEGFR [8]. Overexpression of HIF-1  $\alpha$  is associated with poor prognosis of cervical and breast cancers [25,26]. In contrast, elevated HIF-1  $\alpha$  expression is correlated with better survival in patients with CCRCC, although no association with tumor stage was found [27]. Furthermore, higher *VEGF mRNA* levels are associated with a better prognosis in CCRCC [16]. Similarly, our present study showed that higher VEGFR-1 expression may be correlated with favorable prognostic factors for CCRCC, including the Fuhrman nuclear grading system, which showed significant correlation. Further study is required to understand the underlying mechanism of VEGF/ VEGFR-1 signaling pathways in CCRCC.

In clinical practice, sorafenib, sunitinib, bevacizumab, temsirolimus, everolimus, pazopanib, and axitinib, drugs

which block the VEGF and mTOR pathways, are logical therapeutic targets for the treatment of metastatic RCC [13]. The development of these targeted agents has substantially improved the survival of patients with metastatic RCC to over 2 years [4]. Although tumor shrinkage is achieved to some extent in a large proportion of RCC patients, complete remissions are uncommon, and thus these treatments are not curative [13]. Therefore, better molecular markers should be studied and developed for the treatment of metastatic RCC.

In conclusion, this study examined VEGFR-1 expression in CCRCC, and its expression was compared to clinicopathological parameters and survival data. We demonstrated that higher VEGFR-1 expression may be correlated with favorable prognostic factors of CCRCC and significantly correlated with a lower Fuhrman nuclear grade.

## ACKNOWLEDGEMENTS

This research was supported by the Basic Science Research Program through the National Research Foundation of Korea (NRF) funded by the Ministry of Science, ICT & Future Planning (NRF-2012R1A1A1004233 to M.E.) and the Ministry of Education (NRF-2010-0024789 to S.-K.C). We would like to thank Mr. Joong Seob Kim and Mr. Tae-Young Kang for their technical support.

## REFERENCES

1. Jemal A, Siegel R, Xu J, Ward E. Cancer statistics, 2010. *CA Cancer J Clin* 2010;60:277-300.
2. Mathew A, Devesa SS, Fraumeni JF, Jr., Chow WH. Global increases in kidney cancer incidence, 1973-1992. *Eur J Cancer Prev* 2002;11:171-8.
3. Jung KW, Won YJ, Kong HJ, Oh CM, Seo HG, Lee JS. Cancer statistics in Korea: incidence, mortality, survival and prevalence in 2010. *Cancer Res Treat* 2013;45: 1-14.
4. Cho IC, Chung J. Current status of targeted therapy for advanced renal cell carcinoma. *Korean J Urol* 2012; 53:217-28.
5. Gnarr JR, Tory K, Weng Y, Schmidt L, Wei MH, Li H, Latif F, Liu S, Chen F, Duh FM, Lubensky I, Duan DR, Florence C, Pozzatti R, Walther MM, et al. Mutations of the VHL tumour suppressor gene in renal carcinoma. *Nat Genet* 1994;7:85-90.

6. Kondo K, Kaelin WG, Jr. The von Hippel-Lindau tumor suppressor gene. *Exp Cell Res* 2001;264:117-25.
7. Iliopoulos O, Levy AP, Jiang C, Kaelin WG, Jr., Goldberg MA. Negative regulation of hypoxia-inducible genes by the von Hippel-Lindau protein. *Proc Natl Acad Sci U S A* 1996;93:10595-9.
8. Gnarr JR, Zhou S, Merrill MJ, Wagner JR, Krumm A, Papavassiliou E, Oldfield EH, Klausner RD, Linehan WM. Post-transcriptional regulation of vascular endothelial growth factor mRNA by the product of the VHL tumor suppressor gene. *Proc Natl Acad Sci U S A* 1996;93:10589-94.
9. Kourembanas S, Hannan RL, Faller DV. Oxygen tension regulates the expression of the platelet-derived growth factor-B chain gene in human endothelial cells. *J Clin Invest* 1990;86:670-4.
10. Kuwabara K, Ogawa S, Matsumoto M, Koga S, Clauss M, Pinsky DJ, Lyn P, Leavy J, Witte L, Joseph-Silverstein J. Hypoxia-mediated induction of acidic/basic fibroblast growth factor and platelet-derived growth factor in mononuclear phagocytes stimulates growth of hypoxic endothelial cells. *Proc Natl Acad Sci U S A* 1995;92:4606-10.
11. de Paulsen N, Brychzy A, Fournier MC, Klausner RD, Gnarr JR, Pause A, Lee S. Role of transforming growth factor- $\alpha$  in von Hippel-Lindau (VHL)(-/-) clear cell renal carcinoma cell proliferation: a possible mechanism coupling VHL tumor suppressor inactivation and tumorigenesis. *Proc Natl Acad Sci U S A* 2001;98:1387-92.
12. Dvorak HF. Vascular permeability factor/vascular endothelial growth factor: a critical cytokine in tumor angiogenesis and a potential target for diagnosis and therapy. *J Clin Oncol* 2002;20:4368-80.
13. Voss MH, Hsieh JJ, Motzer RJ. Novel approaches targeting the vascular endothelial growth factor axis in renal cell carcinoma. *Cancer J* 2013;19:299-306.
14. Li C, Liu B, Dai Z, Tao Y. Knockdown of VEGF receptor-1 (VEGFR-1) impairs macrophage infiltration, angiogenesis and growth of clear cell renal cell carcinoma (CRCC). *Cancer Biol Ther* 2011;12:872-80.
15. Tomisawa M, Tokunaga T, Oshika Y, Tsuchida T, Fukushima Y, Sato H, Kijima H, Yamazaki H, Ueyama Y, Tamaoki N, Nakamura M. Expression pattern of vascular endothelial growth factor isoform is closely correlated with tumour stage and vascularisation in renal cell carcinoma. *Eur J Cancer* 1999;35:133-7.
16. Ljungberg BJ, Jacobsen J, Rudolfsson SH, Lindh G, Grankvist K, Rasmuson T. Different vascular endothelial growth factor (VEGF), VEGF-receptor 1 and -2 mRNA expression profiles between clear cell and papillary renal cell carcinoma. *BJU Int* 2006;98:661-7.
17. Edge SB. AJCC cancer staging manual. (7th ed). Springer; New York; London. 2010.
18. Fuhrman SA, Lasky LC, Limas C. Prognostic significance of morphologic parameters in renal cell carcinoma. *Am J Surg Pathol* 1982;6:655-63.
19. Allred DC, Harvey JM, Berardo M, Clark GM. Prognostic and predictive factors in breast cancer by immunohistochemical analysis. *Mod Pathol* 1998;11:155-68.
20. Ljungberg B, Cowan NC, Hanbury DC, Hora M, Kuczyk MA, Merseburger AS, Patard JJ, Mulders PF, Sinescu IC. EAU guidelines on renal cell carcinoma: the 2010 update. *Eur Urol* 2010;58:398-406.
21. Park HS, Jung EJ, Myung JK, Moon KC. The Prognostic Implications of Cystic Change in Clear Cell Renal Cell Carcinoma. *Korean J Pathol* 2010;44:149-54.
22. Ferrara N, Gerber HP, LeCouter J. The biology of VEGF and its receptors. *Nat Med* 2003;9:669-76.
23. Tischer E, Mitchell R, Hartman T, Silva M, Gospodarowicz D, Fiddes JC, Abraham JA. The human gene for vascular endothelial growth factor. Multiple protein forms are encoded through alternative exon splicing. *J Biol Chem* 1991;266:11947-54.
24. Park JE, Chen HH, Winer J, Houck KA, Ferrara N. Placenta growth factor. Potentiation of vascular endothelial growth factor bioactivity, in vitro and in vivo, and high affinity binding to Flt-1 but not to Flk-1/KDR. *J Biol Chem* 1994;269:25646-54.
25. Birner P, Schindl M, Obermair A, Plank C, Breitenecker G, Oberhuber G. Overexpression of hypoxia-inducible factor 1 $\alpha$  is a marker for an unfavorable prognosis in early-stage invasive cervical cancer. *Cancer Res* 2000;60:4693-6.
26. Schindl M, Schoppmann SF, Samonigg H, Hausmaninger H, Kwasny W, Gnant M, Jakesz R, Kubista E, Birner P, Oberhuber G. Overexpression of hypoxia-inducible factor 1 $\alpha$  is associated with an unfavorable prognosis in lymph node-positive breast cancer. *Clin Cancer Res* 2002;8:1831-7.
27. Lidgren A, Hedberg Y, Grankvist K, Rasmuson T, Vasko J, Ljungberg B. The expression of hypoxia-inducible factor 1 $\alpha$  is a favorable independent prognostic factor in renal cell carcinoma. *Clin Cancer Res* 2005;11:1129-35.