

# Arthroscopic Single-Portal Subscapularis Tendon Repair



Jae S. You, M.D., Emily J. Monroe, M.D., James M. Friedman, M.D., Brian T. Feeley, M.D., Drew A. Lansdown, M.D., Alan L. Zhang, M.D., and C. Benjamin Ma, M.D.

**Abstract:** Tears of the subscapularis tendon can be challenging to diagnose and treat. Because the subscapularis plays an important role in shoulder function, careful arthroscopic evaluation and treatment are necessary to restore function. Previous surgical techniques have ranged from full open repairs to complex arthroscopic procedures needing suture passer and/or retriever devices. We describe an arthroscopic surgical technique of subscapularis repair through a single anterior portal using only penetrating graspers. This approach can be used for partial upper-border subscapularis tears, as well as complete and retracted subscapularis tendon tears.

The subscapularis is labeled the forgotten rotator cuff tendon because of the sparseness of the literature on repairs of the subscapularis compared with the supraspinatus and infraspinatus. However, the subscapularis plays an important role as the only anterior rotator cuff muscle. It is the largest muscle, originating on the anterior surface of the scapula and converging as a single robust tendon on the lesser tuberosity.<sup>1,2</sup> The subscapularis internally rotates the humerus and functions as the anterior component of the glenohumeral joint transverse force couple.<sup>3</sup>

Tears of the subscapularis frequently occur in combination with other rotator cuff tendon tears and commonly present as partial articular-sided tears involving the superior third of the tendon.<sup>4</sup> The unique characteristics of the torn subscapularis make arthroscopic repair more challenging. These factors include a limited subcoracoid working space, which makes visualization and instrument manipulation difficult. Furthermore, close proximity to neurovascular structures can make mobilization of adhered and retracted tears demanding.

Diagnosis, likewise, can be challenging. Subscapularis tears typically present as anterior shoulder pain. Weakness in shoulder internal rotation is inconsistently found, given that several other muscles can contribute to internal rotation of the humerus, in addition to the large size of the subscapularis. Of the many named tests for subscapularis insufficiency, the bear-hug test has been found to be the most sensitive physical examination maneuver.<sup>5</sup> However, up to 40% of patients with arthroscopically diagnosed tears present with normal physical examination findings. Furthermore, as few as 31% of tears are correctly identified at the time of preoperative magnetic resonance imaging.<sup>5,6</sup> Thus, a thorough arthroscopic evaluation is paramount to identifying and treating subscapularis tendon injuries. However, there is disparity in the evaluation and treatment of subscapularis tendon tears, with poor to moderate interobserver and intraobserver agreement on the classification of tears and on whether to repair the tendon.<sup>7</sup>

All-arthroscopic subscapularis results were first reported by Burkhart and Tehrany<sup>8</sup> in 2002, with a 5-year median follow-up study showing good to

*From the Department of Orthopaedic Surgery, University of California San Francisco, San Francisco, California, U.S.A. (J.S.Y., J.M.F., B.T.F., D.A.L., A.L.Z., C.B.M.); and Heartland Orthopedic Specialist, Alexandria, Minnesota, U.S.A. (E.J.M.).*

*The authors report the following potential conflicts of interest or sources of funding: B.T.F. reports that he is Associate Editor for Journal of Shoulder and Elbow Surgery and receives research funding through the National Institutes of Health. D.A.L. receives fellowship-related research/educational support from Arthrex and Smith & Nephew, outside the submitted work. A.L.Z. is a paid consultant for Stryker, outside the submitted work. C.B.M. receives research support from Anika, Histogenics, Samumed, and Zimmer; is a paid consultant for ConMed Linvatec, Histogenics, Medacta, Stryker, and Tornier; and receives publishing royalties from SLACK, outside the submitted work. Full ICMJE author disclosure forms are available for this article online, as [supplementary material](#).*

*Received March 20, 2020; accepted June 5, 2020.*

*Address correspondence to C. Benjamin Ma, M.D., Department of Orthopaedic Surgery, University of California San Francisco, 1500 Owens St, Box 3004, San Francisco, CA 94158, U.S.A. E-mail: [maben@ucsf.edu](mailto:maben@ucsf.edu)*

© 2020 by the Arthroscopy Association of North America. Published by Elsevier. This is an open access article under the CC BY-NC-ND license (<http://creativecommons.org/licenses/by-nc-nd/4.0/>).

2212-6287/20402

<https://doi.org/10.1016/j.eats.2020.06.005>

**Table 1.** Equipment Required

|   |
|---|
| 30° Arthroscope (70° Arthroscope Available)                 |
| Angled penetrator (BirdBeak; Arthrex)                       |
| Double-loaded all-suture anchor (No. 2 Y-Knot RC; ConMed)   |
| 8.25-mm × 7-mm cannula (Arthrex)                            |
| Radiofrequency ablation device (ArthroCare; Smith & Nephew) |
| 18-gauge spinal needle                                      |
| Arthroscopic knot pusher                                    |
| Loop grasper  |

excellent results in 80% of patients.<sup>9</sup> Since then, multiple techniques have been reported, including both single- and double-row repairs using both knotless and knotted fixation. We present a technique using a single anterior portal using knotted suture fixation.

### Surgical Technique

With the patient positioned in the standard beach-chair position, diagnostic arthroscopy is performed with a 30° arthroscope through a standard posterior portal. In addition to standard shoulder arthroscopy instruments, a working cannula, an angled soft-tissue penetrator, and a double-loaded all-suture anchor are required (Table 1). A thorough and systematic examination is performed with careful attention to the supraspinatus, infraspinatus, subscapularis, and biceps tendon. The arm is placed in forward flexion and slight internal rotation to help expose the insertional anatomy of the subscapularis (Table 2). Careful inspection of the biceps along its intra-articular length is also performed to look for any subluxation or tendinosis because a subscapularis tear is frequently associated with biceps pathology. Treatment options for biceps instability include tenotomy and tenodesis. However, unless there is frank dislocation or marked tendinosis, we prefer to preserve the biceps because the subscapularis repair can help re-establish the biceps pulley and stabilize the long head of the biceps, given that outcomes of subscapularis repair do not appear to be different with surgical treatment of the biceps tendon.<sup>10</sup> When concomitant posterior-superior rotator cuff pathology is present, we typically address the subscapularis tear first.

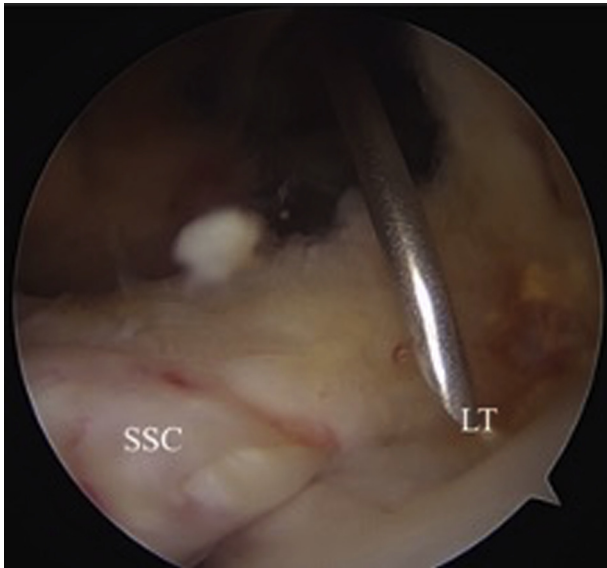
A standard mid-glenoid anterior portal is established, and an 8.25-mm × 7-mm cannula (Arthrex, Naples, FL) is inserted. Establishing this portal slightly inferior and medial will ensure the appropriate trajectory for suture passage through the subscapularis tendon. A rotator interval release is performed using a radiofrequency ablation device (ArthroCare; Smith & Nephew, Memphis, TN) and arthroscopic shaver. The release is carried under the coracoid, and the conjoint tendon is visualized (Table 2). Care is taken to avoid disruption of the superior glenohumeral ligament and biceps sling. Thorough debridement aids in visualization throughout the repair. The subcoracoid space is inspected for subcoracoid impingement, and if required (generally <6 mm of space available), a coracoplasty can be performed. A 70° arthroscope

can be used if additional visualization of the subscapularis footprint or subcoracoid space is required. Further release of adhesions anterior, superior, and posterior to the subscapularis tendon is performed to improve excursion of the tendon (Table 2).

The bare area of the lesser tuberosity is debrided and identified. A double-loaded all-suture anchor (No. 2 Y-Knot RC; ConMed, Utica, NY) is placed into the footprint percutaneously after outside-in spinal needle localization (Figs 1 and 2, Video 1, Table 2). A grasper is used to assess for excursion and reduction of the tendon. An angled penetrator (BirdBeak; Arthrex) is placed in the anterior cannula and used to penetrate the torn subscapularis tendon from outside in (Fig 3, Video 1). The first point of passage through the tendon should be placed distal and medial in the tendon (Table 2). A knot pusher is threaded percutaneously through the path of the suture anchor to deliver one of the suture limbs to the penetrator (Fig 4, Video 1). The penetrator is pulled back to complete passage of the suture through the tendon. This step is repeated with the other, corresponding suture to complete a mattress configuration (Fig 5, Video 1). The sutures are tensioned, and reduction of the tendon is assessed (Fig 6, Video 1). An arthroscopic square knot is tied while visualizing anatomic reduction and tensioning of the tendon, and the sutures are cut. The penetrator is once again passed through the anterior cannula and now used to penetrate the upper border of the tendon more proximally and laterally, and a knot pusher is used in similar fashion to percutaneously pass the appropriate suture (Fig 7, Video 1). The other limb of the suture is retrieved through the cannula using a loop grasper to complete a simple suture configuration for the superior stitch. An arthroscopic square knot is tied, and an arthroscopic probe is used to deliver the knot over the upper border of the tendon (Fig 8, Video 1). Anatomic repair can restore the biceps sling with reduction of the long head of the biceps tendon (Figs 9 and 10, Video 1). For larger tears, 2 double-loaded anchors may be used in this fashion,

**Table 2.** Pearls and Pitfalls

| Pearls  | Pitfalls   |
|---|--|
| Forward flex and internally rotate the arm to fully expose the insertional anatomy of the subscapularis | Inadequate placement of working portal                               |
| Maximize excursion with adequate rotator interval release and lysis of adhesions                        | Underappreciated tear extent and characteristics                     |
| Place all-suture anchor in the upper margin of the lesser tuberosity for adequate tension and reduction | Inadequate mobilization of subscapularis tendon                      |
| Pass sutures medial to the tear in good-quality tendon  | Compromise of tissue quality owing to repeated penetration of tendon |

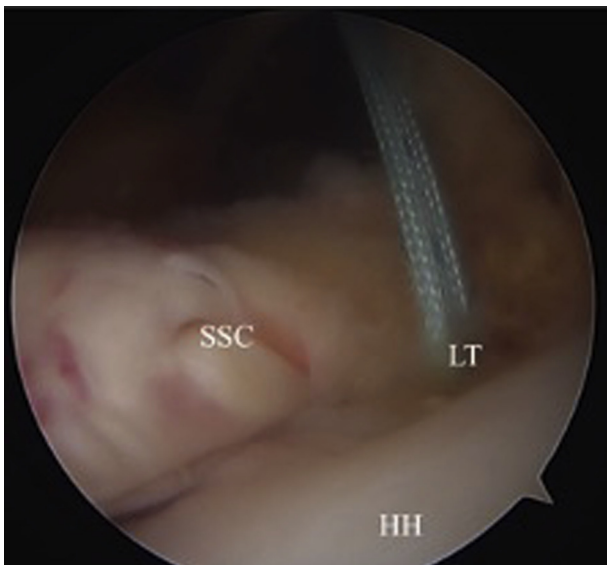


**Fig 1.** Right shoulder visualized from posterior portal with patient in beach-chair position and arm forward flexed and internally rotated. After rotator interval and 3-sided release of the subscapularis (SSC), the lesser tuberosity (LT) is exposed, and outside-in spinal needle localization is used for percutaneous anchor placement.

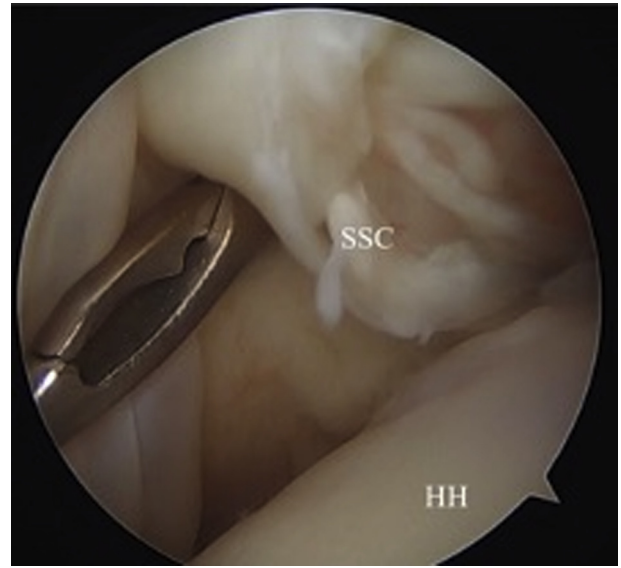
working from distal to proximal, with 2 mattress sutures placed inferiorly, followed by mattress and simple suture configurations more superiorly.

### Rehabilitation

After surgery, the patient is immobilized in a shoulder immobilizer sling for 6 weeks. Physical therapy is started at 1 week postoperatively. Phase 1 includes a focus on

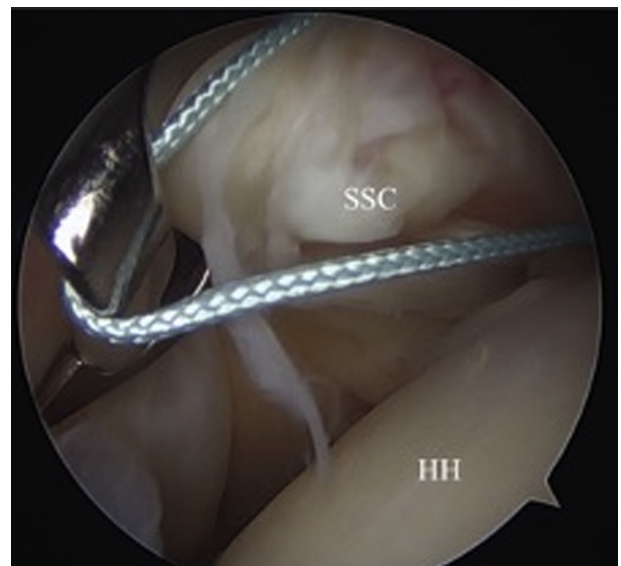


**Fig 2.** Right shoulder visualized from posterior portal with patient in beach-chair position. A double-loaded all-suture anchor is placed into the lesser tuberosity (LT). (HH, humeral head; SSC, subscapularis.)

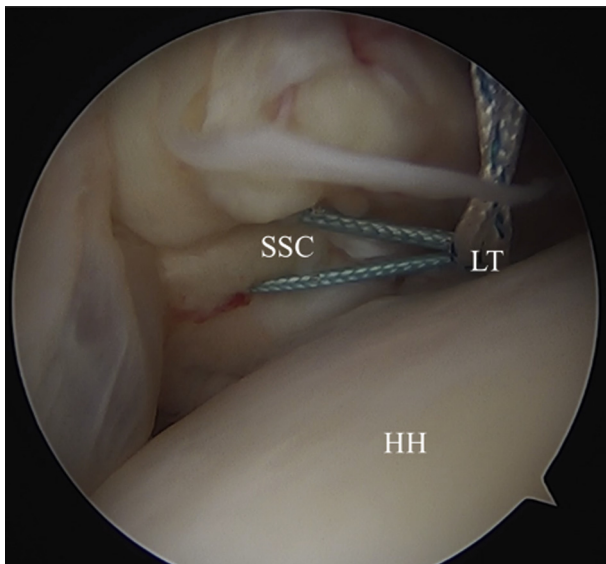


**Fig 3.** Right shoulder visualized from posterior portal with patient in beach-chair position. An angled penetrator (Bird-Beak) is used to penetrate the torn tendon from an anterior to posterior direction through the anterior portal. (HH, humeral head; SSC, subscapularis.)

maintaining passive motion while the tendon repair is healing. We advise limiting forward flexion to no more than 120° and external rotation to no more than 30° in general. The patient may perform pendulum exercises and scapular isokinetic exercises. At 6 weeks, the patient will transition out of the shoulder immobilizer and progress into phase 2. During this phase, range of

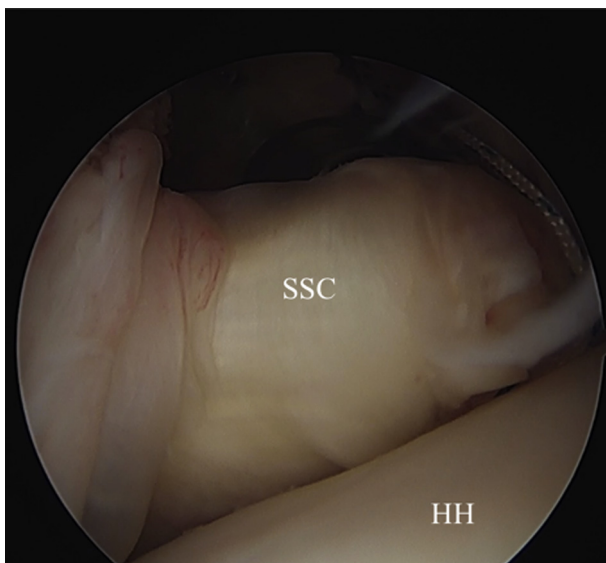


**Fig 4.** Right shoulder visualized from posterior portal with patient in beach-chair position. An arthroscopic knot pusher is threaded percutaneously in line with the suture anchor to deliver one of the suture limbs to the penetrator; the penetrator is pulled back to complete passage of the suture. (HH, humeral head; SSC, subscapularis.)

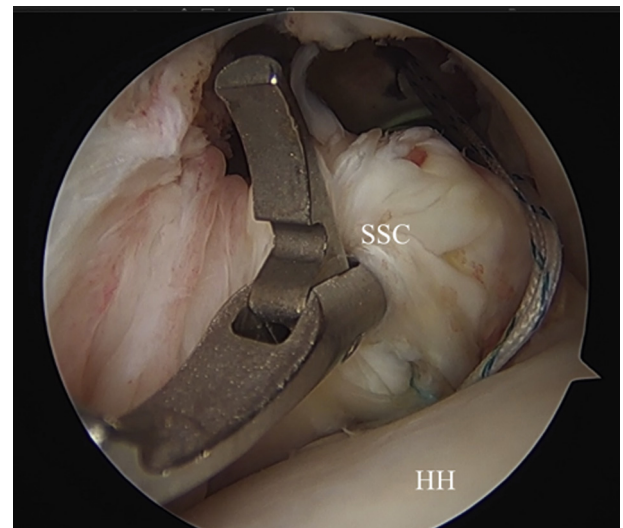


**Fig 5.** Right shoulder visualized from posterior portal with patient in beach-chair position. A penetrator is used to pass the other, corresponding suture to complete a mattress configuration. (HH, humeral head; LT, lesser tuberosity; SSC, subscapularis.)

motion progresses toward full motion, incorporating pulleys and isometric exercises. Phase 3 begins once the patient has recovered nearly full active range of motion and, in general, is targeted at 3 months after surgery. This phase includes advancing strengthening, including weight-based rotator cuff strengthening. Finally, at 6 months, with the return of normal strength, the patient may return to sports and other higher-level activities.



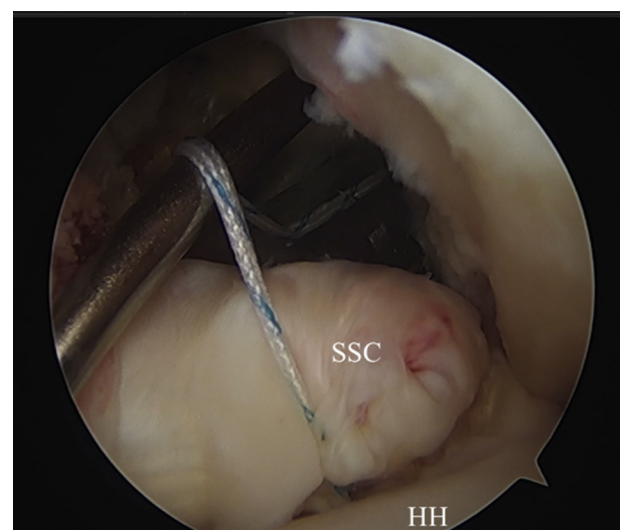
**Fig 6.** Right shoulder visualized from posterior portal with patient in beach-chair position. An arthroscopic square knot is tied to anatomically reduce the intact tendon to the lesser tuberosity. (HH, humeral head; SSC, subscapularis.)



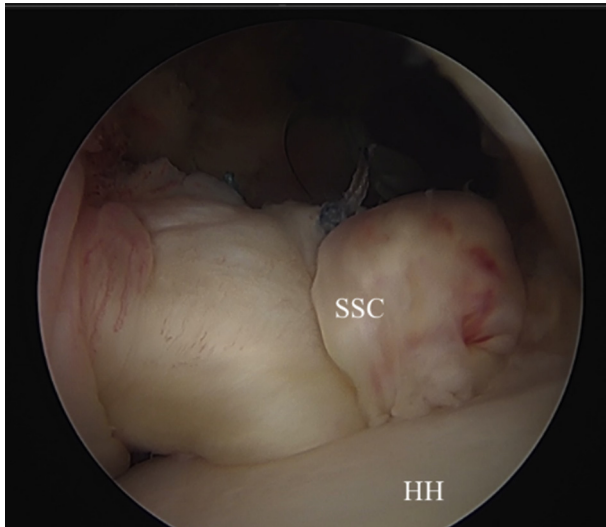
**Fig 7.** Right shoulder visualized from posterior portal with patient in beach-chair position. The penetrator is used to pass a suture through the upper border of the tendon and complete a simple suture configuration. (HH, humeral head; SSC, subscapularis.)

## Discussion

Many techniques for arthroscopic subscapularis repair have been described in the literature, with no current consensus on the ideal technique. Both arthroscopic and open repairs can result in improved function, decreased pain, and tendon healing, with no apparent difference in outcomes between the 2 techniques.<sup>11</sup> Lafosse et al.<sup>12</sup> reviewed their outcomes of isolated subscapularis tears repaired arthroscopically with a mattress suture inferiorly and medially and a simple suture used laterally over the footprint. Significant



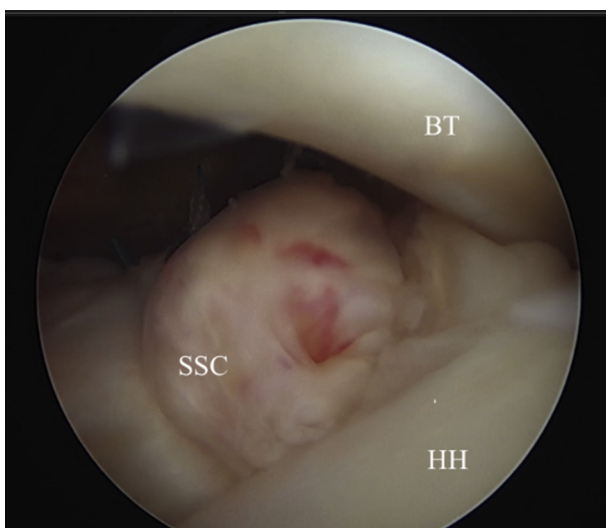
**Fig 8.** Right shoulder visualized from posterior portal with patient in beach-chair position. A probe is used to deliver the knot over the superior edge of the tendon. (HH, humeral head; SSC, subscapularis.)



**Fig 9.** Right shoulder visualized from posterior portal with patient in beach-chair position. Completed subscapularis (SSC) repair. (HH, humeral head.)

improvements in pain and in functional outcome scores, with complete healing on follow-up computed tomography arthrogram, were found in 88% of patients at a mean of 29 months' follow-up.

For full-thickness subscapularis tears, both single- and double-row repair techniques have been described. Biomechanical superiority and higher footprint coverage with double-row fixation in posterior-superior rotator cuff tears have been well documented in the literature.<sup>13</sup> However, there are no similar biomechanical studies of isolated subscapularis tears. There is also a lack of Level I clinical comparative studies, with lower-level studies showing no clinical difference between double- and



**Fig 10.** Right shoulder visualized from posterior portal with patient in beach-chair position. Restoration of biceps sling with reduction of biceps tendon (BT). (HH, humeral head; SSC, subscapularis.)

**Table 3.** Strengths and Limitations

Strengths

- Minimizes incisions and capsular disruption
- Requires simple equipment
- Enables small and precise anchor placement
- Tensions repair with arthroscopic knots

Limitations

- Relies on technically sound arthroscopic knots
- Single-row repair with potential for inferior biomechanical properties compared to double-row repair

single-row constructs. In a retrospective cohort study of arthroscopic subscapularis repairs, Yoon et al.<sup>14</sup> found no significant difference in shoulder outcome scores, range of motion, and retear rates between single- and double-row subscapularis repair groups at 2 years' follow-up.

Data regarding the role of rotator cuff muscle quality in the outcomes of subscapularis tendon repair are limited. Several studies on patients undergoing subscapularis tendon repair have suggested higher retear rates with fatty infiltration of the muscle.<sup>15,16</sup> However, worse subscapularis muscle quality with a higher preoperative grade of fatty infiltration has not been found to correlate with poorer clinical outcomes.<sup>16,17</sup> Our recent study found worse patient-reported outcomes in patients undergoing arthroscopic supraspinatus tendon repairs with poor infraspinatus muscle quality.<sup>18</sup>

Our technique is distinct in that it uses a single anterior portal without the need for complex instrumentation. All-suture anchors have the advantage of leaving a smaller footprint than their knotless counterparts, and the flexible nature of the implant enables introduction via a curved guide for easier placement at the anatomic footprint of the lesser tuberosity (Table 3). Fixation with knots permits greater tensioning maneuverability compared with knotless fixation. The flexibility of a double-loaded suture construct allows for greater spacing between sutures and the possibility of a double-mattress configuration, which results in higher footprint reconstruction, providing a larger contact area and a more uniform pressure distribution compared with a single-row knotless construct. Our technique further emphasizes reinforcing the superior portion of the tendon to provide support in the area that is most likely to be under strain and to ensure good contact between the tendon and footprint. Although there are no risks specific to this technique, repeated attempts to penetrate the tendon should be avoided because the tissue quality can be compromised (Table 2). Moreover, care should be taken during tendon mobilization to avoid damage to adjacent neurovascular structures.

We have previously reported on the clinical outcomes of this technique.<sup>10</sup> Our series comprised 145 patients with subscapularis repair either in isolation ( $n = 50$ ) or in combination with posterosuperior rotator cuff tears ( $n = 95$ ). The mean score on the Patient-Reported Outcomes Measurement Information System for Upper

Extremity (PROMIS-US) test at a minimum of 2 years after surgical treatment was 51.1, representing a value slightly above the expected population mean value of 50. No difference was noted in patients with or without surgical treatment of the biceps tendon (tenotomy or tenodesis compared with biceps preservation,  $P = .53$ ).<sup>10</sup>

In conclusion, we have presented a reproducible technique for arthroscopically repairing the subscapularis tendon through a single anterior portal with an all-suture anchor.

## References

- Clark JM, Harryman DT II. Tendons, ligaments, and capsule of the rotator cuff: Gross and microscopic anatomy. *J Bone Joint Surg Am* 1992;74:713-725.
- D'Addesi LL, Anbari A, Reish MW, Brahmabhatt S, Kelly JD. The subscapularis footprint: An anatomic study of the subscapularis tendon insertion. *Arthroscopy* 2006;22:937-940.
- Glousman R, Jobe F, Tibone J, Moynes D, Antonelli D, Perry J. Dynamic electromyographic analysis of the throwing shoulder with glenohumeral instability. *J Bone Joint Surg Am* 1988;70:220-226.
- Sakurai G, Ozaki J, Tomita Y, Kondo T, Tamai S. Incomplete tears of the subscapularis tendon associated with tears of the supraspinatus tendon: Cadaveric and clinical studies. *J Shoulder Elbow Surg* 1998;7:510-515.
- Barth JR, Burkhart SS, De Beer JF. The bear-hug test: A new and sensitive test for diagnosing a subscapularis tear. *Arthroscopy* 2006;22:1076-1084.
- Tung GA, Yoo DC, Levine SM, Brody JM, Green A. Subscapularis tendon tear: Primary and associated signs on MRI. *J Comput Assist Tomogr* 2001;25:417-424.
- Smucny M, Shin EC, Zhang AL, et al. Poor agreement on classification and treatment of subscapularis tendon tears. *Arthroscopy* 2016;32:246-251.
- Burkhart SS, Tehrany AM. Arthroscopic subscapularis tendon repair: Technique and preliminary results. *Arthroscopy* 2002;18:454-463.
- Adams CR, Schoolfield JD, Burkhart SS. The results of arthroscopic subscapularis tendon repairs. *Arthroscopy* 2008;24:1381-1389.
- Monroe EJ, Flores SE, Chambers CC, et al. Patient-reported outcomes after isolated and combined arthroscopic subscapularis tendon repairs. *Arthroscopy* 2019;35:1779-1984.
- Mall NA, Chahal J, Heard WM, et al. Outcomes of arthroscopic and open surgical repair of isolated subscapularis tendon tears. *Arthroscopy* 2012;28:1306-1314.
- Lafosse L, Jost B, Reiland Y, Audebert S, Toussaint B, Gobezie R. Structural integrity and clinical outcomes after arthroscopic repair of isolated subscapularis tears. *J Bone Joint Surg Am* 2007;89:1184-1193.
- Smith CD, Alexander S, Hill AM, et al. A biomechanical comparison of single and double-row fixation in arthroscopic rotator cuff repair. *J Bone Joint Surg Am* 2006;88:2425-2431.
- Yoon JS, Kim JS, Choi YR, Kim SH, Chun YM. Arthroscopic repair of the isolated subscapularis full-thickness tear: Single- versus double-row suture bridge technique. *Am J Sports Med* 2019;47:1427-1433.
- Lanz U, Fullick R, Bongiorno V, Saintmard B, Campens C, Lafosse L. Arthroscopic repair of large subscapularis tendon tears: 2- to 4-year clinical and radiographic outcomes. *Arthroscopy* 2013;29:1471-1478.
- Nove-Josserand L, Coln P, Godeneche A, et al. Ten-year clinical and anatomic follow-up after repair of anterosuperior rotator cuff tears: Influence of the subscapularis. *J Shoulder Elbow Surg* 2017;26:1826-1833.
- Edwards TB, Walch G, Sirveaux F, et al. Repair of tears of the subscapularis. *J Bone Joint Surg Am* 2005;87:725-730.
- Monroe EJ, Flores SE, Zhang AL, et al. Do outcomes of arthroscopic subscapularis tendon repairs depend on rotator cuff fatty infiltration? *Orthop J Sports Med* 2020;8:2325967120913036.