

Hysteroscopic Intrauterine Adhesiolysis Resulting in Positive Reproductive Outcome

Pooja Choudhary¹, Vinita Singh^{2*}

¹Department of Obstetrics and Gynaecology, Senior Consultant Apollo Cradle Royale, New Delhi, ²Department of Obstetrics and Gynecology, AIMS, Raipur, Chhattisgarh, India

Abstract

Intrauterine adhesions (IUA) following any less invasive uterine procedure like curettage or due to genital tuberculosis can lead to partial or complete dysfunction of the endometrium due to adhesions and uterine scarring with impairment of fertility and menstruation and also recurrent pregnancy loss. Therefore, hysteroscopic adhesiolysis was beneficial in this case in restoring fertility, and hence, the introduction of hysteroscopy has definitely improved the fertility outcome and positive reproductive outcome. This is a case report of a 28-year-old infertile woman with IUA leading to bilateral corneal block following dilatation and curettage who conceived after hysteroscopic adhesiolysis.

Keywords: Asherman syndrome, dilatation and curettage, hysteroscopic adhesiolysis, intrauterine adhesions

Intrauterine adhesions (IUA) following any invasive uterine procedure like curettage or following any genital infections like tuberculosis can lead to partial or complete dysfunction of the endometrium due to adhesions and uterine scarring with impairment of fertility and menstruation and also recurrent pregnancy loss.^[1-3] Gravid uterus is supposed to be more susceptible to such trauma. There are case reports where the presence of IUA is not associated with any symptoms in the patients so the term of Asherman syndrome (AS) should be used with caution.^[3] Hence, AS should be defined by the presence of adhesions inside uterine cavity and/or endocervix whereby derives one or more clinical manifestations such as amenorrhea, hypomenorrhea, recurrent pregnancy loss, infertility, and history of abnormal placentation.^[4] A 28-Year-old female, P2A2, presented to outpatient department with secondary infertility. She had previous two normal vaginal deliveries following spontaneous conception. Last child birth was 7 years back. In the next

5 years, it was followed by two spontaneous abortions for which dilatation and curettage were done in both the cases. She gave no significant history suggestive of any congenital anomalies in her genital tract or any ultrasound abnormalities featured in her previous sonography report and images done during her those uneventful pregnancies. There was no history of any contraception, operative intervention, or any genital tract infection during the antepartum, intrapartum, or postpartum period. The patient was sincerely trying to conceive for the last 2 years but was unable to conceive. Her menstrual cycles were regular with normal flow and showed no significant variation since menarche in amount, duration, or flow. She gave no significant past medical or surgical history and no history of any congenital anomalies of uterus in the family. As a routine protocol of infertility workup, both patient's and her husband's all required tests were done, but every report was within normal limits including ultrasonography report which

Article History:

Received 21 January 2019
Received in revised form 8 March 2019
Accepted 7 May 2019
Available online 24 October 2019

Access this article online

Quick Response Code:



Website:
www.e-gmit.com

DOI:
10.4103/GMIT.GMIT_126_18

Address for correspondence: Dr. Vinita Singh,
Department of Obstetrics and Gynecology, AIMS, Raipur,
Chhattisgarh, India.
E-mail: ddvinitasingh@gmail.com

This is an open access journal, and articles are distributed under the terms of the Creative Commons Attribution-NonCommercial-ShareAlike 4.0 License, which allows others to remix, tweak, and build upon the work non-commercially, as long as appropriate credit is given and the new creations are licensed under the identical terms.

For reprints contact: reprints@medknow.com

How to cite this article: Choudhary P, Singh V. Hysteroscopic intrauterine adhesiolysis resulting in positive reproductive outcome. *Gynecol Minim Invasive Ther* 2019;8:192-3.

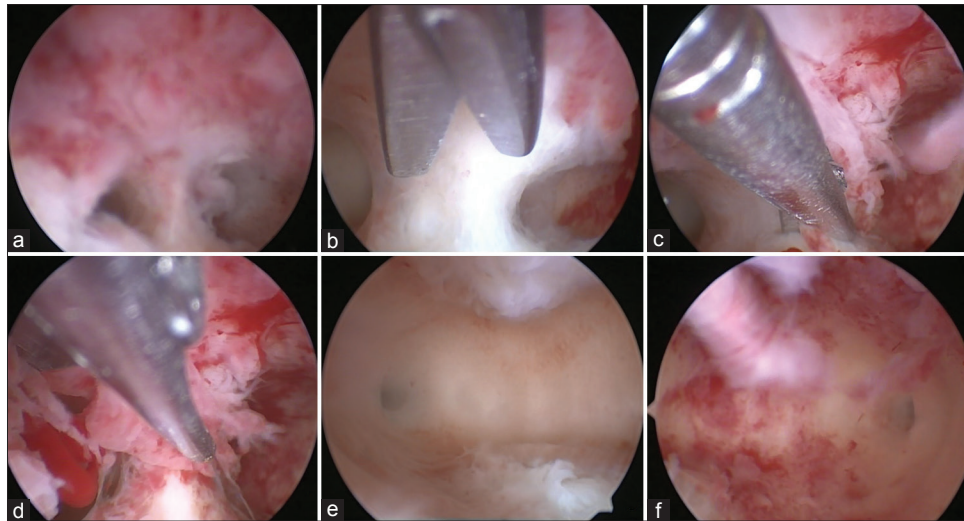


Figure 1: Step-by-step (a-f) illustration of hysteroscopic adhesiolysis. (a) Adhesion band. (b-d) Cutting of adhesion band. (e) Right cornua visualized. (f) Left cornua visualized

showed no significant finding. The patient had also undergone endometrial biopsy which showed no signs of any ovulatory dysfunction or any tubercular infection. The patient was then advised for hysterosalpingography which showed bilateral cornual block following which the patient was posted for diagnostic hysterolaparoscopy. On hysteroscopy [Figure 1a-f], a full-thickness adhesive band was seen running from anterior to posterior wall near to the fundus of the uterus encroaching upper one-third of the uterine cavity. Initially, both the cornua were not visualized. Hence, the adhesions were cut with the help of scissors under hysteroscopic guidance. Tubal patency was also checked, and bilateral spillage was present. Her postoperative period was uneventful, and the patient could conceive in the very next cycle and delivered a healthy male baby vaginally at term. Therefore, hysteroscopic adhesiolysis was beneficial in this case in restoring fertility. Introduction of hysteroscopy has definitely improved the fertility outcome and positive reproductive outcome.^[2,3,5] Recurrence rates of AS remain high, and we must continue to look for techniques which reduce the formation of new adhesions.

Ethical approval

The institute academic committee has given the ethical approval, and the approval no.12/IAC was obtained on 20th August in 2019.

Declaration of patient consent

The authors certify that they have obtained all appropriate patient consent forms. In the form the patient(s) has/have given his/her/their consent for his/her/their images and other clinical information to be reported in the journal. The patients understand that their names and initials will not be published and due efforts will be made to conceal their identity, but anonymity cannot be guaranteed.

Financial support and sponsorship

Nil.

Conflicts of interest

There are no conflicts of interest.

REFERENCES

1. Asherman JG. Traumatic intra-uterine adhesions. *J Obstet Gynaecol Br Emp* 1950;57:892-6.
2. Yu D, Wong YM, Cheong Y, Xia E, Li TC. Asherman syndrome – One century later. *Fertil Steril* 2008;89:759-79.
3. Deans R, Abbott J. Review of intrauterine adhesions. *J Minim Invasive Gynecol* 2010;17:555-69.
4. Conforti A, Alviggi C, Mollo A, De Placido G, Magos A. The management of Asherman syndrome: A review of literature. *Reprod Biol Endocrinol* 2013;11:118.
5. March CM. Management of Asherman's syndrome. *Reprod Biomed Online* 2011;23:63-76.