



ELSEVIER

Contents lists available at [ScienceDirect](https://www.sciencedirect.com)

# Trauma Case Reports

journal homepage: [www.elsevier.com/locate/tcr](http://www.elsevier.com/locate/tcr)

## Case Report

# Occult traumatic impaled foreign body, a challenging diagnosis of severe chronic lower extremity radicular pain

Michael Kartiko<sup>\*</sup>, Mounika Guduru, Tami Denotter, Fabio Villada

Creighton University School of Medicine Department of Radiology, 7710 Mercy Rd. Suite 502, Omaha, NE 68124, United States of America

## ARTICLE INFO

### Keywords:

Retained foreign body  
Occult foreign body  
Radicular pain  
Magnetic resonance  
Computed tomography  
Musculoskeletal

## ABSTRACT

The investigation of embedded soft tissue foreign bodies relies heavily on radiological imaging. The prompt identification of these objects is critical as retained foreign bodies may lead to serious infection or chronic debilitating pain depending on anatomical location. In this report, we present a case of a radiographically occult traumatically implanted foreign body in a 15-year-old female after a high-speed motor vehicle accident. Initial computed tomography (CT) scan was unremarkable and exploration under anesthesia demonstrated no other significant findings, yet the patient continued to suffer severe refractory radicular pain with marked limitation of daily function. It was not until 12 weeks after the accident that a magnetic resonance image (MRI) of the pelvis revealed a deep sinus tract with central low magnetic resonance (MR) signal, raising suspicion for a retained foreign body. A 10-centimeter plastic foreign body extending from the patient's coccyx to the sciatic foramen was identified and surgically removed resulting in immediate symptom relief. This case illustrates that the detection of a retained foreign body is not always straightforward and multiple imaging modalities may be necessary for accurate diagnosis. We also discuss the most appropriate diagnostic imaging algorithm when a foreign body of the musculoskeletal system is suspected.

## Case report

A 15-year-old female presented to the ED after a high-speed automobile accident where she was an unrestrained passenger. At initial presentation, her primary complaint was rectal-perineal pain. On physical exam, a perineal laceration was identified. Contrast CT of the abdomen, pelvis, and the lumbar spine were obtained and found to be unremarkable. The patient was subsequently taken to the operating room for exploratory surgery. In the O.R. the patient was placed in lithotomy position and the rectum was examined thoroughly with no evidence of rectal injury. Proctoscopy was performed to approximately 20 cm. On examination, the patient was found to have a right perirectal wound that was tracking upwards towards the sacrum posteriorly but never penetrating the rectal wall. No other injuries were identified. The area was irrigated and a drain was placed into the wound. The patient was then discharged on hospital day 3 with instructions to follow up with surgery. Over the next 3 months, the patient was treated with regular physical therapy and pain management. However, she continued to endorse severe pain with marked limitation of daily functioning, requiring increasing doses of opioids for pain management. A repeat CT pelvis without contrast and an MRI of the lumbar spine performed one month after the motor vehicle accident showed no abnormalities. The patient was subsequently referred to Physical Medicine and Rehabilitation to explore further treatment options. At this point in time, her perineal wound had completely healed without any

<sup>\*</sup> Corresponding author at: 7500 Mercy Rd, Omaha, NE 68124, United States of America.

E-mail address: [MichaelKartiko@creighton.edu](mailto:MichaelKartiko@creighton.edu) (M. Kartiko).

<https://doi.org/10.1016/j.tcr.2021.100514>

Accepted 1 August 2021

Available online 3 August 2021

2352-6440/© 2021 Published by Elsevier Ltd. This is an open access article under the CC BY-NC-ND license

(<http://creativecommons.org/licenses/by-nc-nd/4.0/>).

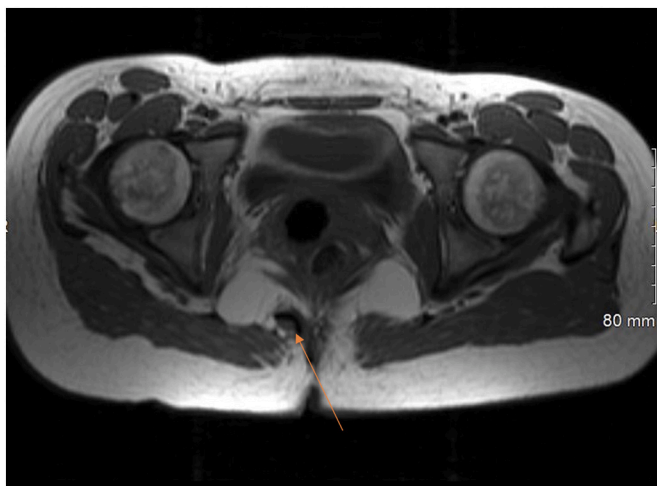


Fig. 1. Axial T1 inferior.

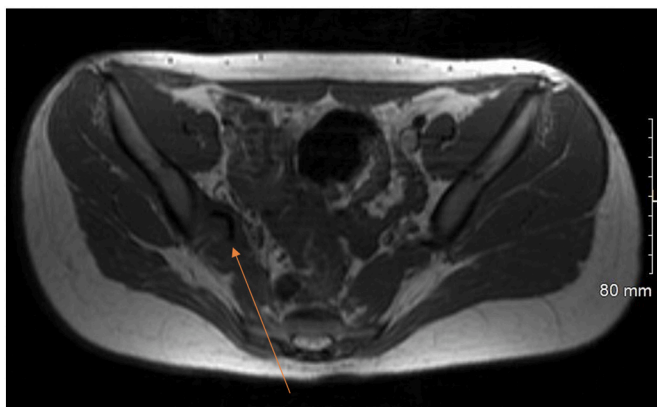


Fig. 2. Axial T1 superior.

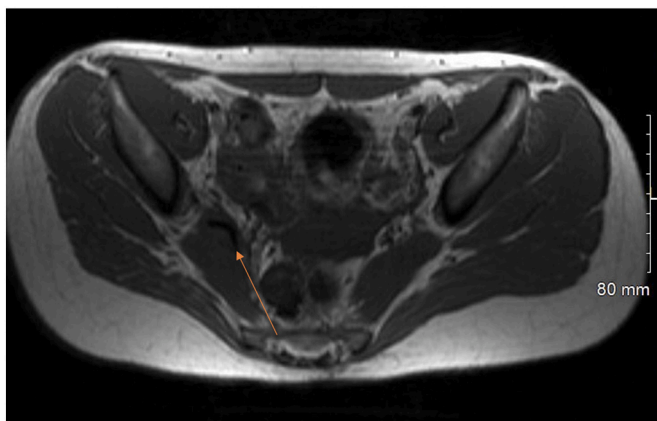


Fig. 3. Axial T1.

evidence of drainage, discharge, or infection. Despite this, any movement involving the coccyx would continue to elicit severe pain and paresthesias radiating into the right lower extremity. Physical examination of the right lower extremity was significant for hypertonicity of the hamstrings, weakness with both knee flexion and plantar flexion, allodynia of the right foot, and severe gait dysfunction

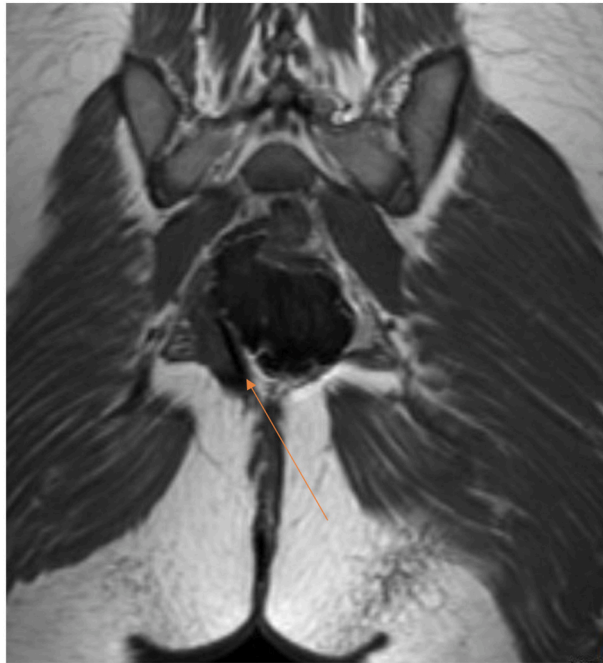


Fig. 4. Coronal T1 mid.

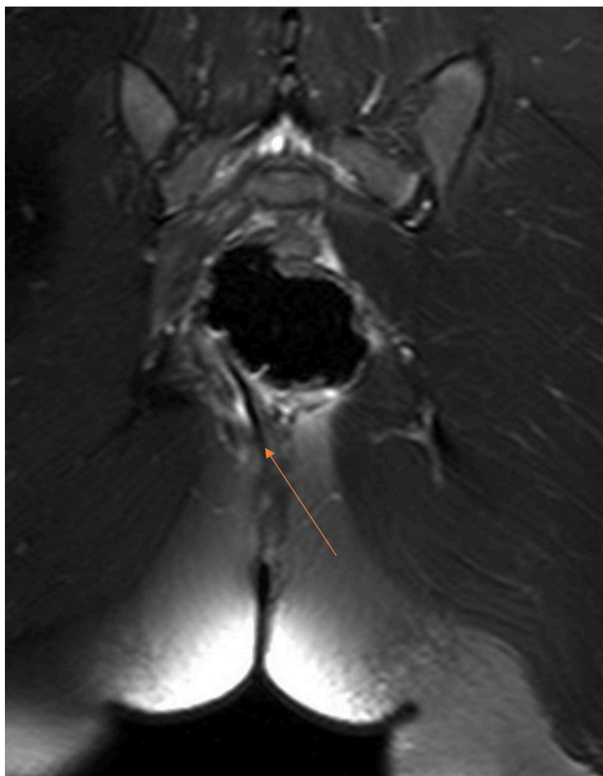


Fig. 5. Coronal T2 inferior.

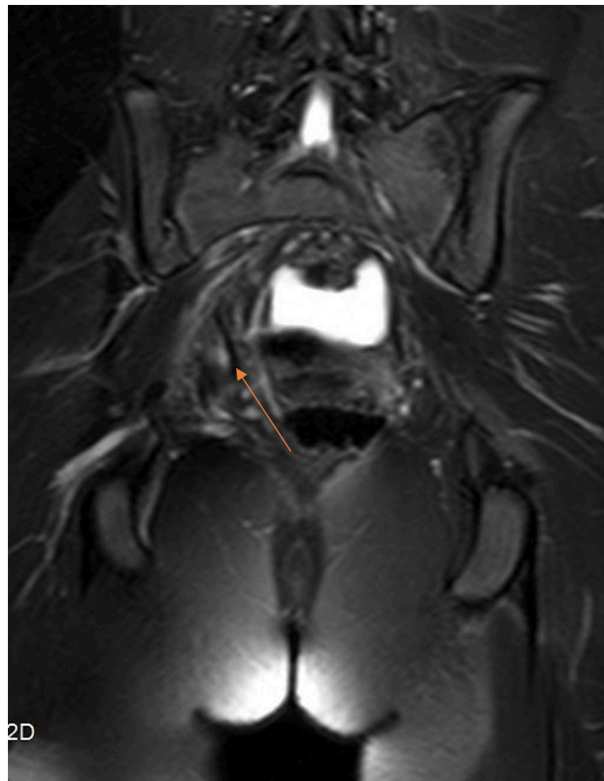


Fig. 6. Coronal T2 mid.

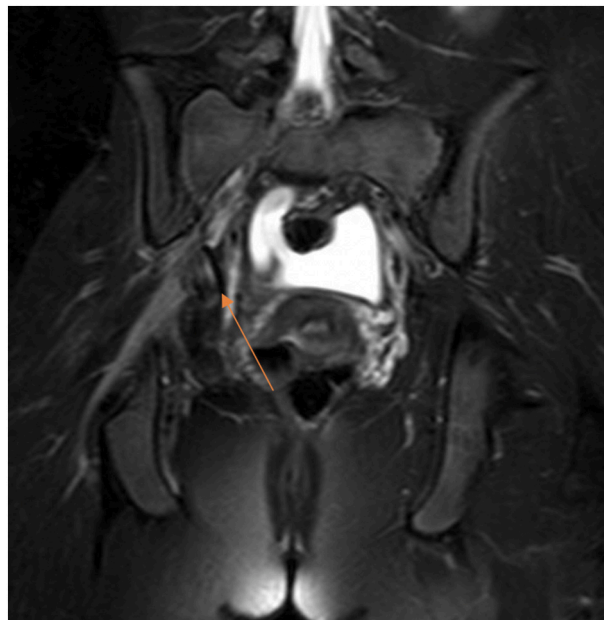


Fig. 7. Coronal T2 superior.

for which the patient required crutches. No muscle atrophy or skin changes were noted. Temperature and vascular exams were symmetric and unremarkable.

Twelve weeks after the accident, an MRI of the pelvis was obtained which revealed a deep sinus tract with a low signal intensity in

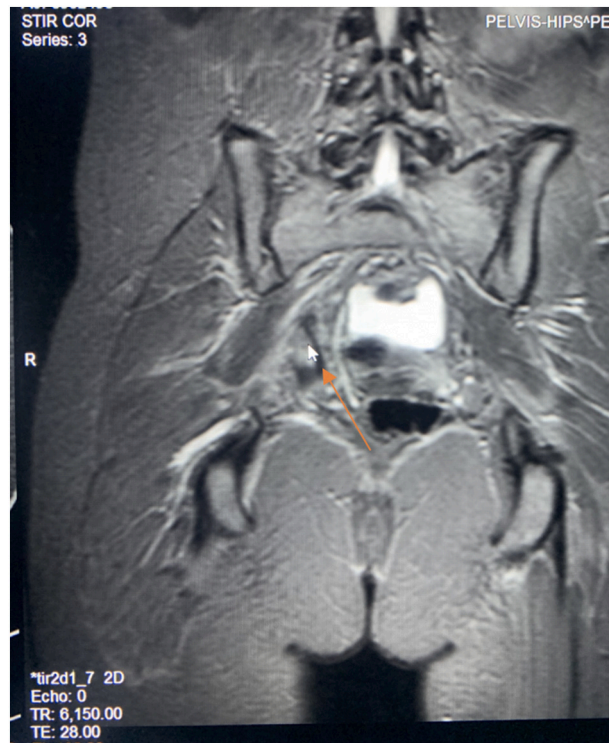


Fig. 8. Coronal T1.

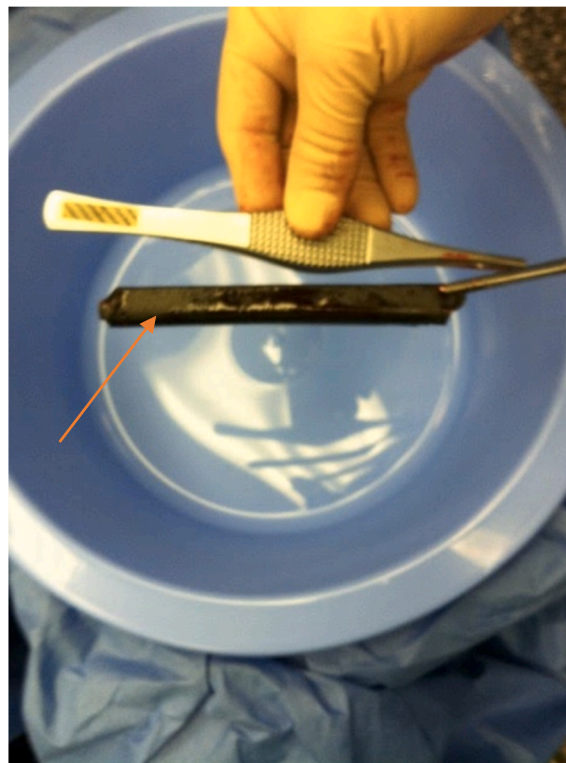


Fig. 9. A 10 cm plastic foreign body extracted from the patient 12 weeks after the motor vehicle accident.

T1 and T2 weighted image extending from the patient's coccyx to the right sciatic foramen (Figs. 1–8). The sinus tract coursed from the inferior tip of the coccyx ventral to the piriformis muscle and adjacent to the lumbosacral plexus. Contrast enhanced CT was obtained to further characterize this lesion. The scan demonstrated the absence of air or calcium within the lesion to account for the low MR signal, which elicited the differential of a retained foreign body. The patient was taken for repeat surgical exploration. A plastic foreign body of approximately 10 cm in length was explanted (Fig. 9). She reported remarkable pain improvement on postoperative day one. Over the following week, her dysesthesia symptoms regressed. With continued PT, she was able to resume walking without assistance.

## Discussion

The majority of foreign bodies are implanted as a result of trauma or accidental injury. Soft tissue foreign bodies from penetrating injuries are not an uncommon presentation in the emergency department [5]. Foreign bodies after a penetrating tissue injury may lead to a granulomatous reaction resulting in infection, tendinitis, synovitis, or neurovascular injury [6]. Early detection is crucial in order to minimize these complications. Most foreign bodies are found superficially and can be located with a thorough history and physical exam [5]. However, in the scenario that a foreign body is implanted deeper or not visible during wound exploration, imaging studies are necessary for localization [5]. This case illustrates an unusual presentation and protracted course of a traumatically implanted foreign body. It exemplifies that different diagnostic imaging modalities are best suited for the detection of a foreign body (FB) based on its composition and depth [1]. The detection of a FB is not always straightforward. Typically radiographs and CT are the preferred modalities for identifying gravel, glass, and metal. Sonography is typically used for visualization of superficial wood, plastic or cactus spine [2]. The radiologic evaluation of wooden FB is complex given the varied appearance of wood and changes within the wood [3]. Some types of plastic display very similar attenuation to soft tissue, making them nearly undetectable by CT when implanted in muscle [4]. Given the deep intramuscular location of this FB, MR imaging was needed to identify the large piece of implanted plastic. Radiologic imaging studies are complementary. What can be occult on one imaging modality can be readily seen on a different imaging modality, based on the composition and location of the foreign body. When a retained foreign body is suspected, radiography is a reasonable first test to screen for objects, but negative findings do not absolutely rule out presence of a foreign body [6]. If radiolucent objects such as thorns, wood, or plastic are suspected, sonography is a reasonable next choice. If no object is identified but clinical suspicion remains high, CT or MRI would be indicated [5,6]. It is important to remember that all post-traumatic wounds carry the potential for foreign bodies and the consequences of missing this can be severe for the patient [5]. A combination of high clinical suspicion, comprehensive physical exam, and selection of appropriate imaging modalities will provide optimal patient outcomes [5].

## Declaration of competing interest

None.

## References

- [1] A. Haghnegahdar, A. Shakibafard, N. Khosravifard, Comparison between computed tomography and ultrasonography in detecting foreign bodies regarding their composition and depth: an in vitro study, *J. Dent. (Shiraz)* 17 (3) (2016) 177–184. Sep.
- [2] D.E. Manthey, A.B. Storrow, J.M. Milbourn, B.J. Wagner, Ultrasound versus radiography in the detection of soft-tissue foreign bodies, *Ann. Emerg. Med.* 28 (1) (1996 Jul) 7–9.
- [3] T. Natung, W. Shullai, D. Lynser, T. Tripathy, A challenging case of a large intraorbital foreign body perforating the nasal septum in a child, *Indian J. Ophthalmol.* 66 (10) (2018 Oct) 1511–1513, [https://doi.org/10.4103/ijoo.IJO\\_150\\_18](https://doi.org/10.4103/ijoo.IJO_150_18).
- [4] C.R. Ingraham, L. Mannelli, J.D. Robinson, K.F. Linnau, Radiology of foreign bodies: how do we image them? *Emerg. Radiol.* 22 (4) (2015) 425–430, <https://doi.org/10.1007/s10140-015-1294-9>. Epub 2015 Feb 4.
- [5] E.A. Campbell, C.D. Wilbert, Foreign Body Imaging. SourceStat pearls [Internet], StatPearls Publishing, Treasure Island (FL), 2021. <https://www.ncbi.nlm.nih.gov/books/NBK470294/>.
- [6] M. Jarraya, D. Hayashi, R.V. De Villiers, et al., Multimodality imaging of foreign bodies of the musculoskeletal system, *Am. J. Roentgenol.* 203 (1) (2014) 92–102, <https://doi.org/10.2214/AJR.13.11743>.