World Neurosurgery: X 23 (2024) 100312

Contents lists available at ScienceDirect

World Neurosurgery: X

journal homepage: www.journals.elsevier.com/world-neurosurgery-x

Spinal calcifying pseudoneoplasms of the neuraxis: A case report and review of the literature

Ajay Chatrath [a,#], Mackenzie Lemieux [a,#], Rujvee P. Patel [a], Kaleigh F. Roberts [b], Sonika Dahiya [b], Brenton Pennicooke [a,*]

[a] Department of Neurosurgery, Washington University School of Medicine in St. Louis, MO, USA
[b] Department of Pathology & Immunology, Division of Neuropathology, Washington University School of Medicine in St. Louis, MO, USA

ARTICLE INFO

Keywords:
Calcifying pseudoneoplasms of the neuraxis (CAPNON)
Surgical excision
Central nervous system
Intradural extramedullary lesion
Pain and sensory symptoms
Pathognomonic imaging findings
Favorable surgical outcomes

ABSTRACT

Calcifying pseudoneoplasms of the neuraxis (CAPNON) are rare, non-neoplastic, slow-growing tumors that can present anywhere throughout the central nervous system. While the etiology of these lesions remains unknown, the mainstay of treatment is surgical excision. We describe a case of CAPNON at our institution in a 66 year-old female patient who presented with 5 months of pain and burning sensation in her thigh. On MRI, an intradural extramedullary lesion was identified at the level of T11-T12. The mass was surgically excised and the patient reported resolution of her symptoms by her six week follow-up appointment. We reviewed 79 spinal CAPNON cases, covering all cases reported in the literature thus far. In summary, we find that spinal CAPNON are most commonly lumbar and extradural in location, with pain as the most common presenting symptom. Lesions are well-defined and hypointense on T1 and T2 MRI sequence. The majority of cases had favorable surgical outcomes with near complete resolution of pain and associated symptoms.

1. Introduction

Calcifying pseudoneoplasms of the neuraxis (CAPNON), first pathologically described in 1978 by Rhodes and Davis, are rare, benign, calcified lesions that arise within the central nervous system (CNS). With less than 150 total reported cases, the epidemiology and pathogenesis of CAPNON is poorly understood. Given the rarity of these lesions, diagnosing CAPNON is difficult and little research is available to guide treatment decisions. Since CAPNON often mimic other more common CNS lesions on imaging, it is often misdiagnosed as meningioma, metastasis, hematoma, vascular malformations and even more rare occurrences like neurocysticercosis.

Beyond mimicking more common lesions on imaging, spinal CAPNON in particular may not be initially worked up as presenting symptoms caused by spinal CAPNON such as back pain or sciatica are not specific which can delay identification.[1,2,3,4,5] Other presentations of spinal CAPNON include radiculopathy, myelopathy, paraparesis, tetraparesis, and gait changes.[6,7] Given the non-specific presentations and imaging findings, a better understanding and characterization of CAPNON cases is important to inform medical and surgical decision making.

Despite frequent uncertainty in diagnoses, the majority of spinal CAPNON are treated surgically with favorable outcomes and often total relief of symptoms.[5] Definitive diagnosis of CAPNON often occurs after the lesion is resected and analyzed histologically. Common histologic findings associated with CAPNON are calcifications, palisading of histiocytes, multinucleated giant cells, fibrocellular stroma, positive immunohistochemical stain for EMA and Vimentin and negative stain for GFAP and S-100.[8–11,12,13] The granulomatous appearance on histology in addition to the good clinical outcomes, has led to the hypothesis that the pathogenesis of CAPNON is a reactive process as opposed to a neoplastic one.[1] However, the exact pathogenesis of CAPNON is unknown.

In this case report, we present a case of spinal CAPNON treated at our institution and review the literature to identify all cases of spinal CAPNON cases that have been published thus far to summarize the diagnosis and management of these cases.

2. Case report

BS was a 66 year old female with a history of hypertension, hypercholesterolemia, malnutrition, CKD, and depression who initially

* Corresponding author.
E-mail address: bpennicooke@wustl.edu (B. Pennicooke).
# These authors contributed equally to this work.

https://doi.org/10.1016/j.wnsx.2024.100312
Received 7 June 2023; Accepted 21 February 2024
Available online 24 February 2024

Abbreviations

CAPNON Calcifying pseudoneoplasms of the neuraxis
MRI – Magnetic Resonance Imaging
CNS – Central Nervous System
GFAP – Glial Fibrillary Acidic Protein
S-100 – Schwannian Marker protein soluble in saturated (100%) ammonium sulfate solution
CKD – Chronic Kidney Disease
NSAIDs – Non-Steroidal Anti Inflammatory Drugs
CT – Computed tomography
CD68 – Cluster of Differentiation 68
EMA – Epithelial Membrane Antigen

presented to an outside clinic with right anterior thigh pain in the L2-L3 distribution which began 5 months prior to her presentation to the clinic in March 2022. She had previously had pain 8 years ago that lasted 3 months and then resolved spontaneously. Her pain had been managed with NSAIDs and gabapentin. She was neurologically intact on exam. Her primary care physician ordered an MRI of the spine without contrast which demonstrated an intradural extramedullary mass on the right at the level of T11-T12. The patient was then referred to a neurosurgeon at an outside clinic. Upon retrospective review by the neurosurgeon of the patient's prior lumbar MRI performed 2 years ago due to low back pain, the lesion was present on her MRI performed 10 years ago, though the lesion had been slightly smaller at that time. The lesion was also apparent in retrospect on CT of the abdomen and pelvis ordered at the same time as the MRI which demonstrated a partially calcified intradural extramedullary mass on the right from T11-T12. The neurosurgeon at that time believed that the most likely diagnosis was a meningioma given the appearance of the lesion and its slow growth over the past decade. Neurofibroma and schwannoma were considered to be less likely diagnoses. The neurosurgeon discussed expectant management and surgical resection of the mass with the patient and the patient favored expectant management at that time.

Two years later, the neurosurgeon referred the patient to our institution for evaluation for resection of the lesion given the patient's worsening proximal leg pain and burning. The patient remained neurologically intact on our exam. CT of the thoracic spine and MRI of the spine with contrast was performed. CT of the thoracic spine demonstrated a calcified intradural lesion of the right aspect of the spinal cord at the level of T11-T12 that was up to 1.1 cm in length (Fig. 1). MRI of the thoracic spine with contrast demonstrated an intradural extramedullary calcified lesion at T11-T12 with nodular peripheral enhancement and mass effect on the spinal cord with associated dorsal spinal cord edema from T10-T12 (Fig. 2). The neuroradiologist at our institution believed that this finding was most likely consistent with meningioma given the slow growth of the lesion. The differential diagnosis at that time also included calcified vascular malformation or a calcified metastatic lesion. The patient ultimately elected for neurosurgical resection of the lesion following discussions of the risks and benefits of the procedure.

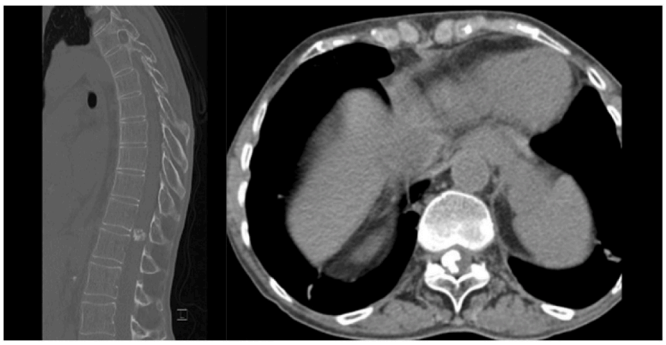

Fig. 1. Sagittal (A) and axial (B) sections of a pre-operative CT scan without contrast of the thoracic spine demonstrating a 1.1 × 0.9 × 1.1 cm calcified intradural lesion at T11-T12.

We elected to perform a posterior thoracic laminectomy from T11-T12 with resection of the intradural, extramedullary spinal tumor and placement of a lumbar drain. Intraoperative neural monitoring was used. Following the T11-T12 laminectomy, the tumor was easily visualized. The tumor was attached to the dura and was found to be highly calcified. The tumor was easily dissected from the spinal cord. The frozen specimen sent from the operating room came back as meningioma with extensive calcification. Motor evoked potentials and somatosensory-evoked potentials remained stable throughout the case. Inspection of the surgical site and ultrasound showed that the spinal cord was completely decompressed. In a patient who presented with myelomalacia resulting from a decade-long spinal cord compression, we opted for a 2-level laminectomy instead of a hemilaminectomy. This choice provided superior access for the resection of the pathology without requiring any significant retraction of the spinal cord. Additionally, it facilitated a more thorough spinal cord decompression, minimizing the risk of re-compression in the event of an incomplete resection of the CAPNON.

Postoperatively, the patient was neurologically intact at the time of discharge. Her proximal leg pain had almost entirely resolved. She continued to exhibit resolution of her right proximal anterior thigh pain at her follow-up appointment 6 weeks after the surgery. Final pathology demonstrated chondromyxoid matrix with fibrillary appearance, calcifications and ossification (osseous metaplasia), as well as reactive fibroconnective tissue on hematoxylin and eosin staining, overall most consistent with CAPNON (Fig. 3). Immunohistochemical staining demonstrated that the lesion was negative for progesterone receptor with only rare foci of epithelial membrane antigen (EMA) positivity favored to represent entrapped arachnoid cap cells. S100 was negative in the lesion. CD68 highlighted numerous histiocytes. Follow-up imaging 3 months later demonstrated T11 laminectomy for partial resection of a heterogeneously calcified mass with decreased mass effect on the spinal cord (Fig. 4).

3. Methods

3.1. Statistical analysis

All statistical analyses were performed using GraphPad Prism version 9.0.0 for macOS, GraphPad Prism Software, La Jolla California USA, www.graphpad.com. Fisher's exact test of independence was performed for 2x2 contingency tables and Pearson's Chi-square test was performed for contingency tables with greater than 2 rows. In all of our statistical analyses, we compared expected values based on the null hypothesis to actual values obtained through the literature review. Our expected values are based on the assumption that the number of patients in each group is equal, and thus the null hypothesis is no significant difference between groups. p values of <0.05 were regarded as significant.

4. Discussion

CAPNON is a rare benign calcified lesion first described intracranially in 1978[14]; subsequent reports have also described its spinal manifestation.[15] Here, we describe a spinal CAPNON case surgically treated at our institution, adding one more case to the stark CAPNON literature.

Our extensive review of spinal CAPNON cases has found that to date, including our patient case, there have been 80 instances of CAPNON reported in the spine (Table 1). In summarizing these cases, we find that CAPNON can occur across the lifespan, reportedly diagnosed in patients

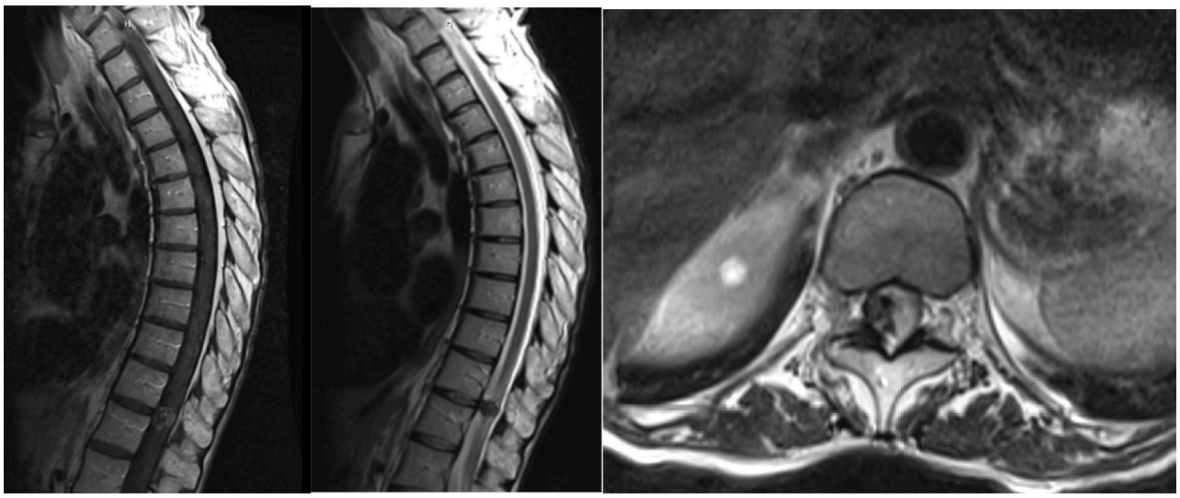

Fig. 2. Sagittal T1W (A), T2W (B) and axial T11-12 disc space (C) sections from a MRI of the thoracic spine with and without contrast demonstrating an intradural, extramedullary calcified lesion with peripheral nodular enhancement at T11-T12 with mass effect on the spinal cord.

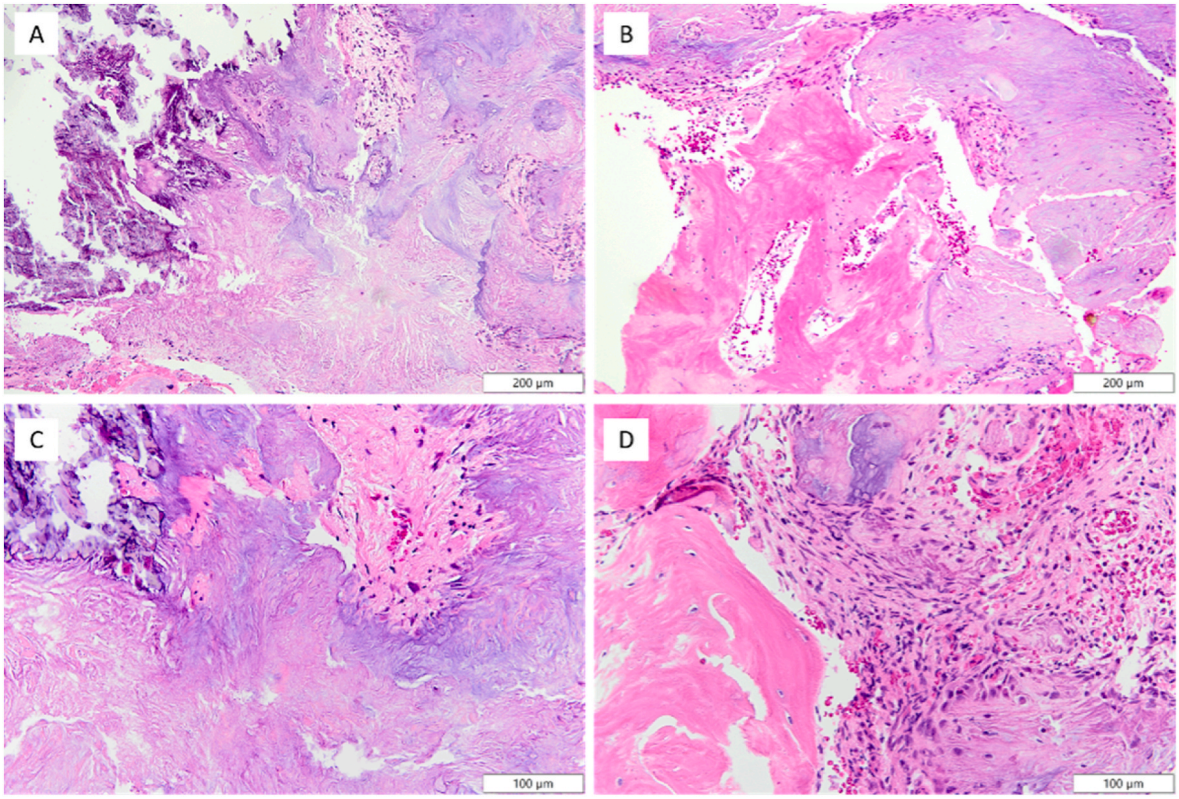

Fig. 3. Hematoxylin and eosin-stained formalin fixed paraffin embedded sections show abundant hypocellular basophilic amorphous to fibrillated material with ghost cells, consistent with the characteristic chondromyxoid fibrillary matrix of CAPNON. There are areas of coarse and amorphous calcifications (A and C) and osseous metaplasia (B and D). There is intervening reactive fibrous stroma with focal areas of palisading epithelioid cells with eccentric nuclei at the periphery of the chondromyxoid matrix (D).

from one to 90 years of age, with the majority (70.1%) occurring over the age of 49. Before a recent surge in spinal CAPNON cases reported in the literature between 2020 and 2022,[16,17,18,19] there was a male predominance in CAPNON.[6] With the most recent cases included, we find a female predominance in spinal CAPNON, with 55.7% female cases and 44.3% male cases ($p = 0.5264$).

Prior reports have shown that the majority of CAPNON are more likely to be extradural than intradural ($p = 0.0024$). Interestingly, our case is one of the few intradural extramedullary cases described. Only nine of the 80 described cases are intradural, and four, including this current case, report intradural extramedullary tumor location. Further, CAPNON were more likely to be located in the lumbar spine (51.9%) compared to cervical (20.2%) or thoracic (21.5%) ($p = 0.0336$). We found that CAPNON rarely localize to the most caudal and rostral ends of the spinal cord, with only one case in the sacral region and four cases in the upper clivus/foramen magnum region (Table 1).

Tumor location was related to clinical presentation as the patients suffered from pain or dysfunction in a dermatomal or myotomal

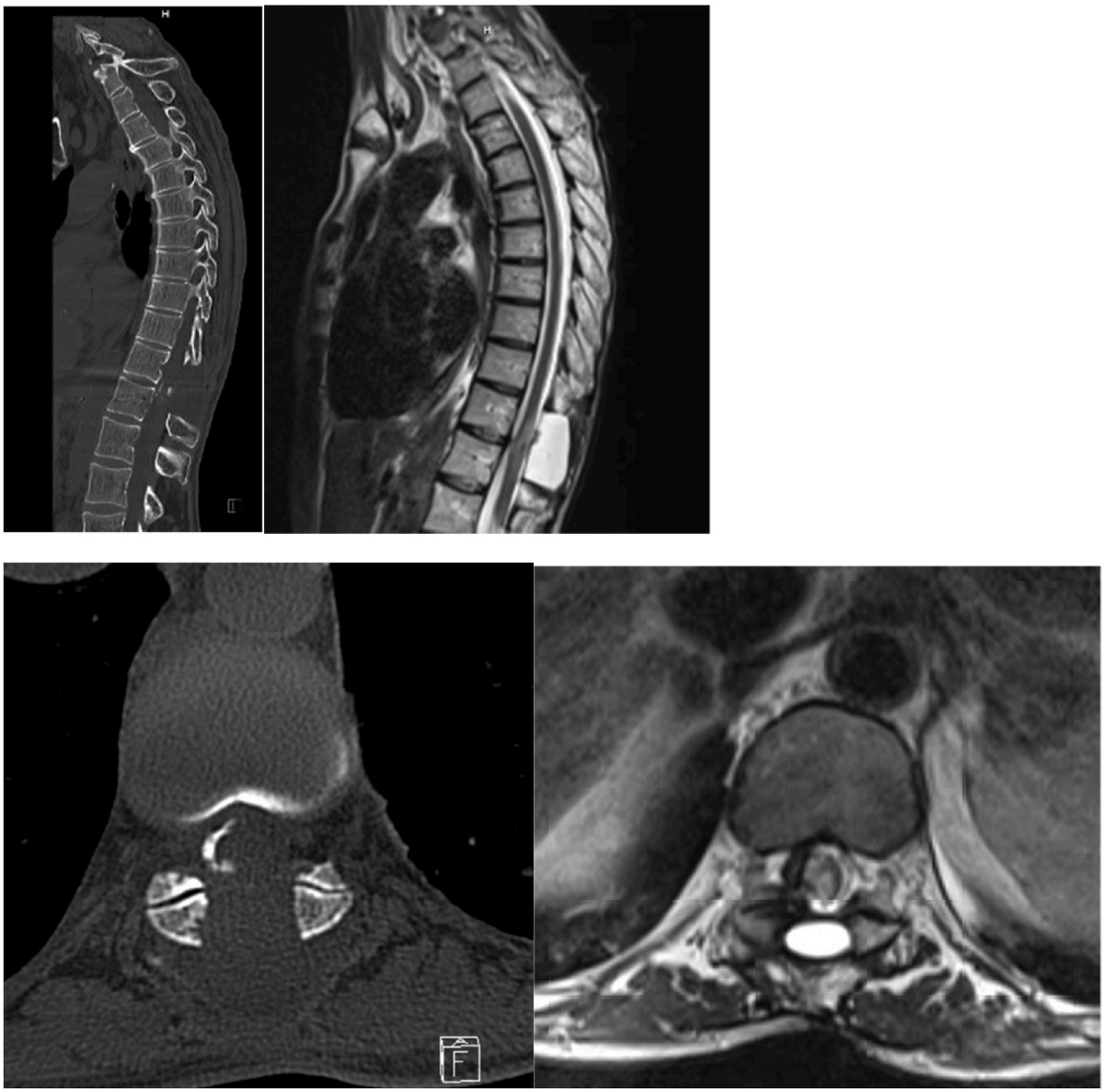

Fig. 4. Sagittal sections from a post-operative CT scan without contrast (A), T2W MRI (B), axial T11-12 sections CT scan without contrast (C) and T2W MRI (D) of the thoracic spine demonstrating T11 laminectomy for partial resection of a heterogeneously calcified mass with decreased mass effect on the spinal cord.

distribution associated with their lesion location (Table 1). Instances of reported back pain and neck pain had corresponding spinal CAPNON located within the range of T8 to L5 and between the foramen magnum and C7, respectively. Patients were more likely to report back pain than neck pain or leg pain ($p = 0.0123$), likely due to spinal CAPNONs most frequently occurring in the lumbar spine. We found that patients were more likely to present with pain as a symptom of CAPNON than other presentations, such as sensory changes, paresis, or radiculopathy ($p = 0.0010$). While our patient's descriptions of burning sensation and pain were common among patients with CAPNON, her neurological manifestations did not correspond precisely to the tumor location. Interestingly, the pain described by our patient was in the L2-L3 distributions despite the tumor being located at the T11-T12 spinal cord level. Difficulty walking was noted as a predominant symptom in one patient with lumbar CAPNON. A shuffling gate was noted twice with CAPNON located in the upper cervical spine and the foramen magnum, likely reflecting the patient's cervical myelopathy from spinal cord compression.

Imaging reports from X-ray, CT, and MRI led to misdiagnoses of CAPNON, such as disc herniation, meningioma, calcified hematoma, cancer metastasis, or abscess (Table 1). While CAPNON can mimic these other spinal pathologies on imaging, we found that CAPNON does have some pathognomonic imaging findings (Table 1, Supplementary Table 1.). On MRI, CAPNON lesions of the spine were predominantly T1 and T2 hypointense. We found that for T1 weighted sequences, CAPNON lesions were more likely to be hypointense than iso- or hyperintense ($p = 0.0001$). When looking at T2 weighted sequences, again, lesions were more likely to be hypointense than iso- or hyperintense ($p = 0.0003$). Imaging reports further suggest that CAPNON are well-defined lesions with widely variable sizes. The average size was 18.68 mm, with a standard deviation of 15.55 mm. The largest spinal CAPNON described in the literature is 65 mm × 56 mm × 56 mm, while the smallest was reported as 5 mm (Table 1).

Surgical resection was the most common treatment of CAPNON, except for one case treated medically with indomethacin. Gross total resection was more likely to be performed than subtotal resection ($p = 0.0034$). Of the 24 cases describing the extent of resection, only two cases had subtotal resection because the capsule was densely adherent to the dura, as it was in our case. Overall, both patients had good outcomes despite subtotal resection with relief of symptoms at follow-up

Table 1
Clinical, radiological, surgical, pathological, and post-operative information from all cases of spinal CAPNON in the literature.

Author	Age (year), Sex	Presentation	Location, relationship to dura	Pre-op diagnosis	MRI	CT	Maximum Dimension (mm)	Extent of Resection	Adherence to spinal cord	Recurrence (months)	Follow-up	Follow-up Length (months)
Bertoni, 1990[1]	50, M	NP	FM, e					N/A	N		A	42
Bertoni, 1990	23, M	BP	T10, e					N/A	N			L
Bertoni, 1990	58, M	Pp	C2, e					N/A	N		A	112
Bertoni, 1990	12, M	NP	C6, e					N/A	N		A	39
Bertoni, 1990	32, M	BP	L4, e					N/A	N		A	84
Bertoni, 1990	33, F	BP	T9, e					N/A	N			L
Bertoni, 1990	68, F	Sc	L4, e					N/A	N		S	16
Bertoni, 1990	20, F	I	C2, e					N/A	N			L
Bertoni, 1990	56, F	BP	L4, e					N/A	N			L
Smith, 1994[4]	48, M	Sc	L2, e		HOI		8	N/A	N			
Moser et al 1994[20]	68, M	AP	C7, e	C8 R	HRI/HRI/ Well-defined	HOI/C	10	GTR	AD		A	
Shrier, 1999[7]	59, M	SG, Δ*S* (LUE), Tp	FM, e	MG	HOI/HOI + HRI/E		20	GTR			S	24
Qian et al 1999[21]	49, M	LUE and LLE –S	clivus region				40	GTR			I	90
Qian et al 1999	59, M	NP, SG, Δ*S* (LUE)	C1-2, ea					N/A				46
Chang, 2000[22]	60, M	NP	C3, io		HOI/HOI/E			N/A		24		
Mayr, 2000[2]	58, M	BP, UMN	T10, e	DH, HTc, MG	HOI/HOI/C	C	40	STR			A	48
Mayr, 2000	63, M	-S (LUE), Tp	C3, e		HOI	C		N/A	AD		A	60
Liccardo, 2003[23]	40, M	BP, W	T8, e		HOI/HOI	HRI/C	50	GTR			I	36
Park, 2008[24]	59, F	NP +(LUE), R	C7, e	CM	IOI/IOI/C			GTR	AD			
Apostolopoulos, 2009[25]	53, M	BP, HP, P(LLE)	L1	MG, NF	C		15	GTR	AS			
Tong, 2010[26]	67, F	BP, Cl, W	L4, e	SOA (CPP)		C		N/A				
Rusleh et al, 2011[15]	43, F	BP	L3		HOI/HOI/ well-defined		5	GTR	AS		I	10
Ozdemir, 2011[27]	53, M	Mp	FM, i		E/C/Well-defined		20	GTR				
Naidu et al 2012[28]	43, M	BP, +(LLE)	L4, e	HTc, MG, NST, TB,	IOI to HRI/ HRI/C	C/Well-defined		N/A				
Muccio, 2012[3]	57, M	BP, Pp	T10-11, e		HRI/HRI/E/ Well-defined	HRI/C/ Well-defined	24	GTR			P	2
Nathoo et al, 2012[29]	44, F	BP (L)		FMT, HTc, LM, NF, Sc	C			GTR	AP			18
Kwan et al 2012[30]	48, M	BP +(LLE)	T9		HOI/HOI	IOI/C	18	N/A			A	
Jentoft et al, 2012[31]	26, F	BP	L1-L2	SW	HOI/HOI		8	GTR	AS			
Bartanusz et al 2013[32]	1.83, F	NP	C1-2		HOI/HOI/C	C	10	STR			A	12
Kocovsky et al 2015[33]	64, F	BP +(LLE)	L5-S1, e		HOI/HOI/ Well-defined	C	38					
Reinard et al 2015[34]	44, M	BP, P(LLE)	L4, e	A, CM, DH, HTc, MG, SyC, SD, SW, TB	HOI/HOI/E	C/well-defined		GTR	AS		A	48
Song, 2015[35]	77, F	BP	T12, e		HOI/HOI	C		GTR	AD		I	5
Song, 2015	67, F	L3 R (R)	L2-3, e			C	10.4	GTR				
Song, 2015	78, F	BP	L1, e			C/well-defined	8.5	GTR				
Lopes et al 2016[36]	72, F	BP, CES	L2, i		HOI/HOI	HRI		GTR	N			<1
Garcia Duque et al 2016[6]	51, F	BP	L2, i, em		HOI/HOI	C		GTR	AD		I	12

(*continued on next page*)

Table 1 (*continued*)

Author	Age (year), Sex	Presentation	Location, relationship to dura	Pre-op diagnosis	MRI	CT	Maximum Dimension (mm)	Extent of Resection	Adherence to spinal cord	Recurrence (months)	Follow-up	Follow-up Length (months)
Garcia Duque et al 2016	46, F	NP	C3, io			C		GTR				27
Garcia Duque et al 2016	73, M	Pp	T2, i, em		HOI/HOI/ well-defined	C		GTR			A	12
Singh, 2016[37]	90, F	Wk (LUE)	C7-T1, i		well-defined			N/A	AD		I	2
Giardinaet al. 2016[38]	68, M	R	L4-5	SyC	HOI to IOI/ HOI to IOI	C		GTR			I	60
Wu et al 2017[39]	39, F	SP	S2, subdural		HOI/E/well-defined	C		GTR	N		A	36
Lu et al 2020[18]	51, F	BP	L3-4, epi		HOI/HOI + HRI/C		65	N/A				
Yang et al 2020[19]	64, F	NP (L)	C3, epi		HOI/HOI	C	11.4	N/A				2
Yang et al 2020	60, M	CM	C7, epi		IOI/IOI/C/ well-defined		17.3	N/A			S	7
Yang et al 2020	64, F	BP (L)	L5-S1, epi		HOI	C/well-defined	38	N/A			I	6
Ho et al 2020[16]	75, M		T11					N/A				
Ho et al 2020	52, M		T7-T8					N/A				
Ho et al 2020	74, F		L5-S1					N/A				
Ho et al 2020	68, F		L4-L5					N/A				
Ho et al 2020	49, M		L5-S2, i		HOI/HOI/ Well-defined			N/A				
Ho et al 2020	43, F		T10-T11, e		HOI/Well-defined			N/A				
Ho et al 2020	70, F		L4-L5, t		HOI			N/A				
Ho et al 2020	67, F		L4-L5, e		Well-defined			N/A				
Ho et al 2020	83, F		L4-L5, e		HOI/Well-defined			N/A				
Ho et al 2020	71, F		L5-S1, t		Well-defined,			N/A				
Ho et al 2020	50, F		L5-S1, e		-/HOI			N/A				
Ho et al 2020	39, F		T9-T10, e		-/HOI/Well-defined,			N/A				
Ho et al 2020	65, M		L2-L3, e					N/A				
Ho et al 2020	7, F		T2-T3, e		HOI/HOI/ Well-defined			N/A				
Ho et al 2020	78, M		T9-T10, e		HOI/HOI/ Well-defined			N/A				
Ho et al 2020	58, M		L2-L3, i		-/HOI			N/A				
Ho et al 2020	77, M		C7-T1, e		-/HOI			N/A				
Ho et al 2020	65, M		L3-L4, t		HOI/HOI			N/A				
Ho et al 2020	71, F		L1-L2, i		HOI/HOI			N/A				
Ho et al 2020	66, M		L4-L5					N/A				
Ho et al 2020	75, M		T8-T9					N/A				
Ho et al 2020	82, F		L4-L5					N/A				
Ho et al 2020	77, F		L4-L5					N/A				
Ho et al 2020	56, F		L4-L5, t					N/A				
Ho et al 2020	45, F		L4-L5, e					N/A				
Ho et al 2020	43, M		T9-T10, e		C			N/A				
Ho et al 2020	52, F		C7-T1, e		HOI/HOI/C/ Well-defined			N/A				
Ho et al 2020	64, M		C6					N/A				

(*continued on next page*)

Table 1 (*continued*)

Author	Age (year), Sex	Presentation	Location, relationship to dura	Pre-op diagnosis	MRI	CT	Maximum Dimension (mm)	Extent of Resection	Adherence to spinal cord	Recurrence (months)	Follow-up	Follow-up Length (months)
Ravi and Srinath, 2021[40]	53, F	L4-L5 R	L5, i, em		IOI/IOI			N/A	AD		A	6
Lu et al 2022[17]	71, F	BP, LP (L)	L1-2		HOI + HRI/HOI	C	46.5	N/A				
Lu et al 2022	78, F	Wk (LE)	T11		HOI/HOI		7.5	N/A				
Lu et al 2022	62, F	LP (R)	L4-L5		HOI/HRI		11	N/A				
Lu et al 2022	76, F	LP (L), U	L3-L4		HOI/HRI		18.7	N/A				
Lu et al 2022	77, F	(same person as above) BP +(RLE)	L3-L4		HOI/HRI		13.9	N/A				

Presentations: AP, arm pain; BP, back pain; Cl, claudication; CES, cauda equina syndrome; CM, cervical myelopathy; HP, hip pain; I, incidental; LE, lower extremity; LP, leg pain; UE, upper extremity pain; Mp, monoparesis; NP, neck pain; P, pain; Pp, paraparesis; R, radiculopathy; Sc, sciatica; SG, shuffling gate; SP, sacrococcygeal pain; Tp, tetraparesis; U, urinary urgency; UMN, upper motor neuron signs; W, difficulty walking; Wk, weakness; ΔS, change in sensation; −S, sensory loss; +, radiating; (L), left; (R), right Location: e, extradural; ea, extraaxial; em, extramedullary; epi, epidural; i, intradural; io, intraosseous; t, transdural Pre-operative diagnosis A, abscess; CM, cancer metastasis; CPP, calcium pyrophosphate; DH, disc herniation; FMT, fibromyxoid tumor; HTc, hematoma calcified; LM, leiomyoma; MG, meningioma; NF, neurofibroma; NST, nerve sheath tumor; SCc, sarcoma calcified; SD, sarcoidosis; SOA, synovial osteochondromatosis and arthropathies; SW, schwannoma; SyC, synovial cyst; TB, tuberculosis infection Imaging AL, anterolateral; C, calcified density; DDD, degenerative disc disease; FM, foramen magnum; E, contrast enhancing; HOI, hypointense; HRI, hyperintense; IOI, isointense Extent of Resection GTR, gross total resection; STR, subtotal resection Adherence to spinal cord AS, adherence to spinal cord; AD, adherence to dura; AP, adherence to periosteum; N, non-adherent Follow-up A, asymptomatic; S, stable; I, improved; P, partially improved Follow-up Length L, lost to follow-up.

appointments at 1 and 2 years post-operatively.

Pathological findings were overall consistent across cases. Immunohistochemical staining was not frequently reported, but of the cases with GFAP staining, 2 were positive and 2 were negative. Of cases with S-100 staining, there were 2 positive and 2 negative. Lastly, of cases with EMA staining, there were 3 positive and 2 negative. In our case, we report negative S-100 and rare focal EMA staining, but the field has yet to find one consistent and reliable immunohistochemical marker for CAPNON lesions of the spine.

The literature suggests that the prognosis for CAPNON is very favorable. In our review, only one case[22] showed local progression of a pre-existing lesion. This case was unique in that it required 2 operations. First, a total laminectomy with occipitocervical fusion was performed, followed by curettage with an autogenous iliac bone graft one month later. While the patient was symptom-free at 3 months after the second operation, there was evidence of recurrence at the 24-month follow-up. Of cases with information on post-operative imaging and post-operative follow-up of symptoms, the majority showed no evidence of tumor or growth of the residual lesion. Of the 20 cases that reported specifically about recurrence rates, 19 of them (95%) reported no recurrence at follow-up appointments. Of the 25 cases that reported findings at follow-up, 23 (92%) reported complete relief of symptoms or substantial improvement. Of the two cases that reported continued symptom burden, one reported a continued gate disturbance at 24 months with no recurrence,[7] and the other reported minimal improvement in symptoms at 2 months with imaging confirming no recurrence.[3] Given that no controlled studies exist, it is uncertain whether 2 months is a long enough recovery time to assess symptomatic improvement post-operatively. Previous reports noted improvement as quickly as the day of hospital discharge[39] to as long as 9 years postoperatively due to delayed follow-up time.[1] Overall, the average follow-up time was ~30 months. The patient in our case reported symptomatic improvement at the time of discharge, adding to the large number of cases that show quick symptomatic improvement with surgical excision of CAPNON.

5. Conclusions

Although spinal CAPNON are very rare, it is important to synthesize our understanding of the disease and the most optimal treatment approach for patients. Through our comprehensive literature review, we show that majority of spinal CAPNON are located in the lumbar spine, are often extradural, and are well-defined lesions imaging. On T1 and T2 MRI sequence, CAPNON are mostly hypointense. While pain is the most common presenting symptom, symptomatic improvement is the most likely surgical outcome (Fig. 5). We show that overall, patient outcomes are highly favorable with complete or near complete symptomatic relief shortly after surgical resection.

CRediT authorship contribution statement

Ajay Chatrath: Writing – review & editing, Writing – original draft, Visualization, Validation, Software, Methodology, Investigation, Formal analysis, Data curation, Conceptualization. **Mackenzie Lemieux:** Writing – review & editing, Writing – original draft, Visualization, Validation, Software, Formal analysis, Data curation, Conceptualization. **Rujvee P. Patel:** Writing – review & editing, Writing – original draft, Data curation. **Kaleigh F. Roberts:** Writing – review & editing, Data curation. **Sonika Dahiya:** Writing – review & editing, Data curation. **Brenton Pennicooke:** Writing – review & editing, Writing – original draft, Visualization, Validation, Supervision, Software, Resources, Project administration, Methodology, Investigation, Formal analysis, Data curation, Conceptualization.

Declaration of competing interest

The authors declare that they have no known competing financial

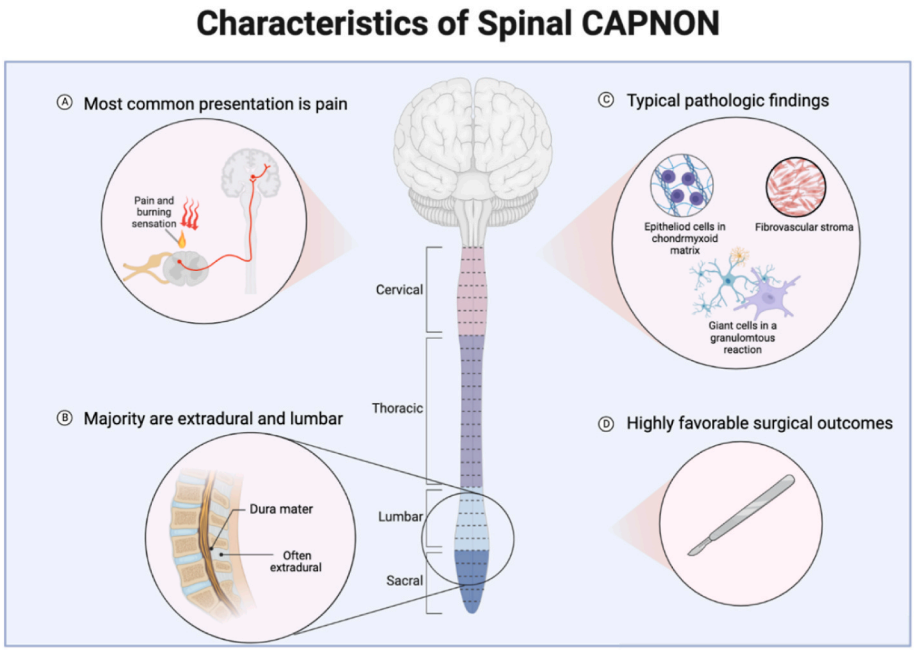

Fig. 5. Graphical depiction of core characteristic of spinal CAPNON determined from extensive literature review.

interests or personal relationships that could have appeared to influence the work reported in this paper.

Appendix A. Supplementary data

Supplementary data to this article can be found online at https://doi.org/10.1016/j.wnsx.2024.100312.

References

1. Bertoni F, Unni KK, Dahlin DC, Beabout JW, Onofrio BM. Calcifying pseudoneoplasms of the neural axis. *J Neurosurg*. 1990;72:42–48.
2. Mayr MT, Hunter S, Erwood SC, Haid Jr RW. Calcifying pseudoneoplasms of the spine with myelopathy. Report of two cases. *J Neurosurg*. 2000;93:291–293.
3. Muccio CF, Cerase A, Leone A, et al. Calcifying pseudoneoplasm of the neuraxis. Two case reports and review of CT and MR findings. *NeuroRadiol J*. 2012;25:453–459.
4. Smith DM, Berry 3rd AD. Unusual fibro-osseous lesion of the spinal cord with positive staining for glial fibrillary acidic protein and radiological progression: a case report. *Hum Pathol*. 1994;25:835–838.
5. Stienen MN, Abdulazim A, Gautschi OP, Schneiderhan TM, Hildebrandt G, Lücke S. Calcifying pseudoneoplasms of the neuraxis (CAPNON): clinical features and therapeutic options. *Acta Neurochir*. 2013;155:9–17.
6. Garcia Duque S, Medina Lopez D, Ortiz de Mendivil A, Diamantopoulos Fernandez J. Calcifying pseudoneoplasms of the neuraxis: report on four cases and review of the literature. *Clin Neurol Neurosurg*. 2016;143:116–120.
7. Shrier DA, Melville D, Millet D, et al. Fibro-osseous lesions involving the brain: MRI. *Neuroradiology*. 1999;41:18–21.
8. Abdaljaleel M, Mazumder R, Patel CB, et al. Multiple calcifying pseudoneoplasms of the neuraxis (MCAPNON): distinct entity, CAPNON variant, or old neurocysticercosis? *Neuropathology*. 2017;37:233–240.
9. Aiken AH, Akgun H, Tihan T, Barbaro N, Glastonbury C. Calcifying pseudoneoplasms of the neuraxis: CT, MR imaging, and histologic features. *AJNR Am J Neuroradiol*. 2009;30:1256–1260.
10. Greco E, Elmandouh O, Desai A, Bhatt A, Vibhute P, Aggarwal A. Calcifying pseudoneoplasms of the neuraxis (CAPNON): the great tumor mimicker. *Radiol Case Rep*. 2022;17:3157–3161.
11. Kerr EE, Borys E, Bobinski M, Shahlaie K. Posterior fossa calcifying pseudoneoplasm of the central nervous system: case report. *Journal of Neurosurgery JNS*. 2013;118:896–902.
12. Saha A, Arevalo-Perez J, Peck KK, et al. Calcifying pseudoneoplasm of the spine: imaging and pathological features. *NeuroRadiol J*. 2018;31:440–444.
13. Vallejo FA, Chen SH, Bano G, Gultekin S, Morcos J. Calcifying pseudoneoplasm of the neuroaxis presenting with refractory seizures: case report and literature review. *J Clin Neurosci*. 2020;78:439–443.
14. Rhodes RH, Davis RL. An unusual fibro-osseous component in intracranial lesions. *Hum Pathol*. 1978;9:309–319.
15. Rulseh A, Keller J, Klener J, et al. Calcifying pseudoneoplasms of the neural axis. Report of three cases. *Ces Slov Neurol Neurochir*. 2011;74:584–589.
16. Ho ML, Eschbacher KL, Paolini MA, Raghunathan A. New insights into calcifying pseudoneoplasm of the neuraxis (CAPNON): a 20-year radiological-pathological study of 37 cases. *Histopathology*. 2020;76:1055–1069.
17. Lu JQ, Al Mohammadi WJB, Fong C, et al. Spinal calcifying pseudoneoplasm of the neuraxis (CAPNON) and CAPNON-like lesions: CAPNON overlapping with calcified synovial cysts. *Pathology*. 2022;54:573–579.
18. Lu JQ, Popovic S, Provias J, Cenic A. Collision lesions of calcifying pseudoneoplasm of the neuraxis and rheumatoid nodules: a case report with new pathogenic insights. *Int J Surg Pathol*. 2020;29:314–320.
19. Yang K, Reddy K, Wang BH, et al. Immunohistochemical markers in the diagnosis of calcifying pseudoneoplasm of the neuraxis. *Can J Neurol Sci*. 2021;48:259–266.
20. Moser FG, Tourje EJ, Pressman BD, Blinderman EE. Calcifying pseudotumor of the cervical spine. *AJNR Am J Neuroradiol*. 1994;15:580.
21. Qian J, Rubio A, Powers JM, et al. Fibro-osseous lesions of the central nervous system: report of four cases and literature review. *Am J Surg Pathol*. 1999;23:1270–1275.
22. Chang H, Park JB, Kim KW. Intraosseous calcifying pseudotumor of the axis: a case report. *Spine*. 2000;25:1036–1039.
23. Liccardo G, Lunardi P, Menniti A, Floris R, Pastore FS, Fraioli B. Calcifying pseudotumor of the spine: description of a case and review of the literature. *Eur Spine J*. 2003;12:548–551.
24. Park P, Schmidt LA, Shah GV, Tran NK, Gandhi D, La Marca F. Calcifying pseudoneoplasm of the spine. *Clin Neurol Neurosurg*. 2008;110:392–395.
25. Apostolopoulos V, David KM, Malcolm A, King A. Intradural calcifying fibroblastic proliferation associated with a nerve root: a reactive process mimicking a nerve sheath tumor. *Spine*. 2009;34:E712–E715.
26. Tong D, Karunaratne N, Howe G, Spencer D, Manolios N. Clinical images: calcifying pseudoneoplasm of the neuraxis. *Arthritis Rheum*. 2010;62:704.
27. Ozdemir M, Bozkurt M, Ozgural O, Erden E, Tuna H, Caglar YS. Unusual localization of an unusual tumor: calcifying pseudoneoplasm of the foramen magnum. *Clin Neuropathol*. 2011;30:25–27.
28. Naidu PK, Patel SC. Calcifying pseudoneoplasm of the neural Axis arising within the lumbar spine: implications of unique cross-sectional imaging characteristics of a rare spinal column lesion. *Neurographics*. 2012;2:27–30.
29. Nathoo N, Viloria A, Iwenofu OH, Mendel E. Calcifying fibrous tumor of the spine. *World Neurosurg*. 2012;77:e591–e594.
30. Kwan MK, Abdelhai AM, Saw LB, Chan CY. Symptomatic calcifying pseudotumor of the thoracic spine that resolved with the indomethacin treatment: a case report. *Spine*. 2012;37:E1676–E1679.
31. Jentoft ME, Scheithauer BW, Bertoni F, Abood C, Chang HT. Calcifying pseudoneoplasm of the neuraxis with single nerve rootlet involvement. *Can J Neurol Sci*. 2012;39:840–842.
32. Bartanusz V, Ziu M, Jimenez DF, Henry JM. Calcifying pseudoneoplasm of the atlantoaxial joint in a child. *J Neurosurg Spine*. 2013;18:367–371.
33. Kocovski L, Parasu N, Provias JP, Popovic S. Radiologic and histopathologic features of calcifying pseudoneoplasm of the neural Axis. *Can Assoc Radiol J*. 2015;66:108–114.
34. Reinard KA, Seyfried DM, Gutiérrez JA, Rock JP. A rare intradural extramedullary calcifying pseudoneoplasm of the spine presenting with radiculopathy. *Br J Med Med Res*. 2015;7:419–424.

35. Song SY, Ahn SY, Rhee JJ, Lee JW, Hur JW, Lee HK. Three cases of calcifying pseudoneoplasm which involve the epidural space of the spine. *Korean J Spine*. 2015; 12:235–238.
36. Lopes AJ, Brock RS, Martins TG, et al. Intradural calcifying pseudoneoplasm of the neuraxis presenting as a cauda equina syndrome. *Surg Neurol Int*. 2016;7: S1102–S1105.
37. Singh H, Zengou R, Moss IL. Intradural calcifying pseudoneoplasm. *Spine J : official journal of the North American Spine Society*. 2016;16 1:e45–e46.
38. Giardina FGG, Righi A, Bertoni F. Calcifying pseudotumor of the spine : a case report. *Clinics In Surgery*. 2016;1.
39. Wu HG, Yue L, Luo CJ, Wei ZH, Wang S, Zheng ND. Calcifying pseudoneoplasm of the neuraxis arising from the sacral canal: case report and review of the literature. *World Neurosurg*. 2017;98:875 e879–e875 e812.
40. Ravi V, Srinath P. A rare case of calcifying pseudoneoplasms of the neural Axis in lumbar spine. *Indian Journal of Neurosurgery*. 2021; 11:-177-178.