


# Superior clinical pregnancy rates after microsurgical epididymal sperm aspiration

Hatsuki Hibi<sup>1</sup>  | Makoto Sumitomo<sup>2</sup> | Noritaka Fukunaga<sup>3</sup> | Megumi Sonohara<sup>3</sup> | Yoshimasa Asada<sup>3</sup> 

<sup>1</sup>Department of Urology, Kyoritsu General Hospital, Nagoya, Japan

<sup>2</sup>Department of Urology, Aichi Medical University School of Medicine, Nagakute, Japan

<sup>3</sup>Asada Ladies Clinic, Nagoya, Japan

## Correspondence

Hatsuki Hibi, Department of Urology, Kyoritsu General Hospital, Nagoya, Japan.  
Email: hibih@quartz.ocn.ne.jp

## Abstract

**Purpose:** To assess normal fertilization, clinical pregnancy, and live birth rates after the use of microscopic epididymal sperm aspiration (MESA).

**Methods:** One-hundred-and-sixty azoospermic participants who underwent MESA were evaluated. The MESA was performed by using a micropuncture method with a micropipette. In cases in which motile sperm were not obtained after the MESA, conventional or micro-testicular sperm extraction (TESE) was completed.

**Results:** Adequate motile sperm were retrieved in 71 participants by using MESA and in 59 out of 89 participants by using TESE. Of the total number of patients, 123 underwent intracytoplasmic sperm injection. After MESA, the normal fertilization rate was 73.5% and the clinical pregnancy rate per case was 95.7%. Healthy deliveries resulted after MESA in 65 (92.9%) cases and after TESE in 38 (71.7%) cases.

**Conclusion:** The MESA specimen collection does not have any special requirements, such as mincing tissue disposition. The MESA also can reduce the amount of laboratory work that is needed for cryopreservation. In the authors' experience, MESA is a beneficial procedure and should be given priority over TESE.

## KEYWORDS

azoospermia, cryopreservation, intracytoplasmic sperm injection outcome, microscopic epididymal sperm aspiration, sperm retrieval

## 1 | INTRODUCTION

Approximately 20% of men who visit infertility clinics, excluding those who have undergone vasectomies, are azoospermic.<sup>1</sup> Azoospermia can be classified as either "obstructive" or "non-obstructive"; regardless, it is important in each case that the specific etiology of each participant be considered.<sup>2</sup> Varying surgical methods are available for sperm retrieval. Testicular sperm extraction (TESE) is now used widely as a method of sperm retrieval surgery owing to its technical simplicity. There is no doubt that micro-TESE has become a standard technique for non-obstructive

azoospermia (NOA).<sup>3</sup> Obstructive azoospermia (OA), in contrast, can be caused by a vasectomy, congenital bilateral absence of the vas deferens (CBAVD), scarring from past epididymal infections, inguinal hernia, and hydrocelectomy. The initial therapy option for these patients includes microsurgical seminal reanastomosis with surgical skill. However, this is not always plausible in cases of CBAVD, and in others, the requirements of surgical skill for reanastomosis are unattainable. In addition, the patency and pregnancy rates following microsurgical epididymovasostomy for unknown causes of epididymal obstruction are limited. Although patients with OA are good candidates for microscopic epididymal sperm

This paper was presented at the Annual Meeting of European Society of Human Reproduction and Embryology, held at Geneva, Switzerland, July 2-5, 2017.

This is an open access article under the terms of the Creative Commons Attribution-NonCommercial License, which permits use, distribution and reproduction in any medium, provided the original work is properly cited and is not used for commercial purposes.

© 2017 The Authors. Reproductive Medicine and Biology published by John Wiley & Sons Australia, Ltd on behalf of Japan Society for Reproductive Medicine.

aspiration (MESA) in theory, TESE is performed widely by many surgeons because less surgical skill is required. Moreover, some authors have reported that because MESA specimens contain DNA fragmentations of sperm, intracytoplasmic sperm injection (ICSI) results in poorer fertilization and pregnancy rates.<sup>4,5</sup> In this study, normal fertilization, clinical pregnancy, and live birth rates for clinically considered patients with OA, in which sperm were retrieved via either MESA or TESE, was assessed retrospectively.

## 2 | MATERIALS AND METHODS

### 2.1 | Patients

Of the 438 participants who underwent surgical sperm retrieval in our clinic between April, 2004 and January, 2016, 160 who underwent MESA were evaluated. The mean age of the patients was 33.2 years (range: 25-63) and the mean age of the spouses was 30.3 years (range: 22-43). The mean testicular volume was 20 mL (range: 12-26) in the right and 16 mL (range: 10-22) in the left. The mean endocrinal panel of luteinizing hormone (LH), follicle-stimulating hormone (FSH), testosterone, and free testosterone were 3.0 mIU/mL (range: 0.6-9.8), 4.9 mIU/mL (range: 2.0-8.2), 4.84 ng/mL (range: 2.15-8.29), and 8.8 pg/mL (range: 5.5-16.3), respectively. The mean Body Mass Index was 23.4 (range: 18.4-30.8). The etiology of obstruction included: CBAVD (21 participants), epididymitis (19 participants), mumps (14 participants), orchidopexy (12 participants), inguinal herniation (11 participants), vasectomy (10 participants), spinal cord injury (10 participants), Young's syndrome (seven participants), failed seminal reconstruction (five participants), and unknown (51 participants). The complications included: acute myelogenous leukemia (three participants) and malignant lymphoma, seminoma, scleroderma, and depression in one participant, respectively.

### 2.2 | Surgical procedure

The surgical procedure was performed under local anesthesia with a spermatic block under the use of a sedative by using the micropuncture method, as was previously described (MESA group).<sup>6,7</sup> Micropipette tips, which were sharpened to a diameter of ~75  $\mu$ m, were connected to a 10 mL glass syringe with a silicone tube (Fig. 1). As MESA was the

primary treatment strategy for obstructive azoospermia, in cases in which motile sperm were not obtained after repeated bilateral puncturing of the epididymis, conventional or micro-TESE was used (MESA/TESE group). The aspirated or extracted samples were transferred into modified human tubal fluid (Naka Medical, Tokyo, Japan) and sent to the in vitro fertilization (IVF) laboratory for cryopreservation.

Differences between the MESA and MESA/TESE groups for average values were tested by using the F-test and the t test. The fertilization and clinical pregnancy rates were analyzed with the chi-square test.

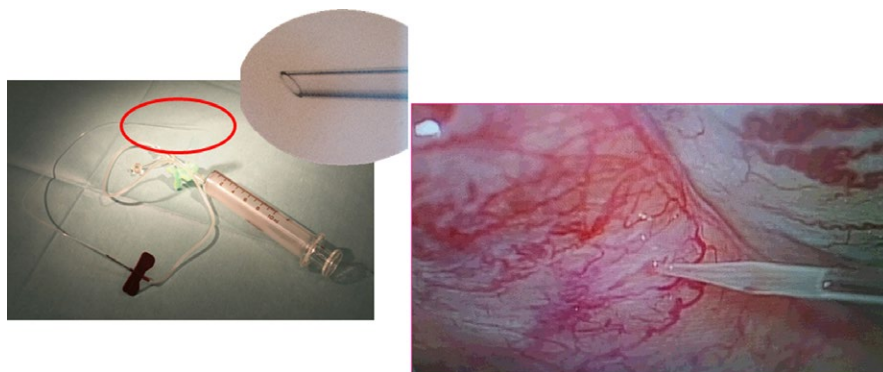
## 3 | RESULTS

The MESA group included 71 participants and the MESA/TESE group included 89 participants. The patient characteristics of each group are shown in Table 1. The varying etiologies of obstruction in each group can be seen in Table 2. Adequate motile sperm were retrieved in 71 participants (100%) in the MESA group, but in only 59 out of 89 participants (66.2%) in the MESA/TESE group. Thus, ultimately the cryopreservation of the motile sperm of 130 patients was achieved. Of these, 123 underwent ICSI. Although the mean ages of the patient and spouse were not significantly different between groups, the MESA group displayed lower LH and FSH levels, a larger testicular volume, and higher testosterone levels, as compared with the MESA/TESE group (Table 1).

The normal fertilization and clinical pregnancy rates per case were 73.5% and 95.7% in the MESA group, respectively, and 71.5% and 78.0% in the MESA/TESE group, respectively. Although the normal fertilization rates in the MESA and MESA/TESE groups were not significantly different, the clinical pregnancy rate per case in the MESA group was markedly higher than in the MESA/TESE group. Healthy deliveries resulted after MESA in 65 cases (92.9%) and after MESA/TESE in 38 cases (71.7%) (Table 3).

## 4 | DISCUSSION

Azoospermia is classified as either "OA" or "NOA," mainly according to the FSH value, testicular volume, chromosomal evaluation, and past history. Maintaining consideration of the specific etiology of the



**FIGURE 1** Under the microscope, the micropipette that was sharpened to a diameter of ~75  $\mu$ m was inserted directly into the epididymal tubule by using the micropuncture technique

**TABLE 1** Patient characteristics in the microscopic epididymal sperm aspiration (MESA) and MESA/testicular sperm extraction (TESE) groups

Characteristic	MESA (n = 71)	MESA/TESE (n = 89)	P-value
Mean age (years)	35 (25-47)	36 (26-63)	.08
Spouse age (years)	32 (22-43)	34 (25-43)	.06
Testicular volume: right/left	19 mL/16 mL (2-26)/(2-27)	17 mL/15 mL (2-26)/(4-24)	<.05
LH (mIU/mL)	4.0 (1.0-14.1)	4.8 (0.6-15.6)	<.05
FSH (mIU/mL)	5.1 (1.4-21.0)	8.6 (1.9-36.3)	<.01
Testosterone (ng/mL)	5.22 (1.50-12.60)	4.67 (1.79-6.76)	<.05

FSH, follicle-stimulating hormone; LH, luteinizing hormone.

**TABLE 2** The etiology of obstruction in each group

Etiology	MESA (n = 71) N (%)	MESA/TESE (n = 89) N (%)
Epididymitis	-	19 (21.3)
CBAVD	6 (8.5)	15 (16.9)
Mumps	7 (9.9)	7 (7.9)
Orchidopexy	5 (7.0)	7 (7.9)
Vasectomy	-	10 (11.2)
Inguinal herniation	6 (8.5)	5 (5.6)
Spinal cord injury	5 (7.0)	5 (5.6)
Young's syndrome	5 (7.0)	2 (2.2)
Failed seminal reconstruction	5 (7.0)	-
Unknown	32 (45.0)	19 (21.3)

CBAVD, congenital bilateral absence of the vas deferens; MESA, microscopic epididymal sperm aspiration; TESE, testicular sperm extraction.

presentation in each participant is important. Although NOA is characterized as demonstrating elevated FSH and atrophic testes, no precise data exist. In the case of NOA, there is not a sufficient quantity of sperm production occurring for such to "spill over" into the ejaculate. The causes of NOA include genetic mutations, chromosomal aberrations, hormonal disorders, testicular maldescent, systemic disease, the use of certain medications, radiation, and the presence of toxins. The TESE is now widely applied as a method of sperm retrieval surgery and there is no doubt that micro-TESE has become a standard technique for use in patients with NOA.<sup>3</sup>

In contrast, patients with OA that is brought on by a vasectomy, CBAVD, scarring from past epididymal infections, inguinal hernia, and hydrocelectomy are much different from NOA. The initial therapy for these patients is microsurgical seminal reanastomosis. As seminal tract reanastomosis can obtain natural pregnancy, there is no requirement of an invasive procedure for the spouse. Moreover, it is cost-effective, compared to ICSI. However, this is not always able to be completed in CBVAD or after failed reanastomosis. Microsurgical vasoepididymostomy for epididymal obstruction that is caused by unknown etiology is considered to be a challenging surgery due to the limited patency and pregnancy rates. In a nationwide Japanese survey, the appearance of sperm in the postoperative ejaculate for vasectomy, epididymal obstruction, herniorrhaphy, unknown etiology, and other etiology groups

**TABLE 3** Details of the intracytoplasmic sperm injection outcomes

Variable	MESA	MESA/TESE	P-value
Number receiving ART	70/71 (98.6%)	53/59 (89.8%)	-
Mean spousal age (years)	32 (22-43)	34 (25-43)	.06
Normal fertilization rate	73.50%	71.50%	.25
Number of embryo transfers	70	50	-
Clinical pregnancies	67	39	-
Clinical pregnancy rate per case	95.70%	78.00%	.01
Embryo transfers per cycle	258	173	-
Clinical pregnancy cycles	111	64	-
Clinical pregnancy rate per cycle	43.00%	37.00%	.21
Delivery rate	65	38	-

ART, assisted reproductive technology; MESA, microscopic epididymal sperm aspiration; TESE, testicular sperm extraction.

were 73.6%, 38.9%, 38.9%, 34.0%, and 70.0%, respectively.<sup>8</sup> It should be disappointing not only for the surgeon, but also for the patient and his family when the semen analysis reveals azoospermia after an operation. Therefore, MESA and TESE have been the standard methods for sperm retrieval surgery. The choice of the sperm retrieval method is based on the attending surgeon's preference. Varying surgical methods are available for sperm retrieval. However, sperm retrieval surgery requires that an adequate number of motile sperm are present and that there is minimized damage to the reproductive tract. The MESA is considered by most andrological experts to be the gold-standard method for sperm retrieval, given its high yield of sperm. In cases of ICSI, the fertilization and pregnancy rates using surgically retrieved sperm that have been obtained from the epididymis or testis have been comparable to the results that have been obtained with ejaculated sperm. In the MESA procedure, the sperm-containing epididymal tubule is identified under high-power optical magnification that is provided by an operating microscope and is made to aspirate epididymal fluid. The MESA that is completed by using the micropuncture technique can offer a

large quantity of uncontaminated sperm for ICSI. Nevertheless, TESE is still widely applied, even in the case of the patient with OA due to its technical simplicity and lower requirements for surgical skill. However, TESE requires surgical intervention and hence carries associated risks, such as bleeding, infection, inflammation, devascularization, and the prompting of impaired testicular function, such as decreased testosterone.<sup>9</sup> In the 1990s, the percutaneous epididymal or testicular sperm retrieval technique was used as a minimally invasive and cost-effective method.<sup>10,11</sup> Although the collection of sperm for cryopreservation via percutaneous epididymal sperm aspiration (PESA) is successful, the amount of sperm that is obtained in this fashion is limited. Even if PESA is more successful in terms of sperm harvesting in further attempts, there is an increasing risk for postsurgical complications.<sup>12</sup> Thus, the percutaneous approach is surely the less-invasive technique; however, this also yields a limited number of sperm to freeze and so could lead to a poor pregnancy result.

The reason for failed epididymal aspiration is related to the obstruction of the rete testis. Successful epididymal sperm retrieval can be achieved in ~70% of cases.<sup>13</sup> In this study, adequate motile sperm retrieval and cryopreservation was achieved in 71 of the 71 (100%) participants in the MESA group, whereas it was only completed in 59 of the 89 (66.3%) participants in the MESA/TESE group. As MESA was the primary treatment for obstructive azoospermia, there were no data collected comparing the performance of MESA and the performance of TESE without MESA. In this series, the MESA group displayed a lower LH and FSH level, larger testicular volume, and higher testosterone, as compared with the MESA/TESE group. These differences could be related to the cryopreservation rate per case between the MESA group and the MESA/TESE group.

In retrospective single-center studies, the ICSI outcomes might be better when using epididymal sperm. One study of 368 ICSI cycles in 171 patients with OA showed a significantly higher pregnancy loss rate when testicular sperm collection was attempted.<sup>14</sup> Recently, one study reported that in the first ICSI cycles of couples with obstructive azoospermia, the use of epididymal spermatozoa resulted in a significantly higher live birth rate than did the use of testis spermatozoa.<sup>15</sup> The chance of obtaining a live birth was 39% following MESA-ICSI and 24% following TESE-ICSI. Following adjustment for the available confounders, the odds ratio for an ongoing pregnancy rate was 1.82 (98% confidence interval: 1.05-3.67) for MESA, compared to TESE.

Uncontaminated sperm can be retrieved only by MESA and there is no need for any special requirement before cryopreservation. The MESA yields high-quality sperm and allows for a reduction in the amount of laboratory work by embryologists. Previously, the authors reported that MESA that was completed by using the micropuncture technique resulted in higher fertilization and pregnancy rates.<sup>6,7</sup> Thus, the advantage of MESA is that a large quantity of sperm can be cryopreserved in a single procedure for future attempts at ICSI and that a clinical pregnancy rate of 42%-60% can be achieved.<sup>12,16</sup>

Conversely, another study reported that a testicular sperm group exhibited an obviously higher implantation rate, with a trend toward

a higher ongoing pregnancy rate and a lower miscarriage rate, in comparison with an epididymal sperm group.<sup>17</sup> The hypothesis for this result was that motile sperm that are randomly taken from the epididymis have a lower reproductive potential than those taken from the testicles. Moreover, since MESA specimens contain DNA fragmentations of sperm, ICSI resulted in poorer fertilization and pregnancy rates.<sup>4,5</sup> However, in a meta-analysis setting, a report noted that fertilization rates varied from 45% to 72% for epididymis sperm and from 34% to 81% for testicular sperm.<sup>18</sup> The relative risk ratios of 1.08, 1.01, and 0.71 were described for the fertilization rate, clinical pregnancy rate, and live birth rate, respectively, for epididymal in comparison with testicular sperm. The researchers concluded that epididymal aspiration should be used in view of the possible complication of testicular damage.

In conclusion, the successful completion of MESA specimen collection does not have any special requirement, such as mincing tissue disposition. The MESA also can reduce the amount of laboratory work that is associated with collection and handling, such as that required for sperm cryopreservation. Moreover, a MESA specimen is easily applied for ICSI in cases in which the sperm is either fresh or frozen-thawed. In the authors' experience, MESA is a beneficial procedure and should be given priority over TESE.

## ACKNOWLEDGEMENTS

The authors thank all of the members of the IVF Laboratory team of the Asada Ladies Clinic and the staff of the Asada Fertility Research Center, Nagoya, Japan.

## DISCLOSURES

*Conflict of interest:* The authors declare no conflict of interest. *Human and Animal Rights:* The protocol for this research project, including its use of human participants, was approved by a suitably constituted ethics committee. Informed consent was obtained from the patients for the purpose of inclusion in this study. All the completed procedures were done in accordance with the ethical standards of the responsible committees on human experimentation (institutional and national) and with the Helsinki Declaration of 1964 and its later amendments. This article does not contain any study with animal participants that was performed by any of the authors.

## ORCID

Hatsuki Hibi  <http://orcid.org/0000-0001-9579-7064>

Yoshimasa Asada  <http://orcid.org/0000-0002-0448-9953>

## REFERENCES

1. Jarow JP, Espeland M, Lipshultz LI. Evaluation of the azoospermic patient. *J Urol.* 1989;142:62-65.
2. Sharif K. Reclassification of azoospermia: the time has come? *Hum Reprod.* 2000;15:237-238.

3. Schlegel PN. Testicular sperm extraction: microdissection improves sperm yield with minimal tissue excision. *Hum Reprod.* 1999;14:131-135.
4. Ramos L, Kleingeld P, Meuleman E, et al. Assessment of DNA fragmentation of spermatozoa that were surgically retrieved from men with obstructive azoospermia. *Fertil Steril.* 2002;77:233-237.
5. O'Connell M, McClure N, Lewis SE. Mitochondrial DNA deletions and nuclear DNA fragmentation in testicular and epididymal human sperm. *Hum Reprod.* 2002;17:1565-1570.
6. Yamamoto M, Hibi H, Miyake K, Asada Y, Suganuma N, Tomoda Y. Microsurgical epididymal sperm aspiration versus epididymal micropuncture with perivascular nerve stimulation for intracytoplasmic sperm injection to treat unreconstructable obstructive azoospermia. *Arch Androl.* 1996;36:217-224.
7. Hibi H, Fukatsu H, Asada Y, Yamamoto M. Epididymal micropuncture. Our experience during the past seven years. *Jpn J Fertil Steril.* 2000;45:61-66.
8. Taniguchi H, Iwamoto T, Ichikawa T, et al. Contemporary outcomes of seminal tract re-anastomoses for obstructive azoospermia: a nationwide Japanese survey. *Int J Urol.* 2015;22:213-218.
9. Manning M, Junemann KP, Alken P. Decrease in testosterone blood concentrations after testicular sperm extraction for intracytoplasmic sperm injection in azoospermic men. *Lancet.* 1998;352:37.
10. Levine LA, Lisek EW. Successful sperm retrieval by percutaneous epididymal and testicular sperm aspiration. *J Urol.* 1998;159:437-440.
11. Belker AM, Sherins RJ, Dennison-Lagos L, Thorsell LP, Schulman JD. Percutaneous testicular sperm aspiration: a convenient and effective office procedure to retrieve sperm for in vitro fertilization with intracytoplasmic sperm injection. *J Urol.* 1998;160:2058-2062.
12. Schroeder-Printzen I, Zumbe J, Bispink L, et al. Microsurgical epididymal sperm aspiration: aspirate analysis and straws available after cryopreservation in patients with non-reconstructable obstructive azoospermia. *Hum Reprod.* 2000;15:2531-2535.
13. Bromage SJ, Falconer DA, Lieberman BA, Sangar V, Payne SR. Sperm retrieval rates in subgroups of primary azoospermic males. *Eur Urol.* 2007;51:534-540.
14. Buffat C, Patrat C, Merlet F, et al. ICSI outcomes in obstructive azoospermia: influence of the origin of surgically retrieved spermatozoa and the cause of obstruction. *Hum Reprod.* 2006;21:1018-1024.
15. Van W, Barbey N, Meissner A, Repping S, Silber SJ. Live birth rates after MESA or TESE in men with obstructive azoospermia: is there a difference?. *Hum Reprod.* 2015;30:761-766.
16. Janzen N, Goldstein M, Schlegel PN, Palermo GD, Rosenwaks Z. Use of electively cryopreserved microsurgically aspirated epididymal sperm with IVF and intracytoplasmic sperm injection for obstructive azoospermia. *Fertil Steril.* 2000;74:696-701.
17. Dozortsev D, Neme R, Diamond MP, et al. Embryos generated using testicular spermatozoa have higher developmental potential than those obtained using epididymal spermatozoa in men with obstructive azoospermia. *Fertil Steril.* 2006;86:606-611.
18. Nicopoullos JD, Gilling-Smith C, Almeida PA, Norman-Taylor J, Grace I, Ramsay JW. Use of surgical sperm retrieval in azoospermic men: a meta-analysis. *Fertil Steril.* 2004;82:691-701.

**How to cite this article:** Hibi H, Sumitomo M, Fukunaga N, Sonohara M, Asada Y. Superior clinical pregnancy rates after microsurgical epididymal sperm aspiration. *Reprod Med Biol.* 2018;17:59-63. <https://doi.org/10.1002/rmb2.12069>