

Ovarian Sertoli-Leydig Cell Tumor, Multinodular Goiter, Cystic Nephromas and *DICER1* Mutations: Case Report and Literature Review

Yanglin Ni¹
Xuan Zhou²
Ling Wu³
Ping Wu³
Ying Liu³
Yinnan Li³
Li Cai³
Xueshu Fu³
Chunhua Zhang³

¹Department of Gynaecology, Huai'an Hospital of Traditional Chinese Medicine, Huai'an, Jiangsu Province, People's Republic of China; ²MyGenostics Inc., Beijing, People's Republic of China; ³Department of Gynaecology, Huai'an Maternal and Child Health Hospital, Huai'an, Jiangsu Province, People's Republic of China

Correspondence: Chunhua Zhang
Department of Gynaecology, Huai'an Maternal and Child Health Hospital, Huai'an, Jiangsu Province, People's Republic of China
Tel +8613952326117
Email hafyzch@yeah.net

Introduction: *DICER1* syndrome is a rare tumor predisposition syndrome caused by germline *DICER1* mutation, which is related to a variety of benign and malignant diseases. Our report is the first described case of these three disease phenotypes of *DICER1* syndrome. The female patient with a novel germline *DICER1* nonsense mutation (c.1088_1089delCTinsAA p.F363X) in exon 8 that was inherited from her mother. In addition to germline *DICER1* mutation, two different hotspot somatic *DICER1* mutations were detected in her ovarian tissue and goiter tissue. Our report will expand the report of *DICER1* mutations in *DICER1*-syndrome-related diseases and provide case references for further research in the future.

Conclusion: When the related disease phenotype appears in childhood, it should be considered whether it is *DICER1* syndrome. Genetic testing can help diagnose *DICER1* syndrome and develop related surveillance strategies. Awareness of the *DICER1* syndrome may result in early recognition of these rare pediatric tumors and appropriate therapeutic management.

Keywords: case report, *DICER1*, Sertoli-Leydig cell tumor, multinodular goiter, cystic nephroma

Introduction

DICER1 syndrome is also known as pleuropulmonary blastoma family tumor susceptibility syndrome, shows a large spectrum of clinical phenotypes. Affected individuals are at increased risk of developing pleuropulmonary blastoma, cystic nephroma (CN), rhabdomyosarcoma, multinodular goiter (MNG), thyroid cancer, ovarian Sertoli-Leydig cell tumors (SLCTs), Wilms tumor, renal sarcoma, pineoblastoma, pituitary blastoma, and other neoplasia.¹⁻⁴ SLCTs are a rare type of sex-cord stromal tumors in the ovary.⁵ SLCTs have been classified into three histologic types by World Health Organization, that is well differentiated, moderately differentiated, and poorly differentiated, and almost all of the moderately and poorly differentiated tumors harbor *DICER1* mutation.⁶ MNG is a common disease characterized by nodular hyperplasia of the thyroid. MNG is also a frequent manifestation of *DICER1* syndrome.^{7,8} Individuals with *DICER1* mutations have 16–24 times the risk of developing thyroid cancer than the general population. Thyroid cancers associated with *DICER1* syndrome are usually follicular or papillary.⁹ CN is also called multilocular cystic nephroma, which is an uncommon benign renal neoplasm.^{10,11} CN associated with *DICER1* syndrome usually occurs in children



below 2 years of age.¹² Here we present a patient with a history of CN who was diagnosed with SLCT and MNG.

Patient Information

At 17 years of age, the patient came to the hospital due to a pelvic mass found on physical examination. Anal examination found that the right appendage touched a mass with medium texture and good mobility. Color Doppler ultrasound showed that the right ovary was unclear, and the pelvic cavity had mixed cystic and solid masses. MRI examination revealed a huge cystic solid mass in the pelvic cavity, measuring 10.48×8.31×12.92cm. She immediately underwent unilateral oophorectomy and subsequent histopathological examination detected showed ovarian sex cord stromal tumor, considering medium-low differentiated Sertoli-Leydig cell tumor (Figure 1).

Later, the patient was admitted to the hospital again with a history of thyroid sarcoidosis. The right lobe of the thyroid could palpate a mass of about 2*1.5cm in size. The

left lobe of the thyroid had no obvious mass. The lymph nodes in both necks were not significantly enlarged. Color Doppler ultrasound results showed that there were multiple isoechoic nodules in the two leaves. The largest nodule on the right was 2.22*1.57cm, and the largest size of the left nodule was 1.54*1.00cm. The results of the puncture pathological diagnosis suggested that the right lobe of the thyroid gland was suspected to be papillary thyroid carcinoma. Therefore, the patient was operated under anesthesia. Postoperative pathology showed: papillary carcinoma of the right thyroid lobe, bilobular multinodular goiter (Figure 2).

The patient had a previous medical history. A mass in the left upper abdomen was found when the patient was almost 2 years old. After neoadjuvant chemotherapy, she underwent left nephrectomy. Postoperative pathology revealed multilocular cystic nephroma in the left kidney.

Since the patient had multiple diseases, the clinician suspected a *DICER1* mutation. By using high-throughput

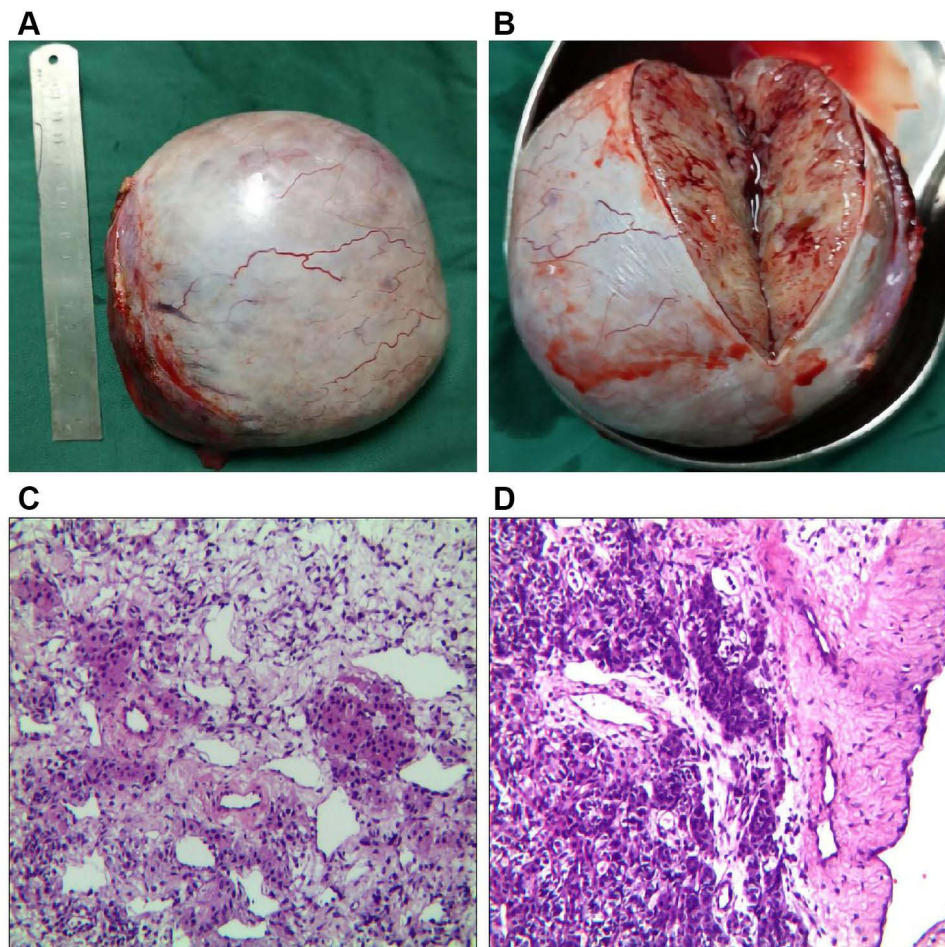


Figure 1 (A and B) Ovary and ovarian profile; (C and D) ovarian Sertoli-Leydig cell tumor of medium-low differentiation (HES ×400).

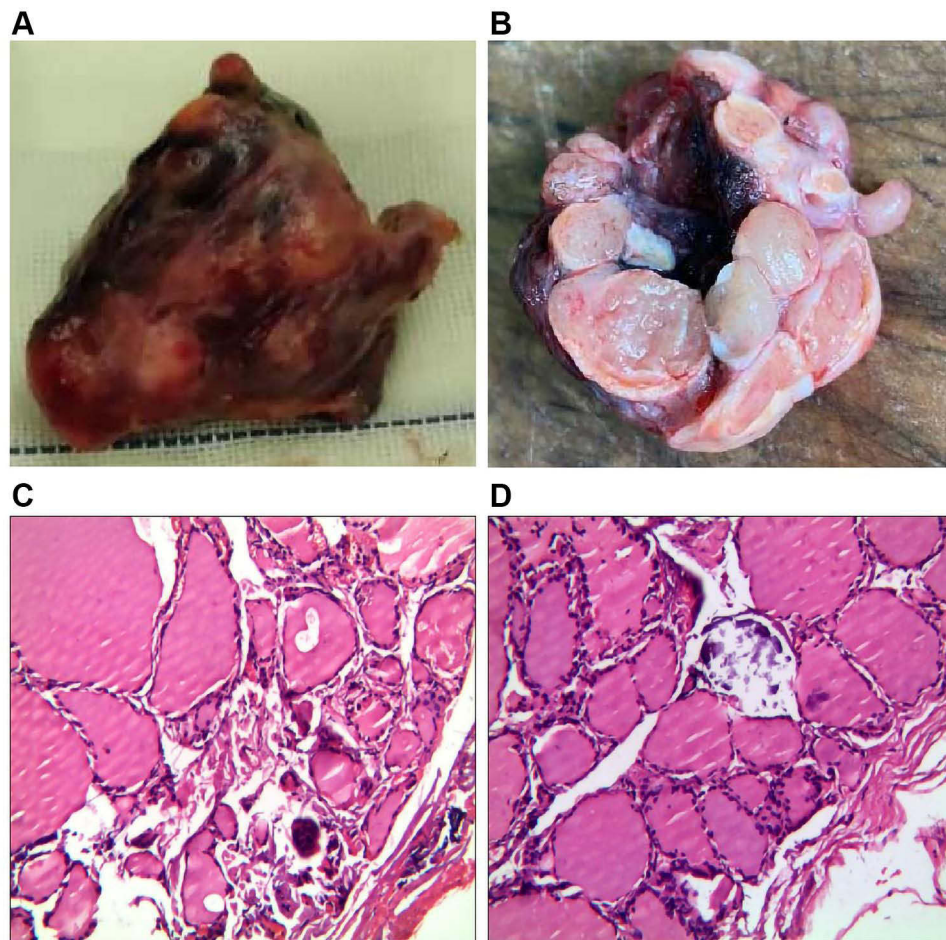


Figure 2 (A and B) Thyroid and thyroid profile; (C and D) multinodular goiter (HES $\times 400$).

target sequencing (MyGenostics, Beijing, China) of a panel of genes involved in tumor development, including entire coding region and the exon-intron boundaries of *DICER1*, we identified a heterozygous nonsense germline *DICER1* mutation (c.1088_1089delCTinsAA p.F363X). The mutation was confirmed by Sanger sequencing (Figure 3A). Sequencing revealed that her *DICER1* mutation was inherited from her mother (Figure 3B).

To further identify the genetic mutation profile, we performed whole-exome gene sequencing (MyGenostics, Beijing, China), using ovarian tumor tissue and thyroid tumor tissue as samples, and blood as the control. Molecular studies have revealed that these two lesions harbored distinct genetic mutations. Ovarian tissue revealed somatic mutation in *DICER1* missense mutation in the exon 25 (c.5428G>T p. D1810Y) with the variant allele frequency of 50% (Figure 3C), and thyroid tissue revealed somatic mutations in *DICER1* missense mutation in exon 24 (c.5126A>G p.D1709G) with the variant allele

frequency of 24% (Figure 3D). The two different somatic *DICER1* mutations were all located in the RNase IIIb domain of *DICER1* gene. Both of somatic mutations had been reported in previous studies.^{1,13,14}

Discussion

Germline mutations in *DICER1* are associated with *DICER1*-related disorders. Recent research shows that Mesenchymal hamartoma of the liver (MHL) is also a new phenotype of *DICER1* syndrome.¹⁵ However, our report is the first described case of a patient with a history of CN who was diagnosed with SLCT and MNG. Our case report adds evidence for the description of the phenotypes of *DICER1* syndrome. When there are later cases who were diagnosed with cystic nephroma at an early age, relevant genetic testing should be done as soon as possible to prevent other related diseases early.

Moreover, many cases report that ovarian SLCT and MNG can be associated with *DICER1* mutations (Table 1). The novel

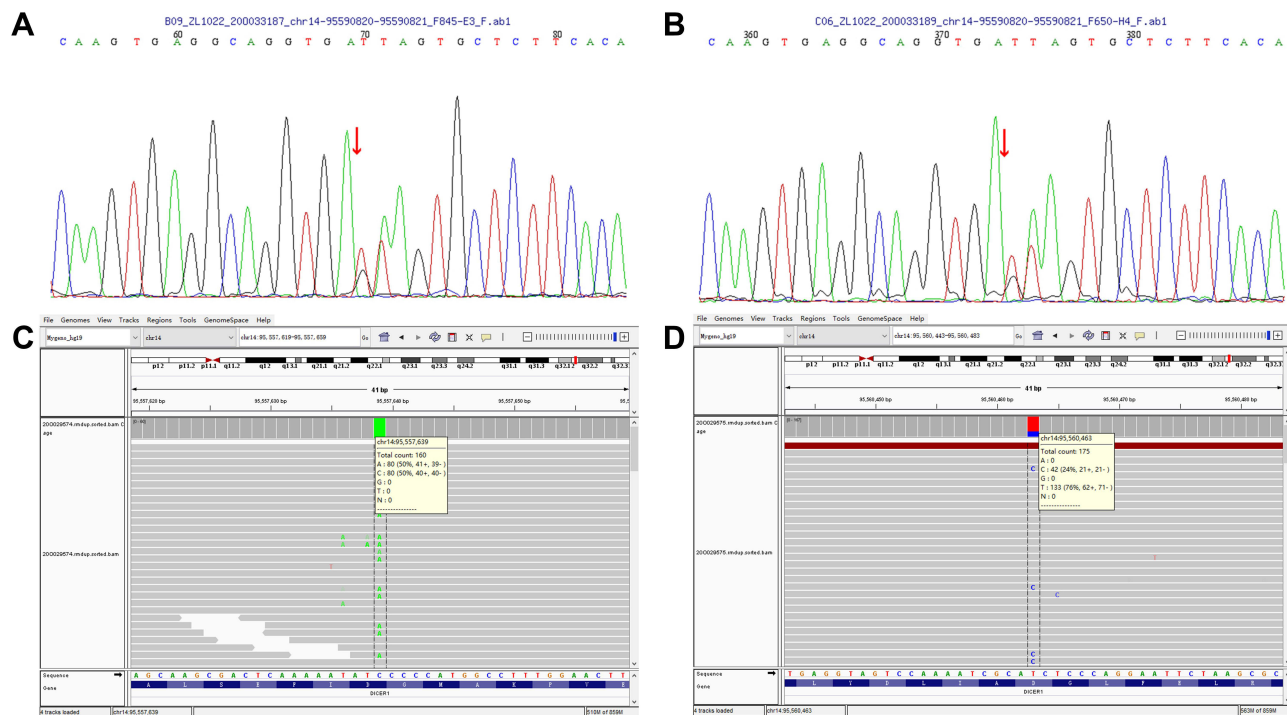


Figure 3 (A) Germline *DICER1* mutation (c.1088_1089delCTinsAA p.F363X) of the patient was confirmed by Sanger sequencing. (B) Germline *DICER1* mutation (c.1088_1089delCTinsAA p.F363X) of the patient's mother was confirmed by Sanger sequencing. (C) Somatic *DICER1* missense mutation in the exon 25 (c.5428G>T p.D1810Y) of Ovarian tissue. (D) Somatic *DICER1* missense mutation in exon 24 (c.5126A>G p.D1709G) of thyroid tissue.

nonsense mutation (c.1088_1089delCTinsAA p.F363X) identified in the present study resides in exon 8. According to previous studies, exon 8 of *DICER1* gene has a high frequency of disease-causing mutations. Bioinformatics prediction of pathogenicity by PolyPhen2 and MutationTaster state that c.1088_1089delCTinsAA is a possibly damaging mutation, may be the disease causing. The case in our study indicates relatively low penetrance of the *DICER1* c.1088_1089delCTinsAA mutation. At the time of our study, the patient's mother and mother's family members did not have any signs of tumors. The relatively low penetrance of some *DICER1* mutations has also been reported in other studies.³ Hence, it is necessary to conduct clinical follow-up studies in patients who harbor pathogenic *DICER1* mutations with or without tumorous diseases. Once a disease-causing mutation in the *DICER1* gene is found in a family member, it is recommended that relatives of all ages undergo genetic testing to provide screening recommendations for relatives with inherited disease-causing mutations for their age.⁴

Somatic mutations of *DICER1* exist in the tumors of many of the patients who harbor germline mutations in this gene. Somatic mutations that affect the metal-binding sites of the RNase IIIb domain are called "hotspots".^{1,13,14,16} Hotspot somatic mutations (D1709G and D1810Y) were

also detected in our case. Tumor cells with *DICER1* hotspot mutations often have loss of function defects in the other allele due to germline or other somatic events. And it is also indicating a "two-hit" tumor-suppressive model of *DICER1*. However, unlike classic "two-hit" models, these second "hits" of *DICER1* mutations generate a partially functional allele.^{13,16,17}

Recognizing *DICER1* syndrome has important clinical significance for patients and their family members and potential offspring, especially if cystic nephroma is found in very early childhood, more attention should be paid. In addition, few clinicians combine the rare SLCT with the more common MNG, more understanding and attention of co-occurrence of SLCT and MNG should be improved in the future. Clinicians should be alert to the existence of *DICER1* mutations in these related diseases. Awareness of the *DICER1* syndrome may result in early recognition of these rare pediatric tumors and appropriate therapeutic management.

Informed Consent

We have obtained the consent from the patient and patient's parents. We also obtained the consent to publish the case details and accompanying images. No institutional approval is required to publish case details.

Table I Published Cases of SLCT+MNG with DICER1 Mutations

Study	Date	Age at Diagnosis of SLCT	Age at Diagnosis of MGN (or Thyroid Cancer)	Germline <i>DICER1</i> Mutation	Somatic <i>DICER1</i> Mutation
Jensen et al ¹⁸	1974	Mother: 13 yrs Daughter: 18 yrs	Mother: 13 yrs Daughter: 17 yrs	Unknown	Unknown
O'Brien and Wilansky ¹⁹	1981	18 yrs	16 yrs	Unknown	Unknown
Young and Scully ²⁰	1985	1 case, age not stated	Age not stated	Unknown	Unknown
Niedziela ²¹	2008	14 yrs	13 yrs	Unknown	Unknown
Rio Frio et al (Family C) ⁸	2011	32 yrs	18 yrs	c.5018_5021delTCAA	Unknown
Slade et al (Family 17) ²²	2011	12 yrs	9 yrs	c.2988-2_2988-1delAGinsCT	Unknown
Foulkes et al (Family 6) ²³	2011	9 yrs	20 yrs	c.4050+1delG	Unknown
Ramasubramanian et al ²⁴	2013	Before 16 yrs	Before 16 yrs	Unknown	Unknown
Darrat et al ²⁵	2013	Sibling 2: SLCT (left), 8 yrs SLCT (right), 14 yrs	14 yrs	c.1525C>T	Unknown
Schultz et al ²⁶	2014	13 yrs	Follicular variant of papillary thyroid Carcinoma, 8 yrs	c.1376 + 1G> A	c.5438 A>T in thyroid carcinoma; c.5439G>T (exon 25) in SLCT
Wu et al ²⁷	2014	16 yrs	14 yrs	c.3540C > A and c.4206 +8insTT	Unknown
Rossing et al ³	2014	13 yrs	13 yrs	c.3647C> A and c.3649T> A	Unknown
de Kock et al ²⁸	2016	SLCT (left), 13.4 yrs; SLCT (right), 15.7 yrs	Follicular variant of papillary thyroid Carcinoma, 10.6 yrs	c.5437G>C	c.4626-4626delG in SLCT (left)
Durieux et al ²⁹	2016	Case 1:17 yrs; Case 2:15 yrs	Case 1:Follicular variant of papillary thyroid carcinoma, 18 yrs; Case 2: Follicular variant of papillary thyroid carcinoma, 12 yrs	Unknown	Case 1: c.5113G>A in SLCT; Case 2: c.5125G>A in SLCT; c.5437G>C in thyroid carcinoma in both cases
Moke et al ³⁰	2018	13 yrs	Follicular variant of papillary thyroid carcinoma, 13 yrs	c.5504_5507delATCC	c.5439G> T in SLCT; c.5113G> A in thyroid carcinoma

(Continued)

Table I (Continued).

Study	Date	Age at Diagnosis of SLCT	Age at Diagnosis of MGN (or Thyroid Cancer)	Germline <i>DICER1</i> Mutation	Somatic <i>DICER1</i> Mutation
Apellaniz-Ruiz et al ⁷	2018	Proband:13 yrs	Proband:15 yrs	c.4207-41_5364 +1034del	c.5437G>C in SLCT;c.5113G>C, and c.5114A>T in MGN
Cowan et al ³¹	2018	After 17 yrs	12 yrs	c.904-1G > C	c.5425G > A in SLCT
Chen et al ³²	2018	15 yrs	Thyroid follicular adenoma, 12 yrs	c.3307_3311delGACAG	c.5439G>T in SLCT (left); c.5439G>C in SLCT (right); c.5439G>T in thyroid follicular adenoma
Haley et al ⁹	2019	Mother: 38 yrs	Age not stated	c.325C> T	Unknown
Zhang et al ³³	2020	Proband:21 yrs	Proband:20 yrs	Unknown	c.5113G> A and c.2403C> A in SLCT

Acknowledgments

The authors thank the technical assistance in genetic analysis from MyGenostics Inc.

Disclosure

The authors report no conflicts of interest in this work.

References

- Witkowski L, Mattina J, Schönberger S, et al. *DICER1* hotspot mutations in non-epithelial gonadal tumours. *Br J Cancer*. 2013;109(10):2744–2750. doi:10.1038/bjc.2013.637
- Bahubeshi A, Tischkowitz M, Foulkes WD. miRNA processing and human cancer: *DICER1* cuts the mustard. *Sci Transl Med*. 2011;3(111):111ps146. doi:10.1126/scitranslmed.3002493
- Rossing M, Gerdes AM, Juul A, et al. A novel *DICER1* mutation identified in a female with ovarian Sertoli-Leydig cell tumor and multinodular goiter: a case report. *J Med Case Rep*. 2014;8:112. doi:10.1186/1752-1947-8-112
- Schultz KAP, Williams GM, Kamihara J, et al. *DICER1* and associated conditions: identification of at-risk individuals and recommended surveillance strategies. *Clin Cancer Res*. 2018;24(10):2251–2261. doi:10.1158/1078-0432.CCR-17-3089
- Lantzsch T, Stoerer S, Lawrenz K, Buchmann J, Strauss HG, Koelbl H. Sertoli-Leydig cell tumor. *Arch Gynecol Obstet*. 2001;264(4):206–208. doi:10.1007/s004040000114
- de Kock L, Terzic T, McCluggage WG, et al. *DICER1* mutations are consistently present in moderately and poorly differentiated Sertoli-Leydig cell tumors. *Am J Surg Pathol*. 2017;41(9):1178–1187. doi:10.1097/PAS.0000000000000895
- Apellaniz-Ruiz M, de Kock L, Sabbaghian N, et al. Familial multinodular goiter and Sertoli-Leydig cell tumors associated with a large intragenic in-frame *DICER1* deletion. *Eur J Endocrinol*. 2018;178(2):K11–k19. doi:10.1530/EJE-17-0904
- Rio Frio T, Bahubeshi A, Kanellopoulou C, et al. *DICER1* mutations in familial multinodular goiter with and without ovarian Sertoli-Leydig cell tumors. *JAMA*. 2011;305(1):68–77. doi:10.1001/jama.2010.1910
- Haley M, Bindal P, McAuliffe A, Vredenburg J. A family with Sertoli-Leydig cell tumour, multinodular goiter, and *DICER1* mutation. *Curr Oncol*. 2019;26(3):183–185. doi:10.3747/co.26.4727
- Kurian JJ, Sen S, Joseph RT, Bindra MS. A rare case of bilateral cystic nephroma associated with embryonal rhabdomyosarcoma of the penile urethra. *J Indian Assoc Pediatr Surg*. 2015;20(2):82–83. doi:10.4103/0971-9261.151553
- Stamatiou K, Polizois K, Kollaitis G, et al. Cystic nephroma: a case report and review of the literature. *Cases J*. 2008;1(1):267. doi:10.1186/1757-1626-1-267
- Bahubeshi A, Bal N, Rio Frio T, et al. Germline *DICER1* mutations and familial cystic nephroma. *J Med Genet*. 2010;47(12):863–866. doi:10.1136/jmg.2010.081216
- Heravi-Moussavi A, Anglesio MS, Cheng SW, et al. Recurrent somatic *DICER1* mutations in nonepithelial ovarian cancers. *N Engl J Med*. 2012;366(3):234–242.
- Doros LA, Rossi CT, Yang J, et al. *DICER1* mutations in childhood cystic nephroma and its relationship to *DICER1*-renal sarcoma. *Mod Pathol*. 2014;27(9):1267–1280. doi:10.1038/modpathol.2013.242
- Apellaniz-Ruiz M, Segni M, Kettwig M, et al. Mesenchymal hamartoma of the liver and *DICER1* syndrome. *N Engl J Med*. 2019;380(19):1834–1842. doi:10.1056/NEJMoa1812169
- Anglesio MS, Wang Y, Yang W, et al. Cancer-associated somatic *DICER1* hotspot mutations cause defective miRNA processing and reverse-strand expression bias to predominantly mature 3p strands through loss of 5p strand cleavage. *J Pathol*. 2013;229(3):400–409. doi:10.1002/path.4135
- Wang Y, Chen J, Yang W, et al. The oncogenic roles of *DICER1* RNase IIIb domain mutations in ovarian Sertoli-Leydig cell tumors. *Neoplasia*. 2015;17(8):650–660. doi:10.1016/j.neo.2015.08.003
- Jensen RD, Norris HJ, Fraumeni JF Jr. Familial arrhenoblastoma and thyroid adenoma. *Cancer*. 1974;33(1):218–223. doi:10.1002/1097-0142(197401)33:1<218::AID-CNCR2820330132>3.0.CO;2-Z
- O'Brien PK, Wilansky DL. Familial thyroid nodulation and arrhenoblastoma. *Am J Clin Pathol*. 1981;75(4):578–581. doi:10.1093/ajcp/75.4.578
- Young RH, Scully RE. Ovarian Sertoli-Leydig cell tumors. A clinicopathological analysis of 207 cases. *Am J Surg Pathol*. 1985;9(8):543–569. doi:10.1097/0000478-198508000-00001

21. Niedziela M. Virilizing ovarian tumor in a 14-year-old female with a prior familial multinodular goiter. *Pediatr Blood Cancer*. 2008;51(4):543–545. doi:10.1002/pbc.21675
22. Slade I, Bacchelli C, Davies H, et al. DICER1 syndrome: clarifying the diagnosis, clinical features and management implications of a pleiotropic tumour predisposition syndrome. *J Med Genet*. 2011;48(4):273–278. doi:10.1136/jmg.2010.083790
23. Foulkes WD, Bahubeshi A, Hamel N, et al. Extending the phenotypes associated with DICER1 mutations. *Hum Mutat*. 2011;32(12):1381–1384. doi:10.1002/humu.21600
24. Ramasubramanian A, Correa ZM, Augsburger JJ, Sisk RA, Plager DA. Medulloepithelioma in DICER1 syndrome treated with resection. *Eye*. 2013;27(7):896–897. doi:10.1038/eye.2013.87
25. Darrat I, Bedoyan JK, Chen M, Schuette JL, Lesperance MM. Novel DICER1 mutation as cause of multinodular goiter in children. *Head Neck*. 2013;35(12):E369–371. doi:10.1002/hed.23250
26. Schultz KA, Yang J, Doros L, et al. DICER1-pleuropulmonary blastoma familial tumor predisposition syndrome: a unique constellation of neoplastic conditions. *Pathol Case Rev*. 2014;19(2):90–100. doi:10.1097/PCR.0000000000000027
27. Wu Y, Chen D, Li Y, Bian L, Ma T, Xie M. DICER1 mutations in a patient with an ovarian Sertoli-Leydig tumor, well-differentiated fetal adenocarcinoma of the lung, and familial multinodular goiter. *Eur J Med Genet*. 2014;57(11–12):621–625. doi:10.1016/j.ejmg.2014.09.008
28. de Kock L, Wang YC, Revil T, et al. High-sensitivity sequencing reveals multi-organ somatic mosaicism causing DICER1 syndrome. *J Med Genet*. 2016;53(1):43–52. doi:10.1136/jmedgenet-2015-103428
29. Durieux E, Descotes F, Mauduit C, Decaussin M, Guyetant S, Devouassoux-Shisheboran M. The co-occurrence of an ovarian Sertoli-Leydig cell tumor with a thyroid carcinoma is highly suggestive of a DICER1 syndrome. *Virchows Arch*. 2016;468(5):631–636. doi:10.1007/s00428-016-1922-0
30. Moke DJ, Thomas SM, Hiemenz MC, et al. Three synchronous malignancies in a patient with DICER1 syndrome. *Eur J Cancer*. 2018;93:140–143. doi:10.1016/j.ejca.2017.12.021
31. Cowan M, Suntum T, Olivas AD, et al. Second primary rhabdomyosarcoma of the uterine cervix presenting with synchronous ovarian Sertoli-Leydig cell tumor: an illustrative case of DICER1 syndrome. *Gynecol Oncol Rep*. 2018;25:94–97. doi:10.1016/j.gore.2018.06.008
32. Chen KS, Stuart SH, Stroup EK, et al. Distinct DICER1 hotspot mutations identify bilateral tumors as separate events. *JCO Precis Oncol*. 2018;2. doi:10.1200/PO.17.00113
33. Zhang Y, Ren M, Hong Y, et al. Sertoli-Leydig cell tumor in two siblings with DICER1 syndrome: a case report and literature review. *Medicine*. 2020;99(27):e20806. doi:10.1097/MD.00000000000020806

Pharmacogenomics and Personalized Medicine

Dovepress

Publish your work in this journal

Pharmacogenomics and Personalized Medicine is an international, peer-reviewed, open access journal characterizing the influence of genotype on pharmacology leading to the development of personalized treatment programs and individualized drug selection for improved safety, efficacy and sustainability. This journal is indexed

on the American Chemical Society's Chemical Abstracts Service (CAS). The manuscript management system is completely online and includes a very quick and fair peer-review system, which is all easy to use. Visit <http://www.dovepress.com/testimonials.php> to read real quotes from published authors.

Submit your manuscript here: <https://www.dovepress.com/pharmacogenomics-and-personalized-medicine-journal>