


# Undifferentiated pleomorphic sarcoma in oropharyngeal mucosa of patients with multiple basal cell carcinomas

Rare Tumors  
Volume 13: 1–4  
© The Author(s) 2021  
Article reuse guidelines:  
sagepub.com/journals-permissions  
DOI: 10.1177/20363613211026483  
journals.sagepub.com/home/rtu  


Andrea Dekanić<sup>1</sup> , Marko Velepić<sup>2</sup>, Margita Belušić Gobić<sup>3</sup>,  
Ita Hadžisejdić<sup>4</sup>  and Nives Jonjić<sup>4</sup>

## Abstract

Malignant mesenchymal tumors of oropharyngeal mucosa are rare. Those with fibroblastic and histiocytic differentiation in the skin are called atypical fibroxanthoma (AFX) and in the soft tissue undifferentiated pleomorphic sarcoma (UPS). Here we present a case of an older patient with a history of multiple basal cell carcinomas and recently with a rapidly growing polypoid lesion in the mucosa of posterior oropharyngeal wall with AFX/UPS morphology. The differential diagnosis, histological pitfalls of this poorly characterized mesenchymal lesions, and the challenges associated with treatment are discussed.

## Keywords

Differential diagnosis, KRAS, malignant fibrohistiocytic tumor, NRAS, oropharynx neoplasm

Date received: 23 December 2020; accepted: 1 June 2021

## Introduction

Atypical fibroxanthoma (AFX) is a rare primary skin tumor first reported by Helwing<sup>1</sup> in the early 1960s, as a neoplasm with relatively well-defined infiltration of the dermis by neoplastic cell of fibroblastic origin that had transformed into a histiocytic cell type. Today it is described as a solitary, localized skin nodule as large as 2 cm that typically occurs in UV-damaged skin, especially in the head and neck region of elderly individuals. The histology of AFX is like that of a high-grade sarcoma, typically highly cellular with nuclear hyperchromasia and pleomorphism. Mitotic figures, including abnormal forms, are common.<sup>2</sup> In the past, tumors with the same morphology occurring in the soft tissue were termed as malignant fibro histiocytoma (MFH) and AFX was viewed as a superficial variant of MFH.<sup>3</sup> In 1992 it was suggested that MFH represents a variety of poorly differentiated malignant mesenchymal neoplasms that can be classified, according to immunohistochemistry and electron microscopy, in liposarcoma, leiomyosarcoma or rhabdomyosarcoma, while a small

number that were previously termed MFH are now classified as undifferentiated pleomorphic sarcoma (UPS).<sup>4</sup>

UPS in contrast to AFX in spite of identical histology, is a high-grade sarcoma of soft tissue that is anatomically ubiquitous and occurs in all ages with no difference between the sexes.<sup>5</sup> In the skin, UPS is usually poorly delineated with diffuse infiltration of the subcutis and deeper structures, while AFX has superficial location, in the dermis, without

<sup>1</sup>University of Rijeka Faculty of Medicine, Rijeka, Croatia

<sup>2</sup>Clinic for Otorhinolaryngology, Clinical Hospital Center Rijeka, Rijeka, Croatia

<sup>3</sup>Clinic for Maxillofacial Surgery, Clinical Hospital Center Rijeka, Rijeka, Croatia

<sup>4</sup>Department of Pathology and Cytology, Clinical Hospital Center Rijeka, Rijeka, Croatia

## Corresponding author:

Andrea Dekanić, University of Rijeka Faculty of Medicine, Braće Brancetta 20, Rijeka 51000, Croatia.  
Email: andrea.dekanic@uniri.hr



significant subcutaneous infiltration and thus behaves differently from UPS. AXF has a more favorable prognosis, with local recurrence but no tendency to metastasize (in contrast with UPS that has an aggressive behavior).<sup>6</sup>

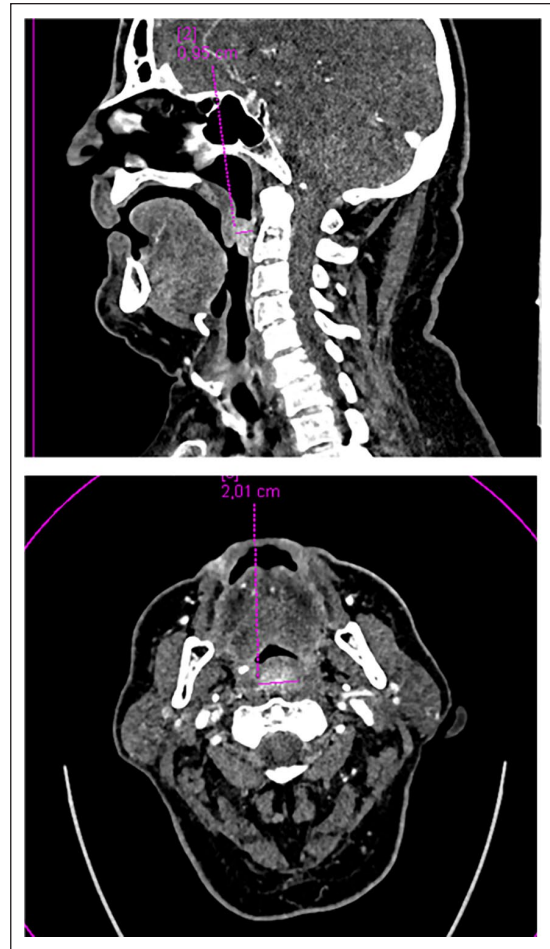We present a case of an 83-year-old man with the history of multiple skin basal cell carcinomas (BCCs), and recently with the polypoid lesion of AFX/UPS morphology in the mucosa of posterior oropharyngeal wall. The case is of interest since this tumor occurs very rarely in mucosa and diagnosis without immunohistochemical analysis can be difficult. In addition, it highlights the problem of recommendation of an adequate treatment strategy for this tumor with superficial location like AFX, a low-grade sarcoma, and aggressive morphology like UPS, a high-grade sarcoma.

### Case report

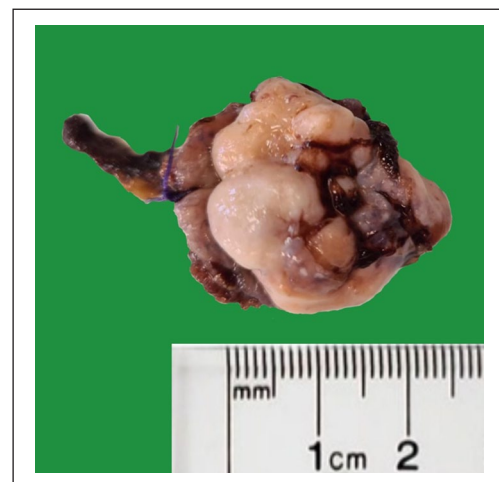
An 83-year-old male had a medical history of multiple skin cancer, BCCs in several sites, mostly head and neck during a period of 9 years. The patient presented with odynophagia and dysphagia at the Department of Otorhinolaryngology. The symptoms had started progressively 1 month earlier. Oropharyngoscopically, an exophytic mass about 2 cm in diameter lied on the entire posterior oropharynx wall, protruding above the soft palate. Fiber optic nasopharyngoscopy revealed the mass reaching the level of the hard palate. No lymphadenopathy was noted.

Computer tomography scan was made. Nodal lesion in the posterior part of the oropharynx, measuring 21 mm × 9 mm × 20 mm (CC × AP × LL) was seen. No signs of infiltration to prevertebral tissue nor progression to parapharyngeal or retropharyngeal space were seen (Figure 1). There was no pathological neck lymphadenopathy. Neck ultrasound was normal. The patient was admitted to hospital. The tumor was fully excised in general anesthesia. The postoperative period was without complications. The patient started normal feeding after 10 days and the wound site epithelized well.

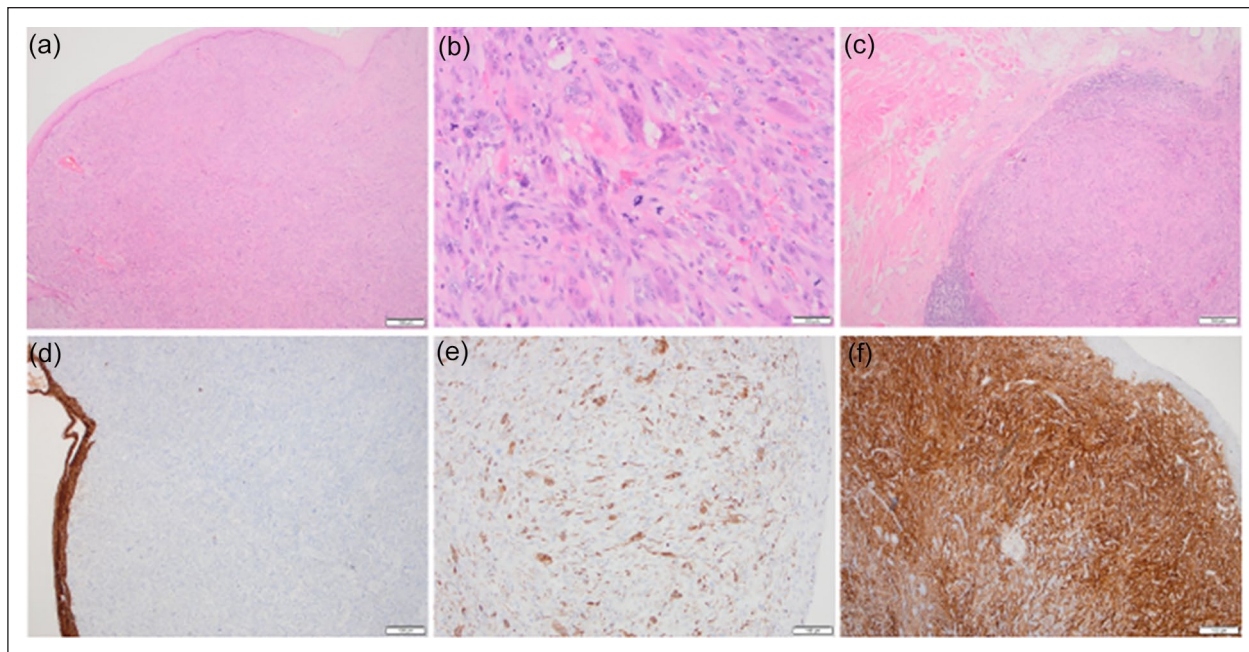
Macroscopic examination of the excised tissue revealed a mucosal sample with ulcerative nodule, measuring 2.5 cm × 2 cm × 1 cm (Figure 2). The histological sections showed a polypoid, non-encapsulated, well circumscribed mucosal lesion composed of pleomorphic spindle shaped cells with hyperchromatic nuclei and abundant cytoplasm and the histiocyte-like cells, commonly arranged in a spindle cell pattern. Multinucleated giant tumor cells and atypical mitotic figures were scattered. The appearance was consistent with a malignant lesion of differential diagnosis. Additional immunohistochemical analysis with panCK (AE1/AE3), CK5/6, p63, S-100, Vimentin, SMA, Calponine, CD10, CD68, CD99, and BCL2 were done. The tumor was strongly diffuse positive for Vimentin and CD10, focally positive for CD68, CD99, and Bcl-2, and negative for all other markers (Figure 3). A diagnosis of soft tissue sarcoma



**Figure 1.** CT Imaging of oropharyngeal area. Well-limited formation along the posterior part of the oropharynx, behind the uvula from which it is inseparable, measuring 21 mm × 9 mm × 20 mm. No signs of infiltration and penetration through the oropharyngeal wall are seen.



**Figure 2.** Gross pathological sample of tumor. Elevated, partially ulcerated nodule, approximately 2 cm in diameter, in the mucosa of 83-year-old man.



**Figure 3.** Microscopic pathological slides of tumor. Undifferentiated pleomorphic sarcoma in oropharyngeal mucosa of an 83 year-old man. Elevated nodule composed of pleomorphic, mostly spindle-shaped cells with some intervening collagen covered with normal squamous epithelium (a). On higher magnification a polymorphic cells, an atypical epitheloid tumor cells with large, vesicular, and hyperchromatic nuclei, with atypical mitosis and occasional tumor multinuclear giant cells (b). Well delineated nodule on the base of tumor in lamina propria with sparing the muscular layer (c). By immunohistochemistry tumor cells were negative with epithelia marker (pan cytokeratin, AE1/AE3) (d), focally positive with CD68 (e), and strongly positive for CD10 (f).

of AFX/UPS morphology was made. Additional molecular analyses excluded K- and N-ras mutation.

## Discussion

Present case describes a rapidly growing oropharyngeal mucosal exophytic nodule in an elderly patient with a history of multiple skin BCCs. The differential diagnosis of lesion included poorly differentiated squamous cell carcinoma (SCC) and sarcoma. In order to establish the diagnosis, immunohistochemical analysis was required. Vimentin, CD68, CD10, and CD99 were positive, while CK (AE1-AE3) showed an intact mucosal surface. Immunohistochemistry confirmed the diagnosis of soft tissue sarcoma with AFX/UPS morphology.<sup>7-9</sup> Soft tissue sarcomas mainly arise in the extremities and trunk, and only 5%–20% of them arise in the head and neck.<sup>10</sup> According to literature data, the most common soft tissue sarcoma in the head and neck area is rhabdomyosarcoma, followed by UPS, fibrosarcoma and neurogenic sarcoma.<sup>11</sup> Therefore, recently there are several reports of UPS in buccal mucosa,<sup>12</sup> gingiva,<sup>13</sup> and mandible with pathological fracture,<sup>14</sup> and one case of AFX in the mucosa of the floor of mouth in a patient after squamous cell carcinoma, treated with radiotherapy.<sup>15</sup> The lesion in the last case was superficial with a malignant, histiocytic morphology, thus a diagnosis of AFX to those authors seemed more appropriate than UPS.

In spite of virtually identical histological and immunohistochemical findings, AFX and UPS differ clinically. AFX in the skin is characterized by a benign clinical course and extremely rare metastasis, although such cases were reported,<sup>16</sup> while UPS has a more aggressive clinical course and a higher frequency of metastasis.<sup>5</sup> Those tumors also show difference in their genetic alteration that might contribute to their different biological behavior. On the other side, similarities in genetic alteration on chromosome 9p and 13q might suggest a common pathogenetic pathway.<sup>17</sup> There are few studies of DNA analysis of AFX and UPS of the skin. Ras mutation in the H-ras gene (codon 12) and K-ras gene (codon 13) was found in some UPS cases but not in AFX. The authors presume that the absence of H-, K-, and N-ras mutation in AFX may be the reason for a more favorable behavior than UPS.<sup>18</sup>

In literature we found two cases of collision skin tumor with BCC and AFX morphology,<sup>19,20</sup> but according to our knowledge, this is the first case of mucosal UPS in a patient associated with multiple BCCs. Basal cell carcinoma is the most common malignant skin tumor with multifactorial causes. Ultraviolet radiation exposures, genetic alteration, mutation of tumor suppressor genes are known to be the most significant etiological factors for multiple BCCs, as well as for AFX.<sup>21</sup>

As mentioned, in skin biopsy AFX does not histologically differ from UPS. Nevertheless, some authors presume



that tumors with a diameter more than 2 cm, with involvement of the (deep) subcutis or even deeper structures or with necrosis or vascular or perineural invasion should be diagnosed as UPS.<sup>6,19</sup>

UPS of oral region is usually treated by radical surgical resection since it is an aggressive tumor, with local recurrence in 44%, distant metastasis in 42%, and with 5-year survival no more than 30%.<sup>13</sup> On the other hand, when adequately treated with a safety margin, AFX has an excellent prognosis, but long-term follow-up is recommended due to the potential for aggressive behavior.<sup>8</sup> The problem of adequate treatment in such cases can be resolved in collaboration with an experienced head and neck surgeon, medical oncologist, pathologist, and radiation oncologist.

### Contributorship

The authors gave their intellectual and practical contribution.

### Declaration of conflicting interest

The author(s) declared no potential conflicts of interest with respect to the research, authorship, and/or publication of this article.

### Funding

The author(s) received no financial support for the research, authorship, and/or publication of this article.

### Ethics approval

Our institution does not require ethical approval for reporting individual cases or case series.

### Informed consent

Written informed consent was obtained from the patient(s) for their anonymized information to be published in this article.

### ORCID iDs

Andrea Dekanić  <https://orcid.org/0000-0003-0625-7483>

Ita Hadžisejdić  <https://orcid.org/0000-0003-1800-3552>

### References

1. Helwing EB. Atypical fibroxanthoma. *Tex J Med* 1963; 59: 664–667.
2. Elder DE, Massi D, Scolyer RA, et al. *WHO classification of skin tumours*. France: Lyon, 2018, p. 368.
3. Kempson RL and McGavran MH. Atypical fibroxanthoma of the skin. *Cancer* 1964; 17: 1463–1471.
4. Fletcher CD. Pleomorphic malignant fibrous histiocytoma: fact or fiction? A critical reappraisal based on 159 tumours diagnosed as pleomorphic sarcoma. *Am J Surg Pathol* 1992; 16(3): 213–228.
5. Fletcher CDM, Bridge JA, Hogendoorn PCW, et al. *WHO classification of tumours of soft tissue and bone*. Lyon, France, 2013, p. 236.
6. Ziemer M. Atypical fibroxanthoma. *J Dtsch Dermatol Ges* 2012; 10: 537–550.
7. Scolyer RA, Murali R, McCarthy SW, et al. Atypical fibroxanthoma: differential diagnosis from other sarcomatoid skin lesions. *Diagn Histopathol* 2010; 16(9): 401–408.
8. Koch M, Freundl AJ, Agaimy A, et al. Atypical fibroxanthoma – histological diagnosis, immunohistochemical markers and concepts of therapy. *Anticancer Res* 2015; 35: 5717–5736.
9. Lopez L and Velez R. Atypical fibroxanthoma. *Arch Pathol Lab Med* 2016; 140: 376–379.
10. Pandey M, Thomas G, Mathew A, et al. Sarcoma of the oral and maxillofacial soft tissue in adults. *Eur J Surg Oncol* 2000; 26: 145–148.
11. Weber RS, Benjamin RS, Peters LJ, et al. Soft tissue sarcoma of the head and neck in adolescent and adults. *Am J Surg* 1986; 152: 386–392.
12. Balaji SM. Malignant fibrous histiocytoma – case report. *J Maxillofac Oral Surg* 2010; 9(3): 292–296.
13. Vijayalakshmi D, Fathima S, Ramakrishnan K, et al. Malignant fibrous histiocytoma of the gingiva. *BMJ Case Rep* 2012; 1–4.
14. Lambade PN, Lambade D, Saha TK, et al. Malignant fibrous histiocytoma: an uncommon sarcoma with pathological fracture of mandibular. *J Maxillofac Oral Surg* 2015; 14(1): S283–S287.
15. High AS, Hume WJ and Dyson D. Atypical fibroxanthoma of oral mucosa: a variant of malignant fibrous histiocytoma. *Br J Oral Maxillofacial Surg* 1990; 28: 268–271.
16. Nergard J, Glener J, Reimer D, et al. Atypical fibroxanthoma of the scalp with recurrent and multiple regional cutaneous metastases. *JAAD Case Rep* 2016; 2(6): 491–493.
17. Mihic-Prost D, Zhao J, Saremaslani P, et al. CHG analysis shows genetic similarities and differences in atypical fibroxanthoma and undifferentiated high grade pleomorphic sarcoma. *Anticancer Res* 2004; 24: 19–26.
18. Sakamoto A, Oda Y, Itakura E, et al. H-, K-, and N-ras gene mutation in atypical fibroxanthoma and malignant fibrous histiocytoma. *Hum Pathol* 2001; 32(11): 1225–1231.
19. Alves R, Ocana J, Vale E, et al. Basal cell carcinoma and atypical fibroxanthomas: an unusual collision tumor. *J Am Acad Dermatol* 2010; 63(3): e74–e76.
20. Speiser JJ, Aggarwal S, Wold L, et al. A rare collision in dermatopathology: basal cell carcinoma and atypical fibroxanthoma. *Am J Dermatopathol* 2015; 37(12): 950–953.
21. Dei Tos AP, Maestro R, Doglioni C, et al. Ultraviolet-induced p53 mutations in atypical fibroxanthoma. *Am J Pathol* 1994; 145(1): 11–17.