

Case Report

Heterotopia or overlying cortex: What about in-between?

Emilija Cvetkovska^{a,b,*}, William Alves Martins^{a,c}, Jorge Gonzalez-Martinez^{a,d}, Ken Taylor^a, Jian Li^e, Olesya Grinenko^a, John Mosher^{a,f}, Richard Leahy^e, Patrick Chauvel^a, Dileep Nair^a

^a Epilepsy Center, Cleveland Clinic Foundation, 9500 Euclid Avenue, Cleveland, OH 44195, USA

^b University Clinic of Neurology, Medical Faculty, Ss. Cyril and Methodius University, Vodnjanska str. 17, MK-1000, Skopje, Macedonia

^c Service of Neurology, Hospital São Lucas, Pontifícia Universidade Católica do Rio Grande do Sul (PUCRS), Porto Alegre, Brazil

^d Department of Neurosurgery, Cleveland Clinic Foundation, 9500 Euclid Avenue, Cleveland, OH 44195, USA

^e Signal and Image Processing Institute, University of Southern California, Los Angeles, CA, USA

^f Department of Neurology, University of Texas, Huston, TX, USA



ARTICLE INFO

Article history:

Received 3 June 2018

Received in revised form 12 September 2018

Accepted 19 September 2018

Available online 9 October 2018

Keywords:

Periventricular nodular heterotopia

Stereo-EEG

Epileptogenicity

ABSTRACT

We describe a patient with unilateral periventricular nodular heterotopia (PNH) and drug-resistant epilepsy, whose SEEG revealed that seizures were arising from the PNH, with the almost simultaneous involvement of heterotopic neurons (“micronodules”) scattered within the white matter, and subsequently the overlying cortex. Laser ablation of heterotopic nodules and the adjacent white matter rendered the patient seizure free.

This case elucidates that “micronodules” scattered in white matter between heterotopic nodules and overlying cortex might be another contributor in complex epileptogenicity of heterotopia. Detecting patient-specific targets in the epileptic network of heterotopia creates the possibility to disrupt the pathological circuit by minimally invasive procedures.

© 2018 The Authors. Published by Elsevier Inc. This is an open access article under the CC BY-NC-ND license (<http://creativecommons.org/licenses/by-nc-nd/4.0/>).

1. Introduction

Periventricular nodular heterotopia (PNH) is a malformation of neuronal migration characterized by masses of neurons and glial cells with a rudimentary laminar organization located close to the periventricular germinal matrix [1,2]. PNH may be bilateral or unilateral. Genetic factors can play a major role in bilateral cases while acquired factors may be more important in the latter [3]. Focal epilepsy, most commonly drug-resistant, presents in childhood or early adulthood [4]. PNH often has intrinsic epileptogenicity but may not always be primarily involved in the generation of seizures [4–8]. Stereo-EEG (SEEG) studies found diverse, patient-specific networks, with seizure-onset being simultaneous in nodules and overlying or widespread cortical structures, or simultaneous in mesial temporal structures and ipsilateral adjacent heterotopia, or onset in the overlying cortex or the nodules alone [4,5,7,8]. Although an earlier study has characterized PNH as poorly responsive to traditional epilepsy surgery [9], others reported a high rate of seizure-freedom, similar to other lesional epilepsies [5]. Conflicting results were published recently on SEEG-guided thermocoagulation: as a very effective therapeutic approach for drug-resistant epilepsy related to PNH [7] and on contrary, having transitory, mild, or no effect [8].

There are only a few cases describing laser ablation in PNH (summaries and outcomes are shown in Table 1).

We present a case of a patient with PNH who displayed a specific epileptogenic network involving primarily the PNH and interestingly the “micronodules” in the adjacent white matter. The overlying cortex was not found to be primarily involved in the epileptic networks and so the patient was subsequently successfully treated with laser ablation aimed at the PNH and adjacent white matter.

2. Methods and results

A 28-year-old left-handed male patient with drug-resistant epilepsy was referred for pre-surgical evaluation. His seizures started at the age of 21 years with a generalized tonic-clonic seizure at which time he was started on levetiracetam. Previous perinatal and developmental history was unremarkable and he had no family history of seizures. The patient had a high school education and was working as a salesman. His neurological examination was normal.

During the course of his epilepsy, he had a total of five generalized tonic-clonic seizures, usually in association with missed anti-seizure medications. However, two years after the initial seizure, the patient started to have focal seizures preceded by an aura. He described the feeling “like entering a dream and object fading away.” He also felt that his voice sounded louder than everyone else. Following these auras, he would grin and laugh involuntarily. His seizure then evolved into a blank stare, with mouth and hand automatisms. He might speak out

* Corresponding author at: University Clinic of Neurology, Medical Faculty, Ss. Cyril and Methodius University, Vodnjanska str. 17, MK-1000, Skopje, Macedonia.
E-mail address: emilicvetkovska@gmail.com (E. Cvetkovska).

Table 1

Summary of reported cases of periventricular nodular heterotopia treated with laser ablation.

Reference	Pt	MRI findings	Ablation	Follow-up (months)	Outcome
Esquenazi Y et al. [10]	1	Unilateral PNH	Complete	12	IVb ^a
	1	Bilateral PNH	Partial	9	IIIa ^b
Clarke et al. [11]	1	Bilateral PNH	Complete	8	la
Thompson et al. [12]	1	Bilateral PNH + PMG + HS	Partial	12	Ia ^c
	1	Unilateral PNH + PMG	Partial	6	Ia

PMG – polymicrogyria; HS – hippocampal sclerosis.

^a Achieved seizure freedom with medication adjustment.

^b Achieved seizure freedom with subsequent anterior temporal lobectomy.

^c Anterior temporal lobectomy combined with laser ablation.

of context – his wife reports a well-formed sentence. These focal seizures occurred in clusters, approximately 2–3 clusters per month. He underwent a series of anti-seizure drug trials including zonisamide, lamotrigine, and lacosamide. Despite good compliance, his seizures persisted.

2.1. Non-invasive investigations

During scalp video-EEG monitoring interictal sharp waves were recorded over the right frontotemporal region. A total of seven focal seizures were recorded. The patient had an impairment of consciousness with the left arm/hand automatisms. He never pushed the seizure button but did remember having his aura of “confusion” or “things fading away” upon later interview. Seizure onset was localized in the right temporoparietal region (maximum T8-P8). A 3 T brain MRI with contrast (epilepsy protocol) showed three gray matter signal intensity foci along the right lateral ventricle, consistent with multiple nodular heterotopias. There was neither additional migrational abnormality nor mesial temporal sclerosis. Overlying cortex with gray-white distinction was unremarkable. FDG-PET showed mildly reduced FDG activity (5–10%) in the bilateral anterior temporal lobe and mesial temporal structure, mild asymmetry on the right. The right paraventricular heterotopia demonstrated mild FDG uptake. Neuropsychological testing

suggested that the patient's general level of ability ranged from average to high average. Based on clinical data and non-invasive evaluation, it was concluded that the patient suffers from drug-resistant focal epilepsy, likely arising from the right temporoparietal region. Available data indicated the possibility that epileptogenicity may involve the periventricular heterotopia, overlying cortex or/and also the hippocampal formation. SEEG exploration was proposed to determine the extent and type of surgery that could be offered.

2.2. Invasive investigation

SEEG evaluation was performed using a previously described technique detailed by Gonzalez-Martinez et al. [13]. A SEEG exploration targeted each of three heterotopic nodules, mesial and lateral temporal lobe structures, as well as operculo-insular and parietal cortices. Frequent small-amplitude spikes, usually in long runs, at times synchronized, as well as sequences of low voltage fast activity, were seen in all three heterotopic nodules. After cessation of his anti-seizure medications, the interictal epileptiform activity also involved the inferior temporal gyrus, temporal pole, anterior part of middle temporal gyrus and superior temporal sulcus. Surprisingly, interictal spikes, and low voltage fast activity were recorded from electrode contacts of electrode V(#5) located in white matter, on the way between heterotopic nodule and overlying cortex (temporal operculum and superior temporal gyrus). Localization of the electrode V, as well as an example of an interictal activity, are shown in Fig. 1. Finally, only rare spikes were seen from the hippocampus.

A total of 12 seizures were recorded out of sleep over a 15 h period. The EEG onset preceded clinical manifestations by 5 to 20 s. First, several seizures started within heterotopic nodules and almost simultaneously showed a clear evolution of low-voltage fast activity within the contacts in the nearby white matter which we will hitherto refer to as the “abnormal white matter”, and also rapidly involved the temporal pole, middle and inferior temporal gyrus (Fig. 2). In the latter seizures, the ictal-onset was identified simultaneously in heterotopic nodules, abnormal white-matter, and temporal neocortex. The clinical manifestations of the seizures consisted of a slight head turn to the left and rarely some swallowing or mouth or extremities movements. There is a suggestion that he doesn't fully understand commands

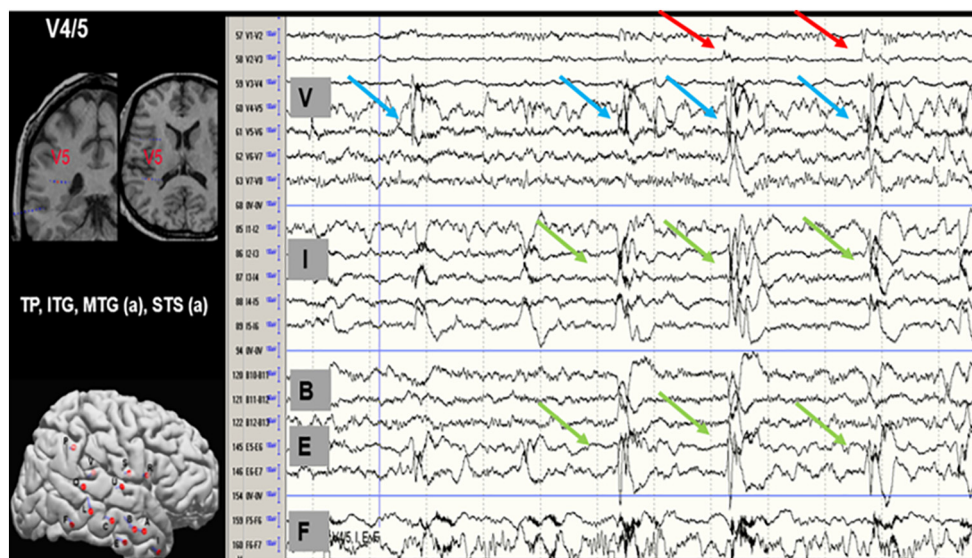


Fig. 1. Interictal activity. The left panel shows the anatomical locations of the recording sites (electrode V) on MRI and post-implantation map of recording electrodes. Localization of displayed electrodes' contacts: V1–2 in PNH, V3–5 in white matter, V6–8 in temporal operculum; I in temporal pole; B10–12 in superior temporal sulcus; E5–7 in lateral temporo-occipital sulcus; F5–7 in inferior temporal gyrus. Frequent interictal discharges are recorded in white matter (contacts V4–5; blue arrows) preceding or simultaneous with spikes in temporal operculum, temporal pole, superior temporal sulcus and inferior temporal gyrus (green arrows). Small spikes are seen in PNH (contacts V1–2; red arrows).

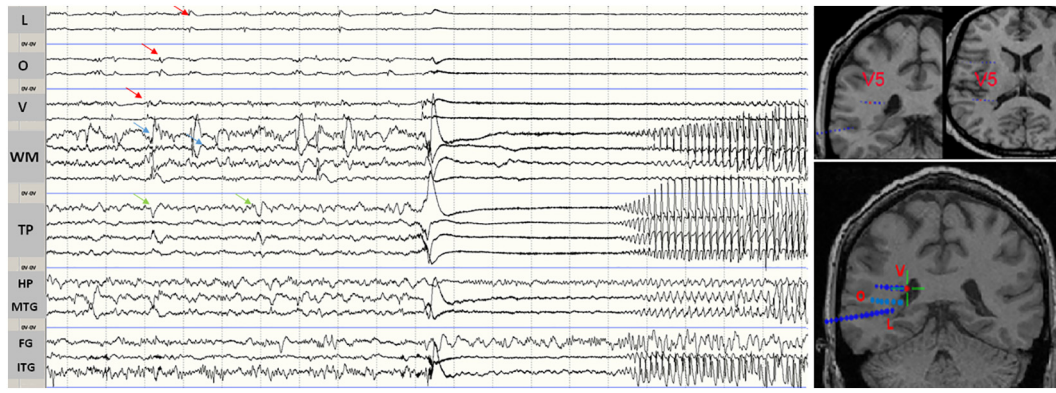


Fig. 2. Ictal SEEG. Prior to seizure onset, there is a build-up of repetitive spikes and fast activity involving the heterotopias (red arrows) and white matter (blue arrows), at times spreading to the temporal pole (green arrows). The seizure occurs in the heterotopias (electrodes L 1–3, O1–3, and V1–3), simultaneous with the white matter electrode (V4–6), which shows a clear evolution of low-voltage fast activity, rapidly involving the temporal pole, middle and inferior temporal gyrus. Bipolar montage; sensitivity 50 $\mu\text{V}/\text{mm}$; 1.5 cm/s. On the right side, MRI shows coregistration of electrodes in the heterotopias and white matter. L, O, and V: heterotopias; WM: white matter 'abnormality'; TP: temporal pole; HP: hippocampus; MTG: middle temporal gyrus; FG: fusiform gyrus; ITG: inferior temporal gyrus.

initially. He smiles at the interviewer but does not respond. Then in the later course of the seizures, he could talk or read.

Electrical stimulations were performed to map functionally eloquent regions. Square pulses of current were delivered between two contacts at high-frequencies (25 Hz, pulse width 1 ms, duration 3–5 s). The stimulation was started at 1 mA with 1 mA increments until the patient exhibited symptoms, afterdischarges were elicited, or a maximum of 10 mA was reached. No language impairment was mapped upon stimulation on the superior temporal gyrus. Cortical stimulation at 3–5 mA evoked typical aura from two of the heterotopic nodules (contacts V1–2 and L1–2).

To better understand the process of ictal propagation we used corticocortical evoked potential (CCEP), which reveals connectivity within brain networks. Details of the CCEP methodology have been

described elsewhere [14]. CCEPs can be used to study the propagation networks from stimulating within the ictal onset zone. In this case, CCEPs showed extensive connectivity of heterotopic nodules with the overlying cortex and adjacent cortices (Fig. 3).

The findings were discussed at patient management conference and the unequivocal agreement was that current data support the diagnosis of drug-resistant focal epilepsy likely arising from the heterotopic nodules. This was supported by frequent interictal epileptiform abnormalities as well as the ictal onset of typical seizures. There is also evidence of epileptogenicity in the vicinity of nodules (contacts V4/5) which might represent traces of gray matter into the white one. Lateral temporal neocortex in the anterior part of middle and inferior temporal gyrus, superior temporal sulcus as well as temporal pole seems to be triggered by heterotopic nodes as epileptogenic activity in this region is seen either

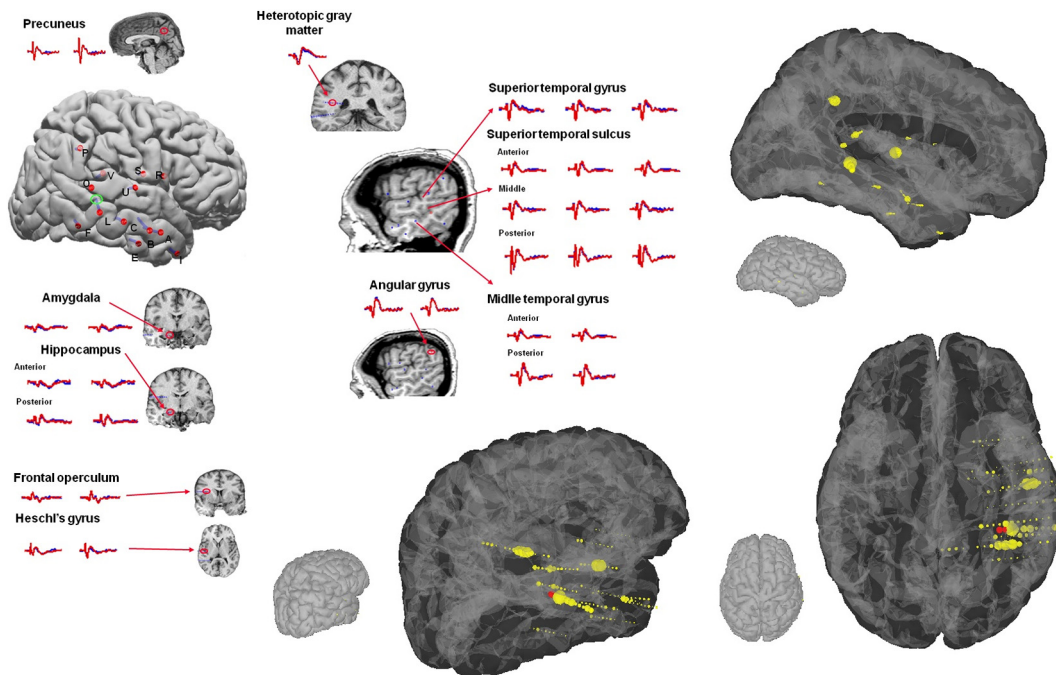


Fig. 3. Connectivity of PNH. CCEPs during stimulation of L1–2 (heterotopia – green circle) showed an extensive network that included not only the overlying cortex but also the frontal operculum, precuneus, angular gyrus, all banks of the superior temporal sulcus and mesial temporal structures (amygdala, hippocampus). The three adjacent panels shows the connectivity patterns in three different views. The SEEG contacts are scaled to represent the greatest strength of connectivity based on the standard deviation of the response. Note that the regions of greatest effective connectivity involves overlying temporal/parietal connectivity from the nodular heterotopia which was stimulated. The regions of connectivity match well with the various proposed surgical resection margins.

following heterotopic one or independently in the course of the cluster of seizures.

2.3. Surgical strategy

In addition to the analysis of the interictal and ictal ECoG patterns, the connectivity patterns demonstrated by CCEPs from stimulating the electrode pair in the PNH was used to opt for a laser ablation of the nodule and not to resect overlying cortex. (Fig. 3).

Subsequently, laser ablation of heterotopic nodules and the abnormal white matter was performed resulting in the patient being rendered seizure free. Retrospectively, an analysis was carried out looking at the pre-ictal to ictal transition period using a recently published bio-marker of epilepsy showed the particular time-frequency pattern termed “fingerprint” of the epileptogenic zone restricted to the PNH (Fig. 4) [15]. This analysis uses a software that extracts features from the time-frequency data after which a support vector machine classifies each contact pair to be within the epileptogenic zone or not. Although the abnormal white matter showed some features of the fingerprint such as the spiking that are used in classifying a contact pair within the epileptogenic zone, it did not feature all the patterns used in predicting the epileptogenic zone for all seizures. Notably the surrounding cortex was not predicted to be within the epileptogenic zone based on the finger print analysis.

2.4. Follow-up

The patient is currently seizure free for 16 months and we have been able to decrease the doses of his anti-seizure medications. Neuropsychological testing didn't show a decline in the patient's general level of ability.

3. Discussion

This patient illustrates the complexity of epileptogenicity in PNH. His seizures were noted to arise from heterotopic nodules, and on visual analysis almost simultaneously involving the adjacent white matter, which likely contained scattered heterotopic neurons (“micronodules”) as well as the adjacent lateral temporoparietal neocortex. Paraventricular heterotopic nodules can generate both normal and abnormal electrical activity [4,5] and recent reports on cohorts of patients evaluated with SEEG, have shown that seizures may arise from both the nodule and overlying cortex, the nodules alone or the cortex alone [7,8]. It is interesting to note that the three recorded seizures from a single patient with PNH showed different patterns, suggesting a vast epileptogenic network with great variety underlying seizure generation [16]. We observed a consistent epileptogenic zone prediction with the classifier that was trained to identify fingerprint pattern in cortical epilepsies [15]. The findings from this report can suggest that heterotopia share

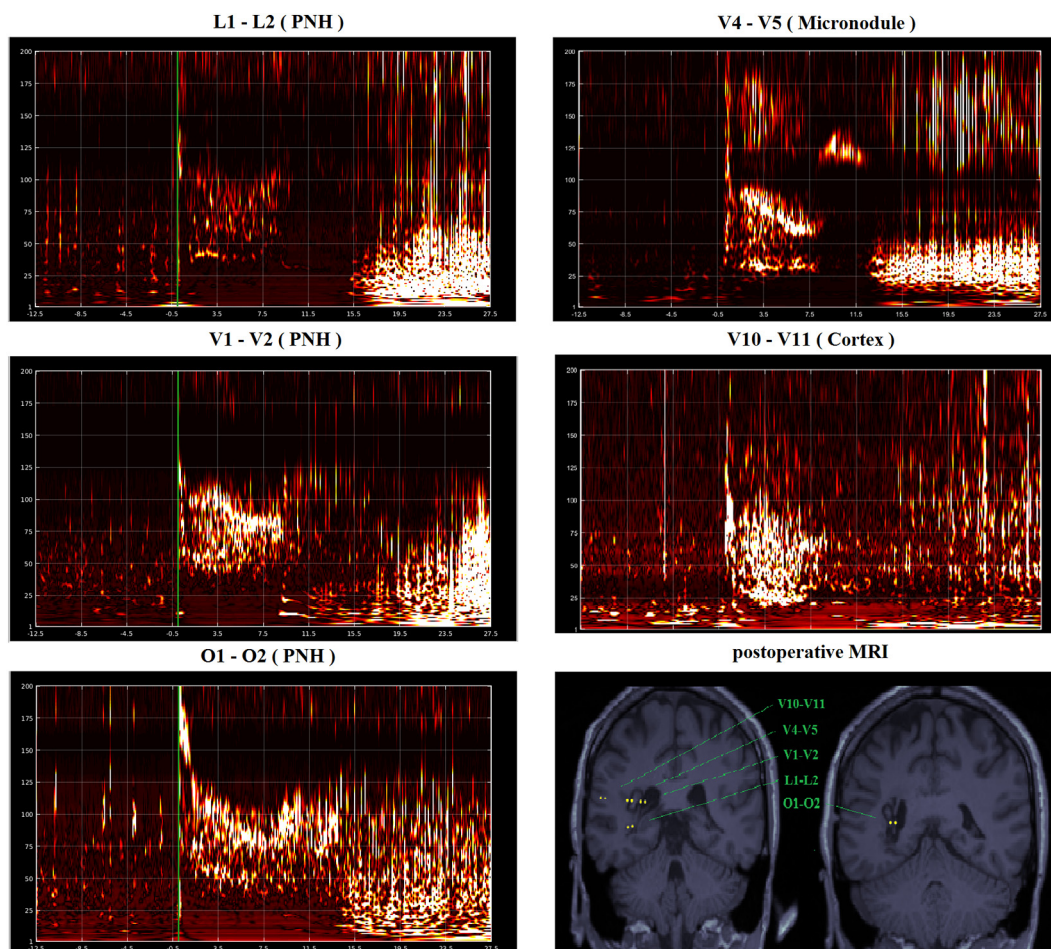


Fig. 4. Post-operative MRI shows SEEG-guided ablation of heterotopic nodules and adjacent white matter. The time-frequency plots of each contact pair at the pre-ictal to ictal transition shows the combination of features of pre-ictal spikes, multiband fast activity and simultaneous suppression of slower background frequencies. The contact pairs (L1–L2, V1–V2 and O1–2) in the periventricular nodular heterotopia (PNH) were identified by the machine learning algorithm classifier as showing features consistent with the epileptogenic zone based on the fingerprint analysis. Note that the contact pairs which were positive for the fingerprint of the epileptogenic zone all lie in the ablated zones. In comparison, contacts in the cortex (V10–V11) were not identified by the classifier as having features of the epileptogenic zone. Notably there is no clear suppression of frequencies or multiband fast activity. The contact pairs in the micronodule (V4–V5) show some features of the fingerprint on visual analysis but were not identified by the classifier as significant.

the same cellular structure with the cortex. Blumke et al., reported that heterotopia includes all types of interneurons as well as pyramidal cells [17]. Other authors have suggested that a heterotopia has rudimentary laminar structure [1].

It is interesting that the ictal pattern in the surrounding white matter also presents with spike and fast activity. Even though our automatic classification procedure did not identify this pattern as the epileptogenic zone, the presence of these elements suggests a particular cellular structure of “micronodules” and its significance in seizure generation.

Functional coupling and involvement of the hippocampus in seizure generation were shown both in SEEG as well as in vitro studies [4,18]. The mesial temporal structures did not seem to play a key role in ictogenesis our patient.

This case considers the possible role of “micronodules” scattered in white matter between PNH and overlying cortex, which seem to be able to produce electrical activity and get involved in seizure generation. In a group of patients with unilateral PNH, MRI revealed scattered radial bands, of the same signal intensity as gray matter, extended from the nodules to the adjacent cortex [5]. In postoperative specimens from those patients, numerous heterotopic neurons were present in the subcortical white matter and were more numerous in the vicinity of the nodules [5]. The existence of heterotopic neurons scattered within the white matter adjacent to the periventricular nodules was later described in a single patient with PNH who was successfully treated with temporal lobectomy including some of the heterotopic nodules [18]. We further appreciate their role as maybe another noteworthy player in the epileptic network of heterotopia.

While we cannot know for certain if the ablation of the PNH without micronodules in the adjacent white matter would have rendered the patient seizure free, we speculate this is unlikely due to the patient's interictal and ictal patterns in the SEEG evaluation. It clearly demonstrates interictal spikes originating from micronodules in white matter as well their immediate involvement in seizure generation. Epilepsy involving a PVNH may be viewed as network disease and probably the interplay of a number of components causes a clinical phenotype. The role of different constituents within epileptogenic networks is likely not the same in every case, as demonstrated by previous studies [4,5,7,8]. Subsequently, we could not suggest periventricular white matter ablation routinely, as ablation of PNH alone was enough to lead to a seizure-free outcome as has been shown in the past by other investigators [10–12]; we suggest that assessment of patient-specific networks should precede surgical planning. Our case in particular highlights the utilization of the fingerprint analysis of the epileptogenic zone and cortico-cortical evoked potentials to understand seizure propagation. These two approaches were used along with the SEEG analysis to explore various surgical options. Although our SEEG evaluation suggests that patient-specific networks are potentially contributory, the exact roles such as in generating, amplification and spread of ictal activity need to be evaluated across larger number of patients. The notion that epileptic networks may be variable in PNH [4,5] may be in line with our findings; whether the whole radial band from mesial to lateral need to be ablated should be assessed individually.

In addition, CCEPs study in our patient also showed extensive connectivity with cortex in the ipsilateral temporal lobe, directional from the heterotopic nodules to the regions of temporal and parietal neocortex also involved in the initial seizure propagation. The existence of functional connectivity between periventricular heterotopic and cortical neurons was also shown in a SEEG study [16] as well as by using resting-state MRI [19], whereas diffusion tensor tractography showed that a majority of heterotopias showed structural connectivity to discrete regions of overlying and non-overlying cortex [19].

Finally, a minimally invasive procedure of laser ablation of PNH and adjacent micronodules rendered our patient seizure-free and might be a valuable alternative to traditional surgical resections [5,9] and gamma knife radiosurgery [20]. Stereotactic laser ablation appears to be a safe and effective surgical option especially in the treatment of epileptogenic

foci near deep, eloquently situated brain structures [21,22]. The first use of magnetic resonance-guided laser interstitial therapy for PNH on two patients was reported by Esquenazi et al. [10]. Both patients tolerated the procedure well but achieved seizure freedom only after medication adjustment in the first patient and after subsequent anterior temporal lobectomy (ATL) in the second patient. Of note, the second patient's MRI revealed questionable right hippocampal sclerosis (HS), which was confirmed postoperatively. A third patient reported in the literature, by Clarke et al. [11] received laser ablation for the treatment of bilateral PNH with occipital dysplasia and remained seizure-free at 8 months follow-up with no neurological deficits. More recently, Thompson et al. [12] reported another two case studies of PNH. One patient, with bilateral, asymmetric (right > left) PNH, polymicrogyria and right hippocampal sclerosis, with seizures of complex origin involving PNH and mesial temporal structures, was treated with both a right ATL and laser ablation of the remaining right hemispheric nodules. At 12 months postablation, the patient remained seizure free. The second patient treated with laser ablation remained seizure-free at 6 months postsurgery. Three of the reported cases along with our patient demonstrate that focal laser ablations may be successful if the role of the PNH within the complex epileptogenic network is recognized. Other two patients which achieved seizure freedom only after combined ATL and laser ablation of nodules, has already demonstrated dual pathology on their MRIs. Subsequently, a minimally invasive and safe approach may be recommended prior to undergoing an extensive resection if the imaging and the electroclinical picture is concordant.

Of interest, the absence of neuropsychological decline after the intervention is in accordance with the notion that although electric stimulation of PNH elucidated its participation in higher cerebral functions, functional roles of heterotopia are, at least, nonessential [23].

4. Conclusion

This case report elucidates that neurons (“micronodules”) scattered in the white matter might be another contributor in complex and expanded epileptogenicity of heterotopia. Our study also confirms that despite the complexity, seizure freedom can be achieved in patients with PNH. Laser ablation aimed at eliminating patient-specific targets in the epileptic network revealed by SEEG creates the possibility to disrupt the pathological subcortical circuitry associated with seizures.

Funding

This research in this publication was supported in part by the National Institutes of Health under award RO1 NS089212 and RO1 EB026299. The content is solely the responsibility of the authors and does not necessarily represent the official views of the National Institute of Health.

Ethical statement

Informed consent was obtained from the patient.

References

- [1] Garbelli R, Rossini L, Moroni R, Watakabe A, Yamamori T, Tassi L, et al. Layer-specific genes reveal a rudimentary laminar pattern in human nodular heterotopia. *Neurology* 2009;73:746–53.
- [2] Barkovich AJ, Guerrini R, Kuzniecky R, Jackson G, Dobyn W. A developmental and genetic classification for malformations of cortical development: update 2012. *Brain* 2012;135:1348–69.
- [3] Battaglia G, Chiapparini L, Franceschetti S, Freri E, Tassi L, Bassanini S, et al. Periventricular nodular heterotopia: classification, epileptic history, and genesis of epileptic discharges. *Epilepsia* 2006;47(1):86–97.
- [4] Aghakhani Y, Kinay D, Gotman J, Soualmi L, Andermann F, Olivier A, et al. The role of periventricular nodular heterotopia in epileptogenesis. *Brain* 2005;128:641–51.
- [5] Tassi L, Colombo N, Cossu M, Mai R, Francione S, Lo Russo G, et al. Electroclinical, MRI and neuropathological study of 10 patients with nodular heterotopia, with surgical outcomes. *Brain* 2005;128:321–37.

- [6] Acar G, Acar F, Oztura I, Baklan B. A case report of surgically treated drug-resistant epilepsy associated with subependymal nodular heterotopia. *Seizure* 2012;21:223–6.
- [7] Mirandola L, Mai FR, Francione S, Pelliccia V, Gozzo F, Sartori I, et al. Stereo-EEG: diagnosis and therapeutic tool for periventricular nodular heterotopia epilepsies. *Epilepsia* 2017;58(11):1962–71.
- [8] Pizzo F, Roehri N, Catenoix H, Medina S, McGonigal A, Giusiano B, et al. Epileptogenic networks in nodular heterotopia: a stereoelectroencephalography study. *Epilepsia* 2017;58(12):2112–23.
- [9] Li LM, Dubeau F, Andermann F, Fish DR, Watson C, Cascino GD, et al. Periventricular nodular heterotopia and intractable temporal lobe epilepsy: poor outcome after temporal lobe resection. *Ann Neurol* 1997;41:662–8.
- [10] Esquenazi Y, Kalamangalam G, Slater J, Knowlton R, Friedman E, Morris S, et al. Stereotactic laser ablation of epileptogenic periventricular nodular heterotopia. *Epilepsy Res* 2014;547–554:108.
- [11] Clarke D, Tindall K, Lee M, Patel B. Bilateral occipital dysplasia, seizure identification, and ablation: a novel surgical technique. *Epileptic Disord* 2014;16(2):238–43.
- [12] Thompson S, Kalamangalam G, Tandon N. Intracranial evaluation and laser ablation for epilepsy with periventricular nodular heterotopia. *Seizure* 2016;41:211–6.
- [13] Gonzalez-Martinez J, Mullin J, Vadera S, Bulacio J, Hughes G, Jones S, et al. Stereotactic placement of depth electrodes in medically intractable epilepsy. *J Neurosurg* 2014;120:639–44.
- [14] Enatsu R, Kazutaka J, Elwan S, Kubota Y, Piao Z, O'Connor T, et al. Correlation between ictal and response to electrical cortical stimulation: a cortico-cortical evoked potential study. *Epilepsy Res* 2012;101:76–87.
- [15] Grinenko O, Li J, Mosher JC, Wang IZ, Bulacio JC, Gonzalez-Martinez J, et al. A fingerprint of the epileptogenic zone in human epilepsies. *Brain* 2018;141:117–31.
- [16] Valton L, Guye M, McGonigal A, Marquis P, Wendling F, Rergis R, et al. Functional interactions in brain networks underlying epileptic seizures in bilateral diffuse periventricular heterotopia. *Clin Neurophysiol* 2008;119:212–23.
- [17] Sarnat HB, Blümcke I. Malformations of cortical development. In: Blümcke I, Sarnat HB, Coras R, editors. *Surgical neuropathology of focal epilepsies: textbook and atlas*. Montrouge: John Libbey Eurotext; 2015. p. 41–4.
- [18] Kitaura H, Oishi M, Takei N, Fu YJ, Hiraishi T, Fukuda M, et al. Periventricular nodular heterotopia functionally couples with the overlying hippocampus. *Epilepsia* 2012;53(7):e127–31.
- [19] Christodoulou J, Walker L, Del Tufo S, Katzir T, Gabrieli JD, Whitfield-Gabrieli S, et al. Abnormal structural and functional brain connectivity in gray matter heterotopia. *Epilepsia* 2012;53(6):1024–32.
- [20] Wu C, Sperling M, Falowski S, Chitale A, Wasik M, Evans J, et al. Radiosurgery for the treatment of dominant hemisphere periventricular heterotopia and intractable epilepsy in a series of the three patients. *Epilepsy Behav Case Rep* 2013;1:1–6.
- [21] Curry DJ, Gowda A, McNichols RJ, Wilfong AA. MR-guided stereotactic laser ablation of epileptogenic foci in children. *Epilepsy Behav* 2012;24(4):408–14.
- [22] Curry DJ, Raskin J, Ali I, Wilfong AA. MR-guided laser ablation for the treatment of hypothalamic hamartomas. *Epilepsy Res* 2018;142:131–4.
- [23] Wagner J, Elger C, Urbach H, Bien C. Electric stimulation of periventricular heterotopia: participation in higher cerebral functions. *Epilepsy Behav* 2009;14:425–8.